

Association Between Atherosclerotic Aortic Plaques and Left Ventricular Hypertrophy in Patients With Cerebrovascular Events

João Carlos Hueb, Silméia G. Zanati, Katashi Okoshi, César N. Raffin, Liciana Vaz de Arruda Silveira and Beatriz B. Matsubara

Stroke. 2006;37:958-962; originally published online March 9, 2006;

doi: 10.1161/01.STR.0000208112.18484.e6

Stroke is published by the American Heart Association, 7272 Greenville Avenue, Dallas, TX 75231

Copyright © 2006 American Heart Association, Inc. All rights reserved.

Print ISSN: 0039-2499. Online ISSN: 1524-4628

The online version of this article, along with updated information and services, is located on the World Wide Web at:

<http://stroke.ahajournals.org/content/37/4/958>

Permissions: Requests for permissions to reproduce figures, tables, or portions of articles originally published in *Stroke* can be obtained via RightsLink, a service of the Copyright Clearance Center, not the Editorial Office. Once the online version of the published article for which permission is being requested is located, click Request Permissions in the middle column of the Web page under Services. Further information about this process is available in the [Permissions and Rights Question and Answer](#) document.

Reprints: Information about reprints can be found online at:
<http://www.lww.com/reprints>

Subscriptions: Information about subscribing to *Stroke* is online at:
<http://stroke.ahajournals.org/subscriptions/>

Association Between Atherosclerotic Aortic Plaques and Left Ventricular Hypertrophy in Patients With Cerebrovascular Events

João Carlos Hueb, MD, PhD; Silméia G. Zanati, MD; Katashi Okoshi, MD, PhD; César N. Raffin, MD, PhD; Liciana Vaz de Arruda Silveira, PhD; Beatriz B. Matsubara, MD, PhD

Background and Purpose—The purpose of this research was to evaluate whether an association exists between the presence of atherosclerotic plaque in the thoracic aorta and left ventricular hypertrophy (LVH) in patients with a cerebrovascular event.

Methods—We included 116 consecutive patients (79 men; mean age, 62 ± 12.4 years) with previous history of stroke or transient ischemic attack in a cross-sectional study. Transthoracic echocardiogram was performed to diagnose LVH and transesophageal echocardiogram for the detection of atheromas of the thoracic aorta. Continuous variables were analyzed by Student *t* or Mann-Whitney tests and categorized variables by Goodman test. From the significant association of LVH and age with atheromatous disease of the aorta, an adjustment to the multivariate logistic model was made using high blood pressure history or age as covariates. All of the statistical tests were carried out at a level of 5% significance.

Results—Almost half of the patients (43.1%) presented atherosclerotic lesions in the aorta. LVH was present in 90.0% of patients with plaque and in only 30.3% of patients without plaque. Using high blood pressure as a covariate, the risk of patients with LVH presenting atherosclerotic plaque in the aorta was 18.23-fold greater than the risk for patients without LVH (95% CI, 5.68 to 58.54; $P < 0.0001$). Adding age into the model, the risk increased to 26.36 (95% CI, 7.14 to 97.30; $P < 0.0001$).

Conclusions—LVH detected by conventional echocardiogram is associated with high risk of atherosclerotic plaque in the aorta and would be used as a criterion for indication of transesophageal echocardiography in patients with previous stroke or transient ischemic attack LVH. (*Stroke*. 2006;37:958-962.)

Key Words: echocardiography ■ left ventricular hypertrophy ■ stroke ■ transient ischemic attack

Several studies have shown the association of atheromas of the thoracic aorta with cerebrovascular events.¹⁻¹⁷ Its mechanism appears to be related to the migration of thrombi and cholesterol crystals, components which detach from the plaque located in the proximal thoracic aorta.¹¹ The risk of a cerebrovascular event (CVE) increases with plaque thickness and complexity.^{6,8,12,16,18}

Despite the fact that transesophageal echocardiography (TEE) is the elected method for detection of aortic and cardiac emboligenic source,¹⁹⁻²¹ this test is not performed on all patients suspected of cerebral emboli. The possible explanation is that such a test requires a special probe and a trained professional, in addition to the slight discomfort to the patient. On the other hand, transthoracic echocardiography (TTE), although cheaper and simpler to perform, has low accuracy for the study of the thoracic aorta.²¹ Therefore, it allows neither the identification nor the risk stratification for the embolic events of atheromatous disease of the aorta.

Evidence from the literature²²⁻³⁶ indicates that the development of atherosclerotic lesions and myocardial remodeling share common pathological mechanisms. If this assumption is correct, it is reasonable to hypothesize that structural cardiac alteration indicating remodeling could be associated with the presence of atherosclerotic plaque of the aorta in patients seized by CVE. The objectives of the present study were as follows: (1) to evaluate the incidence of atherosclerotic plaque in the thoracic aorta in patients with a previous history of stroke or transient ischemic attack (TIA) by TEE, and (2) to evaluate whether there is an association between the presence of these plaques and left ventricular hypertrophy (LVH) observed by TTE.

Methods

Study Population

This study was approved of by the Committee of Ethics in Research of the Botucatu Medical School. All of the patients or their guardians

Received December 13, 2005; final revision received January 13, 2006; accepted January 20, 2006.

From the Departments of Internal Medicine (J.C.H., S.G.Z., K.O., B.B.M.) and Neurology (C.N.R.), Botucatu Medical School—Unesp, Sao Paulo, Brazil; and the Department of Statistics (L.V.d.A.S.), Institute of Biosciences, Botucatu—Unesp, Sao Paulo, Brazil.

Correspondence to João Carlos Hueb, MD, PhD, Departamento de Clínica Médica, Faculdade de Medicina, Distrito de Rubiao Jr. S/n, 18618-000, Botucatu, Sao Paulo State, Brazil. E-mail jchueb@uol.com.br

© 2006 American Heart Association, Inc.

Stroke is available at <http://www.strokeaha.org>

DOI: 10.1161/01.STR.0000208112.18484.e6

signed a Term of Free Informed Consent. The cross-sectional study included patients with prior stroke or TIA in the period from March 2001 to November 2002. We studied 116 patients (79 men) with ages ranging from 26 to 82 years (62 ± 12.4 years). Most of them (79.3%) were white, and 20.7% were African Brazilian.

Clinical Evaluation

Neurological evaluation was performed by an expert neurologist using tomographic and clinical criteria for diagnosis, including etiology definition and whether the patient suffered from stroke or TIA. A complete medical history and physical examination were performed, and heart rate, systolic blood pressure (SBP), and diastolic blood pressure (DBP) were recorded.

TTE

All of the procedures were performed by an expert echocardiographer using Sonos 2000 (Hewlett Packard) equipment attached to a multifrequency 2.5- to 3.5-MHz transducer. The echocardiograms were performed with the patients in left decubitus and the upper left limb slightly flexed beneath the head. The images were obtained according to the American Society of Echocardiography recommendations³⁷ and recorded on video cassette.

Systolic and diastolic left ventricular (LV) dimensions (LVd) and systolic and diastolic function indexes were obtained. LV diastolic function was evaluated by isovolumetric relaxation time (IVRT), E-wave deceleration time, and transmitral flow early:late transmitral flow velocities ratio (E/A ratio).³⁸

Myocardial hypertrophy was defined as the increase in either wall thickness and/or LV mass (MM). The interventricular septum or posterior wall thickness (PWd) ≥ 12 mm was indicative of hypertrophy.^{39,40} PWd normalized to LVd (PWd/LVd) >0.2 was also interpreted as myocardial hypertrophy.^{39,40} Bennett's equation was used to calculate LV mass as follows: $MM(g) = [(2PWd + LVd)^3 - LVd^3] \times 1.05$, where the normal upper limit is 294 g for males and 198 g for females.⁴¹

TEE

The transesophageal examination was performed by the same examiner after the conclusion of the transthoracic echocardiogram using the same equipment attached to a 6-MHz frequency multiplane transducer. Patients, advised previously to maintain a 4-hour fast, were submitted to oropharyngeal anesthesia with lidocaine spray and placed in left decubitus with the left arm under the head, which was kept in a flexed position. The transducer was introduced through the mouth and into the esophagus and gastric cavity for visualization of the cardiac and aorta structures. When the existence of aortic atheroma was detected, the following characteristics were recorded: thickness, prominence, presence of thrombi, and mobile projections. A simplified classification was adopted where the plaques were considered "simple" if thickness was <5 mm and "complex" if thickness was ≥ 5 mm, with thrombi and mobile projections.

Statistical Analysis

Analysis of the quantitative variables (SBP, DBP, age, interventricular septum, PWd, PWd/LVd, MM, IVRT, E-wave deceleration time, and E/A) in function of the presence of atherosclerotic plaque in the proximal thoracic aorta or according to plaque type were performed using the Student *t* test or Mann-Whitney test, and the results are presented in tables showing descriptive statistics and statistical test values.⁴² The presence of LVH, a qualitative variable, was analyzed by the Goodman test.^{43,44}

As LVH, age and history of high blood pressure (HBP) were associated with aortic atheroma, and a multivariate logistic model was fitted considering the presence/absence of atherosclerosis as a response variable. First, the model was fitted using only LVH as a predictor. Then, history of HBP and age (<60 or ≥ 60 years old) were included in the model. The odds ratio (OR) and 95% CI were obtained for each explanatory variable. Data were analyzed using standard statistical software (SAS for windows, version 8.02). A *P* value of <0.05 was considered significant.

Results

Fifty of 116 patients (43.1%) presented atheromatous disease in the thoracic aorta, and in 29 of them, the plaques were categorized as complex. The remaining 21 patients showed simple plaques. Complex plaques were more frequent in older patients. Typically, atheromas were located in the proximal descending aorta. Lesions in either the ascending aorta or aortic arch were less frequent.

The patients in the group with aortic atheroma were older (69.0 ± 6.6 versus 54.5 ± 9.0 years; $P < 0.0001$) and presented higher SBP and DBP (SBP: 145.8 ± 23.3 versus 131.4 ± 17.8 mm Hg, $P < 0.0005$; DBP: 92.4 ± 14.6 versus 85.8 ± 13.5 mm Hg, $P < 0.05$). In this group, the history of HBP was more frequent (92.0% versus 46.9%; $P < 0.05$).

Morphometric data are presented in Table 1. Wall thickness and LV mass were significantly higher in the group with plaque, and it should be noted that, of the patients with plaque, 90.0% presented LV hypertrophy whereas, in the group without plaque, this prevalence was only 30.3% (Figure). No significant difference was found between the subgroups with simple and complex plaque. Using the univariate logistic regression analysis, patients with LVH presented a 14.66-fold greater risk of showing atherosclerotic plaque in the aorta than patients without LVH (OR, 14.66; 95% CI, 3.24 to 38.13; $P < 0.0001$). The adjustment for age showed that patients who were <60 years old also presented a higher risk of atherosclerotic disease in aorta (OR, 11.1; 95% CI, 3.24 to 38.13; $P = 0.0002$). The risk increased in older patients (OR, 19.35; 95% CI, 6.65 to 56.34; $P < 0.0001$). Adding previous history of hypertension as a covariate, the risk of atheromatous disease in the aorta increased to 26.36 (95% CI, 7.14 to 97.30; $P < 0.0001$) in those with HBP and LVH. Patients with LVH and no history of HBP presented a still-elevated risk of atherosclerotic plaque (OR, 4.22; 95% CI, 1.91 to 9.32; $P = 0.0004$).

There was no association between either LV chamber diameters or LV systolic function indexes with the presence of aortic atheroma. However, the group with plaque showed greater diastolic dysfunction when compared with the group without plaque (Table 2).

Discussion

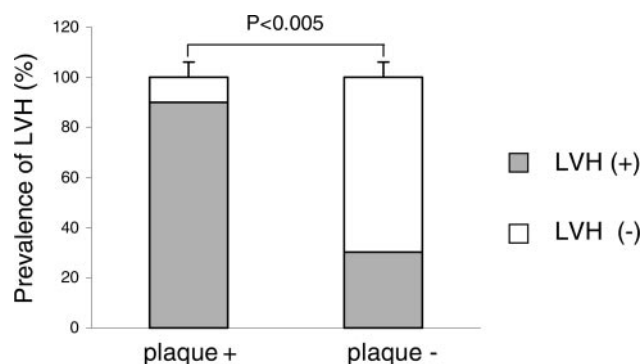
LVH and Atherosclerotic Plaque in the Aorta

Echocardiographic data indicating greater LV mass and/or wall thickness in the group with plaque and the higher

TABLE 1. Echocardiographic Data and Atherosclerotic Aortic Plaque Status

| Variable | Group | | Statistical Test |
|----------|--------------------|-----------------------|-----------------------|
| | With Plaque (n=50) | Without Plaque (n=66) | |
| ISd, mm | 13.9 ± 2.43 | 10.6 ± 2.28 | 7.32 ($P < 0.0001$) |
| PWd, mm | 13.6 ± 2.13 | 10.5 ± 2.15 | 7.58 ($P < 0.0001$) |
| PWd/LVd | 0.31 ± 0.06 | 0.23 ± 0.06 | 6.91 ($P < 0.0001$) |
| MM, g | 299.3 ± 77.96 | 221.8 ± 70.51 | 5.60 ($P < 0.0001$) |

ISd and PWd indicate diastolic interventricular septum and posterior wall thickness, respectively; MM, LV mass.



Bar graph showing significantly higher prevalence of LVH in patients with atherosclerotic plaque in the thoracic aorta (plaque+) vs patients without plaque (plaque-).

prevalence of LVH in those with atheromatous disease of the thoracic aorta strongly suggest an association between LVH and plaque in the aorta. These findings are in accordance with other studies. Verdecchia et al⁴⁵ prospectively evaluated 2363 patients with arterial hypertension in a 5-year follow-up period, recording 105 patients seized by CVE. In this group, the prevalence of LVH, as detected by TTE and ECG, was greater than in the other patients. Selvetella et al⁴⁶ showed an association between LVH, detected by ECG and echocardiogram, and cerebral ischemic lesions diagnosed by electromagnetic resonance in asymptomatic patients who had arterial hypertension. Di Tullio et al⁴⁷ published a case-control study including 431 patients with ischemic CVE. The authors described high incidence of LVH, diagnosed by echocardiograms in these patients. The authors did not address the mechanisms beneath these observations. The results of the present study indicate a clear association between LVH and atherosclerotic plaque in the thoracic aorta, adding another piece of evidence, which could eventually help to clarify this issue.

Although the exact mechanism of the association between LVH and atherosclerotic lesions in the aorta remains undefined, several physiopathological possibilities can be surmised. First of all, it is well known that not only hemodynamic factors play a role in the development of LVH. Humoral factors, such as angiotensin II and noradrenaline, are associated with myocardial growth.³¹ Angiotensin II and endothelin participate in the development of myocardial hypertrophy by acting on cellular membrane receptors and inducing protein synthesis as a part of a complex process.³³ Other than its important role in LV remodeling,³⁰⁻³⁴ angiotensin II actively participates in atherogenesis.²²⁻²⁹ It is well

known that circulating monocytes containing angiotensin-converting enzyme (ACE) can penetrate the vascular wall after endothelial dysfunction and/or damage. Those cells transform themselves into foam cells containing ACE, which provokes local synthesis of angiotensin II. In the vascular wall, angiotensin II stimulates the production of growth factors, cytokines, and oxidized low-density lipoproteins, contributing to the formation and instability of atheromas.²³ It is worth emphasizing that angiotensin II also presents other important effects on atherogenesis, such as increased oxidative stress of the vessel walls, the release of endothelin, and the degradation of NO, along with the uncoupling of NO synthase.²⁹ An important evidence of the association between LVH and atherosclerosis was reported in several studies on the ACE gene, which presents the polymorphisms DD, ID, and II. Genotype DD is associated with remarkably higher levels of ACE, LVH, and atherosclerosis.^{27,33,34,36} This physiopathological mechanism reveals the evident relation between atherogenesis and cardiac remodeling, justifying the association found in the present study between atheromatous disease of the aorta and LVH.

Curiously, cardiac morphofunctional alterations did not present any relation to plaque characteristics. Both subgroups, with simple or complex plaques, were similar as cardiac alterations were concerned. Although our findings would suggest that the complexity of the atherosclerotic lesions in the aorta bear no relation to the determinant factors for atherosclerosis, these results have to be interpreted cautiously, given the several factors involved in the development and complexity of the plaque. Also, atherosclerosis plaques present a dynamic morphology, which can modify over a short period of time, rapidly changing from simple to complex and vice versa.¹³

LV Diastolic Function and Plaque in the Aorta

The LV diastolic function indexes, transmitral flow E/A ratio, E wave deceleration time, and LV IVRT showed greater diastolic dysfunction in the group with plaque as compared with the group without plaque. This difference was expected, given the greater myocardial hypertrophy in those patients. Typically, increased myocardial mass is accompanied by other structural alterations, which compromise the ventricular function.⁴⁸ It seems that those alterations are closely related to activation of the renin-angiotensin-aldosterone system.^{35,49} Therefore, it is possible to suggest that the association of atherosclerosis in the aorta with LV diastolic dysfunction would have other mechanisms than just the presence of myocardial hypertrophy.

The Influence of Age and HBP

Patients seized by CVE in the presence of LVH demonstrated ≈ 15 times greater risk of presenting plaque in the aorta when compared with patients without LVH. This risk remained elevated when the model was adjusted to include only those patients aged <60 years. The adjustment of the multivariate logistic model, including previous history of hypertension and age, markedly increased the risk of aortic atheroma in the presence of LVH. Patients without a previous history of hypertension and presenting LVH at TTE also had an

TABLE 2. LV Diastolic Dysfunction Indexes and Atherosclerotic Aortic Plaque Status

| Variable | Group | | Statistical Test |
|----------|--------------------|-----------------------|-----------------------|
| | With Plaque (n=50) | Without Plaque (n=66) | |
| IVRT, ms | 144.2 \pm 24.17 | 114.5 \pm 34.34 | 5.21 ($P < 0.0001$) |
| EDT, ms | 285.6 \pm 60.72 | 258.5 \pm 66.27 | 2.27 ($P < 0.05$) |
| E/A | 0.63 \pm 0.11 | 0.77 \pm 0.29 | 3.73 ($P < 0.0005$) |

EDT indicates E-wave deceleration time.

increased risk of aortic disease. These findings would allow us to affirm that LVH could be an independent marker of atherosclerotic aortic plaques in patients without other medical conditions associated with myocardial hypertrophy, other than arterial hypertension.

Clinical Implications

Click et al¹⁹ proposed an algorithm for TEE indication in the evaluation of emboligenic source after TTE. The authors claimed that the only presumable factor of atherosclerosis plaque in the aorta indicating a need for TEE is the presence of atherosclerotic disease in the peripheral and/or coronary circulation. Because atheromatous disease of the aorta is not always associated with clinical manifestations of atherosclerotic disease in coronary or peripheral circulation, it is possible that many patients suffering from that condition would be excluded from the possibility of diagnosis, with relevant clinical implications.

Therefore, the most relevant clinical implication of the present study is the suggestion that, in the presence of LVH, patients at risk of CVE, that is, those who are older and/or with arterial hypertension, should be submitted for tests to detect atherosclerotic plaques in the thoracic aorta. The examination recommended for this purpose is the transesophageal echocardiogram, which is not routinely performed for early identification of the risk of embolic events. In most cases, patients are submitted to TEE to search for an embolic source when CVE has already occurred. It is important to emphasize that even patients seized by CVE are not always addressed for TEE, remaining at risk of new embolic episodes. However, the indication of TEE for all patients at risk of CVE would require additional studies to confirm the association between LVH and clinically relevant atheromatous disease in the aorta in patients without CVE. We concluded that LVH detected by conventional echocardiogram is associated with high risk of atherosclerotic plaque in the aorta and would be used as a criterion for the indication of TEE in patients with previous stroke or TIA.

References

- Kronzon I, Tunick PA. Atheromatous disease of the thoracic aorta: pathologic and clinical implications. *Ann Intern Med.* 1997;126:629–637.
- Dressler FA, Craig WR, Castello R, Labovitz AJ. Mobile aortic atheroma and systemic emboli: efficacy of anticoagulation and influence of plaque morphology on recurrent stroke. *J Am Coll Cardiol.* 1999;33:899–907.
- Kessler C, Mitusch R, Guo Y, Rosengart A, Sheikhzadeh A. Embolism from the aortic arch in patients with cerebral ischemia. *Thromb Res.* 1996;84:145–155.
- Mitusch R, Tepe C, Stierle U, Schwabe K, Potratz J, Kummer-Kloess D, Kessler C, Sheikhzadeh A. Determinants of arterial embolism with special reference to atheromatous changes of the thoracic aorta. *Z Kardiol.* 1995;84:198–204.
- Nihoyannopoulos P, Athanasopoulos G, Oakley CM. Detection of atherosclerotic lesions in the aorta by transesophageal echocardiography. *Am J Cardiol.* 1993;71:1208–1212.
- Heinzle O, Cohen A, Amarenco P. Atherosclerotic aortic plaques and risk of embolic stroke. *Rev Neurol.* 2001;157:619–631.
- Tunick PA, Kronzon I. Atheromas of the thoracic aorta: clinical and therapeutic update. *J Am Coll Cardiol.* 2000;35:545–554.
- Amarenco P, Duyckaerts C, Tzourio C, Henin D, Bousser MG, Hauw JJ. The prevalence of ulcerated plaques in the aortic arch in patients with stroke. *N Engl J Med.* 1992;326:221–225.
- Amarenco P, Cohen A, Tzourio C, Bertrand B, Hommel M, Besson G, Chauvel C, Touboul PJ, Bousser MG. Atherosclerotic disease of the aortic arch and risk of ischemic stroke. *N Engl J Med.* 1994;331:1474–1479.
- Toyoda K, Yasaka M, Nagata S, Yamaguchi T. Aortogenic embolic stroke: a transesophageal echocardiographic approach. *Stroke.* 1992;23:1056–1061.
- Karalis DG, Chandrasekaran K, Victor MF, Ross JJ, Mintz GS. Recognition and embolic potential of intraortic atherosclerotic debris. *J Am Coll Cardiol.* 1991;17:73–78.
- Jones EF, Kalman JM, Calafiore P, Tonkin AM, Donnan GA. Proximal aortic atheroma. An independent risk factor for cerebral ischemia. *Stroke.* 1995;26:218–224.
- Montgomery DH, Vervesis JJ, McGorisk G, Frohwein S, Martin RP, Taylor WR. Natural history of severe atheromatous disease of the thoracic aorta: transesophageal echocardiographic study. *J Am Cardiol.* 1996;27:95–101.
- Khatibzadeh M, Mitusch R, Stierle U, Gromoll B, Sheikhzadeh A. Aortic atherosclerotic plaques as a source of systemic embolism: atherosclerotic lesions in the aorta by transesophageal echocardiography. *Am J Cardiol.* 1993;71:1208–1217.
- Di Tullio MR, Sacco RL, Savoia MT, Sciacca RR, Homma S. Aortic atheroma morphology and the risk of ischemic stroke in a multiethnic population. *Am Heart J.* 2000;139:329–336.
- Tunick PA, Perez BA, Kronzon I. Protruding atheromas in the thoracic aorta and systemic embolization. *Ann Intern Med.* 1991;115:423–427.
- Vaduganathan P, Ewton A, Nagueh SF, Welbaecker DG, Safi HJ, Zoghbi WA. Pathologic correlates of aortic plaques, thrombi and mobile “aortic debris” imaged in vivo with transesophageal echocardiography. *J Am Coll Cardiol.* 1993;30:357–363.
- Tunick PA, Rosenzweig BP, Katz ES, Freedberg RS, Perez JL, Kronzon I. High risk for vascular events in patients with protruding aortic atheromas: a prospective study. *J Am Coll Cardiol.* 1994;23:1085–1090.
- Click LC, Espinosa RE, Khandheria BK. Source of embolism. In: Freeman WK, ed. *Transesophageal Echocardiography.* Boston, Mass: Little Brown and Company; 1994:469–499.
- Toyoda K, Yasaka M, Yamashita N, Imakita S, Yamaguchi T. Transesophageal echocardiography for detecting intracardiac thrombi in embolic stroke. *Angiology.* 1993;44:376–383.
- Cujec B, Polasek P, Voll C, Shuaib A. Transesophageal echocardiography in the detection of potential cardiac source of embolism in stroke patients. *Stroke.* 1991;26:727–733.
- Metzger R, Bohle RM, Chumachenko P, Danilov SM, Franke FE. CD143 in the development of atherosclerosis. *Atherosclerosis.* 2000;150:21–31.
- Scholkens BA, Landgraf W. ACE inhibition and atherosclerosis. *Can J Physiol Pharmacol.* 2002;80:354–359.
- Kim JA, Berliner JA, Nadler JL. Angiotensin II increases monocyte binding to endothelial cells. *Biochem Biophys Res Commun.* 1996;226:862–868.
- Sleigh P. The hope study (Heart outcomes prevention evaluation). *J Renin Angiotensin Aldosterone Syst.* 2000;1:18–20.
- Wilfert K, Guski H, Persson PB, Stauss HM. Cardiovascular responses to angiotensin II in atherosclerosis. *Acta Physiol Scand.* 2002;176:95–100.
- Miyazaki M, Takai S. Involvement of angiotensin II in development of atherosclerosis. *Nippon Rinsho.* 2002;60:1904–1910.
- Hope S, Breccher P, Chobanian AV. Comparison of the effects of AT1 receptor blockade and angiotensin converting enzyme inhibition on atherosclerosis. *Am J Hypertens.* 1999;12:28–34.
- Schiffirin EL. Beyond blood pressure: the endothelium and atherosclerosis progression. *Am J Hypertens.* 2002;15:115S–22S.
- Lonn E. Dose response of ACE inhibitors: implications of the SECURE trial. *Curr Control Trials Cardiovasc.* 2001;2:15515–15519.
- Frohligh ED, Dustan HP, Marcus M. The heart in hypertension. *N Engl J Med.* 1992;327:998–1008.
- Martinez Filho EE, Balestrini CS. Hipertrofia ventricular esquerda e hipertensão. *Hipertensão.* 2002;5:92–102.
- Schunckert H, Hense H, Holmer SR, Stender M, Perz S, Keil U, Lorell B, Riegger GAJ. Association between a deletion polymorphism of the angiotensin-converting-enzyme gene and left ventricular hypertrophy. *N Engl J Med.* 1994;330:1634–1638.
- Lechin M, Quimones MA, Omran A, Hill R, Yu Q, Rakowski H, Wigle D, Liew CC, Sole M, Roberts R, Marian AJ. Angiotensin-I converting enzyme genotypes and left ventricular hypertrophy in patients with hypertrophic cardiomyopathy. *Circulation.* 1995;92:1808–1812.
- Izar COM, Ihara SSM, Relvas WGM. Preditores genéticos da aterosclerose coronariana. *Rev Soc Cardiol Estado São Paulo.* 2000;10:761–768.

36. Weber KT, Sun Y, Guarda E. Structural remodeling in hypertensive Heart disease and the role of hormones. *Hypertension*. 1994;6:869–877.
37. Sahn DJ, DeMaria A, Kissio J, Weiman A. Recommendations regarding quantitation in M-mode echocardiography: results of a survey of echocardiographic measurements. *Circulation*. 1978;58:1072–1079.
38. Rakowski H, Appleton C, Chan KL, Dumesnil JG, Honos G, Jue J, Koilpillai C, Lepage S, Martin RP, Mercier LA, O' B, Prieur T, Sanfilippo A, Sasson Z, Alvarez N, Pruitt R, Thompson C, Tomlinson C. Canadian consensus recommendations for the measurement and reporting of diastolic dysfunction of echocardiography: from the investigators of Consensus of Diastolic Dysfunction by Echocardiography. *J Am Soc Echocardiogr*. 1996;9:736–760.
39. Grant C, Greene DG, Bunnell IL. Left ventricular enlargement and hypertrophy. A clinical and angiographic study. *Am J Med*. 1965;39:895–907.
40. Siogren AL. Left ventricular wall thickness in patients with circulatory overload of the left ventricle. Ultrasonic, physical, electrocardiographic and radiologic correlations. *Ann Clin Res*. 1972;4:310–319.
41. Bennett DH, Evans DW. Correlation of left ventricular mass determined by echocardiography with vectorcardiographic and electrocardiographic voltage measurements. *Br Heart J*. 1974;36:981–993.
42. Norman GR, Streiner DL. *Biostatistics: The Bare Essentials*. St. Louis, Mo: Mosby Book; 1994.
43. Goodman LA. Simultaneous confidence intervals for contrast among multinomial populations. *Ann Math Stat*. 1964;35:716–725.
44. Goodman LA. On simultaneous confidence intervals for multinomial proportions. *Tedinometrics*. 1995;7:247–254.
45. Verdecchia P, Porcellati C, Reboldi G, Gattobigio R, Borgioni C, Pearson T, Ambrosio J. Left ventricular hypertrophy as an independent predictor of acute cerebrovascular events in essential hypertension. *Circulation*. 2001;104:2039–2044.
46. Selvetella G, Notte A, Maffei A, Calistri V, Scamardella V, Frati G, Trimarco B, Colonnese C, Lembo G. Left ventricular hypertrophy is associated with asymptomatic cerebral damage in hypertensive patients. *Stroke*. 2003;34:1766–1770.
47. Di Tullio MR, Zwas DR, Sacco RL, Sciacca RR, Homma S. Left ventricular mass and geometry and risk of ischemic stroke. *Stroke*. 2003;34:2380–2384.
48. Janicki JS, Matsubara BB. Myocardial collagen and left ventricular diastolic dysfunction. In: Gaasch W, LeWinter M, eds. *Left Ventricular Diastolic Dysfunction and Heart Failure*. Philadelphia, Pa: Lea & Febiger; 1994:125–140.
49. Clarkson PBM, Wheleldon NM, MacLeod C, Tennent M, MacDonald TM. Effects of angiotensin II and aldosterone on diastolic function in vivo normal man. *Clin Sci*. 1994;87:397–401.