

## Low-Level Laser Therapy in Pediatric Bell's Palsy: Case Report in a Three-Year-Old Child

Carla Raquel Fontana, PhD<sup>1</sup> and Vanderlei Salvador Bagnato, PhD<sup>2</sup>

### Abstract

**Objectives:** The objective of this study was to apply low-level laser therapy (LLLT) to accelerate the recovery process of a child patient with Bell's palsy (BP). **Design:** This was a prospective study.

**Subject:** The subject was a three-year-old boy with a sudden onset of facial asymmetry due to an unknown cause.

**Materials and methods:** The low-level laser source used was a gallium aluminum arsenide semiconductor diode laser device (660 nm and 780 nm). No steroids or other medications were given to the child. The laser beam with a 0.04-cm<sup>2</sup> spot area, and an aperture with approximately 1-mm diameter, was applied in a continuous emission mode in direct contact with the facial area. The duration of a laser session was between 15 and 30 minutes, depending on the chosen points and the area being treated. Light was applied 10 seconds per point on a maximum number of 80 points, when the entire affected (right) side of the face was irradiated, based on the small laser beam spot size. According to the acupuncture literature, this treatment could also be carried out using 10–20 Chinese acupuncture points, located unilaterally on the face. In this case study, more points were used because the entire affected side of the face (a large area) was irradiated instead of using acupuncture points.

**Outcome measures:** The House-Brackmann grading system was used to monitor the evolution of facial nerve motor function. Photographs were taken after every session, always using the same camera and the same magnitude. The three-year-old boy recovered completely from BP after 11 sessions of LLLT. There were 4 sessions a week for the first 2 weeks, and the total treatment time was 3 weeks.

**Results:** The result of this study was the improvement of facial movement and facial symmetry, with complete reestablishment to normality.

**Conclusions:** LLLT may be an alternative to speed up facial normality in pediatric BP.

### Introduction

**F**ACIAL NERVE PARALYSIS may be congenital or neoplastic or may result from trauma, toxic exposures, iatrogenic causes, autoimmune inflammation, vascular ischemia, or infections.<sup>1,2</sup> This problem can also be caused by a degenerative cerebral disease, the Guillain-Barré syndrome, or other diseases that affect the nerves and any associated tissues.<sup>3</sup>

The most frequent nontrauma-related etiologies in otherwise neurologically intact patients is the idiopathic dysfunction of the cranial nerve VII, called Bell's palsy (BP), which has a good prognosis. The facial nerve has motor, sensory, and parasympathetic fibers. Among its functions are the vital control of the facial expression, taste to the anterior two thirds of the tongue, and salivary and lachrymal-gland secretion. The main sign for BP is a distorted facial expression, but patients can experience symptoms (e.g., taste loss,

pain around the ear, or hearing problems<sup>1,4</sup>). One of the main differential diagnoses for central paralysis versus BP is that only the voluntary movement of the lower face is affected, without any loss of taste, salivary, and lachrymal secretions. Patients with those characteristics should immediately be referred to a neurologist.<sup>1,4,5</sup>

Warning signs for a serious underlying cause are otitis media (osteomyelitis), hearing loss, lymphadenopathy, tonsillar enlargement (parotid tumor), mastoid enlargement, frontal sparing, and motor function of tongue/fingers for a duration of longer than 1 month. Physical examination, including otoscopy, and examination of the parotid and cranial nerves are important in order to determine the cause and the location of facial nerve injury. The involvement of other cranial nerves can be a sign of polyneuropathy or malignancy and a concomitant involvement of the VI pair reveals a pathology of the brainstem, V, VI, and VIII, pathology of

<sup>1</sup>Department of Clinical Analysis, School of Pharmaceutical Sciences, Univ Estadual Paulista (UNESP), Araraquara, SP, Brazil.

<sup>2</sup>Institute of Physics of São Carlos, University of São Paulo (USP), São Carlos, SP, Brazil.

the petrous apex, and the IX, X, and XI, pathology of the skull base.<sup>1,5,6</sup>

Although most cases of facial palsy are idiopathic, their diagnosis can be determined only after having ruled out all other possible etiologies.<sup>7,8</sup>

The prevalence of BP is about four times lower for those patients who are up to 10 years old compared to adults; no significant difference between the sexes has been observed.<sup>9</sup> The right or left side of the face is equally affected, and less than 1% of cases are bilateral.<sup>10</sup> Diabetes and pregnancy can increase the risk of developing Bell's palsy.<sup>8,11</sup>

Most people with BP (about 69%) show a spontaneous complete recovery. However, patients who did not receive an appropriate treatment may suffer from incomplete recovery and continue to show certain symptoms for life.<sup>12</sup> Residual facial muscle weakness with complications such as synkinesis, hyperkinesis, and/or contracture can occur. The latter may cause secondary psychologic sequels. Conventional treatment may include use of steroid or antiviral medications. A surgical decompression of the nerve is subject to debate in medicine.<sup>13</sup>

Although there is a controversy about the role of alternative treatment methods (e.g., physical therapy, acupuncture, local superficial heat therapy, massage, exercises, electrical stimulation, and laser therapy), all of these have been used with different degrees of success.<sup>14</sup>

Currently, each method has its indication in the treatment of lower motor facial palsy. A lot of attention has paid to improve the outcome of the treatments, and to decrease the incidence of complications in BP.

This report describes the complete recovery of a three-year-old boy from BP after 11 sessions of low-level laser treatment (LLLT). This case report will present a therapeutic option for treating BP and fully rehabilitating to normal.

**Materials and Methods**

The methods of assessment of facial nerve function may be classified into two major groups: clinical and electrophysiologic.<sup>15-19</sup> The clinical evaluation of the degree of facial paralysis is a subjective parameter and may differ from examiner to examiner. Several systems have been proposed to standardize a universal scale, and the House-Brackmann (HB) system is the most widely accepted scale, adopted by the American Academy of Otolaryngology.<sup>20</sup>

The HB grading system is quite comprehensive and includes important criteria (e.g., the appearance of the frontal, periorbital, and peribuccal musculature, both at rest and in motion<sup>16-18</sup>). The literature shows rates of agreement for 93% of different evaluators using the HB system to assess the function of the facial nerve).<sup>19,20</sup> In this case study, the HB grading system (Table 1) was used to monitor the evolution of the facial nerve motor function. Photographs were taken after every session using the same camera and the same magnitude. The patient was photographed facing the camera both at rest and in motion.<sup>6,10</sup>

*Case history*

A three-year-old boy showed a sudden onset of facial asymmetry. The mother, who accompanied her child to the clinic, stated that he had difficulties closing his right eye. She

TABLE 1. HOUSE-BRACKMANN SYSTEM TO GRADE THE DEGREE OF NERVE DAMAGE IN A FACIAL NERVE PALSY

---

*Grade 1: Normal*  
 Normal symmetrical function in all areas

*Grade 2: Slight*  
*General:* slight weakness noticeable only on close inspection  
 Forehead: good to moderate function  
 Eye: complete eye closure with minimal effort  
 Mouth: Slight asymmetry of smile with maximal effort  
 Synkinesis barely noticeable, contracture or spasm absent

*Grade 3: Moderate*  
*General:* Obvious weakness but not disfiguring  
 Difference between sides, synkinesis and/or hemifacial spasm noticeable but not severe  
 May not be able to lift eyebrow  
 Forehead: slight to moderate movement  
 Eye: complete eye closure with effort,  
 Mouth: asymmetrical mouth movement with maximal effort  
 Obvious but not disfiguring synkinesis, mass movement or spasm

*Grade 4: Moderately Severe*  
*General:* Obvious disfiguring weakness  
 Inability to lift brow  
 Forehead: no movement  
 Eye: Incomplete eye closure  
 Mouth: asymmetry of mouth with maximal effort  
 Severe synkinesis, mass movement, spasm

*Grade 5: Severe*  
*General:* Motion barely perceptible  
 Facial asymmetry  
 Forehead: no movement  
 Eye: Incomplete eye closure  
 Mouth: slight movement corner mouth  
 Synkinesis, contracture, and spasm usually absent

*Grade 6: Total*  
 No movement, loss of tone, no synkinesis, contracture, or spasm

---

denied excessive eye tearing, fever, cough, vomiting, diarrhea, cold, or recent travel. No signs of gait disturbance, weakness, numbness, hyperacusis, tingling, or taste disturbance were noted. No allergies were known for this patient, and he was taking no medication.

At the emergency room of a public hospital in Sao Carlos, a medical doctor prescribed laser therapy for BP on the child's facial muscles and nerves of the affected side of the face, to be performed by the Optics Group of the University of Sao Paulo. A clinical evaluation of the degree of severity of the facial paralysis on day 1, was evaluated as an HB, Grade 5. Approved informed consent and permission to take pictures of the patient was obtained from the boy's mother, protocol number: BP/2011 at the University of Sao Paulo.

*Medical history*

There is no medical history for the child. In general, the child appeared to be well nourished and of appropriate height and weight for the stated age. The child had not been in pain, or subject to infections or frequent headaches.

The only unusual situation experienced by the patient was a stress condition with his parents before the rapid onset of BP, presenting irritability at that occasion.

### Light Source and Irradiation Procedure

The patient was treated using laser therapy without any other co-intervention. The only other medication used was artificial tears (Refresh® Allergan) to maintain the eye moisture. To document the progress, the patient pictures were captured during each session.

The low-level laser source used was a gallium aluminum arsenide semiconductor diode laser device (Twin-Laser; MmOptics Industry, São Carlos, SP, Brazil), which had the following specifications: wavelength of 780 nm, 70 mW output power; area of beam spot size of 0.04 cm<sup>2</sup>, aperture of approximately 1 mm diameter. The time of irradiation was 10 seconds per point, with an energy density of 17.5 J/cm<sup>2</sup> per point, during each of the first 4 sessions.

During the 5th, 7th, 9th, and 11th sessions, the diode laser wavelength was chosen at 660 nm, because according to the literature<sup>21-25</sup> the infrared light (780 nm) has more penetration and can stimulate deeper regions, especially during the early treatment. Once the stimulus has been initiated, however, a 660-nm laser with a low (10 J/cm<sup>2</sup>) or moderate (60 J/cm<sup>2</sup>) energy density can be helpful to accelerate the neural recovery.<sup>21,23,24,26</sup> For these reasons, from the sixth session onward, the energy density was progressively decreased, based on the patient's report as well as clinical observations. Output power of 60 mW, 50 mW, and 40 mW were applied for sessions 6, 7, and 8. The laser beam was delivered in a continuous emission mode in direct contact with the facial area. LLLT should be used within hours following the onset of BP. The earlier the irradiation is started, the faster and better are the results. This patient received a total of 11 sessions. In the first 2 weeks, there were 4 sessions a week, so a total of 3 weeks of treatment was done in this case.

The length of the laser treatment session varied from 15 to 30 minutes, depending on the number of chosen points and the area being treated. The irradiation can be applied to all the facial muscles and nerves of the lower part of the face or frontalis to treat BP. A maximum of up to 80 points may therefore have to be used to apply the laser beam with a spot area of 0.04 cm<sup>2</sup>. Each application included points around the eyes, mouth, maxilla, and other areas penetrated by the facial nerve. The distance between the points treated were very close in the beginning of the treatment and gradually became more distant from each other (after the eighth session). The laser treatment should not be applied close to the eyes without proper eye protection. During the laser therapy, it is recommended to use specific glasses or to cover the eyes with aluminum foil wrapped in cotton gauze, especially if the patient is unable to close the eyelid.

### Outcome

An obvious improvement was noted during the course of the treatment: a marked development of the right facial muscle strength and a progressive attenuation of the facial asymmetry. After every session, the overall improvement of different facial expressions were rated and scored (Fig. 1) using the HB grading system.

### Discussion

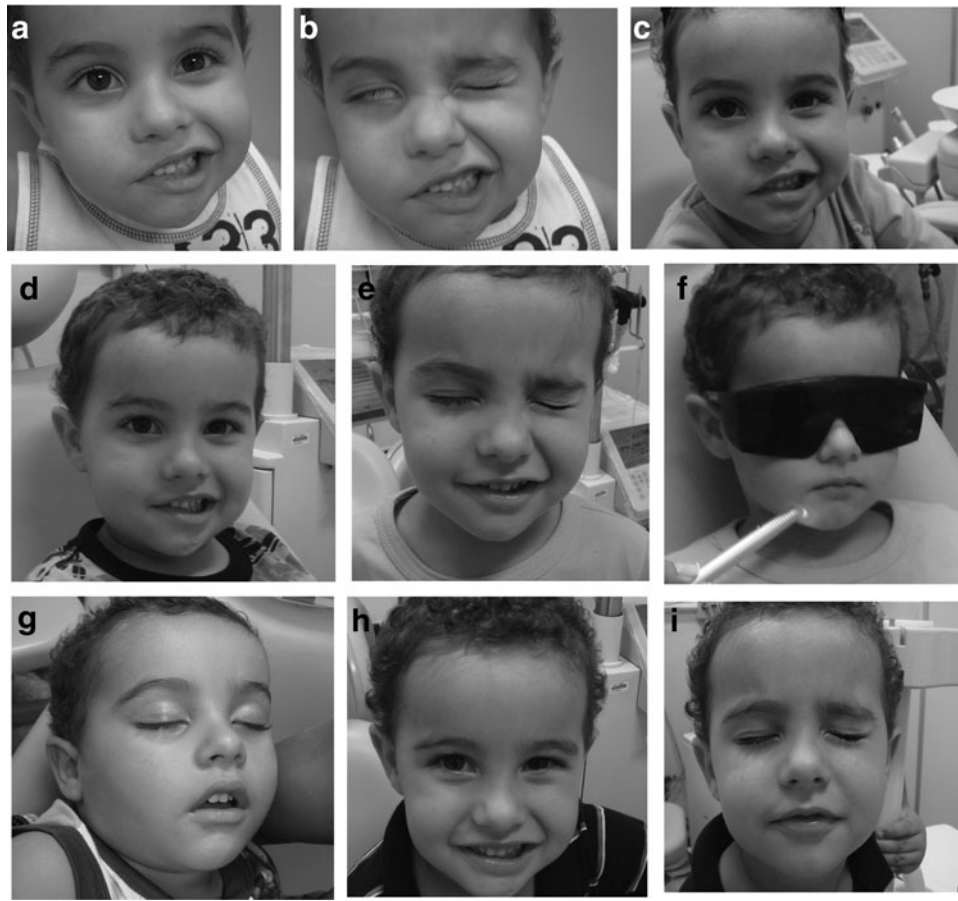To the best of the authors' knowledge, laser treatment and management of LLLT on BP for children have not yet been

evaluated or documented in depth in the literature so far. Neural regeneration and neuromuscular recovery after different types of injury have been explored more deeply in the literature. Several studies have used therapeutic sources (e.g., low-power lasers) in order to promote early nerve regeneration. However, this laser therapy has not gained unanimous acceptance with regard to its methodology, having led to controversial conclusions. Barbosa et al.<sup>21</sup> compared the effects of low-power lasers (660 nm and 830 nm) applied during 21 days to regenerate sciatic nerves following crushing injuries in rats. One source found that the laser application at 660 nm was effective in promoting early functional recovery. In another study, Rochkind et al.<sup>22</sup> examined the effects of composite implants of cultured embryonal nerve cells and the effect of 14 days of laser irradiation (780 nm) on the regeneration and repair of the completely transected spinal cord. The results showed that infrared laser light enhances axonal sprouting and spinal cord repair. Another study<sup>23</sup> using a biodegradable nerve guide conduit and a red laser irradiation applied daily for 21 consecutive days demonstrated that LLLT contributes to accelerate neural repair in rats. Gigo-Benato et al.<sup>24</sup> investigated the effect of 660 nm and 780 nm laser light using different energy densities on neuromuscular and functional recovery as well as on matrix metalloproteinase (MMP) activity after crush injury in sciatic nerves of rats. The data suggest that a 660 nm LLLT with low (10 J/cm<sup>2</sup>) or moderate (60 J/cm<sup>2</sup>) energy densities can accelerate neuromuscular recovery after nerve crush injuries in rats. Dias et al.<sup>25</sup> reported that low-level laser therapy (780 nm) stimulated the oxidative metabolism and the expression of MMPs of the masseter muscles, which may indicate a matrix remodeling process. However, a high dosage of infrared laser light did not show the best results for oxidative metabolism.

In this case report, both effects of 660 nm and 780 nm laser light were explored, avoiding high dosage based on results reported in the literature. For this patient, both the wavelength selection and point selection were adjusted from time to time, and seemed to contribute to the patient's improvement. In order to balance between beneficial stimulatory and inhibitory effects, the authors suggest alternating use of red and infrared wavelength. During the first five treatment sessions, only infrared laser light (780 nm) was used, while the other sessions were carried out alternating red laser (660 nm) and infrared laser light. This was done in order to avoid plateau effect stimulations due to an extended use of a single wavelength.

Initially, LLLT was mainly used in medicine to assist in wound healing and pain relief. The field of application of LLLT has now been broadened to include use in treatment of diseases such as stroke, myocardial infarction, and neurodegenerative or traumatic brain disorders. In a recent review, Hashmi et al.<sup>26</sup> covered the mechanisms of LLLT that operate both on a cellular and a tissue level. The authors discussed animal studies and human clinical trials of LLLT for indications with relevance to neurology. These studies support the present case application and reinforce the rapidly growing applications of low level laser in physical therapy, acupuncture, chiropractic, sports medicine, and increasingly in mainstream medicine. Hashmi et al.<sup>27</sup> reviewed the studies that compared continuous wave and pulsed light in both animals and patients. There is some evidence that applications using pulsed light do show effects different from





**FIG. 1.** Clinical evaluation of facial paralysis degree at the first day classified as House-Brackmann (HB) Grade 5 and after the following 11 sessions (in 3 weeks) of treatment classified as HB Grade 1 (normal symmetrical function in all areas). **A.** First session (day 1, Tuesday) Right-sided facial nerve palsy. HB Grade 5 during initial presentation (first week). **B.** Facial asymmetry (day 1) (first week). Eye: Incomplete eye closure. Mouth: slight movement corner of mouth. Muscles: Nasolabial folds away; fall of the labial commissure jaw muscle does not contract on the affected side. **C.** Third session (day 3, Thursday) (first week). The face is asymmetrical both at rest and during mimicry. Patient cannot wrinkle one side of his forehead or jaw or raise the eyebrow, and when attempting to smile, the face is pulled to the opposite side. **D.** Fourth session (day 4, Friday). Finalizing first week of treatment. Labial commissure begins to restore position (not fallen), but the jaw muscles in the area close to right mental foramen are not contracting. **E.** Fifth session (day 7, Monday). HB Grade 3 (initializing the second week of treatment). Difference between sides, noticeable but not severe. Not able yet to easily lift eyebrow. Eye: complete eye closure with effort. Mouth: asymmetrical mouth movement with maximal effort. **F.** Fifth session (second week). HB Grade 3. Application of low-level laser source: red diode laser device, 660 nm, 50 mW, 12.5 J/cm<sup>2</sup>. Note especially the nasolabial folds, forehead wrinkles, corner of the mouth, and symmetry of the face starting return to normality. **G.** Sixth session (day 8, Tuesday) (second week). Patient was sleeping. Note the eye closes perfectly on the affected side. Face symmetry reestablished at rest. **H.** Seventh session (day 10, Thursday). HB Grade 2 (second week). Slight weakness noticeable only on close inspection. Mouth: Slight asymmetry of smile with maximal effort. **I.** HB Grade 2, seventh session (day 10, Thursday) (second week). Forehead: good-to-moderate function. Eye: complete eye closure with minimal effort. **J.** HB Grade 1, ninth session. Last week of treatment (third week) (day 15, Tuesday). Normal symmetrical function in all areas. Total ability to move corners of mouth. **K.** HB Grade 1. **L.** Tenth session. HB Grade 1 (day 17 Thursday). Normalized nasolabial folds. Symmetry of the face is normalized. **M.** HB Grade I (day 17). Normal symmetrical function in all areas. **N.** Eleventh session. HB Grade 1 (day 18, Friday). Normal symmetrical function in all areas. **O.** Eleventh session. HB Grade 1 (day 18, Friday). Final session. (Photos printed with parental permission. Since the permission was signed in Portuguese, to facilitate the understanding of "Termo de Consentimento Liver Esclarecido," we also added an English version of this document.)

those using continuous-wave light. However, further work is needed to define these effects for different disease conditions and pulse structures. According to Cruccu et al.,<sup>28</sup> laser pulses excite superficial free nerve endings stimulated by small-myelinated (Adelta) and unmyelinated (C) fibers. The authors reveal that pulsed laser may be useful in patients with lesions affecting the trigeminal thermal pain pathways.

In the present study, the duration of a laser session was between 15 and 30 minutes, depending on the number of chosen points on the treated area. The maximum number of points used was 80. It was necessary to irradiate on 80 spots, when the entire face was treated, as the spot of the laser beam used is small. According to acupuncture literature,<sup>29-31</sup> this treatment could also be carried out using less than 20 Chinese

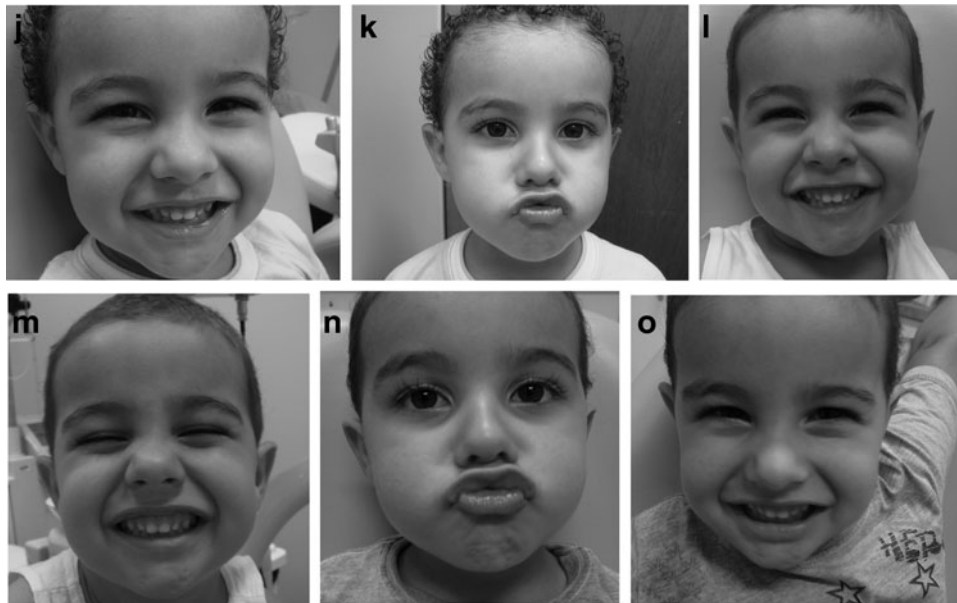


FIG. 1. (Continued).

acupuncture points defined unilaterally on a face. O'Connor and Bensky,<sup>32</sup> Wang and Yang,<sup>33</sup> and other authors<sup>34,35</sup> have used a much smaller number of points (average of 10 acupuncture points) with equally good success. Lei et al.<sup>36</sup> also used few acupuncture points to achieve a complete recovery from BP of a 27-year-old woman, 27 weeks pregnant. After 2 weeks of acupuncture treatment the symptoms had disappeared, her face was restored to normal, and HB returned to grade 1.

In the case reported here, more points were used because the laser device had a laser beam with a spot area of 0.04 cm<sup>2</sup>. Furthermore, instead of using acupuncture points, our irradiation protocol covered the entire right side of the face, requiring about 80 points to cover the large irradiation area. Using different laser equipment with a larger "pad" applicator could also lead to the same satisfactory treatment results using fewer irradiation points.<sup>37</sup> In the current study, the laser beam with a spot area of 0.04 cm<sup>2</sup> was delivered in a continuous emission mode in direct contact with the facial area without targeting acupuncture points. A complete recovery was achieved after 3 weeks of treatment.

According to Wong and Wong,<sup>38</sup> acupuncture in a 7-year-old child with chronic BP takes longer to show good results. The patient was given 25 acupuncture treatment sessions in 2 months. The acupuncture points used (apparently on only the affected side, except for midline points) included the following three sets of points: (1) on the face—LI20, ST2, ST3, ST4, ST6, ST7, SI18, BL2, TE17, TE23, GB14, GV26, CV24, EXHN5, and EX-HN16; (2) on the upper extremity—LI11, HT8, SI3, PC8, TE5; and (3) on the lower extremity—ST36, ST40, SP6, SP10, BL67, and LR3. Self-perceived muscle strength when smiling and puffing out cheeks increased from 20% of normal strength to 65%, and the strength when raising eyebrows increased from 10% to 70%. Synkinesis was attenuated. HB scale changed to grade 3 after treatment.

Hou et al.<sup>39</sup> compared therapeutic effects of acupuncture combined with He-Ne laser irradiation to use of Western medicine to treat facial paralysis. After 14 days, the cure rate was 81.8% for the acupuncture with laser group, and 45.20%

for the medication group. There was a significant difference concerning the results of the two groups after treatment, showing that the therapeutic effect of acupuncture combined with He-Ne laser on facial paralysis is higher than that of routine medication. Tang et al.,<sup>40</sup> in a retrospective study, reviewed the factors that may influence the treatment outcome for patients with idiopathic facial nerve paralysis. Full recovery was more likely for patients treated with combined acyclovir and prednisolone compared to being treated with prednisolone alone. However, adult patients who were treated with routine medication with concurrent chronic medical illness and facial nerve paralysis HB Grade IV–VI showed a reduced chance of full recovery of facial nerve paralysis. Salman and MacGregor<sup>41</sup> studied the effect of corticosteroids when treating pediatric BP. The pediatric trial did not provide proof of benefit when using corticosteroids. Even though the study was based on a quite heterogeneous population evaluated, based on a subsequent systematic review, the authors do not recommend the routine use of steroids in children with BP. Prescott,<sup>42</sup> evaluating 228 children with BP during a 10-year period, concluded that the children treated with a high dose of steroids did not show any positive effects, neither an improved recovery rate nor a decreased recovery period.

Patients or people responsible for the pediatric patients receiving laser therapy usually asked about the number of sessions needed to obtain an optimal therapeutic effect. Unfortunately, there is no general rule. Each case must be treated individually, and for chronic conditions, patients may receive recommendation to continue lifelong treatment. The patient in this report received the laser therapy promptly after he had the onset of BP. In this case, improvement was initially noted after 5 sessions (of a total of 11 sessions during 3 weeks of treatment), but sometimes the beneficial effect can reach a plateau before complete recovery. If the effect flattens out toward the end of the course after a certain period of continued treatment, it is suggested that the patient stop the treatment temporarily, continuing only after a 2–3-weeks' break in the treatment.

Based on data from the literature, it was determined that combinations of many different laser parameters may influence clinical outcomes. Various types of laser equipment and treatment parameters that need to be considered include the following: continuous wave or pulsed wave, power output, beam spot size, beam diameter, wavelength, pulse frequency, and duty cycle. Additional factors include the irradiation duration, treatment technique, number of points to be treated (or the area of affected tissue to be treated), and the target tissue depth. Patient characteristics such as skin color and tissue type, and whether the condition is acute, subacute, or chronic should also be considered. Even given this limited set of factors, there still remain innumerable combinations of factors to consider when applying laser therapy. The purpose of this study was to present the current LLLT protocol, as an alternative therapy, to routine medication when treating pediatric BP. Other LLLT or light-emitting diode protocols could also be effective.

### Conclusions

Common signs of BP are weakness of the muscles, generally on one side of the face, one-sided drooping eyelid or mouth, or drooling from one side of the mouth as presented in this case. After treatment with a low-level diode laser, the patient's symptoms ceased and he completely recovered after 11 sessions during a 3-week treatment period. This study provided clinical evidence to support the early use of LLLT in BP as an effective alternative treatment, which may be considered a noninvasive application especially for pediatric use.

### Acknowledgments

The authors acknowledge the financial support provided by Fundacao amparo a Pesquisa do estado de Sao Paulo (Centro pesquisa optica fotonica-centro pesquisa inovacao e difusao program) and Conselho nacional desenvolvimento cientifico tecnologico.

### Disclosure Statement

The authors affirm no financial affiliation with any commercial organization that might create a conflict of interest in connection with this article.

### References

1. Facer GW. Facial nerve paralysis: Is it always Bell's palsy? *Postgrad Med* 1981;69:206–208, 211–213, 216.
2. Musani MA, Farooqui AN, Usman A, et al. Association of herpes simplex virus infection and Bell's palsy. *J Pak Med Assoc* 2009;59:823–825.
3. Smith N, Grattan-Smith P, Andrews IP, Kainer G. Acquired facial palsy with hypertension secondary to Guillain-Barre syndrome. *J Paediatr Child Health* 2010;46:125–127.
4. Sajadi MM, Sajadi MR, Tabatabaie SM. The history of facial palsy and spasm: Hippocrates to Razi. *Neurology* 2011;77:174–178.
5. Kanerva M, Jonsson L, Berg T, et al. Sunnybrook and House-Brackmann systems in 5397 facial gradings. *Otolaryngol Head Neck Surg* 2011;144:570–574.
6. Merino P, Gómez de Liaño P, Villalobo JM, et al. Etiology and treatment of pediatric sixth nerve palsy. *J AAPOS* 2010;14:502–505.
7. Linder TE, Abdelkafy W, Caverro-Vanek S. The management of peripheral facial nerve palsy: "Paresis" versus "paralysis" and sources of ambiguity in study designs. *Otol Neurotol* 2010;31:319–327.
8. Grosheva M, Beutner D, Volk GF, et al. Idiopathic facial palsy HNO. 2010;58:419–425.
9. Wong CL, Wong VC. Effect of acupuncture in a patient with 7-year-history of Bell's palsy. *J Altern Complement Med* 2008;14:847–853.
10. Smith SA, Ouvrier R. Peripheral neuropathies in children. In: Kenneth F, Swaiman SA, eds. *Pediatric Neurology: Principles and Practice*. 3rd ed. vol 2. St. Louis, MO: Mosby, 1999: 1178–1181.
11. Fawale MB, Owolabi MO, Ogunbode O. Bell's palsy in pregnancy and the puerperium: A report of five cases. *Afr J Med Med Sci* 2010;39:147–151.
12. Holland J, Bernstein J. Bell's palsy. *Clin Evid (Online)* 2011; pii:1204.
13. Browning GG. Bell's palsy: A review of three systematic reviews of steroid and anti-viral therapy. *Clin Otolaryngol* 2010;35:56–58.
14. Teixeira LJ, Soares BG, Vieira VP, Prado GF. Physical therapy for Bell's palsy (idiopathic facial paralysis). *Cochrane Database Syst Rev* 2008;3:CD006283.
15. Mackinnon SE, Dellon AL. *Surgery of peripheral nerve*. 1st ed. New York: Thieme Medical, 1988:638.
16. Yen TL, Driscoll CLW, Lalwani AK. Significance of House-Brackmann facial nerve grading global score in the setting of differential facial nerve function. *Otol Neurotol* 2003;24:118–122.
17. Satoh Y, Kanzaki J, Yoshihara S. A comparison and conversion table of the House-Brackmann facial nerve grading system and the Yanagihara grading system. *Auris Nasus Larynx* 2000;27:207–212.
18. Kang TS, Vrabc JT, Giddings N, Terris DJ. Facial nerve grading systems (1985–2002): Beyond the House-Brackmann scale. *Otol Neurotol* 2002;23:767–771.
19. Evans RA, Harries ML, Baguley DM, Moffat DA. Reliability of the House and Brackmann grading system for facial palsy. *J Laryngol Otol* 1989;103:1045–1046.
20. House JW, Brackmann DE. Facial nerve grading system. *Otolaryngol Head Neck Surg* 1985;93:146–147.
21. Barbosa RI, Marcolino AM, de Jesus Guirro RR, et al. Comparative effects of wavelengths of low-power laser in regeneration of sciatic nerve in rats following crushing lesion. *Lasers Med Sci* 2010;25:423–430.
22. Rochkind S, Shahar A, Amon M, Nevo Z. Transplantation of embryonal spinal cord nerve cells cultured on biodegradable microcarriers followed by low power laser irradiation for the treatment of traumatic paraplegia in rats. *Neurol Res* 2002; 24:355–360.
23. Shen CC, Yang YC, Liu BS. Large-area irradiated low-level laser effect in a biodegradable nerve guide conduit on neural regeneration of peripheral nerve injury in rats. *Injury* 2011; 42:803–813.
24. Gigo-Benato D, Russo TL, Tanaka EH, et al. Effects of 660 and 780 nm low-level laser therapy on neuromuscular recovery after crush injury in rat sciatic nerve. *Lasers Surg Med* 2010;42:673–682.
25. Dias FJ, Issa JP, Vicentini FT, et al. Effects of low-level laser therapy on the oxidative metabolism and matrix proteins in the rat masseter muscle. *Photomed Laser Surg* 2011;29:677–684.
26. Hashmi JT, Huang YY, Osmani BZ, et al. Role of low-level laser therapy in neurorehabilitation. *PMR* 2010;2(12 suppl 2):S292–S305.

27. Hashmi JT, Huang YY, Sharma SK, et al. Effect of pulsing in low-level light therapy. *Lasers Surg Med* 2010;42:450–466.
28. Cruccu G, Pennisi E, Truini A, et al. Unmyelinated trigeminal pathways as assessed by laser stimuli in humans. *Brain* 2003;126(pt 10):2246–2256.
29. Naeser MA. Acupuncture to treat paralysis due to central nervous system damage. *J Altern Complement Med* 1996;2: 211–248.
30. Naeser MA. Neurological rehabilitation: Acupuncture and laser acupuncture to treat paralysis in stroke, other paralytic conditions, and pain in carpal tunnel syndrome. *J Altern Complement Med* 1997;3:425–428.
31. Naeser MA. Acupuncture in the treatment of paralysis due to central nervous system damage. *J Altern Complement Med* 1996;2:211–248.
32. O'Connor J, Bensky DF. *Acupuncture, A Comprehensive Text*, Shanghai College of Traditional Chinese Medicine. Chicago: Eastland Press, 1981:609.
33. Wang Y, Yang J. Clinical observation on treatment of acupuncture for different stages of Bell's palsy. *Zhongguo Zhen Jiu* 2010;30:23–26.
34. Lim S. WHO Standard acupuncture point locations. *Evid Based Complement Alternat Med* 2010;7:167–168.
35. Qiu T, Li L. Discussion on the Chinese edition of the WHO Standard Acupuncture Point Locations in the Western Pacific Region. *Zhongguo Zhen Jiu* 2011;31:827–830.
36. Lei H, Wang W, Huang G. Acupuncture benefits a pregnant patient who has Bell's palsy: A case study. *J Altern Complement Med* 2010;16:1011–1014.
37. Saeki S. Equipment for low reactive level laser therapy including that for light therapy. *Masui* 2006;55:1104–1111.
38. Wong CL, Wong VC. Effect of acupuncture in a patient with 7-year-history of Bell's palsy. *J Altern Complement Med* 2008;14:847–853.
39. Hou YL, Li ZC, Ouyang Q, et al. Observation on therapeutic effect of acupuncture combined with He-Ne laser radiation on facial paralysis. *Zhongguo Zhen Jiu* 2008;28:265–266.
40. Tang IP, Lee SC, Shashinder S, Raman R. Outcome of patients presenting with idiopathic facial nerve paralysis (Bell's palsy) in a tertiary centre: A five year experience. *Med J Malaysia* 2009;64:155–158.
41. Salman MS, MacGregor DL. Should children with Bell's palsy be treated with corticosteroids? A systematic review. *J Child Neurol* 2001;16:565–568.
42. Prescott CA. Idiopathic facial nerve palsy in children and the effect of treatment with steroid. *Int J Pediatr Otorhinolaryngol* 1987;13:257–264.

Address correspondence to:

*Carla Raquel Fontana, PhD*

*Department of Clinical Analysis*

*School of Pharmaceutical Sciences*

*Univ Estadual Paulista (UNESP)*

*Rua Expedicionários do Brasil 1621 Araraquara*

*SP 14801-960*

*Brazil*

*E-mail: fontanacr@fctfar.unesp.br*