Journal of Equine Veterinary Science 31 (2011) 26-34

Journal of Equine Veterinary Science

journal homepage: www.j-evs.com



Original Research

Use of Adipose Tissue-Derived Mesenchymal Stem Cells for Experimental Tendinitis Therapy in Equines

Armando de Mattos Carvalho MSc [a], Ana Liz Garcia Alves PhD [a], Patrícia Galvão Gomes de Oliveira MSc [a], Luis Emiliano Cisneros Álvarez MSc [b], Renée Laufer Amorim PhD [c], Carlos Alberto Hussni PhD [a], Elenice Deffune PhD [d]

[a] *Department of Veterinary Surgery and Anesthesiology, School of Veterinary Medicine and Animal Science, São Paulo State University, Botucatu, São Paulo, Brazil*
[b] *Department of Animal Reproduction and Veterinary Radiology, School of Veterinary Medicine and Animal Science, São Paulo State University, Botucatu, São Paulo, Brazil*
[c] *Department of Clinical Veterinary, School of Veterinary Medicine and Animal Science, São Paulo State University, Botucatu, São Paulo, Brazil*
[d] *Blood Center, Botucatu Medical School, São Paulo State University, Botucatu, São Paulo, Brazil*

Keywords:
Equine
Tendinitis
Mesenchymal stem cells
Adipose tissue
Tendon repair
Collagenase

A B S T R A C T

Superficial digital flexor tendon lesion is an important cause of lameness in equine athletes. Although numerous treatments have been described, few are effective at promoting significant improvement in the quality of the extracellular matrix. Therefore, great potential remains for recurrence and in certain cases, an abrupt end to the horse's athletic career. Recently, several experiments have focused on the therapeutic potential of mesenchymal stem cells (MSCs) in cases of tendon lesions. This study aimed to evaluate the effect of adipose tissue-derived MSCs in the treatment of induced tendinitis of the superficial digital flexor tendon in horses by clinical, ultrasonographic, histopathological, and immunochemical analyses. Tendinitis was induced in both thoracic limbs of eight mares by administration of collagenase solution and adipose tissue was collected from the tail base for MSCs isolation and expansion, which were used during cellular therapy on only one limb 30 days after lesion induction. No differences occurred between the groups regarding the clinical and ultrasonographic analyses; however, histopathological evaluation revealed a significant improvement in tendon fiber organization and diminished inflammatory infiltrate, whereas immunohistochemical analysis showed increased expression of type I collagen in the treated group as compared with controls. The cellular therapy model implanted in this experiment promoted increased perivascular inflammatory infiltrate, fibroblastic density, neovascularization, and qualitative healing improvement of tendon extracellular matrix, in terms of fiber orientation and type I/III collagen ratio; moreover, it was considered to be a safe and viable process.

1. Introduction

Tendinitis of the superficial digital flexor tendon (SDFT) is an extremely important affliction for equine athletes in all types of sports [1]. Tendinitis is an important cause of lameness and diminished performance in equine athletes because of its high incidence, prolonged recovery period, and high rate of recurrence [2]. Possible explanations for the slow healing of tendons and, in the majority of cases, the resulting formation of mechanically inferior extracellular matrix are probably because of the fact that tendon is a minimally vascularized tissue, presents cells that exhibit diminished mitotic activity, and the presence of few progenitor cells in the tissue [3,4].

Recurrences are related to the nonregeneration of tendon tissue and the production of a matrix of collagen fibrils that are smaller in diameter and of inferior quality,

Corresponding author at: Armando de Mattos Carvalho, MSc, Department of Veterinary Surgery and Anesthesiology, School of Veterinary Medicine and Animal Science, São Paulo State University (UNESP), Rubião Júnior, Botucatu 560, São Paulo, Brazil.
E-mail address: armandodvm@gmail.com (A. de Mattos Carvalho).

0737-0806/$ - see front matter
doi:10.1016/j.jevs.2010.11.014

showing a reduced number of crosslinks [3]. Therapies that promote healthy tendon tissue regeneration should produce a reduction in recurrence rates as compared with those that promote the formation of scar tissue [5].

Knowledge concerning tendon repair and its implications for the athletic capacity of the individual horses affected by tendinitis has stimulated research regarding new therapies applied to this tissue. Cellular therapy using mesenchymal stem cells (MSCs) has shown promising results in several published works [1,2,6,7]. In cases of tendon lesion in horses, the majority of published data have focused mainly on the therapeutic potential of MSCs derived from bone marrow and adipose tissue, even though studies indicate the possibility of other sources of MSCs in adult tissue, including brain tissue, dermis, periosteal, skeletal muscle, synovial, trabecular bone, and vascular tissue [8]. The most abundant and accessible source of stem cells is adipose tissue [9], justifying the expressive interest in the development of cellular therapy involving this source.

The stromal vascular fraction is a heterogenous cell population derived from adipose tissue that includes endothelial and epithelial cells, preadipocytes, and certain progenitor cells. These progenitors, adipose-derived MSCs, have shown multiple differentiation potential similar to bone marrow-derived MSCs [10].

MSCs implantation causes an increase in the number of progenitor cells than normally present in tendon tissue, thereby improving the potential for regeneration [11]. The immunomodulatory properties of MSCs translate into anti-inflammatory effects *in vivo* and numerous animal studies have demonstrated that exogenously administered MSCs attenuate inflammation and facilitate regeneration of injured tissue [12].

Till recently, existing reports have only described the clinical use of adipose tissue-derived MSCs isolated from horses and expanded in the laboratory, as outlined by Leppänen et al. [13]; however, no controlled study of equine tendon therapy using these cells exists. To investigate this, collagenase was used to induce tendinitis in the SDFT, followed by adipose tissue collection for the isolation of mononuclear cells and posterior culture of progenitor cells. After intralesional implantation of MSCs in the treated group, clinical, ultrasonographic, histological, and immunohistochemical analyses were conducted to compare the treatment and control groups. It is our hypothesis that the injection of progenitor cells improves tendon healing by increasing the number of stem cells at the lesion site, thereby favoring the synthesis of extracellular matrix similar to healthy tendon tissue, the reduction in tendon inflammation, and increased concentrations of type I collagen, leading to improved quality in tendon repair.

2. Materials and Methods

2.1. Animals

Eight clinically normal young mares of undefined breed (age: 2-3.5 years) were used in the study. The mares were examined clinically and by ultrasonography to ensure that they presented no preexisting tendon damage. The experimental protocol was approved by the Committee of Ethics and Animal Welfare of the School of Veterinary Medicine and Animal Science, São Paulo State University, Brazil, and was performed under international guidelines for the care and use of experimental animals. All the mares were submitted to the same procedures, with differences only in the time of biopsy. To further improve the elucidation of the experiment, the horses were divided into two groups of four mares each: Group A (GA), in which the mares were submitted to ultrasound examinations at 0, 2, 4, 6, and 8 weeks and a bilateral biopsy of the digital flexor tendon performed 60 days after lesion induction; and Group B (GB), in which the mares were submitted to ultrasound examinations at 0, 2, 4, 6, 8, 10, to a maximum of 21 weeks and a bilateral biopsy of the digital flexor tendon after lesion induction for posterior histopathological and immunohistochemical analyses. The tendon biopsies were obtained on days 60 and 150 after collagenase application to investigate tendon healing evolution.

2.2. Tendinitis Induction

All the mares were subjected to lesion induction in the SDFT of both thoracic limbs in the region of the middle one-third of the metacarpal region. Lesion induction was achieved by local administration of 2.5 mg or 690 IU of type I collagenase (Collagenase type 1: C-0130, Sigma Pharmaceutical, St. Louis, MO, USA) diluted in 1.0 mL of sterile water, guided by ultrasound equipment (Logiq 3, General Electric, Sangdaewon-Dong, Korea), similar to the method described by Maia et al. [14]. Prior sedation of the mares was achieved with 10% xylazine (Sedazine, Fort Dodge, Campinas, São Paulo, Brazil) at a dosage of 0.8 mg/kg, the region around the collection site was shaved and aseptically prepared, and local anesthesia was performed by perineural blockage of the lateral and medial palmar nerves in the proximal metacarpal region, using 2 mL of 2% lidocaine chlorhydrate (Xylestesin, Cristália Produtos Químicos e Farmacêuticos Ltda, Itapira, São Paulo, Brazil) without the application of a vasoconstrictor at each point.

2.3. Adipose Tissue Collection

The region above the dorsal gluteal muscle, at the base of the tail, was chosen as the adipose tissue collection site because of the availability of material, the absence of large veins, and easy access. The mares were sedated with xylazine (1 mg/kg, i.v.), followed by infiltration of the skin and subcutaneous tissues with an anesthetic, 2% lidocaine chloride, using an inverted L-block. An incision of approximately 10 cm in length was made parallel to and approximately 15 cm below the spinal column, permitting visualization of a layer of adipose tissue between the skin and musculature. Approximately 5 mL of adipose tissue was collected and stored in a sterile 50-mL conic flask containing Roswell Park Memorial Institute - 1640 medium (Sigma Chemical Co., St. Louis, MO, USA), such that the sample was entirely immersed. The skin was sutured with nylon suture in simple isolated stitches.

2.4. Isolation of Stromal Vascular Fraction Cells

The sample materials were then subjected to successive washes with phosphate buffered saline (PBS) in sterile

Falcon tubes (Becton Dickinson Co., Franklin Lakes, NJ, USA). To isolate the cells, the extracellular matrix was then subjected to mechanical separation using a No. 15 scalpel blade (Wuxi Xinda Medical Device Co., China) and the digestive action of 0.02% of type I collagenase (Gibco, Grand Island, NY, USA) in RPMI-1640 medium, in a humidified incubator at 37°C, under 5% CO_2 for 12 hours, followed by neutralization of the enzyme with Knockout Dulbecco's modified Eagle's medium (Gibco, Grand Island, NY, USA) containing 10% fetal bovine serum (Gibco, Grand Island, NY, USA). This solution was centrifuged with a relative centrifugal force of 260 *g* for 10 minutes and the supernatant was aspirated and added to Dulbecco's phosphate buffered saline (Gibco, Grand Island, NY, USA) and homogenized for future centrifugation. After this procedure, the number of cells was quantified in an improved Neubauer counting chamber (Labor Optik, Germany) to evaluate cellular viability by the standard exclusion test using 0.02% trypan blue (Trypan Blue Stain, Gibco, Grand Island, NY, USA).

2.5. MSC Culture

Cells of the stromal vascular fraction were cultured at a density of 10^5 cells/cm^2 in 25-cm^2 culture plates and these were maintained in an incubator at 37°C under 5% CO_2 with Knockout Dulbecco's modified Eagle's medium and 10% fetal bovine serum culture medium. The medium was changed every 3 days and when a minimum confluence of 70% of the plate occurred, trypsinization was conducted, on the basis of a technique previously described in horses [15]. The cells (100 μL) were collected and transferred to a hemolysis tube for cell counts, where the number of cells was quantified using a hemocytometer and cellular viability was evaluated by the trypan blue exclusion test. The remainder was transferred to three 25-cm^2 culture plates that were further incubated at 37°C under 5% CO_2. Cell cultivation was maintained until the fourth passage using samples from one horse and until the second passage for the remaining horses, after which cell counts and immunophenotypic characterization of MSCs were conducted.

2.6. Flow Cytometry Analysis

Flow cytometry was performed in all the passages tested (first to fourth) in FACSCalibur (BD, Franklin Lakes, NJ, USA) equipment using the mouse anti-rat CD90-fluorescein isothiocyanate (FITC) (Caltag Laboratories, Burlingame, CA, USA) monoclonal antibody, as well as tests with specific monoclonal mouse anti-horse CD13 (AbD Serotec, Kidlington, Oxford, UK) and mouse anti-horse CD44 (AbD Serotec, Kidlington, Oxford, UK) antibodies, which were marked with goat anti-mouse immunoglobulin G (IgG)-FITC IgG (Molecular Probes, Eugene, OR, USA) secondary monoclonal antibodie. Randomized analysis of variance (ANOVA) was performed to verify statistically significant differences ($P < .05$) regarding the markers used by comparing their expression in the different passages.

2.7. MSC Implantation

Cell implantation was performed by randomized selection of the right or left limb of each mare and this information remained blinded. Thirty days after tendinitis induction, implantation of approximately 10×10^6 adipose tissue-derived MSCs was performed at the lesion site of the chosen leg, a procedure similar to that described by Maia et al., to achieve lesion induction [14]. Before cell implantation, puncture of the jugular vein was performed to collect blood in a tube not containing any anticoagulant (BD Vacutainer Serum, Franklin Lakes, NJ, USA), and after 30 minute at rest, coagulation started, with the precipitation of red blood cells and supernatant containing autologous serum, 0.5 mL of which was removed to dilute the MSCs. These were quickly placed in refrigerated thermal containers and immediately carried to the location of cellular implantation. Guided by ultrasound equipment, the 21-G needle was positioned at the center of the lesion site and coupled to the syringe containing the cells was injected into one of the thoracic limbs of each mare. No substance was administered to the contralateral limb, which was denominated as the control limb.

The mares were followed up daily for a week after lesion induction, then weekly until the time of the biopsy. The presence of sensitivity was evaluated and scored as follows: 0: absent; 1: slight; 2: moderate; and 3: severe.

2.8. Physical Activity

After cellular implantation, the mares were submitted to progression-controlled physical activity, on the basis of the following scheme:

- Day 0 to 44: stall rest (GA and GB).
- Day 45 to 60: walking for 15 minutes, once a day (GA and GB).
- Day 61 to 90: walking for 15 minutes, twice a day (GB).
- Day 91 to 120: walking for 30 minutes, once a day (GB).
- Day 121 to 150: walking for 30 minutes, twice a day (GB).

2.9. Ultrasonographic Control

Ultrasonographic evaluations were performed with a 7.5-MHz linear transductor, to evaluate lesion induction and tissue repair. Ultrasound analysis was carried out before collagenase administration, before and after cellular implantation at 0, 2, 4, 6, and 8 weeks in GA or at 0, 2, 4, 6, 8, 10, to a maximum of 21 weeks after lesion induction in GB, until the end of the experimental period (60 days, GA), and 150 days after injury induction (GB). The following parameters were measured: tendon area; lesion area; percentage of lesioned area in the interior of the tendon; echogenic pattern, graduated from 0 to 4, according to Genovese et al. [16]; and tendon fiber alignment. The images obtained were recorded for posterior comparison between the different time intervals and groups of mares.

2.10. Statistical Analysis

Statistical analysis was performed by two-way repeated measures ANOVA ($P < .05$) with random effects, incorporating the dependency between observations at the different time points and between observations for the same mare, with respect to the continuous quantitative

variables: tendon area, lesion area, and percentage of the lesion area.

2.11. Biopsy

The biopsy was performed in core lesions of the tendon, from the lateral direction at two different times, according to the group of mares. In GA, the biopsy was performed on day 60 after lesion induction, whereas in GB, collection of tendon material was performed on day 150 after lesion induction. The mares were submitted to general anesthesia, including preanesthetic medication with 10% xylazine (1.1 mg/kg, i.v.), induction with *guaiacol glyceryl ether* (Vetec Química Fina Ltda, Duque de Caxias, Rio de Janeiro, Brazil) at a dosage of 100 mg/kg, i.v., followed by ketamine (Dopalen, Vetbrands, Paulínia, São Paulo, Brazil) at a dosage of 2.2 mg/kg, i.v., and maintenance by inhalatory anesthesia using isoflurane (Isofluorano, Cristália Produtos Químicos e Farmacêuticos Ltda, Itapira, São Paulo, Brazil). Local anesthetic blockage of the median, medial antebrachial cutaneous, and ulnar nerves was performed by 20 mL of 2% lidocaine without the application of a vasoconstrictor. The biopsy was performed with the horse positioned in right lateral recumbency and an incision of approximately 5 cm in length was made in both the skin and subcutaneous tissue for later identification and individualization of the tendon with the aid of hemostatic tweezers. After localization of the injured area, 1 cm^3 of core lesion was biopsied by resection and was immediately placed in a flask containing 10% buffered formalin (Embramac, Empresa Brasileira de Materiais Cirúrgicos, Itajaí, Santa Catarina, Brazil). Previous marking of the height of the lesion in the limb and ultrasound images were used to identify the exact site for performing the biopsy. In general, tissue was collected between the central and peripheral portion of the tendon, involving the entire area of the lesion, a transverse section of 40% of the total tendon area. Suturing of the paratenon was performed in a single continuous stitch using Vicryl 2-0 (Eletro-Light Ltda, Manaus, Amazonas, Brazil) suture and suturing of the skin in simple interrupted stitches using nylon suture. After the surgical procedure, a compressive bandage was applied to the metacarpal region for 48 hours and the mares were maintained in the stall for 4 weeks. During the postoperative period, daily wound dressing was performed until the removal of sutures on day 14. Phenylbutazone (Equipalazone, Vitalfarma Ltda, São Sebastião do Paraíso, Minas Gerais, Brazil), a nonsteroidal anti-inflammatory medication, was administered at a dosage of 4.4 mg/kg i.v., every 24 hours for 5 days.

2.12. Histopathological Analyses

Processing of the tendon fragments was performed following conventional methods for paraffin inclusion and histopathological sectioning, which was then followed by hematoxylin and eosin or Masson's trichrome staining. Histopathological analysis was performed by using an optical microscope, with the pathologist blinded to the group. For each specific type of analysis, two slides of biopsied tendon tissue were prepared. The density and characteristics of the fibroblasts, the presence and type of inflammatory infiltrate, neovascularization, and tissue organization were analyzed using the criteria described by Maia et al. [14]. Data relative to the histological variables (Table 1), classified by scores (0-3), were analyzed and compared between groups using the Wilcoxon nonparametric test, followed by the Kolmogorov–Smirnov test. The results obtained are presented as the median value of the scores obtained in each SDFT belonging to both MSCs-treated and control limbs per group (GA and GB). All tests were performed using the GraphPad InStat 3.05 statistical software package (Graph Pad Software Inc., San Diego, CA, USA) with $P < .05$.

Table 1
Score used for each variable during the histopathological evaluation of the healing process of the SDTF in the MSCs-treated and control limbs

Variables	Scores and Criteria
Fibroblastic density	0: Sparse (normal) 1: Slight increase 2: Moderate increase 3: Sheets of fibroblasts
Neovascularization (vessel numbers)	0: Normal 1: Slight increase 2: Moderate increase 3: Severe increase
Inflammatory infiltrate	0: None 1: Slight increase 2: Moderate increase 3: Severe increase
Tissue organization	0: None 1: Discretely organized 2: Moderately organized 3: Organized (normal)

2.13. Immunohistochemical Analyses

To perform immunohistochemical analysis, fresh 3-μm sections were obtained from paraffin blocks and placed on ImmunoSlides (EasyPath, São Paulo, Brazil) histological slides. For each specific type of analysis, two slides of biopsied tendon tissue were prepared. The process was initiated with deparaffinization in successive xylol washes, three immersions in absolute alcohol, followed by decreasing concentrations (95% and 85%) of alcohol solution, after which antigen retrieval was performed by enzymatic digestion with 1% pepsin (pH: 1.8) in a heater at 60°C for 10 minutes, followed by 50 minutes at 37°C. Endogenous peroxidase blockage was achieved with hydrogen peroxide (3%) in methanol for 20 minutes, followed by 10 washes with distilled water and two washes of 5 minutes in tris(hydroxymethyl)aminomethane (pH: 7.4). After blocking peroxidase, followed by a blockade of specific binding with 3% milk powder for 1 hour in a heater at 27°C, the slides were subsequently washed with TRIS. Incubation of primary antibodies was performed for 18 hours (overnight) at 4°C, using polyclonal anti-bovine collagen for collagen types I (purified rabbit anti-bovine type I collagen, Novotec, Saint Martin La Garenne, France) and III (purified rabbit anti-bovine type III collagen, Novotec, Saint Martin La Garenne, France). The dilutions used were 1:2000 and 1:1000, respectively. The secondary antibody EnVision (Dako, Carpinteria, CA, USA) was incubated at room temperature for 1 hour. The material was then incubated with the chromogen DAB (Dako,

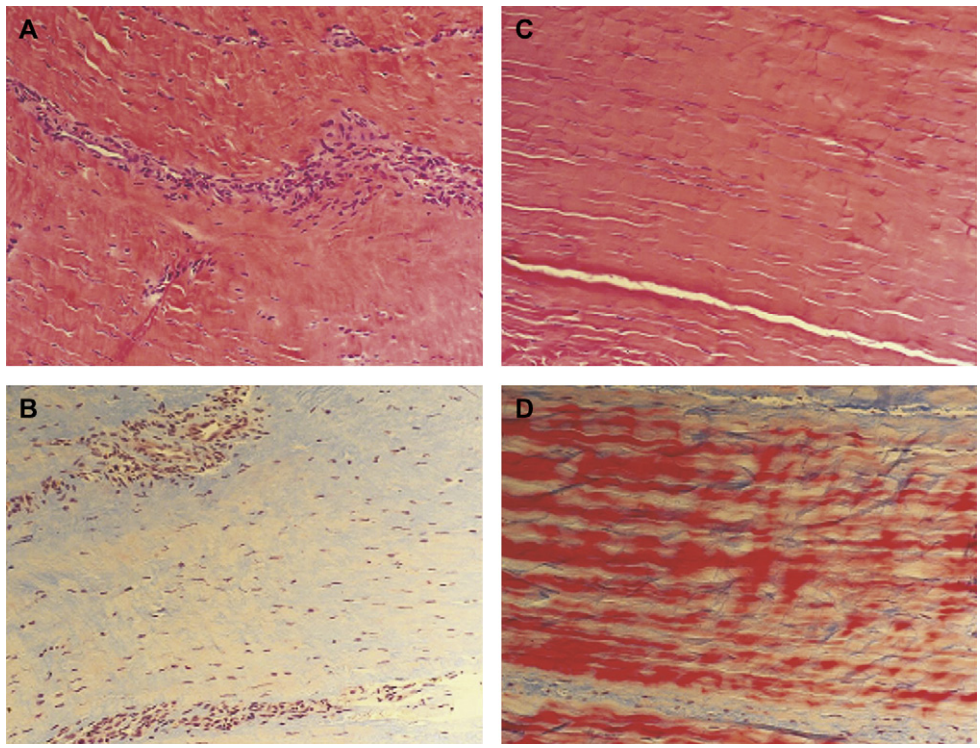

Fig. 1. Histopathological sections at 60 days. (**A**) Control limb (GA): moderate mononuclear perivascular infiltrate and greater cellularity (greater number of nuclei) in the tendon. Unaligned extracellular matrix (hematoxylin and eosin [HE], 20× magnification). (**B**) Control limb (GA): presence of noncollagenized conjunctive tissue, presence of perivascular inflammatory infiltrate, and greater cellularity (Masson's trichrome, 20× magnification). (**C**) Treated limb (GA): parallel arrangement of collagen fibers similar to healthy tendon, lower cellularity as compared with control group (HE, 20× magnification). (**D**) Treated limb (GA): greater collagen deposits (red staining) in the tendon (Masson's trichrome, 20× magnification).

Carpinteria, CA, USA), at a dilution rate of 1 drop per mL. Counterstaining was performed with hematoxylin. To determine collagen expression in the samples collected from the tendons of the control and treatment groups, five fields of each fragment were evaluated. These were obtained by optical microscopy of the slides containing tendon tissue at 400× magnification. The five fields were selected at opposing extremities of the slide, with the fifth field at the center.

In each field, the percentage of labeled cells was measured using Leica Qwin 3.0 (Leica Microsystems, Wetzlar, Germany) software through a binary image processor, during the detection of collagen types I and III in the stained regions. The results are presented as a percentage of stained regions per field. Five fields were analyzed on the basis of optical microscopy of tendon tissue slides at 400× magnitude. These five fields were selected from the four extremities of the slide, with the fifth field of vision at the center. Regarding the statistical analysis of immunohistochemical characteristics (collagen type I and type III), two ANOVAs were performed, one for the biopsy data of GA and the other for GB. The design was randomized blocks, comparing the treated and control groups, with 20 repetitions.

3. Results

Adipose tissue was successfully collected from all the horses and a mean of 2 g of material was collected from each tissue. The skin incisions healed without complications in all mares, except one, in whom dehiscence of the cutaneous suture occurred during the postoperative period. In this mare, the wound was cicatrized by second intention.

The number of MSCs that were viable during cell culture varied between 9.1×10^6 and 17.8×10^6 cells (mean of 14.35×10^6 cells) in the first passage and 10.2×10^6 and 52.9×10^6 cells (mean of 36.53×10^6 cells) in the second passage. After cell counts and calculation of the cellular viability of the second passage, 10×10^6 adipose tissue-derived MSCs were separated and diluted in 0.5 mL of autologous serum and quickly placed in refrigerated thermal containers containing ice for immediate use in each mare.

Flow cytometry analysis revealed CD90 expression in all the passages tested (first–fourth), determining interspecies cross-reactivity between rats and horses. CD44 also expressed a reaction with MSCs in all the passages; however, greater expression showing a statistically significant difference was observed as the number of passages increased. Regarding the analysis of surface marker CD13, no reaction was obtained with MSCs derived from equine adipose tissue [15].

Tendon implantation of the MSCs was performed and no side effects resulting from the injection occurred. Each mare received a single dose of MSCs at the lesion site guided by ultrasound equipment.

Tendinitis induced by collagenase implantation was initially diffuse, becoming more organized over time. During cellular implantation, the lesion was much more

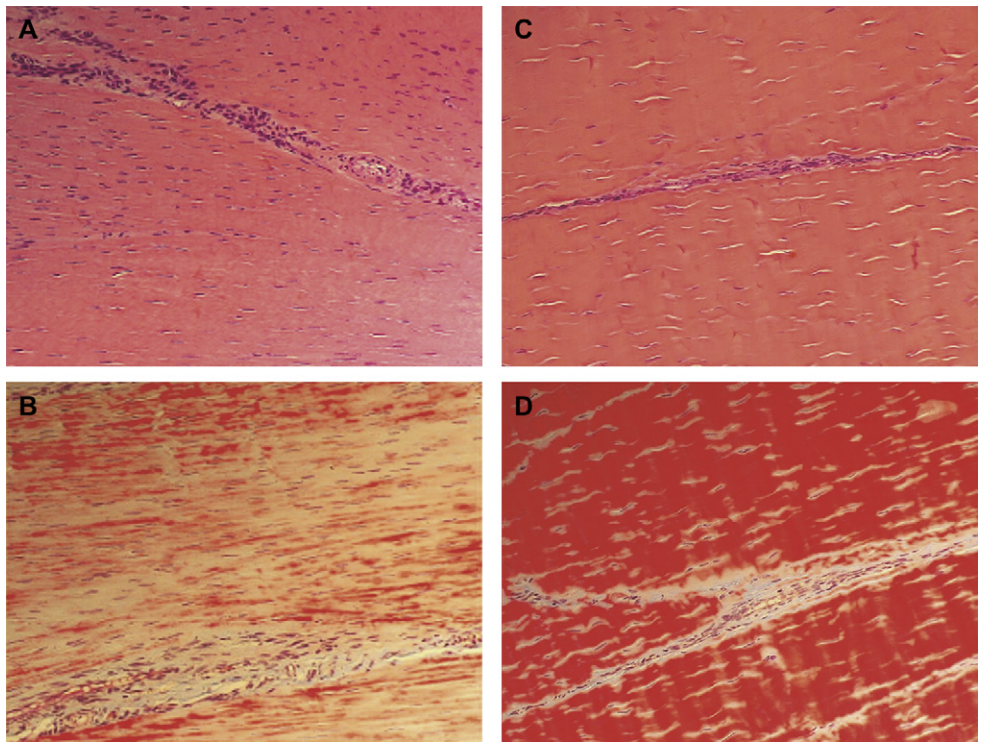

Fig. 2. Histopathological sections at 150 days. (**A**) Control limb (GB): lower cellularity in the tendon as compared with the control group at 60 days. Greater parallel arrangement of collagen fibers and less intense perivascular inflammatory infiltrate (HE stain, 20× magnification). (**B**) Control limb (GB): greater deposits of extracellular matrix (red staining) were observed as compared with the control group at 60 days, although less intense than in the treated group at 150 days (Masson's trichrome, 20× magnification). (**C**) Treated limb (GB): aspect similar to normal tendon, with the presence of parallel arranged extracellular matrix and minimal cellularity (HE, 20× magnification). (**D**) Treated limb (GB): greater collagen deposits (red staining) in the tendon as compared with the control group (Masson's trichrome, 20× magnification).

organized as compared with the initial phase and alterations in echogenicity were evident in the ultrasound examinations of treated thoracic limbs, which can be explained by the high cell concentration of the solution administered. In the control limb, the ultrasound image of tendinitis remained organized and anechoic. No visible clinical differences occurred regarding sensitivity, lameness, or in the circumference of the middle one-third of the metacarpal region between the treatment and control groups.

No difference was detected between the treated and control limbs in both groups (GA and GB) and the sonographic evaluation of the tendon area, lesion area, percentage of damaged area, degree of injury, and the degree of tendon fiber parallelism, that is, the cell therapy used in this experiment demonstrated an improvement during analysis of ultrasound imaging. The period of 150 days after lesion induction was not sufficient for the lesioned area to reveal a normal echo pattern in both treated and control limbs. Moreover, analysis of the ultrasonographic images revealed no improvement in the parallelism of the tendon fibers from the treatment and control groups.

In the histopathological analysis of GA, the MSCs-treated group had a slight to moderate increase in perivascular inflammatory infiltrate (median, 1.5), a slight to moderate increase in fibroblastic density for fibroblast sheets (median, 1.5), a slight to moderate increase in tissue organization (median, 1.5), and a moderate to strong increase in neovascularization (median, 2.5). During analyses, important morphological aspects were observed in GA under MSCs treatment: more well-defined collagen fibers in the treated limbs, together with greater organization and alignment, more representative crimps, and more elongated nuclei in the fibroblasts as compared with the control group. The blood vessels tended to elongate longitudinally, in the direction of the force exerted on the tendon (Fig. 1).

On the basis of the histopathological findings obtained for the GA controls, there was a moderate to severe increase in perivascular inflammatory infiltrate (median, 2.5), a moderate to strong increase in fibroblastic density for fibroblast sheets (median, 2.5), discretely organized tissue (median, 0.5), and a slight to moderate increase in neovascularization (median, 1.5). Differences ($P < .05$) between treated and control tendons in GA were observed in all analyses (inflammatory infiltrate, fibroblastic density, tissue organization, and neovascularization).

Regarding the histopathological findings for GB, the MSCs-treated group showed a slight increase in perivascular inflammatory infiltrate (median, 0.5), a slight increase in fibroblastic density for fibroblastic sheets (median, 1.0), normal tissue organization (median, 3.0), and a slight increase in neovascularization (median, 1.0).

The histopathological findings for GB controls showed a slight to moderate increase in perivascular inflammatory infiltrate (median, 1.5), a moderate increase in fibroblastic

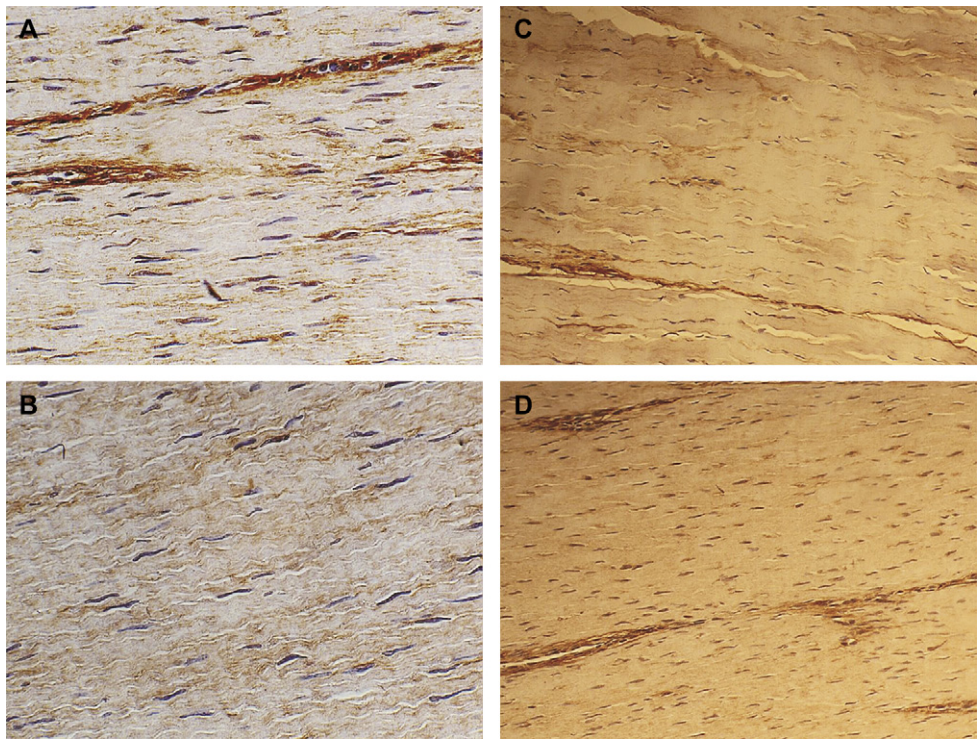

Fig. 3. Immunohistochemistry after 150 days of the experiment. (**A**) Immunohistochemistry for type I collagen, treated limb (400× magnification). (**B**) Immunohistochemistry for type I collagen, control limb (400× magnification). (**C**) Immunohistochemistry for type III collagen, treated limb (400× magnification). (**D**) Immunohistochemistry for type III collagen, control limb (400× magnification).

density (median, 2.0), moderately organized tissue organization (median, 2.0), and a slight increase in neovascularization (median, 1.0). Differences ($P < .05$) between the treated and control tendons in GB were observed in inflammatory infiltrate, fibroblastic density, and tissue organization analysis. No difference between the treated and control tendons in GB was only observed in the neovascularization analysis.

In both GA and GB, the limbs submitted to cellular therapy presented better histopathological evaluations for the tendons in relation to the control limbs; however, the treated limbs of mares in GB presented an aspect much more representative of normal tendon than the treated limbs of mares in GA. The former showed the presence of parallel arrangements of the extracellular matrix and minimal cellularity, indicating that tendon therapy involving adipose-derived MSCs resulted in improved organization of the extracellular matrix (Fig. 2).

Measurement of the percentage of the stained areas per field using type I and III collagen markers was achieved by Leica Qwin 3.0 imaging software (Leica Microsystems). Analysis of the images demonstrated a significant difference ($P < .05$) for the type I collagen marker for both periods that the biopsies were performed, with greater expression in treated tendons (mean value, 7.39) and lower expression in controls (mean value, 5.14) of GA. Analysis of the images also demonstrated significance differences ($P < .05$) for type I collagen expression in treated tendons (mean value, 7.26) of GB than in controls (mean value, 4.11). Regarding type III collagen staining, a statistically significant difference between the groups only occurred for the biopsies performed at 150 days after induction, with greater expression in GB controls (mean value, 5.50) than in treated tendons (mean value, 3.14) of GB. No statistically significant differences ($P < .05$) occurred between the analyses of the images of treated tendons (mean value, 4.98) of GA and controls (mean value, 5.10), (Fig. 3).

4. Discussion

The technique of tendon lesion induction using 2.5 mg of type I collagenase diluted in sterile water, proved to be a reliable technique for promoting experimental tendinitis in horses, as previously reported [2,14,17].

The surgical collection of adipose tissue from the base of the tail performed in this experiment also proved to be viable [1,15,18]. The techniques used to obtain the stromal vascular fraction from the adipose tissue and the posterior culture for the expansion and isolation of the MSCs performed in this study are similar to the techniques described by Vidal et al. [18]. Results verified the adherence of MSCs in culture in <48 hours, a fact in agreement with reports in previously published data concerning the characteristics of these cells to adhere to plastic when maintained in culture conditions [19].

Minimum criteria for the characterization of human MSCs were created: adherence to the plastic when maintained under culture conditions; express markers CD105, CD73, and CD90; present no expression for markers CD45, CD34, CD14 or CD11b, CD79a or CD19 and the human

leukocyte antigen-DR surface molecules; and present the capacity to differentiate into osteoblasts, adipocytes, and chondroblasts in vitro [20]. In this experiment, the immunophenotypic characterization of the surface of the MSCs used was conducted with the markers CD13, CD44, and CD90. The results obtained suggest that the cells isolated and expanded in culture should be MSCs [15]. Few markers were used because of the low number of specific monoclonal antibodies available and evidence that certain markers from other species do not cross-react with the equine species [21].

The results of markers CD90 and CD44 in the flow cytometry analyses revealed compatibility with the results obtained in experiments using MSCs derived from human adipose tissue [22-25]. The nonexpression of MSCs derived from equine adipose tissue by marker CD13 in this study was also observed in a similar work that performed the characterization of the surface of MSCs derived from equine bone marrow [26]. However, this result differs from that verified in MSCs derived from human adipose tissue, which present expression of the marker CD13 [23-25].

No significant increase in lesion cross-sectional area or pain sensitivity occurred after the implantation of adipose-derived MSCs, which is in agreement with the results reported by Fortier and Smith [27], who indicated that the implantation of bone marrow-derived MSCs did not provoke worsening of the lesion or even tendon reaction, with no increase in tendon area in ultrasonographic imaging. The dose of progenitor cells used in this study (10×10^6 cells) was within the range used by other authors [27-29]. At present, there are no published studies evaluating the optimal number of MSCs that should be used in the treatment of tendinitis. It is possible that optimization of the MSCs dose used in tendon therapy in the future could improve the results of such studies [6]. One recent report suggests that MSCs are potentially cytotoxic when injected in high concentrations directly into tumor tissue (melanoma), liberating several angiogenesis inhibitor agents that induce apoptosis and annul tumor growth, a process that would be of enormous potential in cancer therapy [30]. Whether the administration of progenitor cells in high concentrations in tendon injuries stimulates the release of angiogenesis inhibitors remains unknown, though if this does occur, it could result in the inhibition of tendon healing, which is not desirable.

The use of adipose-derived MSCs proved to be safe with the absence of neoplastic tissue formation at the lesion site where the implantation was performed during the experiment; however, Tasso et al. [31] reported that the possibility of tumor (sarcoma) formation exists when using implanted MSCs together with bioscaffold in mice. Although no reports of teratoma formation after the implantation of MSCs in horse tendon have been published, this hypothesis must be considered when using this process for tendon therapy [8].

Analysis of the results of the ultrasonographic evaluation of the tendons is in agreement with previously published reports, which affirmed no significant differences occurred in the ultrasonographic parameters between limbs that received cellular therapy and control limbs [1,6]; this is in contrast with a study by Barreira et al. [2], who affirmed that ultrasonographic differences in the mean values of the percentage of ruptured collagen fibers in a cross-sectional view occurred between the treatment and control groups after the administration of bone marrow-derived mononuclear cells. All ultrasonographic imaging was obtained by the same operator using the same ultrasound equipment, to avoid variation due to different operators and the use of different equipment. This precaution is extremely important because it has previously been demonstrated that significant interoperator variability can occur when measuring the area of the same tendon [32].

The results obtained in the present study concerning histological analysis of the tendon are in agreement with the findings of other studies [1,6], which affirm that horses that received MSCs therapy presented improved organization of tendon fibers and diminished inflammatory infiltrate.

According to Nixon et al. [1], no significant differences occurred in the statistical analysis of the immunohistochemistry results regarding the proliferation and spatial organization of type I collagen among the tendons that received therapy with nucleated cells derived from adipose tissue, but there was a reduction in the formation of type III collagen in the tendons that received treatment. Schnabel et al. [6] conducted a study using MSCs derived from bone marrow as a form of therapy for experimental equine tendinitis. They also reported no significant differences regarding the concentration of type I collagen between treated and control tendons. The result described by Nixon et al. [1] differs from that reported in this study for type I collagen, but it is similar regarding the reduction of collagen type III in the limbs that received cell implantation. A possible explanation for the difference in collagen type I expression is that, in the present study, cell implantation was performed using MSCs derived from adipose tissue that were isolated and cultured, whereas the other study implanted nucleated cells derived from adipose tissue.

In this study, we opted for the use of adipose-derived MSCs isolated and cultured in the laboratory rather than mononucleated cells derived from adipose tissue containing MSCs in smaller quantities and other cells types. Although this choice involves greater cost and is more laborious, it has an advantage in that the procedure permits isolation and expansion of the number of MSCs, thereby avoiding the administration of a heterogenous cell population that can disturb the process of tendon repair. To our knowledge, no harmful effects as a result of the presence of certain cell types in adipose-derived mononucleated cells have been reported [33]; however, according to McCarrel and Fortier [34], a correlation exists between the concentration of white blood cells contained in the material used and increased genetic expression of catabolic agents in tendons and ligaments.

Therefore, in agreement with Nixon et al. [1], the injection of MSCs derived from adipose tissue into the tendon lesion site promoted a reduction in inflammatory cell infiltrate, suggesting that these cells possess an anti-inflammatory effect on tendon regeneration or that they possess some other anti-inflammatory effect such as the stabilization or reduction of tendon fiber degeneration. The precise mechanism of the anti-inflammatory effects of these cells is largely unknown, though a combination of

these together with the antiapoptotic effect, additional recruitment of local multipotent stem cells, and the liberation of growth factors could all contribute to tendon repair [35].

5. Conclusions

Histopathological analysis showed that the lesions that received treatment with adipose-derived MSCs in both groups (GA and GB) presented more organized and uniform tissue repair as compared with the control limb, including lower cellularity in the tendon, less inflammatory infiltrate, lower fibroblastic density, greater parallel arrangement of the fibers, larger extracellular matrix deposits, and greater type I collagen expression. Although positive, future studies are required involving a larger time interval for the evaluation of tissue repair using adipose tissue as the stem cell source, using different therapy protocols and different analysis methods, including biomechanical and biochemical analysis and genetic expression, to more fully elucidate the efficacy of cellular therapy in equine tendon repair.

Acknowledgments

The authors thank the FAPESP (Fundação de Amparo a Pesquisa do Estado de São Paulo) for providing a Masters grant to the main author and to the Blood Center of the Botucatu School of Medicine of São Paulo State University (UNESP) for their support during the laboratorial phase involving cell culture and characterization.

References

[1] Nixon AJ, Dahlgren LA, Haupt JL, Yeager AE, Ward DL. Effect of adipose-derived nucleated cell fractions on tendon repair in horses with collagenase-induced tendinitis. Am J Vet Res 2008;69:928-37.
[2] Barreira APB, Alves ALG, Saito ME, Amorim RL, Kohayagawa A, Menarim BC, et al. Autologous implant of bone marrow mononuclear cells as treatment of induced equine tendinitis. Int J Appl Res Vet Med 2008;6:46-54.
[3] Woo SLY, Hildebrand K, Watanabe N, Fenwick JA, Papageorgiou CD, Wang JC. Tissue engineering of ligament and tendon healing. Clin Orthop Relat Res 1999;367:312-23.
[4] Ahmed T, Lutton JD, Feldman E, Tani K, Asano S, Abraham NG. Gene transfer of alpha interferon into hematopoietic stem cells. Leuk Res 1998;22:119-24.
[5] Guest DJ, Smith MR, Allen WR. Monitoring the fate of autologous and allogeneic mesenchymal progenitor cells injected into the superficial digital flexor tendon of horses: preliminary study. Equine Vet J 2008;40:178-81.
[6] Schnabel LV, Lynch ME, van der Muelen MCH, Yeager AE, Kornatowski MA, Nixon AJ. Mesenchymal stem cells and insulin-like growth factor-I gene-enhance mesenchymal stem cells improve structural aspects of healing in equine flexor digitorum superficialis tendons. J Orthop Res 2009;27:1392-8.
[7] Frisbie DD, Smith RKW. Clinical update on the use of mesenchymal stem cells in equine orthopaedics. Equine Vet J 2010;42:86-9.
[8] Koch TG, Berg LC, Betts DH. Current and future regenerative medicine—Principles, concepts, and therapeutic use of stem cell therapy and tissue engineering in equine medicine. Can Vet J 2009; 50:155-65.
[9] Gimble JM, Guilak F. Adipose-derived adult stem cells: isolation characterization, and differentiation potential. Cytotherapy 2003;5: 362-9.
[10] Mambelli LI, Santos EJC, Frazão PJR, Lisley I, Chaparro MB, Kerkis A, et al. Characterization of equine adipose tissue derived progenitor cells before and after cryopreservation. Tissue Eng Part C Methods 2009;15:87-94.
[11] Fortier LA, Smith RK. Regenerative medicine for tendinous and ligamentous injuries of sport horses. Vet Clin North Am Equine Pract 2008;24:191-201.
[12] Iyer SS, Rojas M. Anti-inflammatory effects of mesenchymal stem cells: novel concept for future therapies. Expert Opin Biol Ther 2008;8:569-80.
[13] Leppänen M, Miettinen S, Mäkinen S, Wilpola P, Katiskalahti T, Heikkilä P, et al. Management of equine tendon and ligament injuries with expanded autologous adipose-derived mesenchymal stem cells: a clinical study. 1st International Meeting of the VSCC. Regen Med 2009;4:S21.
[14] Maia L, Souza MV, Júnior JIR, Oliveira AC, Alves GES, Benjamin LA, et al. Platelet-rich plasma in the treatment of induced tendinopathy in horses: histologic evaluation. J Equine Vet Sci 2009;29:618-26.
[15] de Mattos Carvalho A, Alves ALG, Golim MA, Moroz A, Hussni CA, Oliveira PGG, et al. Isolation and immunophenotypic characterization of mesenchymal stem cells derived from equine species adipose tissue. Vet Immunol Immunopathol 2009;132:303-6.
[16] Genovese RL, Rantanen NW, Hauser ML, Simpson BS. Diagnostic ultrasonography of equine limbs. Vet Clin North Am Equine Pract 1986;2:145-226.
[17] Yamada ALM, Alves ALG, Hussni CA, Nicoletti JLM, Thomassian A, Watanabe MJ, et al. Comparison of different doses of collagenase-induced equine tendonitis: clinical and ultrasonographic study. Cienc Rural 2009;19:1124-30.
[18] Vidal MA, Kilroy GE, Lopez MJ, Johnson JR, Moore RM, Gimble JM. Characterization of equine adipose tissue-derived stromal cells: adipogenic and osteogenic capacity and comparison with bone marrow derived mesenchymal stromal cells. Vet Surg 2007;36:613-22.
[19] Schäffler A, Büchler C. Concise review: adipose tissue-derived stromal cells-basic and clinical implications for novel cell-based therapies. Stem Cells 2007;25:818-27.
[20] Dominici M. Minimal criteria for defining multipotent mesenchymal stromal cell. The International Society for cellular therapy position statement. Cytotherapy 2006;8:315-7.
[21] Taylor SE, Smith RKW, Clegg PD. Mesenchymal stem cell therapy in equine musculoskeletal disease: scientific fact or clinical fiction? Equine Vet J 2007;39:172-80.
[22] Dicker A, Le Blanc K, Aström G, van Harmelen V, Götherström C, Blomqvist L, et al. Functional studies of mesenchymal stem cells derived from adult human adipose tissue. Exp Cell Res 2005;308: 283-90.
[23] Mitchell JB, Micintosh K, Zvonic S, Garrett S, Floyd ZE, Kloster A, et al. Immunophenotype of human adipose-derived cells: temporal changes in stromal-associated and stem cell-associated markers. Stem Cells 2006;24:376-85.
[24] Kern S, Eichler H, Stoeve J, Klüter H, Bieback K. Comparative analysis of mesenchymal stem cells from bone marrow, umbilical cord blood, or adipose tissue. Stem Cells 2006;24:1294-301.
[25] Tapp H, Hanley ENJ, Patt JC, Gruber HE. Adipose-derived stem cells: characterization and current application in orthopaedic tissue repair. Exp Biol Med 2009;234:1-9.
[26] Radicliffe CH, Flamino MJ, Fortier LA. Temporal analysis of equine bone marrow aspirate during establishment of putative mesenchymal progenitor cell populations. Stem Cells Dev 2010;19:269-81.
[27] Fortier LA, Smith RK. Evidence for stem cells in cartilage regeneration. AAEP 2007;53:329-34.
[28] Avella CS, Smith RK. Ultrasound evaluation of stem cell treated tendon injuries in the horse: repair or regeneration? Ultrasound 2009;17:74-9.
[29] Smith RK, Webbon PM. Harnessing the stem cell for the treatment of tendon injuries: heralding a new dawn? Br J Sports Med 2005;39:582-4.
[30] Otsu K, Das S, Houser SD, Quadri SK, Bhattacharya S, Bhattacharya J. Concentration-dependent inhibition of angiogenesis by mesenchymal stem cells. Blood 2009;113:4197-205.
[31] Tasso R, Augello A, Carida M, Postiglione F, Tibilleti MG, Bernasconi B, et al. Development of sarcomas in mice implanted with mesenchymal stem cells seeded onto bioscaffolds. Carcinogenesis 2009;30:150-7.
[32] Pickersgill CH, Marr CM, Reid SW. Repeatability of diagnostic ultrasonographic in the assessment of the equine superficial digital flexor tendon. Equine Vet J 2001;33:33-7.
[33] Butler DL, Juncosa-Melvin N, Boivin GP, Galloway MT, Shearn JT, Gooch C, et al. Functional tissue engineering for tendon repair. A multidisciplinary strategy using mesenchymal stem cells, bioscaffolds and mechanical stimulation. J Orthop Res 2008;26:1-9.
[34] McCarrel T, Fortier L. Temporal growth factor release from platelet-rich plasma, trehalose, lyophilized platelets, and bone marrow aspirate and their effect on tendon and ligament gene expression. J Orthop Res 2009;27:1033-42.
[35] Caplan AI. Review: mesenchymal stem cells: cell—based reconstructive therapy in orthopedics. Tissue Eng 2005;11:1198-211.