



## Original article

# The antineoplastic busulphan impairs peritubular and Leydig cells, and vitamin B<sub>12</sub> stimulates spermatogonia proliferation and prevents busulphan-induced germ cell death



Estela Sasso-Cerri<sup>a,\*</sup>, Bárbara Oliveira<sup>a</sup>, Fabiane de Santi<sup>b</sup>, Flávia L. Beltrame<sup>b</sup>, Breno H. Caneguim<sup>b</sup>, Paulo S. Cerri<sup>a</sup>

<sup>a</sup> Department of Morphology, Dental School of São Paulo State University, Araraquara, SP, Brazil

<sup>b</sup> Department of Morphology and Genetics, Federal University of São Paulo, São Paulo, SP, Brazil

## ARTICLE INFO

## Keywords:

Chemotherapy  
Alkylating agent  
Testosterone levels  
Spermatogonia  
Apoptosis  
Vitamin

## ABSTRACT

Busulphan (Bu), an alkylating agent used for bone marrow and spermatogonial stem cell transplantation (SSCT), impairs Sertoli (SC) cells, which are necessary for the spermatogonial stem cell (SSC) homing during transplantation. As Leydig (LC) and peritubular myoid (PMC) cells are essential for SC support and maintenance of spermatogonial niche, we evaluated the impact of Bu on the LC and PMC structural integrity. Vitamin B<sub>12</sub> (B<sub>12</sub>) has demonstrated beneficial effects against drug-induced testicular changes; thus, we also examined whether this vitamin is able to stimulate spermatogonia mitotic activity and prevent Bu-induced germ cell death. Rats received 10 mg/kg of Bu in the 1st and 4th days, and daily B<sub>12</sub> supplementation during Bu treatment and for 6 days after the last injection of Bu (Bu-6d), totaling 10 days of treatment. Other animals received the same treatment as Bu-6d, and B<sub>12</sub> supplementation (Bu + 7dB<sub>12</sub>) or saline (Bu + 7dS) for 7 more days, totaling 17 days of treatment. Serum testosterone levels were measured. In the historesin-embedded testis sections, the seminiferous tubule and epithelial areas were measured, and the number of spermatogonia and PMC was quantified. Actin and 17β-HSD6 immunofluorescence was detected, and the number of TUNEL-positive LC and germ cells was computed. In Bu-6d, PMC number reduced, and a weak actin immunoeexpression and death in these cells was observed. The testosterone levels reduced, and the interstitial tissue showed a weak 17β-HSD6 immunoeexpression and increased number of TUNEL-positive LC. In Bu + 7dB<sub>12</sub>, the number of spermatogonia was higher than in Bu-6d and Bu + 7dS, and the number of TUNEL-positive germ cells was significantly lower than in Bu + 7dS. Bu exerts a harmful impact on PMC and LC, reducing the testosterone levels. Vitamin B<sub>12</sub> prevents significantly Bu-induced germ cell death and stimulates spermatogonia proliferation, being a useful strategy for the enrichment of SSC *in vitro* and an adjuvant therapy for spermatogenesis recovery in oncologic patients.

## 1. Introduction

Studies have emphasized on the important role of oncologists regarding the reproductive and fertility status of their patients, including the hormonal health [1]. In pediatric patients submitted to therapy with busulphan (Bu), an alkylating agent used for bone marrow transplantation [2], the recovery of spermatogenesis has been a slow progressive process [3]. After treatment with Bu plus cyclophosphamide or Bu alone, a few patients showed recovery of hormonal levels and/or sperm production after an average of 2 to 5 years post-transplant [4–6]. Numerous studies have focused on the clinical impact of chemotherapy on the germinal epithelium and sperm parameters [7], but little attention has been paid to the integrity of the testicular somatic cells,

such as Sertoli (SC), peritubular (PMC) and Leydig (LC) cells [8]. Treatments with gonadotoxic agents, including Bu plus cyclophosphamide, have induced reduction in testosterone concentrations [5,9] and symptoms consistent with androgen deficiency [5]. LC impairment following chemotherapy is clinically relevant [10–12]; however, the evaluation of LC in testicular biopsy of patients after cytotoxic therapy has not been performed [7], and evidence of LC impairment has been based only on the hormonal status [5,9–11] or symptoms of the patients, such as sexual dysfunction and altered mood [12].

In the testes, the spermatogonial cells are vulnerable to cytotoxic agents and may be depleted [13]. Thus, cryopreservation, sperm retrieval techniques and spermatogonial stem cell transplantation (SSCT) have been tested to preserve testicular function and fertility [7,14,15].

\* Corresponding author at: Department of Morphology, Laboratory of Histology and Embryology, Dental School of São Paulo State University, Araraquara, SP, Brazil.  
E-mail address: [esasso@foar.unesp.br](mailto:esasso@foar.unesp.br) (E. Sasso-Cerri).

GROUPS DAYS	Sham-6d	B <sub>12</sub> -6d	Bu-6d	Bu+7dB <sub>12</sub>	Bu+7dS	V+7dB <sub>12</sub>	V+7dS	Sham+7d
	1	V	V+VitB <sub>12</sub>	Bu+V+VitB <sub>12</sub>	Bu+V+VitB <sub>12</sub>	Bu+V+VitB <sub>12</sub>	V+VitB <sub>12</sub>	V+VitB <sub>12</sub>
2	S	VitB <sub>12</sub>	VitB <sub>12</sub>	VitB <sub>12</sub>	VitB <sub>12</sub>	VitB <sub>12</sub>	VitB <sub>12</sub>	S
3	S	VitB <sub>12</sub>	VitB <sub>12</sub>	VitB <sub>12</sub>	VitB <sub>12</sub>	VitB <sub>12</sub>	VitB <sub>12</sub>	S
4	V	V+VitB <sub>12</sub>	Bu+V+VitB <sub>12</sub>	Bu+V+VitB <sub>12</sub>	Bu+V+VitB <sub>12</sub>	V+VitB <sub>12</sub>	V+VitB <sub>12</sub>	V
5	S	VitB <sub>12</sub>	VitB <sub>12</sub>	VitB <sub>12</sub>	VitB <sub>12</sub>	VitB <sub>12</sub>	VitB <sub>12</sub>	S
6	S	VitB <sub>12</sub>	VitB <sub>12</sub>	VitB <sub>12</sub>	VitB <sub>12</sub>	VitB <sub>12</sub>	VitB <sub>12</sub>	S
7	S	VitB <sub>12</sub>	VitB <sub>12</sub>	VitB <sub>12</sub>	VitB <sub>12</sub>	VitB <sub>12</sub>	VitB <sub>12</sub>	S
8	S	VitB <sub>12</sub>	VitB <sub>12</sub>	VitB <sub>12</sub>	VitB <sub>12</sub>	VitB <sub>12</sub>	VitB <sub>12</sub>	S
9	S	VitB <sub>12</sub>	VitB <sub>12</sub>	VitB <sub>12</sub>	VitB <sub>12</sub>	VitB <sub>12</sub>	VitB <sub>12</sub>	S
10	S	VitB <sub>12</sub>	VitB <sub>12</sub>	VitB <sub>12</sub>	VitB <sub>12</sub>	VitB <sub>12</sub>	VitB <sub>12</sub>	S
11	Euthanasia	Euthanasia	Euthanasia	VitB <sub>12</sub>	S	VitB <sub>12</sub>	S	S
12				VitB <sub>12</sub>	S	VitB <sub>12</sub>	S	S
13				VitB <sub>12</sub>	S	VitB <sub>12</sub>	S	S
14				VitB <sub>12</sub>	S	VitB <sub>12</sub>	S	S
15				VitB <sub>12</sub>	S	VitB <sub>12</sub>	S	S
16				VitB <sub>12</sub>	S	VitB <sub>12</sub>	S	S
17				VitB <sub>12</sub>	S	VitB <sub>12</sub>	S	S
18				Euthanasia	Euthanasia	Euthanasia	Euthanasia	Euthanasia

Fig. 1. Protocol of treatment applied to the animals according to the groups.

As Bu induces death and depletion of spermatogonia [13,16–18], this drug has been widely used to prepare testicular recipients for SSCT [5,19,20]. The spermatogonial cell homing is a critical step for a successful transplantation. In this case, spermatogonial stem cells (SSC) need to attach to Sertoli cells, pass through the blood-testis barrier, migrate into the germline niche and attach to the basement membrane [21]. SSC express integrins which are essential for the attachment of these cells to the basement membrane and subsequent homing to their niche [22]. Therefore, a promissory SSCT depends on the homing of SSC and an adequate and healthy surrounding microenvironment (niche), composed not only by SC, but also peritubular cells, macrophages, LC and vasculature [2,23–25]. In a previous study, we have demonstrated that the treatment with Bu for a short period of time induces structural changes and death of SC [18]. Disarrangement of the peritubular tissue has been associated to changes and death of SC, and the SC-peritubular tissue integrity is essential for the maintenance of the seminiferous epithelium [26,27]. Therefore, we hypothesize that the Bu-induced SC death could be associated to a possible harmful effect of this antineoplastic drug on the peritubular tissue and/or LC.

The recovery of spermatogenesis after cytotoxic therapy depends on the survival and mitotic activity of SSC [8]. SSCT is a promising strategy to restore fertility, even in sterile childhood cancer survivors [14,15]. However, few SSC are normally found in the small testicular biopsy from the pubertal testis, and a successful clinical SSCT in these patients depends on the proliferation capacity of human SSC in culture before transplantation [15]. Vitamin B<sub>12</sub> (cobalamin) plays an important role in DNA synthesis and cell division [28]. The vitamin B<sub>12</sub>-deficient rodents have demonstrated testicular changes, including

spermatogenesis arrest, and spermatid and sperm aplasia; however, the supplementation of the animals with vitamin B<sub>12</sub> has recovered the testicular functions [29,30]. This vitamin has also improved spermatogenesis in patients with oligospermia [31] and recovered either the doxorubicin-induced testicular damage in rodents [32,33] or spermatogenesis in cimetidine-treated rats, alleviating tubular atrophy [34]. Moreover, we have demonstrated that the number of spermatogonia in rats supplemented with vitamin B<sub>12</sub> for only 6 days after the last injection of Bu was fourfold higher than the non-supplemented animals [18]. However, in this study [18], we could not clarify whether vitamin B<sub>12</sub> stimulates spermatogonia mitotic activity and/or exerts a protective effect because the busulphan and vitamin B<sub>12</sub> were administered concomitantly.

In a previous study, we have demonstrated that Bu impairs the seminiferous tubule structure, including the SC integrity, leading to SC death [18]. In the present study, considering the importance of SC, PMC and LC for the maintenance of SSC niche, we evaluated the impact of Bu in the serum testosterone levels as well as on the LC and PMC integrity. We have also previously demonstrated that the number of spermatogonia was higher in the animals receiving co-administration of Bu plus vitamin B<sub>12</sub>; however, the way by which this vitamin exerted this effect was not clarified [18]. Therefore, here, we also investigated whether vitamin B<sub>12</sub> is able to stimulate spermatogonia mitotic activity and protect germ cell death against Bu. In this case, animals receiving vitamin for only 6 days after the last injection of Bu were compared with the animals that received this same treatment plus vitamin (or not) for 7 more days.

## 2. Material and methods

### 2.1. Animals and treatment

The animal care was conducted following the national law on animal use (CONCEA, Brasília, DF, Brazil) and the protocol regarding the animal use and treatment was approved by the Ethical Committee on Animal Use of Dental School, São Paulo State University-FOAr/UNESP, Brazil (CEUA no. 11/2009 and 03/2011).

Adult Holtzman male rats aged 100 days were maintained in polypropylene cages under 12 h light/12 h dark cycle at controlled temperature ( $23 \pm 2^\circ\text{C}$ ) and humidity ( $55 \pm 10\%$ ), with water and food provided *ad libitum*.

Busulphan (Sigma, Aldrich; USA) was diluted in polyethylene glycol [18,35] and the animals received two intraperitoneal injections of 10 mg/kg b.w. (Fig. 1), totaling 20 mg/kg b.w. The animals supplemented with vitamin B<sub>12</sub> received 3 µg of vitamin B<sub>12</sub>-cyanocobalamin (Bedozil®, 5000 µg – Bunker Indústria Farmacêutica LTDA, São Paulo, SP, Brazil). This dose of vitamin was determined from a preliminary evaluation of the quantity of daily food intake by the animals at this age [34].

According to Fig. 1, forty animals were distributed into eight groups, containing five animals each.

To evaluate the effect of Bu on the LC and PMC, three groups were used: Bu-6d, B<sub>12</sub>-6d and Sham-6d (Fig. 1). In Bu-6d, the animals received Bu in the 1st and 4th days of the treatment, and continuous daily vitamin supplementation from the 1st to 4th day and for 6 more days after the last injection of Bu, totaling 10 days of treatment. The rats from the B<sub>12</sub>-6d received vehicle in the 1st and 4th days, and daily vitamin supplementation similarly to Bu-6d. In Sham-6d, the animals received vehicle in the 1st and 4th days, and injections of saline, totaling 10 days of treatment (Fig. 1).

To evaluate whether vitamin supplementation is necessary to maintain the seminiferous epithelium integrity and stimulates spermatogonia mitotic activity after Bu treatment, another two groups (Bu + 7dB<sub>12</sub> and Bu + 7dS) were evaluated (Fig. 1). In these groups, the animals received the same treatment as those from Bu-6d (1st to 10th day) except that, in Bu + 7dB<sub>12</sub>, the vitamin supplementation continued for 7 more days (11th to 17th day), whereas in Bu + 7dS, the supplementation was interrupted and the animals received saline for 7 more days, totaling 17 days of treatment. Two additional groups (V + 7dB<sub>12</sub> and V + 7dS) were used as control groups for comparison with Bu + 7dB<sub>12</sub> and Bu + 7dS, respectively. A sham group (Sham + 7d) was also used for comparison with Sham-6d. In this group, the animals received the same treatment as those from Sham-6d, and saline for 7 more days (Fig. 1).

It is important to clarify that all the animals that received the antineoplastic Bu also received concomitant doses of vitamin B<sub>12</sub> from the 1st to 4th day to avoid severe damage to the animals, such as lethargy as well as appetite and weight loss, as previously demonstrated in rats treated only with Bu [18]. In this last study, we have demonstrated that although these effects are softened by vitamin supplementation, the reduction in the number of spermatogonia induced by Bu (a purpose of this study) was still severe in the animals receiving Bu + vitamin B<sub>12</sub>.

### 2.2. Testosterone measurement

Serum testosterone concentration was measured by a chemiluminescence immunoassay by using Elecsys 2010 system and the Access Testosterone kit (Beckman Coulter, CA, USA). The antibody was specific for testosterone (0.4% cross-reactivity) and the analytical sensitivity was 10 ng/dL. The analysis was performed at São Lucas Clinical and Microbiological Laboratory (Araraquara, SP, Brazil).

### 2.3. Histological procedures

The animals were anaesthetized with 80 mg/kg bw of ketamine hydrochloride (Francotar; Virbac do Brasil Ind. Com. Ltda., Jurubatuba, São Paulo, Brazil) and 8 mg/kg bw of xylazine hydrochloride (Virbaxyl; Virbac do Brasil Ind. Com. Ltda).

Testes were removed and fixed for 48 h in 4% formaldehyde freshly prepared from paraformaldehyde (Merck, Darmstadt, Germany) buffered at pH 7.4 with 0.1 M sodium phosphate. Testicular fragments were dehydrated in graded ethanol and embedded in glycol methacrylate (historesin) or in paraffin. The historesin sections were stained with hematoxylin and eosin (H.E.) [36] for morphometric and morphological analyses, while the paraffin sections were submitted to TUNEL (Terminal deoxynucleotidyl Transferase-mediated dUTP Nick End Labeling) method and immunofluorescence reactions.

### 2.4. Seminiferous tubule areas

Three H.E.-stained non-serial testicular sections per animal were used. In each section, 15 round cross-sections of seminiferous tubules in each interval of cycle: stages I–VI, stages VII–VIII, and stages IX–XIV [37] were randomly selected, totaling 45 tubules per animal. The images were captured using a camera (DP-71; Olympus, Tokyo, Japan) attached to a light microscope (BX-51; Olympus) at  $\times 320$  magnification. The areas of the seminiferous tubule sections and seminiferous epithelium were measured using an image analysis system (Image Pro-Express 6.0; Olympus).

### 2.5. Number of spermatogonia

Three non-serial H.E.-stained testicular sections per animal were used. In each section, 10 seminiferous tubule cross sections were captured using a camera (DP-71; Olympus, Tokyo, Japan) attached to a light microscope (BX-51; Olympus), at  $\times 430$  magnification, totaling 30 tubules per animal. As the number of spermatogonia varies according to the stages of the seminiferous epithelium cycle [37], only tubules at stages IX–XIV were randomly selected for a standardized quantification of spermatogonia number. These germ cells were identified according to typical morphological features [38]. The quantification was performed by two calibrated and blinded examiners, and the number of spermatogonia per tubule was calculated.

### 2.6. Number of PMC

In three non-serial testicular sections per animal stained with H.E., 30 seminiferous tubule cross sections were randomly selected and captured using a camera (DP-71; Olympus, Tokyo, Japan) attached to a light microscope (BX-51; Olympus). In each tubular section, the number of PMC was quantified at  $\times 430$  magnification, and the number of PMC per tubule was calculated.

### 2.7. Immunofluorescence for detection of actin and 17β-HSD6

The testicular sections were immersed in 0.001 M sodium citrate buffer pH 6.0 and placed into a microwave oven at 90 °C for the antigen retrieval. The slides were washed in phosphate-buffered saline (PBS) pH 7.4 and incubated overnight at 4 °C with rabbit anti-actin antibody (Sigma-Aldrich, USA), diluted 1:100, for detection of PMC, and rabbit anti-17β-hydroxysteroid dehydrogenase 6 (17β-HSD6) antibody (Santa Cruz Biotechnology; USA), diluted 1:50, to detect LC [39]. After washing in PBS, the sections were incubated with Alexa Fluor® 488 goat anti-rabbit antibody (1:1000; Molecular Probes® by Life Technologies, Carlsbad, USA) or Alexa Fluor® 594 goat anti-rabbit IgG antibody ReadyProbes® reagent (Life Technologies, Carlsbad, USA) for 1 h at room temperature. The nuclear staining was performed with DAPI (Molecular Probes by Life Technologies; Carlsbad, California, USA).

Sections, used as negative controls, were incubated with non-immune serum in place of primary antibodies. The analyses were performed using a fluorescent microscope DM400 B LED, a camera DFC-550 and an Image Analysis System LAS4 (Leica Microsystems, Wetzlar, Germany).

## 2.8. TUNEL method

The TUNEL protocol was performed as previously described [34,40,41] and following the manufacturer instructions of ApopTag® Peroxidase In Situ Apoptosis Detection Kit (Millipore; Temecula, CA, USA). After treatment with proteinase K (Sigma-Aldrich Chemical Co., St. Louis, USA) and hydrogen peroxide, the sections were incubated with TdT (Terminal deoxynucleotidyl Transferase) enzyme for 1 h at 37 °C. Subsequent incubation with anti-digoxigenin-peroxidase was performed, and the reaction was revealed by DAB (Sigma-Aldrich Chemical Co., St. Louis, USA). Carazzi's hematoxylin was used for nuclear staining. For the sections used as negative controls, the same protocol was followed, except that the sections were incubated with a TdT-free solution.

## 2.9. Number of TUNEL-positive germ cells

In three non-serial testicular sections per animal, the number of TUNEL-positive germ cells was quantified in 15 cross sections of seminiferous tubules, totaling 45 tubules per animal.

## 2.10. Number of TUNEL-positive LC

In three non-serial testicular sections per animal submitted to the TUNEL method, the number of TUNEL-positive LC was computed in a total of 600 interstitial cells.

## 2.11. Statistical analyses

All data are presented as mean  $\pm$  SD, and the statistical analysis was performed using GraphPad Prism® 6.01 software. The results were submitted to Student *t*-test or to one-way ANOVA followed by Student Newman Keuls' post-test. The significance level considered was  $p < 0.05$ .

## 3. Results

### 3.1. Effect of busulphan on the peritubular (PMC) and Leydig (LC) cells

#### 3.1.1. Busulphan-induced changes in the PMC

In the animals from Sham-6d group, the seminiferous epithelium showed normal histoarchitecture surrounded by an intact peritubular tissue containing normal flattened PMC (Fig. 2A and C). Otherwise, in the animals treated with Bu (Bu-6d), the seminiferous tubule sections showed irregular outline and depletion of PMC in large portions of the peritubular tissue (Fig. 2B). In these damaged tubules, the PMC showed enlarged and ovoid-shaped nucleus, condensed chromatin in the nuclear periphery and small nuclear portions next to each other, indicating nuclear fragmentation (Fig. 2D–F). Moreover, TUNEL-labeled PMC exhibiting abnormal nuclear features were also found in Bu-6d (Fig. 2G–J).

The number of PMC reduced significantly in the seminiferous tubules of the animals from Bu-6d when compared with Sham-6d (Fig. 2P).

#### 3.1.2. Busulphan-induced changes in the LC and testosterone levels

In Bu-6d, TUNEL-positive LC were usually observed in the interstitial tissue (Fig. 2K–M). Moreover, macrophages containing TUNEL-labeled structures within the cytoplasm were also found (Fig. 2M–O). In Bu-6d, the number of TUNEL-positive LC was significantly higher than

in the animals from Sham-6d (Fig. 2Q), and weak 17 $\beta$ -HSD6 immunofluorescence was observed in the LC of Bu-6d when compared to Sham-6d (Fig. 3A–D). The serum testosterone levels decreased significantly in Bu-6d (Fig. 3E).

### 3.1.3. Actin immunoeexpression in the peritubular tissue

In the animals from Sham-6d, the actin immunofluorescence in the peritubular tissue was continuous around the entire tubule (Fig. 4A and B). However, in the tubules of the animals from Bu-6d, the actin immunofluorescence was weak or absent in some portions of the peritubular tissue (Fig. 4C and D).

## 3.2. Effect of vitamin B<sub>12</sub> in the seminiferous tubules of Bu-treated rats

### 3.2.1. Tubular and epithelial areas of seminiferous tubules

In the animals from the Bu groups (Bu-6d, Bu + 7dB<sub>12</sub> and Bu + 7dS), the tubular and epithelial areas reduced significantly in comparison with the other groups. The tubular area in Bu + 7dB<sub>12</sub> was similar to Bu-6d whereas in Bu + 7dS, the tubular area was smaller than in Bu + 7dB<sub>12</sub> and Bu-6d. Either in Bu + 7dB<sub>12</sub> or Bu + 7dS, the epithelial areas decreased significantly in comparison with Bu-6d; however, in Bu + 7dB<sub>12</sub>, the epithelial area was larger than that of the animals from the Bu + 7dS (Table 1).

### 3.2.2. Tubular morphological features and number of spermatogonia

In the animals from the Sham groups (Sham-6d and Sham + 7d), B<sub>12</sub>-6d and vehicle groups (V + 7dB<sub>12</sub> and V + 7dS), the seminiferous tubules showed normal epithelial histoarchitecture with organized and concentric germ cell layers and normal spermatogonia in the basal compartment (Figs. 5A, B, F–H and 6A, B and F). The tubular sections of the animals treated with Bu, mainly Bu-6d and Bu + 7dS, showed irregular shape and were smaller than those of the other groups (Fig. 5C and E; Table 1). Tubules showing disarranged epithelium, intraepithelial vacuoles and germ cells filling the tubular lumen were also observed in these groups (Fig. 5C and E). In the animals treated with Bu and supplemented with vitamin B<sub>12</sub> for 7 more days (Bu + 7dB<sub>12</sub>), the tubules showed more preserved seminiferous epithelium than in Bu + 7dS and Bu-6d (Fig. 5D).

In the seminiferous tubules of the animals from the Bu-6d and Bu + 7dS, spermatogonia were absent in large portions of the epithelial basal compartment (Fig. 6C and E), whereas in Bu + 7dB<sub>12</sub>, these germ cells were usually found (Fig. 6D). In Bu + 7dS, step 19 spermatids abnormally positioned in the basal compartment, indicating failure in spermatid release, were usually observed in the tubules at stages IX–XIV (Fig. 6E). The quantitative analysis confirmed that the number of spermatogonia increased significantly in the animals that continued receiving vitamin supplementation for 7 more days (Bu + 7dB<sub>12</sub>) when compared with Bu + 7dS and Bu-6d (Fig. 7).

### 3.2.3. Number of TUNEL-labeled germ cells

The seminiferous tubules of the animals from the Sham groups (Sham-6d and Sham + 7d), B<sub>12</sub>-6d and vehicle groups (V + 7dB<sub>12</sub> and V + 7dS) showed few TUNEL-positive germ cells (Fig. 8A and E), whereas in Bu-6d, Bu + 7dB<sub>12</sub> and mainly in Bu + 7dS, numerous labeled germ cells were found (Fig. 8B–E). In the animals whose vitamin supplementation was interrupted (Bu + 7dS), the tubules showed a massive TUNEL labeling throughout the epithelium (Fig. 8C). The quantitative analysis confirmed that the number of TUNEL-labeled cells in this group (Bu + 7dS) was significantly higher than in Bu-6d and Bu + 7dB<sub>12</sub> (Fig. 8E). The number of TUNEL-positive germ cells in Bu + 7dB<sub>12</sub> was similar to Sham and vehicle groups (Fig. 8E).



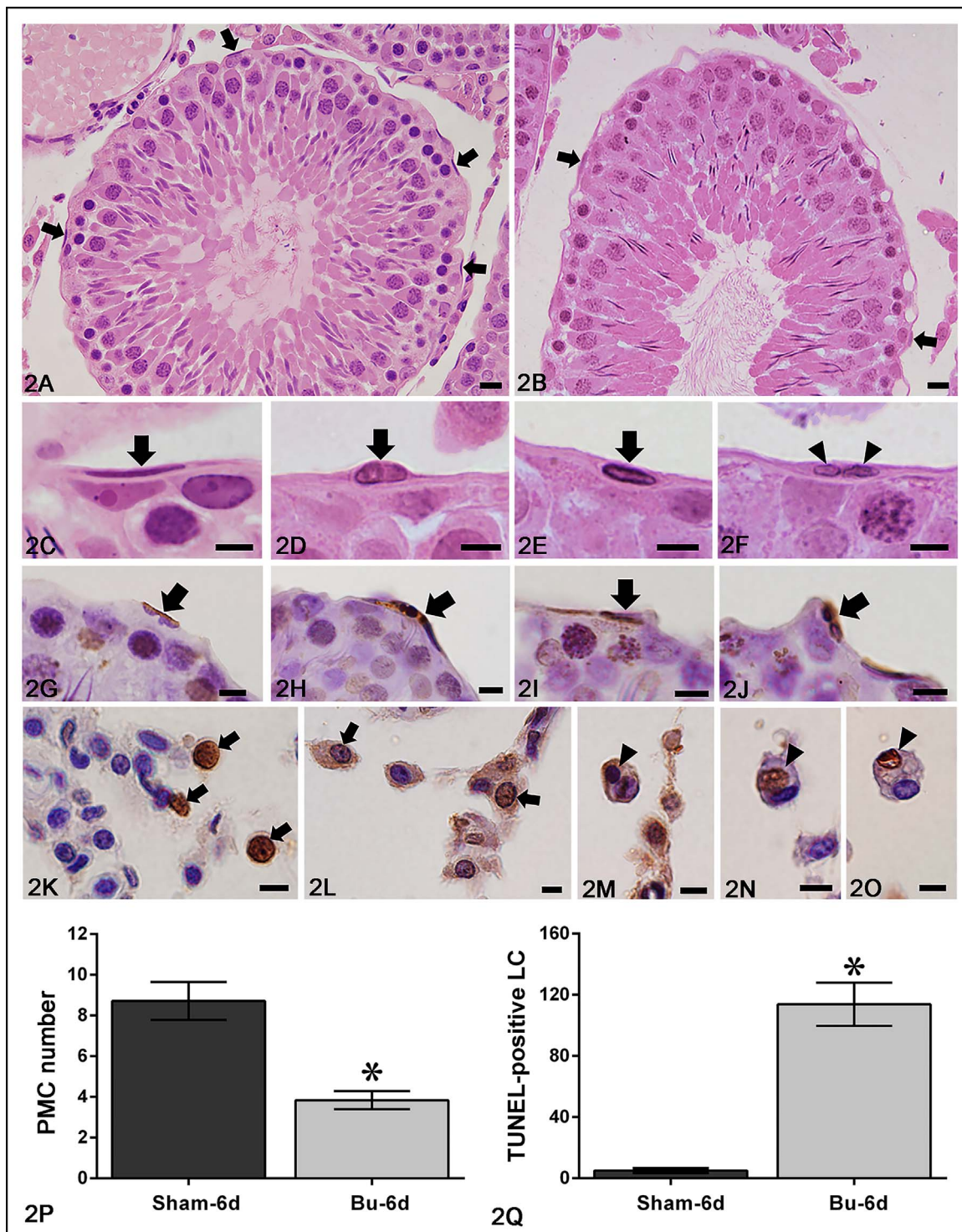


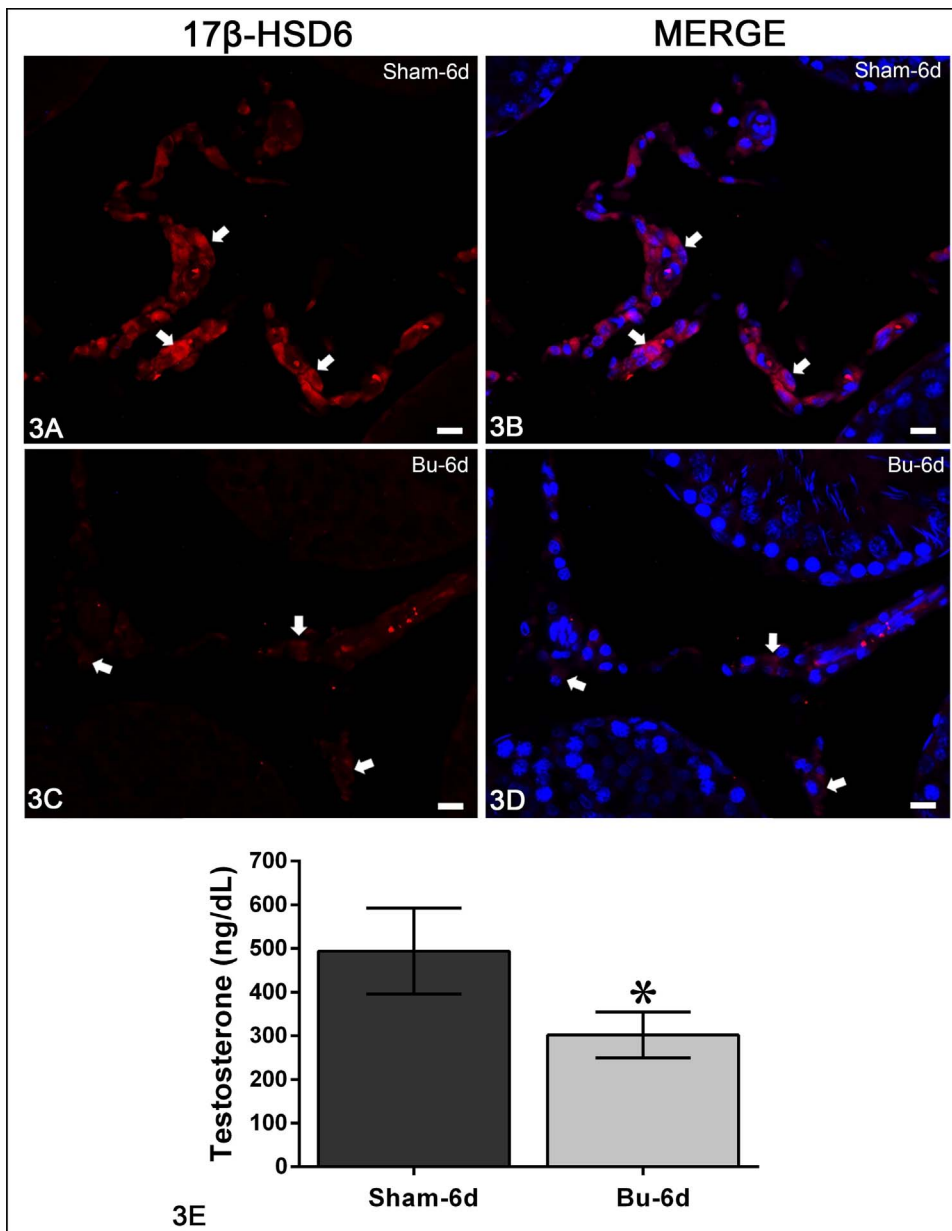
Fig. 2. Photomicrographs of testicular sections stained with H.E. (2A–2F) and submitted to TUNEL method and counterstained with hematoxylin (2G–2O) of animals from Sham-6d (2A, 2C) and Bu-6d (2B, 2D–2O). In A, PMC (arrows) can be observed throughout the intact peritubular tissue whereas in B, scarce myoid cells (arrows) can be found only in a small portion of this tissue. In C, a PMC (arrow) shows normal flattened nucleus. In D–F, the myoid cells show: ovoid-shaped nucleus (D; arrow), condensed chromatin in the nuclear periphery (E; arrow) and fragmented nucleus (F; arrowheads). In G–J, TUNEL-positive PMC exhibiting abnormal nuclear features (arrows) are observed in Bu-6d. In K–M, TUNEL-positive LC (arrows) are observed in the interstitial tissue. In M–O, macrophages containing TUNEL-positive structures within the cytoplasm (arrowheads) are also observed. Bars = 14  $\mu$ m (2A and 2B); 6  $\mu$ m (2C–2O). (2P) The number of PMC is significantly lower in the animals from Bu-6d compared to Sham-6d; asterisk ( $p < 0.05$ ). (2Q) A high number of TUNEL-labeled LC is observed in Bu-6d in comparison to Sham-6d; asterisk ( $p < 0.05$ ).

#### 4. Discussion

##### 4.1. Effect of busulphan on the peritubular myoid and Leydig cells

In a previous study, we have demonstrated that the same protocol of

Bu treatment applied in this study (Bu-6d) affected the integrity of the seminiferous tubules, including the Sertoli cells (SC), culminating in SC death [18]. Here, our findings show that the treatment with Bu (Bu-6d) also induced harmful effects on the Leydig (LC) and peritubular myoid (PMC) cells. It is known that these cells in association with SC



**Fig. 3.** Photomicrographs of testicular sections submitted to immunofluorescence for detection of 17β-HSD6. In Sham-6d (A and B), the Leydig cells show strong immunofluorescence (arrows) in comparison with Bu-6d (C and D). Bars = 14 μm. (3E) The testosterone levels in Bu-6d are significantly reduced when compared to Sham-6d asterisk ( $p < 0.05$ ).

contribute to the maintenance of SSC niche [2,23–25]. SC and PMC are responsible for the maintenance of the tubular histoarchitecture and the blood-testis barrier [42]. These cells produce specific components of the peritubular tissue extracellular matrix [43–45], express several types of alpha and beta integrin subunits [46] and synthesize factors that regulate SC functions [47]. The adherence of SC to the basement membrane has been mediated by integrin  $\alpha 6 \beta 1$  [48]. Moreover, weak cellular adhesion and cell death by apoptosis has been demonstrated in transgenic mice with lack of functional  $\beta 4$  integrin [49]. Thus, damage to the peritubular tissue components has been related to changes in the seminiferous epithelium [26,27,40,50], including detachment of SC from the basement membrane and apoptosis [26,40]. In the present study, the integrity of the PMC, including the actin filaments, was affected after only 6 days of Bu treatment, and the number of PMC decreased significantly. Therefore, the Bu-induced SC damage and death may be consequence of the treatment effect on the peritubular tissue.

It is clear that testosterone is essential for spermatogenesis. However, AR is not expressed in the germ cells [51] and is unnecessary for germ cell maturation [52,53]. As SC, PMC, LC [51] of the mature testis express androgen receptors, it has been widely accepted that the

requirement of testosterone for spermatogenesis is mediated by these cell types [54]. In PMC-ARKO males, spermatogenesis is severely impaired and the animals are infertile, confirming the crucial role for PMC-dependent AR signaling in male fertility [55]. In these PMC-ARKO mice, as the number of SC is not reduced, it has been suggested that the decrease in the number of spermatogonia is due to possible changes in the SC. This is reinforced by the fact that the levels of some SC-specific gene products are reduced in the PMC-ARKO testes, indicating that the AR signaling in PMC exerts an effect on the function of their neighboring SC [54,56]. The ablation of AR action in PMC by Myh6-Cre results in infertile individual with reduced number of germ cells, including spermatogonial germ cells [55]. Therefore, as spermatogonia are in close contact with the basement membrane and PMC, the Bu-induced spermatogonial depletion may be caused by the harmful effect of this antineoplastic drug on the PMC integrity. In the PMC-ARKO, PMC shows a progressive loss of desmin and smooth muscle actin. These changes may impair attachment and signaling between PMC and spermatogonia, leading to disruption in the SSC niche [56]. In view of the fact that PMC-spermatogonia crosstalk and the androgen action on PMC are essential for spermatogenesis and fertility [55], our data

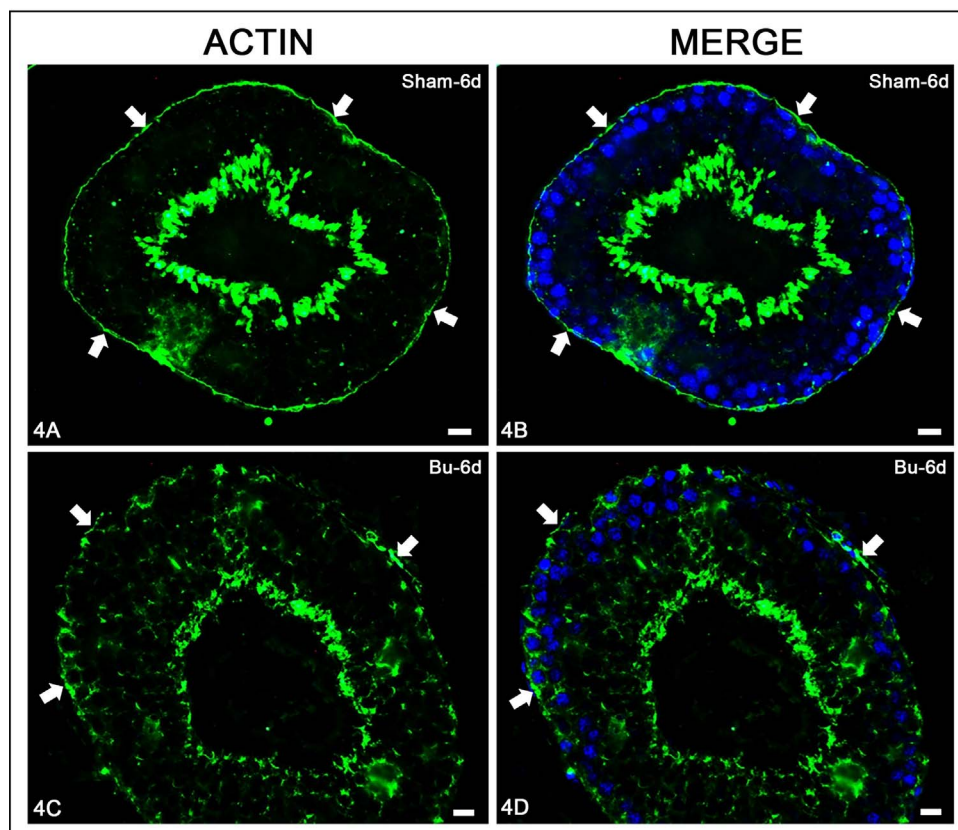


Fig. 4. Photomicrographs of testicular sections submitted to immunofluorescence for detection of actin. In Sham-6d (A and B), an evident and continuous actin immunofluorescence is observed throughout the peritubular tissue (arrows) in contrast to a weak/absent immunofluorescence surrounding the epithelium in Bu-6d (C and D). Bars = 14  $\mu$ m.

Table 1

Areas of seminiferous tubules (TA) and seminiferous epithelium (EA) in the animals from each group.

Groups	TA ( $\mu$ m <sup>2</sup> )	EA ( $\mu$ m <sup>2</sup> )
Sham-6d	88051 $\pm$ 2604 <sup>a</sup>	79549 $\pm$ 3479 <sup>a</sup>
B <sub>12</sub> -6d	88082 $\pm$ 2933 <sup>a</sup>	79706 $\pm$ 2063 <sup>a</sup>
Bu-6d	78378 $\pm$ 659 <sup>b</sup>	70425 $\pm$ 1269 <sup>b</sup>
Bu + 7dB <sub>12</sub>	70049 $\pm$ 7950 <sup>b</sup>	59811 <sup>a</sup> $\pm$ 7192 <sup>c</sup>
Bu + 7dS	59726 $\pm$ 9419 <sup>c</sup>	49823 $\pm$ 7820 <sup>d</sup>
V + 7dB <sub>12</sub>	86914 $\pm$ 1651 <sup>a</sup>	78448 $\pm$ 873 <sup>a</sup>
V + 7dS	85795 $\pm$ 2333 <sup>a</sup>	78328 $\pm$ 1847 <sup>a</sup>
Sham + 7d	84847 $\pm$ 3860 <sup>a</sup>	77149 $\pm$ 3749 <sup>a</sup>

a  $\neq$  b = c = d = statistically significant ( $p < 0.05$ ).

suggest that the spermatogonial depletion and germ cell apoptosis induced by Bu could be caused by changes in the SC, PMC and LC.

Studies focusing on the LC integrity of patients after antineoplastic therapies are scarce in the literature [7], and only findings based on the hormonal status and sexual symptoms have been reported as evidence of decreased serum testosterone levels and/or LC impairment in patients following chemotherapy [5,9–12]. Few *in vivo* studies in adult rats have demonstrated that Bu induces reduction in the serum androgen levels, in the number of LC [57] and in the volume of both interstitial tissue and LC [58]. These findings are in agreement with our results, which showed that the exposure of testes to Bu for only 6 days induced significant decrease of serum testosterone levels in parallel to weak 17 $\beta$ -HSD6 immunofluorescence and significant increase in the LC death index.

The cell type (PMC, SC or LC) primarily affected by Bu treatment needs to be clarified. As Bu reaches the seminiferous tubules through the blood stream, it is conceivable to suggest that the primary tissues to be affected by this antineoplastic drug, besides the endothelium, is the interstitial tissue and then the peritubular tissue. However, LC death may be a secondary effect following Bu-induced SC and/or PMC

changes. An *in vitro* study has demonstrated that Bu impairs the function of SC and PMC, and decreases the production of SC-PMC paracrine factors as well as the production and secretion of a LC-stimulating factor [59]. It is known that SC are not only essential for the maintenance of spermatogenesis and normal PMC cell function, but SC-derived factors act directly on LC and are essential for the maintenance of these cells, being critical regulators of germ cell development and androgen secretion [60]. Moreover, the number of human SC decreases with age [61] and aging is also related to reduction in the number [62] and function [63] of the adult LC population. Besides SC, a study has also demonstrated that PMC play a regulatory role in LH-independent testosterone production by LC [64]. Therefore, it is not surprising that damaged LC is observed in the testes whose SC and/or PMC is significantly affected by antineoplastic agents. Strategies to recover LC population should be designed to improve the fertility of patients following chemotherapy.

#### 4.2. Effect of vitamin B<sub>12</sub> on the integrity of the seminiferous epithelium and apoptotic index

The seminiferous tubules of the animals treated with Bu (Bu-6d, Bu + 7dS and Bu + 7dB<sub>12</sub>) showed abnormal histoarchitecture. However, in the animals whose vitamin B<sub>12</sub> supplementation was continued for 7 more days (Bu + 7dB<sub>12</sub>), the structural changes were less frequent than in Bu + 7dS, and the tubular and epithelial areas were larger than those of the animals from Bu-6d and Bu + 7dS. In agreement with a previous study [18], these results confirm the beneficial effect of the vitamin supplementation on the Bu-damaged seminiferous epithelium. A similar effect has also been demonstrated in the seminiferous tubule diameters of rats receiving doxorubicin plus vitamin B<sub>12</sub> [32].

In the present study, the reduction in the tubular area was caused by loss of germ cells and subsequent reduction of the epithelial area. The apoptotic index was higher in Bu-6d than in Bu + 7dB<sub>12</sub>, leading to germ cell loss and subsequent reduction of the epithelial area 7 days



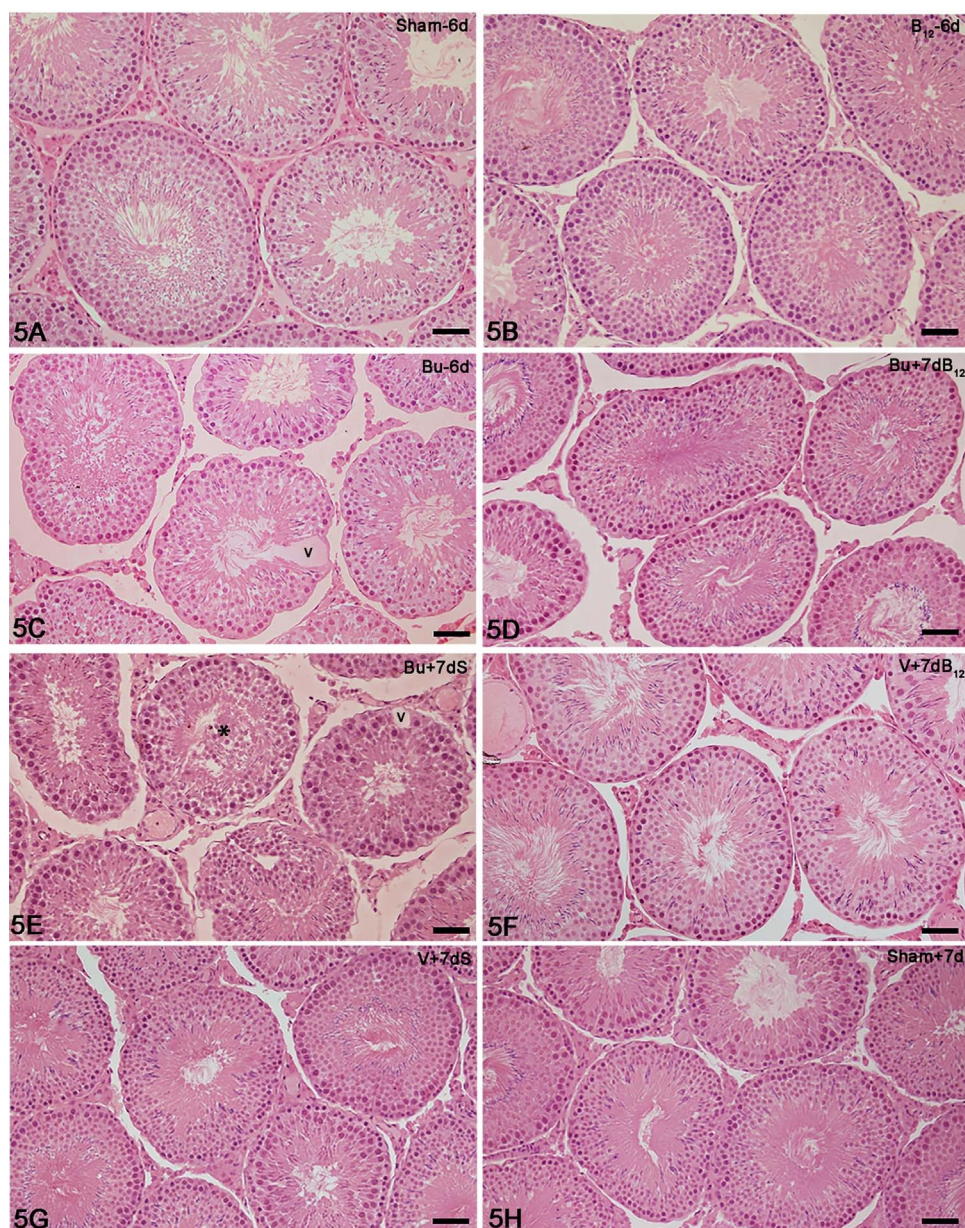


Fig. 5. Photomicrographs of testicular sections of animals from Sham-6d (A), B<sub>12</sub>-6d (B), Bu-6d (C), Bu + 7dB<sub>12</sub> (D), Bu + 7dS (E), V + 7dB<sub>12</sub> (F), V + 7dS (G) and Sham + 7d (H) stained by H.E. In A, B and F–H, the epithelium of the seminiferous tubule sections show normal morphology. In C, D and E, the tubular sections are irregularly shaped (C) and smaller than in the other groups. In C and E, the tubules show intraepithelial vacuoles (v) and detached germ cells in the lumem (asterisk). In D, the epithelial histoarchitecture of the seminiferous tubules is more preserved than in C and E. Bars = 59 μm.

later in Bu + 7dB<sub>12</sub>. However, in the seminiferous tubules of the animals whose vitamin supplementation was discontinued (Bu + 7dS), the apoptotic index increased two and fivefold in comparison with Bu-6d and Bu + 7dB<sub>12</sub>, respectively. This high apoptotic index explains the significant reduction of the epithelial area in these non-supplemented animals. The tubular and/or epithelial areas were more reduced in the animals from Bu + 7dS and Bu + 7dB<sub>12</sub> than Bu-6d due to the fact that the animals were killed 13 days after the last injection of Bu, being exposed for a longer period of time to this antineoplastic drug than the animals from Bu-6d.

Oxidative stress and cell death have been correlated with reduced levels of glutathione, a major antioxidant defense molecule [65], and an important function of vitamin B<sub>12</sub> (cobalamins) is to maintain glutathione status and the sulphhydryl groups of enzymes at a reduced state [66]. Cobalamins (especially thiolatocobalamins), maintain the intracellular glutathione levels, prevent peroxide-induced oxidative stress and avoid cell death, including apoptosis and necrosis [67]. Moreover, hydroxycobalamin, cobinamide, and dicyanocobinamide directly inhibit the isoforms of nitric oxide synthase (NOS) and then the nitric oxide production [68]. Therefore, the significant preventive effect of

vitamin against Bu-induced germ cell death observed in this study may be related to the antioxidant effect of cobalamin.

Vitamin B<sub>12</sub> is an essential cofactor in DNA synthesis and methylation, stimulating cellular proliferation [69]. Therefore, the beneficial effect of this vitamin on the seminiferous epithelium has also been related to a possible mitotic effect of this vitamin [18,34,69]. We have previously demonstrated that the number of spermatogonia after only 6 days after the last injection of Bu increased fourfold in comparison to the non-supplemented animals [18]. However, we could not clarify if this vitamin was able to exert a “protective” or “mitotic” effect on these cells since Bu and vitamin were administered concomitantly to the animals. In the present study, the comparative evaluation of the number of spermatogonia before (Bu-6d) and after the supplementation with vitamin (Bu + 7dB<sub>12</sub>) or without supplement (Bu + 7dS) for 7 more days confirmed that vitamin was able to stimulate the mitotic activity of spermatogonia whose number was two and threefold higher in Bu + 7dB<sub>12</sub> than in Bu-6d and Bu + 7dS, respectively. Recovery of spermatogenesis has also been demonstrated in rats submitted to vitamin B<sub>12</sub> deficient diet and supplemented with this vitamin [29,30]. Moreover, the changes induced by cimetidine in the seminiferous



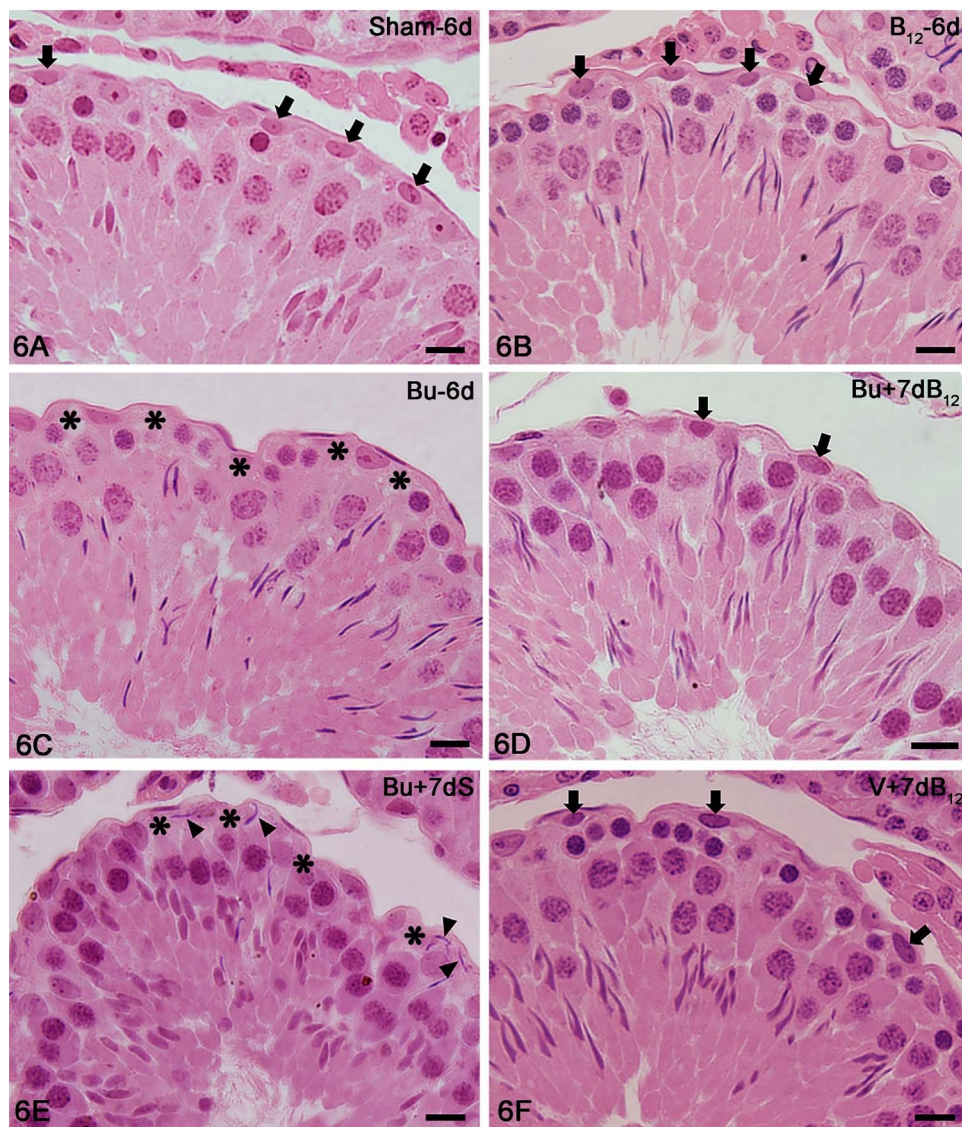


Fig. 6. Photomicrographs of seminiferous tubule sections (stages IX–XIV) of animals from Sham-6d (A), B<sub>12</sub>-6d (B), Bu-6d (C), Bu + 7dB<sub>12</sub> (D), Bu + 7dS (E) and Sham + 7d (F) stained by H.E. In A, B and F, the epithelium shows normal histoarchitecture and spermatogonia (arrows) in the basal compartment. In C and E, depletion of spermatogonia is evident (asterisks) whereas in D, spermatogonia can be observed (arrows). In E, step 19 spermatids (arrowheads) are abnormally positioned in the basal compartment. Bars = 14 μm.

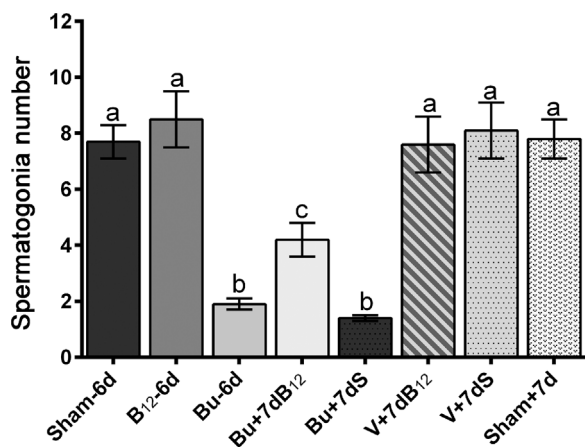


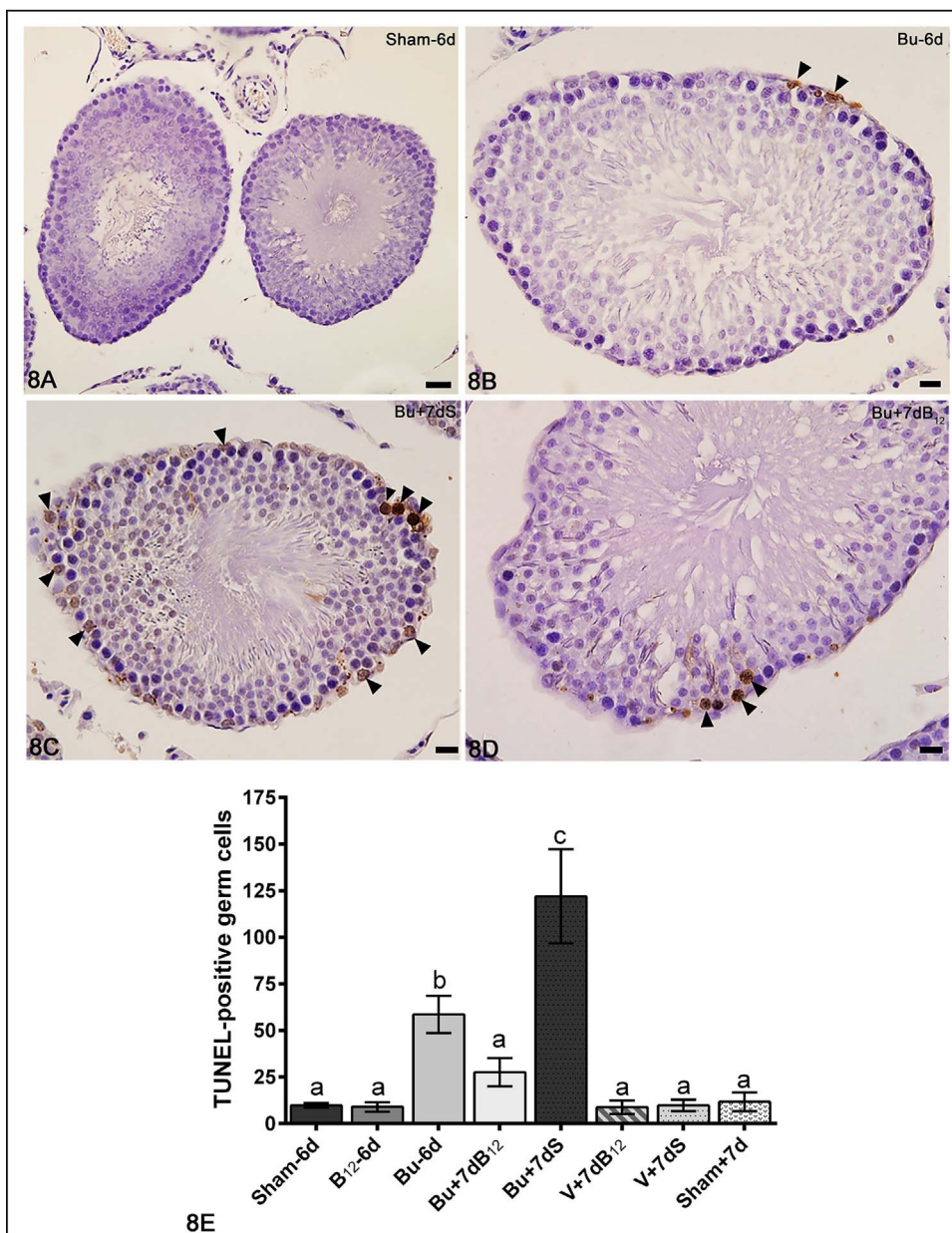
Fig. 7. The number of spermatogonia in the Bu-treated animals decreased significantly in comparison with the other groups; however, in Bu + 7dB<sub>12</sub>, the number of spermatogonia is two and three times higher than the Bu-6d and Bu + 7dS, respectively; a = b ≠ c (p < 0.05).

epithelium, including reduction in the number of SC, have also been ameliorated by vitamin B<sub>12</sub> supplementation [34,70]. A study has demonstrated that cubilin (Cubn), an intestinal intrinsic factor-cobalamin

receptor (IF-B<sub>12</sub>), has been strongly detected in a very small population of spermatogonia (probably SSC) of mouse testes [71]. Moreover, amnionless, a protein that forms a complex with Cubn and plays a role in the nutrient uptake and proliferation, has also been detected in spermatogonia [72], suggesting that Cubn participates in the nutrient uptake in the SSC of mouse testes. These findings reinforce our results and may explain how the supplementation of Bu-treated rats with vitamin B<sub>12</sub> stimulates the mitotic activity of spermatogonia. Therefore, the knowledge of the pharmacological and nutritional processes required by the SSC are essential in attempt to better elaborate adjuvant therapies to improve spermatogonial recovery in oncologic patients, including autotransplantation of SSC to restore fertility in childhood cancer survivors.

### 5. Conclusions

The treatment with the antineoplastic Bu induces significant changes in the PMC and LC, culminating in death of these cells and reduction in the serum testosterone levels. These changes may explain the deleterious effect of Bu on the SC. Thus, strategies to protect the structural and functional integrity of these somatic cells that constitute the spermatogonial niche should be performed in attempt to improve the spermatogenesis progression after SSC transplantation following Bu treatment. The supplementation with vitamin B<sub>12</sub> improves the



**Fig. 8.** Photomicrographs of testicular sections submitted to TUNEL method and counterstained with hematoxylin. Seminiferous tubule sections of animals from Sham-6d (A), Bu-6d (B), Bu + 7dS (C) and Bu + 7dB<sub>12</sub> (D). In A, TUNEL-positive cells are not found. In B and D, occasional TUNEL-positive germ cells are observed whereas in C, numerous TUNEL-labeled cells are seen throughout the epithelium. Bars = 29  $\mu$ m (8A); 14  $\mu$ m (8B–8D). (8E) The number of TUNEL-positive germ cells is significantly higher in the animals from Bu + 7dS compared to the other groups;  $a \neq b \neq c$  ( $p < 0.05$ ).

seminiferous epithelium integrity impaired by Bu, stimulates spermatogonia mitotic activity and exerts a preventive effect against Bu-induced germ cell death. Therefore, vitamin B<sub>12</sub> supplementation may be an excellent strategy for the enrichment of SSC *in vitro* and a useful adjuvant therapy to improve fertility in oncologic patients.

#### Conflict of interest statement

The authors declare that they have no competing interests.

#### Acknowledgements

We thank Luis Antônio Potenza and Pedro Sérgio Simões for the histological technical assistance. This work was supported by FAPESP (2011/19454-6; 2012/23845-3) and CNPq.

#### References

- [1] T.K. Woodruff, K. Smith, W. Gradishar, Oncologists' role in patient fertility care: a call to action, *JAMA Oncol.* 2 (2016) 171–172, <http://dx.doi.org/10.1001/jamaoncol.2015.5609>.
- [2] P. Kadam, D. Van Saen, E. Goossens, Can mesenchymal stem cells improve spermatogonial stem cell transplantation efficiency? *Andrology* 5 (2017) 2–9, <http://dx.doi.org/10.1111/andr.12304>.
- [3] M. Wilhelmsson, A. Vatanen, B. Borgström, B. Gustafsson, M. Taskinen, U.M. Saarinen-Pihkala, J. Winiarski, K. Jahnukainen, Adult testicular volume predicts spermatogenic recovery after allogeneic HSCT in childhood and adolescence, *Pediatr. Blood Cancer* 61 (2014) 1094–10000, <http://dx.doi.org/10.1002/pbc.24970>.
- [4] B.J.S. Sanderson, A.J. Shield, Mutagenic damage to mammalian cells by therapeutic alkylating agents, *Mutat. Res.* 355 (1996) 41–57, [http://dx.doi.org/10.1016/0027-5107\(96\)00021-8](http://dx.doi.org/10.1016/0027-5107(96)00021-8).
- [5] A.P. Grigg, R. McLachlan, J. Zaja, J. Szer, Reproductive status in long-term bone marrow transplant survivors receiving busulfan-cyclophosphamide (120 mg/kg), *Bone Marrow Transplant* 26 (2000) 1089–1095, <http://dx.doi.org/10.1038/sj.bmt.1702695>.
- [6] C. Pfitzer, H. Orawa, M. Balcerek, T. Langer, U. Dirksen, P. Keslova, N. Zubarovskaya, F.R. Schuster, A. Jarisch, G. Strauss, A. Borgmann-Staudt, Dynamics of fertility impairment and recovery after allogeneic haematopoietic stem cell transplantation in childhood and adolescence: results from a longitudinal study, *J. Cancer Res. Clin. Oncol.* 141 (2015) 135–142, <http://dx.doi.org/10.1007/s00432-014-1781-5>.
- [7] S.J. Howell, S.M. Shalet, Testicular function following chemotherapy, *Hum. Reprod. Update* 7 (2001) 363–369.



- [8] C. Zavras, A. Siristatidis, A. Siatelis, Fertility Risk Assessment and Preservation in male and female prepubertal and adolescent cancer patients, *Clin. Med. Insights Oncol.* 10 (2016) 49, <http://dx.doi.org/10.4137/CMO.S32811>.
- [9] E. Whitehead, S.M. Shalet, G. Blackledge, I. Todd, D. Crowther, C.G. Beardwell, The effects of Hodgkin's disease and combination chemotherapy on gonadal function in the adult male, *Cancer* 49 (1982) 418–422.
- [10] S.J. Holmes, R.W. Whitehouse, S.T. Clark, D.C. Crowther, J.E. Adams, S.M. Shalet, Reduced bone mineral density in men following chemotherapy for Hodgkin's disease, *Br. J. Cancer* 70 (1994) 371–375.
- [11] S.J. Howell, J.A. Radford, J.E. Adams, S.M. Shalet, The impact of mild Leydig cell dysfunction following cytotoxic chemotherapy on bone mineral density (BMD) and body composition, *Clin. Endocrinol. (Oxf.)* 52 (2000) 609–616.
- [12] S.J. Howell, J.A. Radford, E.M. Smets, S.M. Shalet, Fatigue, sexual function and mood following treatment for haematological malignancy: the impact of mild Leydig cell dysfunction, *Br. J. Cancer* 82 (2000) 789–793, <http://dx.doi.org/10.1054/bjoc.1999.1000>.
- [13] L.R. Bucci, M.L. Meistrich, Effects of busulfan on murine spermatogenesis: cytotoxicity, sterility, sperm abnormalities, and dominant lethal mutations, *Mutat. Res.* 176 (1987) 259–268.
- [14] A. Polland, B.M. Berookhim, Fertility concerns in men with genitourinary malignancies: treatment dilemmas, fertility options, and medicolegal considerations, *Urol. Oncol.* 34 (2016) 399–406, <http://dx.doi.org/10.1016/j.urolonc.2016.05.007>.
- [15] C.L. Mulder, Y. Zheng, S.Z. Jan, R.B. Struijk, S. Repping, G. Hamer, A.M.M. van Pelt, Spermatogonial stem cell autotransplantation and germline genomic editing: a future cure for spermatogenic failure and prevention of transmission of genomic diseases, *Hum. Reprod. Update* 22 (2016) 561–573, <http://dx.doi.org/10.1093/humupd/dmw017>.
- [16] Y.J. Choi, D.W. Ok, D.N. Kwon, J. Il Chung, H.C. Kim, S.M. Yeo, T. Kim, H.G. Seo, J.H. Kim, Murine male germ cell apoptosis induced by busulfan treatment correlates with loss of c-kit-expression in a Fas/FasL and p53-independent manner, *FEBS Lett.* 575 (2004) 41–51, <http://dx.doi.org/10.1016/j.febslet.2004.08.034>.
- [17] R. Benavides-Garcia, R. Joachim, N.A. Pina, K.N. Mutoji, M.A. Reilly, B.P. Hermann, Granulocyte colony-stimulating factor prevents loss of spermatogenesis after sterilizing busulfan chemotherapy, *Fertil. Steril.* 103 (2015) 270–280, <http://dx.doi.org/10.1016/j.fertnstert.2014.09.023>.
- [18] S.R. Vasiliausha, F.L. Beltrame, F. de Santi, P.S. Cerri, B.H. Caneguim, E. Sasso-Cerri, Seminiferous epithelium damage after short period of busulfan treatment in adult rats and vitamin B<sub>12</sub> efficacy in the recovery of spermatogonial germ cells, *Int. J. Exp. Pathol.* 97 (2016) 317–328, <http://dx.doi.org/10.1111/iep.12195>.
- [19] K. Zohni, X. Zhang, S.L. Tan, P. Chan, M.C. Nagano, The efficiency of male fertility restoration is dependent on the recovery kinetics of spermatogonial stem cells after cytotoxic treatment with busulfan in mice, *Hum. Reprod.* 27 (2012) 44–53, <http://dx.doi.org/10.1093/humrep/der357>.
- [20] Y. Qin, L. Liu, Y. He, W. Ma, H. Zhu, M. Liang, H. Hao, T. Qin, X. Zhao, D. Wang, Testicular injection of busulfan for recipient preparation in transplantation of spermatogonial stem cells in mice, *Reprod. Fertil. Dev.* 28 (2016) 1916–1925, <http://dx.doi.org/10.1071/RD14290>.
- [21] M. Nagano, M.R. Avarbock, R.L. Brinster, Pattern and kinetics of mouse donor spermatogonial stem cell colonization in recipient testes, *Biol. Reprod.* 60 (1999) 1429–1436.
- [22] T. Shinohara, M.R. Avarbock, R.L. Brinster, Beta1 and alpha6 integrin are surface markers on mouse spermatogonial stem cells, *Proc. Natl. Acad. Sci. U. S. A.* 96 (1999) 5504–5509.
- [23] D.J. McLean, Spermatogonial stem cell transplantation and testicular function, *Cell Tissue Res.* 322 (2005) 21–31, <http://dx.doi.org/10.1007/s00441-005-0009-z>.
- [24] D.G. De Rooij, The spermatogonial stem cell niche, *Microsc. Res. Tech.* 72 (2009) 580–585, <http://dx.doi.org/10.1002/jemt.20699>.
- [25] J.M. Oatley, R.L. Brinster, The germline stem cell niche unit in mammalian testes, *Physiol. Rev.* 92 (2012) 577–595, <http://dx.doi.org/10.1152/physrev.00025.2011>.
- [26] E. Sasso-Cerri, P.S. Cerri, Morphological evidences indicate that the interference of cimetidine on the peritubular components is responsible for detachment and apoptosis of Sertoli cells, *Reprod. Biol. Endocrinol.* 6 (2008) 1–10, <http://dx.doi.org/10.1186/1477-7827-6-18>.
- [27] B.H. Caneguim, P.S. Cerri, L.C. Spolidório, S.M. Miraglia, E. Sasso-Cerri, Immunosuppressant prograf (Tacrolimus) induces histopathological disorders in the peritubular tissue of rat testes, *Cells Tissues Organs* 194 (2011) 421–430, <http://dx.doi.org/10.1159/000322901>.
- [28] R. Oh, D.L. Brown, Vitamin B<sub>12</sub> deficiency, *Am. Fam. Physician* 67 (2003) 979–986.
- [29] T. Kawata, A. Tamiki, A. Tashiro, K. Suga, S. Kamioka, K. Yamada, M. Wada, N. Tanaka, T. Tadokoro, A. Maekawa, Effect of vitamin B<sub>12</sub>-deficiency on testicular tissue in rats fed by pair-feeding, *Int. J. Vitam. Nutr. Res.* 67 (1997) 17–21.
- [30] T. S. Watanabe, S. Ebara, K. Kimura, Y. Maeda, H. Watanabe, S. Watanabe, Kasai, Y. Nakano, Maternal vitamin B<sub>12</sub> deficiency affects spermatogenesis at the embryonic and immature stages in rats, *Congenit. Anom. (Kyoto)* 47 (2007) 9–15, <http://dx.doi.org/10.1111/j.1741-4520.2006.00135x>.
- [31] A.A. Sharp, L.J. Witts, Seminal vitamin B<sub>12</sub> and sterility, *Lancet* 2 (1962) 779.
- [32] S. Ozaki, I. Ohkawa, Y. Katoh, T. Tajima, M. Kimura, S. Orikasa, Study on producing rats with experimental testicular dysfunction and effects of mecobalamin, *Nihon Yakurigaku Zasshi.* 91 (1988) 197–207.
- [33] S. Oshio, S. Ozaki, I. Ohkawa, T. Tajima, S. Kaneko, H. Mohri, Mecobalamin promotes mouse sperm maturation, *Andrologia* 21 (1989) 167–173.
- [34] F.L. Beltrame, B.H. Caneguim, S.M. Miraglia, P.S. Cerri, E. Sasso-Cerri, Vitamin B<sub>12</sub> supplement exerts a beneficial effect on the seminiferous epithelium of cimetidine-treated rats, *Cells Tissues Organs* 193 (2011) 184–194, <http://dx.doi.org/10.1159/000319371>.
- [35] A. Zarbock, K. Singbartl, K. Ley, Complete reversal of acid-induced acute lung injury by blocking of platelet-neutrophil aggregation, *J. Clin. Invest.* 116 (2006) 3211–3219, <http://dx.doi.org/10.1172/JCI29499>.
- [36] P.S. Cerri, E. Sasso-Cerri, Staining methods applied to glycol methacrylate embedded tissue sections, *Micron* 34 (2003) 365–372, [http://dx.doi.org/10.1016/S0968-4328\(03\)00098-2](http://dx.doi.org/10.1016/S0968-4328(03)00098-2).
- [37] M. Dym, Y. Clermont, Role of spermatogonia in the repair of the seminiferous epithelium following X-irradiation of the rat testis, *Am. J. Anat.* 128 (1970) 265–282, <http://dx.doi.org/10.1002/aja.1001280302>.
- [38] H. Chiarini-Garcia, A.M. Raymer, L.D. Russell, Non-random distribution of spermatogonia in rats: evidence of niches in the seminiferous tubules, *Reproduction* 126 (2003) 669–680, <http://dx.doi.org/10.1530/reprod/126.5.669>.
- [39] F.L. Beltrame, P.S. Cerri, E. Sasso-Cerri, Cimetidine-induced Leydig cell apoptosis and reduced EG-VEGF (PK-1) immunoposition in rats: evidence for the testicular vasculature atrophy, *Reprod. Toxicol.* 57 (2015) 50–58, <http://dx.doi.org/10.1016/j.reprotox.2015.05.009>.
- [40] E. Sasso-Cerri, S.M. Miraglia, In situ demonstration of both TUNEL-labeled germ cell and Sertoli cell in the cimetidine-treated rats, *Histol. Histopathol.* 17 (2002) 411–417.
- [41] F.L. Beltrame, C.T. Yamauti, B.H. Caneguim, P.S. Cerri, S.M. Miraglia, E. Sasso-Cerri, Cimetidine-induced vascular cell apoptosis impairs testicular microvasculature in adult rats, *Histol. Histopathol.* 27 (2012) 1343–1351.
- [42] M. Galdieri, G. Ricci, Characterization of different cell populations isolated from rat testis peritubular cells, *Differentiation* 63 (1998) 13–19, <http://dx.doi.org/10.1046/j.1432-0436.1998.6310013>.
- [43] M.K. Skinner, P.S. Tung, I.B. Fritz, Cooperativity between Sertoli cells and testicular peritubular cells in the production and deposition of extracellular matrix components, *J. Cell Biol.* 100 (1985) 1941–1947.
- [44] C.M. Davis, V. Papadopoulos, C.L. Sommers, H.K. Kleinman, M. Dym, Differential expression of extracellular matrix components in rat Sertoli cells, *Biol. Reprod.* 43 (1990) 860–869.
- [45] S.S. Raychoudhury, M.G. Irving, E.W. Thompson, A.W. Blackshaw, Collagen biosynthesis in cultured rat testicular Sertoli and peritubular myoid cells, *Life Sci.* 51 (1992) 1585–1596.
- [46] M. Magnanti, A. Gismondi, O. Gandini, F.M. Rossi, P.M. Michetti, V. Santiemmas, S. Morrone, Integrin pattern and effect on contraction in cultured testicular peritubular myoid cells, *Am. J. Reprod. Immunol.* 45 (2001) 21–27.
- [47] M.K. Skinner, I.B. Fritz, Testicular peritubular cells secrete a protein under androgen control that modulates Sertoli cell functions, *Proc. Natl. Acad. Sci. U. S. A.* 82 (1985) 114–118, <http://dx.doi.org/10.1073/pnas.82.1.114>.
- [48] I. Virtanen, J. Lohi, T. Tani, M. Korhonen, R.E. Burgeson, V.P. Lehto, I. Leivo, Distinct changes in the laminin composition of basement membranes in human seminiferous tubules during development and degeneration, *Am. J. Pathol.* 150 (1997) 1421–1431.
- [49] J. Dowling, Q.C. Yu, E. Fuchs, Beta-4 integrin is required for hemidesmosome formation, cell adhesion and cell survival, *J. Cell Biol.* 134 (1996) 559–572.
- [50] O. Zarnescu, G. Zamfirescu, Effects of lithium carbonate on rat seminiferous tubules: an ultrastructural study, *Int. J. Androl.* 29 (2006) 576–582, <http://dx.doi.org/10.1111/j.1365-2605.2006.00697>.
- [51] Q. Zhou, R. Nie, G.S. Prins, P.T.K. Saunders, B.S. Katzenellenbogen, R.A. Hess, Localization of androgen and estrogen receptors in adult male mouse reproductive tract, *J. Androl.* 23 (2002) 870–881.
- [52] M.-Y. Tsai, S.-D. Yeh, R.-S. Wang, S. Yeh, C. Zhang, H.-Y. Lin, C.-R. Tzeng, C. Chang, Differential effects of spermatogenesis and fertility in mice lacking androgen receptor in individual testis cells, *Proc. Natl. Acad. Sci. U. S. A.* 103 (2006) 18975–18980, <http://dx.doi.org/10.1073/pnas.0608565103>.
- [53] D.S. Johnston, L.D. Russell, P.J. Friel, M.D. Griswold, Murine germ cells do not require functional androgen receptors to complete spermatogenesis following spermatogonial stem cell transplantation, *Endocrinology* 142 (2001) 2405, <http://dx.doi.org/10.1210/endo.142.6.8317>.
- [54] L. O'Hara, L.B. Smith, Androgen receptor roles in spermatogenesis and infertility, *Best Pract. Res. Clin. Endocrinol. Metab.* 29 (2015) 595–605, <http://dx.doi.org/10.1016/j.beem.2015.04.006>.
- [55] M. Welsh, P.T.K. Saunders, N. Atanassova, R.M. Sharpe, L.B. Smith, Androgen action via testicular peritubular myoid cells is essential for male fertility, *FASEB J.* 23 (2009) 4218–4230, <http://dx.doi.org/10.1096/fj.09-138347>.
- [56] A. Mayerhofer, Human testicular peritubular cells: more than meets the eye, *Reproduction* 145 (2013) R107–116, <http://dx.doi.org/10.1530/REP-12-0497>.
- [57] G.F. Jansz, D.K. Pomerantz, The effect of prenatal treatment with busulfan on in vitro androgen production by testes from rats of various ages, *Can. J. Physiol. Pharmacol.* 63 (1985) 1155–1158.
- [58] M.T. Hochereau-de-Reviere, M.C. Viguier-Martinez, C. Perreau, Effects of supplementation with impuberal or adult testicular protein extracts on genital tract and testicular histology as well as hormonal levels in adult busulfan treated rats, *Andrologia* 14 (1982) 297–305.
- [59] G. Verhoeven, J. Cailleau, I.D. Morris, Inhibitory effects of alkane sulphonates on the function of immature rat Leydig, Sertoli and peritubular cells cultured in vitro, *J. Mol. Endocrinol.* 2 (1989) 145–155.
- [60] D. Rebouret, P.J. O'Shaughnessy, A. Monteiro, L. Milne, L. Cruickshanks, N. Jeffrey, F. Guillou, T.C. Freeman, R.T. Mitchell, L.B. Smith, Sertoli cells maintain Leydig cell number and peritubular myoid cell activity in the adult mouse testis, *PLoS One* 9 (2014) 1–13, <http://dx.doi.org/10.1371/journal.pone.0105687>.
- [61] L. Johnson, R.S. Zane, C.S. Petty, W.B. Neaves, Quantification of the human Sertoli cell population: its distribution, relation to germ cell numbers, and age-related decline, *Biol. Reprod.* 31 (1984) 785–795.
- [62] W.B. Neaves, L. Johnson, C.S. Petty, Age-related change in numbers of other



- interstitial cells in testes of adult men: evidence bearing on the fate of Leydig cells lost with increasing age, *Biol. Reprod.* 33 (1985) 259–269.
- [63] A.S. Midzak, H. Chen, V. Papadopoulos, B.R. Zirkin, Leydig cell aging and the mechanisms of reduced testosterone synthesis, *Mol. Cell. Endocrinol.* 299 (2009) 23–31, <http://dx.doi.org/10.1016/j.mce.2008.07.016>.
- [64] J. Mishra, M. Gautam, R. Dadhich, B.S. Kowtharapu, S.S. Majumdar, Peritubular cells may modulate Leydig cell-mediated testosterone production through a non-classic pathway, *Fertil. Steril.* 98 (2012) 1308–1317, <http://dx.doi.org/10.1016/j.fertnstert.2012.07.1124> e1.
- [65] V. Vitvitsky, E. Mosharov, M. Tritt, F. Ataulkhanov, R. Banerjee, Redox regulation of homocysteine-dependent glutathione synthesis, *Redox Rep.* 8 (2003) 57–63, <http://dx.doi.org/10.1179/135100003125001260>.
- [66] C. Wheatley, A scarlet pimpernel for the resolution of inflammation? The role of supra-therapeutic doses of cobalamin in the treatment of systemic inflammatory response syndrome (SIRS), sepsis, severe sepsis, and septic or traumatic shock, *Med. Hypotheses* 67 (2006) 124–142, <http://dx.doi.org/10.1016/j.mehy.2006.01.036>.
- [67] C.S. Birch, N.E. Brasch, A. McCaddon, J.H.H. Williams, A novel role for vitamin B<sub>12</sub>: cobalamins are intracellular antioxidants in vitro, *Free Radic Biol. Med.* 47 (2009) 184–188, <http://dx.doi.org/10.1016/j.freeradbiomed.2009.04.023>.
- [68] J.B. Weinberg, Y. Chen, N. Jiang, B.E. Beasley, J.C. Salerno, D.K. Ghosh, Inhibition of nitric oxide synthase by cobalamins and cobinamides, *Free Radic Biol. Med.* 46 (2009) 1626–1632, <http://dx.doi.org/10.1016/j.freeradbiomed.2009.03.017>.
- [69] R.V. Banerjee, R.G. Matthews, Cobalamin-dependent methionine synthase, *FASEB J.* 4 (1990) 1450–1459.
- [70] F.L. Beltrame, E. Sasso-Cerri, Vitamin B<sub>12</sub>-induced spermatogenesis recovery in cimetidine-treated rats: effect on the spermatogonia number and sperm concentration, *Asian J. Androl.* 18 (2016) 1–6, <http://dx.doi.org/10.4103/1008-682X.182397>.
- [71] Y.S. Oh, J.T. Seo, H.S. Ahn, M.C. Gye, Expression of cubilin in mouse testes and Leydig cells, *Andrologia* 48 (2016) 325–332, <http://dx.doi.org/10.1111/and.12450>.
- [72] Y.S. Oh, H.Y. Park, M.C. Gye, Expression of amnionless in mouse testes and Leydig cells, *Andrologia* 44 (2012) 383–389, <http://dx.doi.org/10.1111/j.1439-0272.2011.01195>.