

---

## Denture stomatitis treated with photodynamic therapy: five cases

Ewerton Garcia de Oliveira Mima, DDS, MSc, PhD,<sup>a</sup> Ana Cláudia Pavarina, DDS, MSc, PhD,<sup>b</sup> Mariana Montenegro Silva, DDS, MSc, PhD,<sup>c</sup> Daniela Garcia Ribeiro, DDS, MSc, PhD,<sup>d</sup> Carlos Eduardo Vergani, DDS, MSc, PhD,<sup>e</sup> Cristina Kurachi, DDS, MSc, PhD,<sup>f</sup> and Vanderlei Salvador Bagnato, MSc, PhD,<sup>f</sup> Bragança Paulista, Araraquara, São Paulo, Ponta Grossa, and São Carlos, Brazil  
SÃO FRANCISCO UNIVERSITY, UNESP-Univ Estadual Paulista, CAMILO CASTELO BRANCO UNIVERSITY, PONTA GROSSA STATE UNIVERSITY, AND UNIVERSITY OF SÃO PAULO

**Objective.** Photodynamic therapy (PDT) is an effective method for *Candida* spp. inactivation in vitro and in vivo, but as yet, no clinical trial has been conducted. This report describes 5 cases of denture stomatitis (DS) treated with PDT.

**Study design.** Five subjects with clinical and microbiologic diagnosis of DS were submitted to 6 sessions of PDT 3 times a week for 15 days. In each session, patients' dentures and palates were sprayed with 500 mg/L Photogem, and, after 30 minutes of incubation, irradiated by light-emitting diode light source at 455 nm (37.5 and 122 J/cm<sup>2</sup>, respectively). Cultures of *Candida* spp. from dentures and palates and standard photographs of the palates were taken at baseline (day 0), at the end of the treatment (day 15), and at follow-up time intervals (days 30 and 60).

**Results.** Four patients showed clinical resolution of DS (no inflammation) after PDT sessions, and only 1 subject demonstrated reduction in palatal inflammation. Recurrence of DS was observed in 2 patients during the follow-up period.

**Conclusions.** PDT appears to be an alternative treatment for DS. (*Oral Surg Oral Med Oral Pathol Oral Radiol Endod* 2011;112:602-608)

Denture stomatitis (DS) is an inflammatory lesion of the palatal mucosa under complete or partial removable dentures, which may affect up to 65% of denture wearers.<sup>1</sup> According to Newton,<sup>2</sup> DS may be classified as localized simple inflammation (type I), generalized simple inflammation (type II), or inflammatory papillary hyperplasia (type III). Although the etiology of DS appears to be multifactorial, the presence of *Candida* spp. in denture biofilm is considered to be an important factor in the development of this infection.<sup>3</sup> *Candida*

*albicans* is the most prevalent and virulent species found in DS, but other species have been shown to cause infection, with *C. glabrata*, *C. dubliniensis*, *C. parapsilosis*, *C. krusei*, and *C. tropicalis* being the most commonly described.<sup>4</sup> The emergence of non-*albicans* species is significant, because they are frequently resistant to commonly used antifungal agents.<sup>5,6</sup>

Treatment of DS includes good oral hygiene, denture cleaning procedures, topical or systemic antifungal agents, discontinuation of nocturnal denture wearing habit, and eventually denture replacement.<sup>7,8</sup> Although antifungal agents, such as nystatin and fluconazole, commonly used to treat DS are effective in alleviating the clinical signs and symptoms of *Candida* infection, the recurrence of infection after treatment has frequently been reported.<sup>9,10</sup> Moreover, the widespread use of antifungal agents has resulted in the development of resistant species.<sup>11,12</sup>

Therefore, it is necessary to develop alternative therapies for treating DS. One potential alternative is photodynamic therapy (PDT), which combines a photosensitizing agent and an appropriate wavelength of light in the presence of oxygen producing cytotoxic reactive species.<sup>13,14</sup> Although several in vitro investigations have demonstrated the photoinactivation of *Candida* spp.,<sup>15-20</sup> including resistant strains,<sup>21</sup> in vivo studies

Supported by the São Paulo Council of Research (FAPESP; grant nos. 2005/02193-4 and 2005/03226-3).

<sup>a</sup>Assistant Professor, Dentistry School, São Francisco University.

<sup>b</sup>Adjunct Professor, Department of Dental Materials and Prosthodontics, Araraquara Dental School, UNESP-Univ Estadual Paulista.

<sup>c</sup>Professor of Prosthetic Dentistry, Camilo Castelo Branco University.

<sup>d</sup>Assistant Professor, Department of Dentistry, Ponta Grossa State University.

<sup>e</sup>Professor, Department of Dental Materials and Prosthodontics, Araraquara Dental School, UNESP-Univ Estadual Paulista.

<sup>f</sup>Professor, Physics Institute, University of São Paulo.

Received for publication Feb 1, 2011; returned for revision Apr 19, 2011; accepted for publication May 6, 2011.

1079-2104/\$ - see front matter

© 2011 Mosby, Inc. All rights reserved.

doi:10.1016/j.tripleo.2011.05.019




Fig. 1. LED device used to illuminate the dentures. **A**, Outside view, **B**, Inside view.

are scarce.<sup>22,23</sup> A previous study showed that PDT was effective in reducing *C. albicans* counts in a murine model of oral candidosis when a porphyrin was associated with light from a light-emitting diode (LED).<sup>24</sup> Nonetheless, the effect of PDT against DS is still not known. The present report describes 5 cases of DS treated with PDT for 15 days and follow-up of each patient at the time intervals of 30 and 60 days.

## SUBJECTS AND METHODS

Five edentulous denture-wearing patients with clinical signs of DS who attended the Araraquara Dental School for prosthetic treatment were followed. This study was approved by the Ethics Committee of the Araraquara Dental School, São Paulo State University, and each subject signed an informed consent form. The guidelines of the Helsinki Declaration were followed. DS was classified according to the criteria proposed by Newton.<sup>2</sup>

### Diagnosis of *Candida* infection and recovery of *Candida* spp.

For each patient, recovery of *Candida* spp. was performed by rubbing oral swabs along the palatal mucosa and the tissue surface of the upper denture. Each swab was placed into a test tube containing 5 mL 0.9% sterile saline solution and vortexed for 1 minute to suspend the organisms from the swab. An aliquot of 50  $\mu$ L from this suspension was spread plated on Chromagar Candida (Probac do Brasil Produtos Bacteriológicos, São Paulo, Brazil) and incubated at 30°C for 5 days. Serial 10-fold dilutions from 10<sup>0</sup> to 10<sup>-3</sup> were plated onto Sabouraud Dextrose Agar (SDA; Acumedia Manufactures, Baltimore, MD) with 5  $\mu$ g/mL chloramphenicol. SDA plates were incubated at 37°C for 48 hours. Colonies on SDA were quantified using a digital colony counter (CP 600 Plus; Phoenix Ind. Com. Equipamen-

tos Científicos, Araraquara, Brazil) and the number of colony-forming units per milliliter (cfu/mL) determined. Swabs were collected before treatment (day 0), at the end of the treatment (day 15), and at the follow-up time intervals of days 30 and 60). Colonies on Chromagar Candida were presumptively identified by colony color and submitted to biochemical tests to confirm all identifications. For this, 1 colony of each color type on Chromagar Candida was transferred onto fresh SDA for purity. After 48 hours at 37°C, yeast isolates were identified using the following biochemical tests: carbohydrate assimilation pattern using the ID32C system (Biomérieux, Marcy-L'etoile, France) and morphologic characteristics produced on corn meal agar with Tween-80. Only colonies identified as *Candida* spp. were considered.

### Photosensitizer and light sources

The photosensitizer (PS) used in this study was a hematoporphyrin derivative produced in Moscow (Photogem; Photogem, Moscow, Russia). Solutions of 500 mg/L Photogem were prepared by dissolving the powder in sterile saline solution and were immediately kept in the dark until the moment before use (pH 6.6).

Two LED devices (LXHL-PR09 and Luxeon III Emitter; Lumileds Lighting, San Jose, CA) were designed by the Instituto de Física de São Carlos (Physics Institute, University of São Paulo, São Carlos, Brazil). They covered the wavelength range from 440 to 460 nm, with maximum emission at 455 nm (royal blue). One device, used to illuminate the dentures, was composed of 24 LEDs uniformly distributed throughout the device, resulting in a light intensity of 24 mW/cm<sup>2</sup>, and 3 air coolers to prevent the denture from heating (Fig. 1). The other device, designed to irradiate the patients' palates, was composed of 10 LEDs uniformly distributed on a circular platform with a power output of 260




Fig. 2. LED device used to illuminate the patients' palates. **A**, Top view (*L*, LEDs; *P*, Peltier chip; *AC*, air coolers). **B**, Lateral view.

mW (Fig. 2). The intensity of light delivered was  $102 \text{ mW/cm}^2$ , with a distance of 2 cm from the platform inside the mouth to the deepest area of the palate. Joined to this platform, a semiconducting chip known as Peltier was used to dissipate the heat generated by the LED light. This chip and an air cooler were used to prevent the device from heating (Fig. 2). For illumination, the platform remained in the patient's mouth with the LED facing toward the palate.

### PDT and clinical procedures

Each subject was instructed to brush their dentures with coconut soap followed by toothpaste after every meal and before going to sleep. Each patient received a toothbrush at the beginning of the treatment. They also received instructions to immerse the dentures in filtered water overnight. During the 15-day duration of the treatment and follow-up period (days 30 and 60) time intervals, each subject was repeatedly given these instructions. Every patient had his/her maxillary denture and palate individually submitted to PDT. The denture was sprayed with PS, placed in a transparent plastic bag, and left in the dark for 30 minutes (preirradiation time [PIT]). For illumination, the denture was placed inside the LED device and irradiated for 26 minutes ( $37.5 \text{ J/cm}^2$ ). The palate was also sprayed with PS and illuminated after 30 minutes' PIT. For palate irradiation, the other LED device was handled by the investigator: The platform with LEDs was placed in the patient's mouth and the palate illuminated for 20 minutes ( $122 \text{ J/cm}^2$ ). PDT was performed 3 times a week for 15 days (6 sessions) in each patient. To document the clinical response to the treatment, standard photographs of the palate of all patients were taken before

treatment (day 0), at the end of the treatment (day 15), and at the follow-up time intervals (30 and 60 days).

### RESULTS

The cfu/mL values recovered from dentures and palate of each subject before (day 0) and after (day 15) treatment and at the follow-up time intervals (days 30 and 60) are presented in Table I. During clinical sessions, no patients complained of discomfort, pain or other symptoms. Only subjects who attended all sessions were considered in this survey. Species of *Candida* identified during these periods are described in Table II.

#### Patient 1

This patient, a 65-year-old European woman, was a nonsmoker and had taken antihypertensive, diuretic, and antiinflammatory medications. She had worn her denture for 6 years continuously, without removing it for sleeping. Her palate showed DS type II on day 0, and after PDT sessions (day 15) clinical resolution of DS (no inflammation) was achieved. On days 30 and 60 after treatment (follow-up period), DS was classified as 0 (healthy mucosa) and I, respectively.

#### Patient 2

This patient, a 56-year-old European woman, was a smoker and had used antihypertensive medication. She had worn her denture for 11 years, without removing it for sleeping. On day 0, DS was classified as type II, and after treatment (day 15) petechiae were still present in the palatal mucosa (type I). At the follow-up period

**Table I.** CfU/mL values of *Candida* spp. recovered from dentures and palate of each patient before (day 0) and after (day 15) treatment and at follow-up time intervals (days 30 and 60)

	Day 0	Day 15	Day 30	Day 60
<i>Patient 1</i>				
D	$5.24 \times 10^4$	$4.72 \times 10^3$	$1.28 \times 10^4$	$5.60 \times 10^4$
P	$4 \times 10$	0	0	0
<i>Patient 2</i>				
D	$4.64 \times 10^3$	$1.4 \times 10^3$	$2.00 \times 10^4$	$5.04 \times 10^3$
P	$4 \times 10$	0	$4 \times 10$	0
<i>Patient 3</i>				
D	$1.15 \times 10^5$	$1.72 \times 10^4$	$8.16 \times 10^4$	$1.12 \times 10^4$
P	$1.2 \times 10^2$	0	$4 \times 10$	$8 \times 10$
<i>Patient 4</i>				
D	$7.6 \times 10^4$	$8 \times 10$	$3.4 \times 10^5$	$3.28 \times 10^5$
P	$4 \times 10$	0	$2.68 \times 10^3$	$2.00 \times 10^2$
<i>Patient 5</i>				
D	$7.68 \times 10^4$	0	$4.08 \times 10^5$	0
P	$4 \times 10$	0	0	0

D, Denture; P, palate.

**Table II.** Species of *Candida* identified from denture and palate of each patient before (day 0) and after (day 15) treatment and at follow-up time intervals (days 30 and 60)

	Day 0	Day 15	Day 30	Day 60
Patient 1	<i>C. albicans</i>	<i>C. albicans</i>	<i>C. albicans</i>	<i>C. albicans</i>
Patient 2	<i>C. albicans</i>	<i>C. albicans</i>	<i>C. albicans</i>	<i>C. albicans</i>
Patient 3	<i>C. albicans</i>	<i>C. albicans</i>	<i>C. albicans</i>	<i>C. albicans</i>
	<i>C. glabrata</i>	<i>C. glabrata</i>		<i>C. glabrata</i>
Patient 4	<i>C. albicans</i>	<i>C. albicans</i>	<i>C. albicans</i>	<i>C. albicans</i>
	<i>C. glabrata</i>		<i>C. glabrata</i>	<i>C. glabrata</i>
	<i>C. tropicalis</i>			
Patient 5	<i>C. albicans</i>	—	<i>C. albicans</i>	—

time interval, recurrence of the initial inflammation was verified, and DS was classified as type I and II on days 30 and 60, respectively.

**Patient 3**

This patient, an 80-year-old European man, was a nonsmoker and had taken anticoagulant, diuretic, and digitalis medications. He had worn his denture for 2 years continuously, and DS was classified as type II on day 0. After PDT sessions (day 15), clinical resolution of inflammation was observed. However, at the follow-up time interval, recurrence of DS was noted (type I and II on days 30 and 60, respectively; Fig. 3).

**Patient 4**

This patient, a 57-year-old European woman, was a nonsmoker and had used antihypertensive medication.

She had worn her denture for 15 years continuously. On her palate, DS type II was observed on day 0. After treatment (day 15) and at the follow-up time intervals (days 30 and 60), clinical resolution of palatal inflammation had been achieved.

**Patient 5**

This patient, a 67-year-old European man, was a nonsmoker and had taken antihypertensive and anticoagulant medications. He had worn his denture for 7 years, and on day 0 DS was classified as type II. On day 15 after treatment and at the follow-up time intervals (days 30 and 60), clinical resolution of palatal inflammation was observed.

**DISCUSSION**

Dentures produce ecologic changes in the oral mucosa that facilitate the proliferation and the colonization of microorganisms, especially yeast. Therefore, DS is a common lesion in denture wearers. Because frequent recurrence of infection<sup>25,26</sup> and the development of antifungal resistance<sup>11,12</sup> caused by antifungal agents have been observed, alternative therapies for DS are required. PDT is an effective method for *Candida* inactivation in vitro and in vivo,<sup>13-24</sup> but no clinical trial has as yet been carried out with regard to oral *Candida* infection. The present report describes 5 DS patients treated with PDT and the follow-up of each subject. Cultures of denture and palate of all subjects were positive for *Candida* species before the treatment. Moreover, all patients showed DS type II at baseline (day 0) and improvement of the palatal inflammation at the end of the treatment period (day 15). Most patients showed clinical resolution of DS after PDT sessions, and only 1 subject (patient 2) demonstrated a reduction in the palatal inflammation. Concurrently, reduction of cfu/mL values were also observed after treatment (day 15) compared with baseline (day 0). The encouraging data observed in these 5 patients suggest that PDT may be an alternative treatment for DS. Compared with antifungal agents, PDT appears to be a promising method of treatment. The production of free radicals and other reactive oxygen species, such as singlet oxygen, by PDT leads to cellular damage, membrane lysis, and protein inactivation.<sup>13,14</sup> Notably, the mechanism of PDT inactivation of fungi is completely different from that of antifungal agents. Although most antifungal agents inhibit the biosynthesis of ergosterol, the main sterol in the membranes of fungi,<sup>27</sup> the reactive oxygen species yielded by PDT promote perforation of the cell wall and membrane, thereby permitting the PS to translocate into the cell. Once inside the cell, oxidizing species generated by light excitation induce photodamage



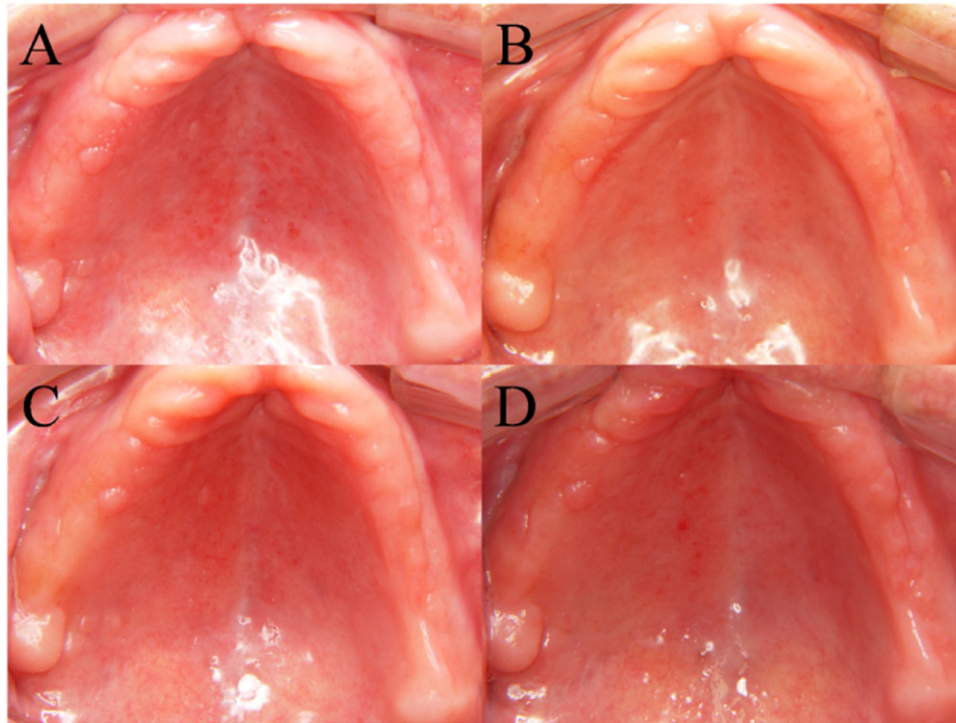


Fig. 3. Palate of patient 3. **A**, denture stomatitis (DS) type II (day 0); **B**, no inflammation (day 15); **C**, DS type I (follow-up, day 30); **D**, DS type II (follow-up, day 60).

to internal cell organelles and cell death.<sup>14,15</sup> Therefore, development of resistance to PDT seems to be unlikely.

In addition to the PDT sessions performed, patients' compliance with the denture and oral care instructions they were given may have contributed to achieving improvement of DS. Although denture and oral hygiene alone are not sufficient to treat DS,<sup>26,28,29</sup> these procedures are essential to maintain a low level of microorganisms on dentures. In addition, application of the intraoral light may affect patient compliance with the treatment. Furthermore, in patient 2, the poorer response to the treatment could be attributed to smoking, which is considered to be a risk factor for DS.<sup>30,31</sup>

During the follow-up period, patients 4 and 5 showed the best response to the treatment, with no inflammation verified until day 60. Subjects 2 and 3 developed recurrence of the initial inflammation (DS type II) on day 60. Recurrence of DS is often reported,<sup>9,25,32</sup> because the tissue surface of the acrylic resin denture acts as a reservoir that harbors microorganisms<sup>33,34</sup> and is therefore a potential source of reinfection of patients. In the present investigation, although no growth of *Candida* spp. from the palate was observed after treatment, most of the patients showed growth of *Candida* spp. from the denture on day 15 (Table I). When dentures are very old, the indication would be to provide new

dentures as adjunctive therapy for complete resolution of DS.<sup>7,35</sup> In the present report, most of the patients had worn the same denture for >5 years. Although the age of a denture is related to DS,<sup>31,36</sup> patient 3 had been wearing his denture for only 2 years. Therefore, other predisposing factors should be considered when treating DS.

Advancing age is also a risk factor for DS in the elderly, because cell-mediated immunity, which provides protection against candidal infection declines with age.<sup>37</sup> According to Ryu et al.,<sup>38</sup> some oral environmental factors, such as unstimulated salivary flow rate and age of subjects, are associated with higher numbers of microbes in the saliva of complete denture wearers. Those authors suggest that a reduction in the salivary flow rate with aging induces an increase in concentration of microbes in saliva. Another predisposing factor associated with DS is medication use. Four patients were taking antihypertensive medications which induce xerostomia. Therefore, although an improvement in palatal inflammation was verified after the treatment (day 15), the recurrence that occurred during the follow-up period may be associated with these predisposing factors to DS. Because DS is a multifactorial disease, a suitable treatment should con-

sider all of the host factors that predispose to *Candida* infection.

In the present report, although improvement of palatal inflammation and reduction of cfu/mL values were verified after PDT, *Candida* spp. were recovered after treatment in most of the patients (Table II). This was an expected finding, because *Candida* spp. are normally isolated from oral mucosa, mainly from dentures, even in denture wearers without DS.<sup>39</sup>

In summary, in 4 patients, clinical resolution of DS was achieved after 6 sessions of PDT, and improvement was observed in 1 patient. These data suggest that PDT may be an alternative treatment for DS. However, because only type II DS patients were followed in this investigation, it is uncertain what treatment response might be seen in more severe cases. As an alternative treatment approach, 6 sessions of 20 minutes each for palatal PDT may be not clinically feasible. Nevertheless, this is a preliminary clinical study, and improvements of the PDT parameters are necessary for further investigations aiming at clinical applications. Moreover, recurrence of DS occurred in 3 of the 5 cases by 30 days, indicating a short-term effect of the therapy. Longer treatment or other therapeutic regimens (for example, treatment every 2 weeks) could be assessed in future investigations. Other types and concentrations of PS and light source could also be evaluated to achieve complete inactivation of *Candida* spp. in vivo and to properly implement such therapy in the context of a dental setting.

As other limitations of this study, only 5 cases were followed, and the majority of them (3 of 5) showed recurrence of DS. Furthermore, investigators were not blinded to the therapy, no control treatment was provided, and there were no objective criteria to discriminate case resolution, improvement, and regression (only clinical observation of palatal inflammation). Randomized clinical trials that overcome these limitations should be conducted to evaluate the potential of PDT in inactivating *Candida* spp. on dentures and the oral mucosa, as well as the correlation between clinical and microbiological data.

## REFERENCES

- Jeganathan S, Lin CC. Denture stomatitis—a review of the aetiology, diagnosis and management. *Aust Dent J* 1992;37:107-14.
- Newton AV. Denture sore mouth as possible etiology. *Br Dent J* 1962;112:357-60.
- Theilade E, Budtz-Jorgensen E. Predominant cultivable microflora of plaque on removable dentures in patients with denture induced stomatitis. *Oral Microbiol Immunol* 1988;3:8-13.
- Lyon JP, da Costa SC, Totti VM, Munhoz MF, de Resende MA. Predisposing conditions for *Candida* spp. carriage in the oral cavity of denture wearers and individuals with natural teeth. *Can J Microbiol* 2006;52:462-7.
- Li L, Redding S, Dongari-Bagtzoglou A. *Candida glabrata*: an emerging oral opportunistic pathogen. *J Dent Res* 2007;86:204-15.
- Redding SW, Kirkpatrick WR, Saville S, Coco BJ, White W, Fothergill A, et al. Multiple patterns of resistance to fluconazole in *Candida glabrata* isolates from a patient with oropharyngeal candidiasis receiving head and neck radiation. *J Clin Microbiol* 2003;41:619-22.
- Pires FR, Santos EB, Bonan PR, de Almeida OP, Lopes MA. Denture stomatitis and salivary *Candida* in Brazilian edentulous patients. *J Oral Rehabil* 2002;29:1115-9.
- Webb BC, Thomas CJ, Willcox MD, Harty DW, Knox KW. *Candida*-associated denture stomatitis. Aetiology and management: a review. Part 3. Treatment of oral candidosis. *Aust Dent J* 1998;43:244-9.
- Bergendal T. Status and treatment of denture stomatitis patients: a 1-year follow-up study. *Scand J Dent Res* 1982;90:227-38.
- Mathaba LT, Davies G, Warmington JR. The genotypic relationship of *Candida albicans* strains isolated from the oral cavity of patients with denture stomatitis. *J Med Microbiol* 1995;42:372-9.
- Johnson EM, Warnock DW, Luker J, Porter SR, Scully C. Emergence of azole drug resistance in *Candida* species from HIV-infected patients receiving prolonged fluconazole therapy for oral candidosis. *J Antimicrob Chemother* 1995;35:103-14.
- Rex JH, Rinaldi MG, Pfaller MA. Resistance of *Candida* species to fluconazole. *Antimicrob Agents Chemother* 1995;39:1-8.
- Konopka K, Goslinski T. Photodynamic therapy in dentistry. *J Dent Res* 2007;86:694-707.
- Donnelly RF, McCarron PA, Tunney MM. Antifungal photodynamic therapy. *Microbiol Res* 2008;163:1-12.
- Bertoloni G, Reddi E, Gatta M, Burlini C, Jori G. Factors influencing the hematoporphyrin-sensitized photoinactivation of *Candida albicans*. *J Gen Microbiol* 1989;135:957-66.
- Bliss JM, Bigelow CE, Foster TH, Haidaris C. Susceptibility of *Candida* species to photodynamic effects of Photofrin. *Antimicrob Agents Chemother* 2004;48:2000-6.
- Chabrier-Roselló Y, Foster TH, Pérez-Nazarío N, Mitra S, Haidaris CG. Sensitivity of *Candida albicans* germ tubes and biofilms to Photofrin-mediated phototoxicity. *Antimicrob Agents Chemother* 2005;49:4288-95.
- Demidova TN, Hamblin MR. Effect of cell-photosensitizer binding and cell density on microbial photoinactivation. *Antimicrob Agents Chemother* 2005;49:2329-35.
- Lambrechts SA, Aalders MC, van Marle J. Mechanistic study of the photodynamic inactivation of *Candida albicans* by a cationic porphyrin. *Antimicrob Agents Chemother* 2005;49:2026-34.
- Donnelly RF, McCarron PA, Tunney MM, David-Woolfson A. Potential of photodynamic therapy in treatment of fungal infections of the mouth. Design and characterisation of a mucoadhesive patch containing toluidine blue O. *J Photochem Photobiol B Biol* 2007;86:59-69.
- Dovigo LN, Pavarina AC, Mima EG, Giampaolo ET, Vergani CE, Bagnato VS. Fungicidal effect of photodynamic therapy against fluconazole-resistant *Candida albicans* and *Candida glabrata*. *Mycoses* 2011;54:123-30.
- Teichert MC, Jones JW, Usacheva MN, Biel MA. Treatment of oral candidiasis with methylene blue-mediated photodynamic therapy in an immunodeficient murine model. *Oral Surg Oral Med Oral Pathol Oral Radiol Endod* 2002;93:155-60.
- Martins J, da S, Junqueira JC, Faria RL, Santiago NF, Rossoni RD, et al. Antimicrobial photodynamic therapy in rat experimental candidiasis: evaluation of pathogenicity factors of *Candida albicans*. *Oral Surg Oral Med Oral Pathol Oral Radiol Endod* 2011;111:71-7.
- Mima EG, Pavarina AC, Dovigo LN, Vergani CE, Costa CA, Kurachi C, et al. Susceptibility of *Candida albicans* to photody-

- dynamic therapy in a murine model of oral candidosis. *Oral Surg Oral Med Oral Pathol Oral Radiol Endod* 2010;109:392-401.
25. Kulak Y, Arikian A, Delibalta N. Comparison of three different treatment methods for generalized denture stomatitis. *J Prosthet Dent* 1994;72:283-8.
  26. Neppelenbroek KH, Pavarina AC, Palomari-Spolidorio DM, Sgavioli-Massucato EM, Spolidorio LC, Vergani CE. Effectiveness of microwave disinfection of complete dentures on the treatment of *Candida*-related denture stomatitis. *J Oral Rehabil* 2008;35:836-46.
  27. Borgers M. Mechanism of action of antifungal drugs, with special reference to the imidazole derivatives. *Rev Infect Dis* 1980;2:520-34.
  28. Cross LJ, Bagg J, Aitchison TC. Efficacy of the cyclodextrin liquid preparation of itraconazole in treatment of denture stomatitis: comparison with itraconazole capsules. *Antimicrob Agents Chemother* 2000;44:425-7.
  29. Barnabé W, de Mendonça-Neto T, Pimenta FC, Pegoraro LF, Scolaro JM. Efficacy of sodium hypochlorite and coconut soap used as disinfecting agents in the reduction of denture stomatitis, *Streptococcus mutans* and *Candida albicans*. *J Oral Rehabil* 2004;31:453-9.
  30. Barbeau J, Séguin J, Goulet JP, de Koninck L, Avon SL, Lalonde B, et al. Reassessing the presence of *Candida albicans* in denture-related stomatitis. *Oral Surg Oral Med Oral Pathol Oral Radiol Endod* 2003;95:51-9.
  31. Freitas JB, Gomez RS, de Abreu MH, Ferreira E, Ferreira E. Relationship between the use of full dentures and mucosal alterations among elderly Brazilians. *J Oral Rehabil* 2008;35:370-4.
  32. Banting DW, Greenhorn, PA, McMinn JG. Effectiveness of a topical antifungal regimen for the treatment of oral candidiasis in older, chronically ill, institutionalized, adults. *J Can Dent Assoc* 1995;61:199-200,203-5.
  33. Budtz-Jorgensen E. Etiology, pathogenesis, therapy, and prophylaxis of oral yeast infections. *Acta Odontol Scand* 1990;48:61-9.
  34. Davenport JC. The denture surface. *Br Dent J* 1972;133:101-5.
  35. Cross LJ, Riggio MP, Bagg J. Genetic typing of *Candida albicans* strains isolated from the oral cavity of patients with denture stomatitis before and after itraconazole therapy. *Microb Ecol Health Dis* 1999;11:35-40.
  36. Coelho CM, Sousa YT, Daré AM. Denture-related oral mucosal lesions in a Brazilian school of dentistry. *J Oral Rehabil* 2004;31:135-9.
  37. Tockman MS. Aging of defense mechanisms. In: Hazard RW, Andres R, Bierman EL, Blass JP, editors. *Principles of geriatric medicine and gerontology*. New York: McGraw-Hill; 1990. p. 449-511.
  38. Ryu M, Ueda T, Saito T, Yasui M, Ishihara K, Sakurai K. Oral environmental factors affecting number of microbes in saliva of complete denture wearers. *J Oral Rehabil* 2010;37:194-201.
  39. vanden Abbeele A, de Meel H, Ahariz M, Perraudin JP, Beyer I, Courtois P. Denture contamination by yeasts in the elderly. *Gerodontology* 2008;25:222-8.
- Reprint requests:*
- Dr. Ana Cláudia Pavarina  
 Faculdade de Odontologia de Araraquara – UNESP  
 R. Humaitá n° 1680  
 Araraquara – São Paulo – Brasil  
 CEP 14801-903  
[pavarina@foar.unesp.br](mailto:pavarina@foar.unesp.br)