

Clinical Paper
Pre-Implant Surgery

Comparative study of volumetric changes and trabecular microarchitecture in human maxillary sinus bone augmentation with bioactive glass and autogenous bone graft: a prospective and randomized assessment

R. S. Pereira, J. D. Menezes,
J. P. Bonardi, G. L. Griza,
R. Okamoto, E. Hochuli-Vieira
Araçatuba Dental School, Universidade
Estadual Paulista – UNESP, Araçatuba, São
Paulo, Brazil

R. S. Pereira, J. D. Menezes, J. P. Bonardi, G. L. Griza, R. Okamoto, E. Hochuli-Vieira: Comparative study of volumetric changes and trabecular microarchitecture in human maxillary sinus bone augmentation with bioactive glass and autogenous bone graft: a prospective and randomized assessment. *Int. J. Oral Maxillofac. Surg.* 2018; 47: 665–671. © 2017 International Association of Oral and Maxillofacial Surgeons. Published by Elsevier Ltd. All rights reserved.

Abstract. The aim of this study was to compare the volumetric changes and the new bone microarchitecture in human maxillary sinuses augmented with bioactive glass (Biogran) alone, bioactive glass combined with autogenous bone graft (1:1), or autogenous bone graft alone. Twelve maxillary sinuses were grafted with bioactive glass (group 1), nine with bioactive glass mixed with autogenous bone graft 1:1 (group 2), and 12 with autogenous bone graft (group 3). Patients underwent cone beam computed tomography 15 days after the procedure to determine the initial volume of the graft (T1) and again 6 months later (T2). Biopsies were obtained at the time of dental implant placement and were subjected to micro-computed tomography. The volumetric change was 44.2% in group 1, 37.9% in group 2, and 45.7% in group 3 ($P > 0.05$). The trabecular microarchitecture results showed that the materials used in groups 1 and 2 were good bone substitutes. However, the addition of 50% bioactive glass to autogenous bone graft improved the microarchitecture of the graft. Furthermore, the results for volumetric changes indicated that bioactive glass, its association with autogenous bone graft in a 1:1 ratio, and autogenous bone graft alone have similar resorption.

Key words: maxillary sinus augmentation; bioactive glass; bioactive glass added to autogenous bone graft; bone graft resorption; trabecular bone microarchitecture.

Accepted for publication 29 November 2017
Available online 13 December 2017

The aim of maxillary sinus augmentation is to restore the ideal bone height, enabling dental implant placement¹. Some studies have proposed the use of bone substitutes to contribute to the maintenance of bone volume and new bone formation in the maxillary sinus²⁻⁷. The autogenous bone graft is still the most predictable and favourable for bone grafting because of its osteogenic, osteoinductive, and osteoconductive properties^{8,9}. However, the use of this graft implies the need for another surgical site, which can increase morbidity for the patient; therefore, it should be chosen for specific cases^{10,11}.

Other bone substitutes have been used to augment the maxillary sinus height, including allogeneic grafts, alloplastic grafts, and combinations of these with autogenous bone grafts^{1,12}. The ideal bone substitute has to work as a template for bone formation in three dimensions and should have certain properties: be biocompatible, promote osteogenic cell attachment, bond to the host bone without intermediary fibrous tissue, have an interconnected porous structure, be degradable, share the mechanical load with the host bone, and be sterilizable¹³. Furthermore, it is important that the new bone formed is strong enough to anchor the dental implants and support the masticatory forces¹⁴.

One of these biomaterials is bioactive glass, a bioactive ceramic with osteoconductive properties that was developed by Professor Larry Hench in 1969 and approved by the United States Food and Drug Administration in 1996. It has all of the necessary characteristics except porosity^{13,15}. A commercial form of this material is Biogran (Biomet 3i, Palm Beach Gardens, Florida, USA), a resorbable bioactive ceramic of 300–355 µm particle size and composed of silicon dioxide (SiO₂; 45%), calcium oxide (CaO; 24.5%), sodium oxide (NaO₂; 24.5%), and phosphorous pentoxide (P₂O₅; 6%)^{16,17}.

It is important to evaluate the dimensional changes in bone grafts placed in the maxillary sinus, because shrinkage occurs during graft healing. Studies analysing bone graft remodelling after sinus floor augmentation with simultaneous implant placement have been performed previously¹⁸⁻²⁰. However, when it is not possible to install the dental implants simultaneously, cone beam computed tomography (CBCT) represents the best method for evaluating volumetric bone changes²¹. This examination offers three-dimensional (3D) visualization, allowing real volumetric measurements

to be obtained during the bone healing phase²².

The new bone formation in the maxillary sinus can be analysed using histological measurements obtained from two-dimensional (2D) sections²³. Nevertheless, the 3D assessment of bone biopsies can also provide information on the trabecular bone structure and its microarchitecture²⁴. One means of analysing these parameters is micro-computed tomography (micro-CT), which is considered the 'gold standard' method because it is non-destructive and provides high-resolution images of the bone structure²⁵.

The aim of this study was to evaluate bioactive glass (Biogran) used alone or in combination with autogenous bone graft in a 1:1 ratio, compared to autogenous bone graft alone in maxillary sinus augmentation. The analyses were conducted through the assessment of volumetric bone changes on CBCT evaluation and the trabecular bone microarchitecture on micro-CT evaluation.

The study hypotheses were: (1) H0 (null hypothesis), that bioactive glass will show less resorption than autogenous bone graft; (2) H1 (alternative hypothesis 1), that the addition of 50% of autogenous bone graft to bioactive glass will improve the trabecular bone microarchitecture.

Materials and methods

Patients with an edentulous posterior maxilla were invited to participate in this study. The number of samples required in each group was determined by statistical power test, performed at the website <http://www.lee.dante.br> and based on the results of a previous study²⁶. The difference in the average to be detected was 11.9%, with a standard deviation of 9.57, at the significance level of 5% and with 80% power in a one-tailed hypothesis test.

The inclusion criteria encompassed patients with a maxillary sinus bone height (pristine bone) of less than 5 mm, who required bone grafting to allow dental implant placement. Patients were excluded if they presented any uncontrolled systemic diseases, periodontitis, any pathologies in the maxillary sinus, were smokers, or had received radiation treatment to the face, head, or neck.

CBCT scans were performed to evaluate all maxillary sinuses prior to treatment. The autogenous bone grafts were harvested from the mandibular symphysis or retromolar region. Anatomical structures next to these areas, such as tooth

roots and the mandibular canal, were identified on CBCT scans.

Twenty-nine patients (35 maxillary sinuses) met the eligibility criteria and were invited to participate in this research. These patients were divided into three groups: group 1 comprised 11 patients (13 maxillary sinuses) grafted with bioactive glass alone (Biogran); group 2 comprised eight patients (10 maxillary sinuses) grafted with bioactive glass mixed with autogenous bone graft in a 1:1 ratio; group 3 comprised 10 patients (12 maxillary sinuses) grafted with autogenous bone graft alone (control group). There was no association between the side of the maxillary sinus and the grafting material used. Randomization was performed by drawing lots to decide which sites would be grafted with each material. This was done by a clinical assistant, who was not involved in the surgeries or in the data evaluation.

Surgical procedures

This prospective study was approved by the institutional ethics committee and was performed at Araçatuba Dental School from March 2014 to July 2016. The autogenous bone block grafts were harvested under local anaesthesia (lidocaine 2% with epinephrine 1:100,000; DFL, Taquara, RJ, Brazil) and milled with a bone crusher (Neodent, Curitiba, PR, Brazil), as recommended by Pereira et al.²⁷. The maxillary sinus bone augmentation was performed in accordance with the surgical procedure of Boyne and James²⁸. Postoperatively, 500 mg of amoxicillin (EMS, São Paulo, SP, Brazil) three times per day was prescribed to reduce the chance of infection, as well as 500 mg paracetamol (EMS, São Paulo, SP, Brazil) four times per day for the management of pain. One patient in group 2 presented a maxillary sinus infection and was excluded from the study, and one patient in group 1 did not return for follow-up; thus, the final analysis included 12 maxillary sinuses for group 1, nine for group 2, and 12 for group 3.

Evaluation of the volumetric change

CBCT scans were obtained to determine the bone graft volume. The first scan was performed 15 days after the maxillary bone augmentation procedure, determining the initial volume (T1). The second scan was performed 6 months after the procedure (after 6 months of bone graft healing), determining the final volume

(T2). This second scan was done during the planning for dental implant placement. The CBCT images were acquired using an i-CAT Classic CBCT unit (i-Cat; Image Sciences International, Hatfield, PA, USA), with settings of 120 kVp, 5 mA, and 20 s exposure. DICOM datasets were reconstructed using OsiriX software version 4.1.2, 32-bit (OsiriX Foundation, Geneva, Switzerland), with the image orientation and generation standardized as reported by Spin-Neto et al.²⁶.

Altogether, 54 examinations were accomplished and analysed: 27 in the early postoperative period (T1) and 27 in the late postoperative period (T2). Four hundred and eighty-nine slices were generated in the early postoperative period (T1) and 400 slices in the late postoperative period (T2). Standardization of the reduction in the distance between the slices, the slice thickness, and the adjustment of the contrast, exposure, and contour of the structures were performed according to Gorla et al.²⁹, by a single researcher who had been trained in advance for this work. TIFF images (tagged image file format) were generated for each section of the CBCTs. The graft volume was calculated from the sum of all areas multiplied by the height, which was equivalent to the distance between the sagittal slices, and expressed in cubic millimetres (mm³). The resorption rate was calculated using the formula T1 – T2 and expressed as a percentage.

Micro-computed tomography evaluation

Biopsies were collected after 6 months of bone healing at the time of dental implant placement. The samples were harvested using a surgical guide and a 3.0 × 15 mm trephine bur (MK Life, Porto Alegre, RS, Brazil). They were then stored in a 10% formalin solution (pH 7) for 24 h, maintaining the apical orientation. After this, the samples were washed in running water for another 24 h and stored in 70% alcohol.

Specimens were subjected to micro-CT scanning (SkyScan; Bruker microCT, Kontich, Belgium) in a horizontal position, maintaining the apico-coronal orientation; they were attached to the device tubes and sliced in 8.74-µm thick sections at an X-ray energy of 50 kV and 500 µA current. Images were captured with a camera with 12.45-µm pixel size, with a row count of 2672 and a column count of 4000. The rotation step was 0.5 with a 180° rotation and a frame average of 3. The filter used was aluminium (0.5 mm), in a

moist medium, and the average scan duration was 41 min.

After these steps, the images were reconstructed using NRecon software v1.6.9.8 (Bruker microCT) with a smoothing of 1, a ring artefact correction of 3, a beam hardening correction of 5%, and an image correction variation from 0.0 to 0.11. The 3D and reconstructed images were analysed using CT-analyser software (CTAn) v1.12.4.0 (Bruker microCT). The images were opened, placed in the axial position, and 100 slices of the apical region of the samples were selected using the region of interest (ROI) tool and a circular ('round') format, with a size of 2.85 × 2.85 mm. The pristine bone was considered the most cortical bone of the sample according to the bone height determined by CBCT. The area selected had to include only the bone graft in the entire circumference and exclude the pristine bone region. Broken samples were not included in the analysis. Using the 'binary selection preview' tool, the histogram was standardized at 255% with an index of 70. After this, the 'morphometry preview' tool was used to analyse the 3D data (3D analysis) of the trabecular bone, defining the bone volume fraction (BV/TV), trabecular thickness (Tb.Th), trabecular number (Tb.N), and trabecular separation (Tb.Sp), as reported previously by Boussein et al.³⁰. All of these analyses and the data collection were performed by a single researcher trained in advance for this work.

Statistical analysis

The Shapiro–Wilk test was used to determine whether the samples had a normal distribution. Comparisons between groups were done by analysis of variance (ANOVA) followed by Tukey's multiple

comparison test (SigmaPlot 12.3; Systat Software Inc., San José, CA, USA). The relationship between volume changes in the augmented bone and the time elapsed was evaluated using Pearson's correlation coefficient. An a priori *P*-value of <0.05 was used for all tests.

Results

Results of the evaluation of volumetric change

All volumes were calculated in cubic millimetres. In group 1, the resorption rate ranged from 15.6% to 75.4%, with a mean rate of 44.0 ± 16.0% (Table 1). The resorption rate in group 2 ranged from 32.4% to 63.0%; however there was an augmentation of 5.8% in the bone volume in one case. The mean resorption rate in group 2 was 37.9 ± 18.9% (Table 2). Group 3 presented resorption rates ranging from 3.3% to 73.6% and a mean rate of 45.7 ± 18.5% (Table 3) (Fig. 1). There was no statistically significant difference between the groups regarding the resorption rate (all *P* > 0.05). The correlation between the periods evaluated was *r* = 0.81 for group 1, *r* = 0.88 for group 2, and *r* = 0.88 for group 3. This strong correlation indicates that the bone graft resorption was progressive during the healing period. With these results, the hypothesis H0 was accepted.

Results of the micro-computed tomography evaluation

The average remaining pristine bone was 3.0 ± 0.6 mm in group 1, 1.8 ± 0.9 mm in group 2, and 1.2 ± 0.4 mm in group 3. The bone volume fraction (BV/TV) was 52.06% in group 1, 57.04% in group 2, and 57.19% in group 3 (*P* > 0.05). The trabecular thickness (Tb.Th) was 0.14 mm

Table 1. Bone graft volume after 15 days of maxillary sinus augmentation (T1), after 6 months (T2) and the resorption rate of group 1.

Maxillary sinus	T1 (mm ³)	T2 (mm ³)	Difference (mm ³) ^a	Resorption (%) ^a
1L	1563.8	697	-866.8	-55.4
2L	1473	867.7	-605.3	-41.1
3L	1435.9	710	-725.9	-50.6
4R	394.6	333.1	-61.5	-15.6
4L	346.9	194.2	-152.7	-44
5R	483.4	249.6	-233.8	-48.4
5L	958.5	396.9	-561.6	-58.6
6R	727.9	545.5	-182.4	-25.1
7R	269.6	188.2	-81.4	-30.2
8R	1087.2	692.3	-394.9	-36.3
9L	1339.3	329.3	-1010	-75.4
10R	834.2	423.4	-410.8	-49.2
Mean ± SD	909.7 ± 472.0	469.2 ± 228.1	-440.8 ± 315.6	-44.0 ± 16.0

L, left; R, right; SD, standard deviation.

^aNegative values indicate volumetric bone graft loss.

Table 2. Bone graft volume in group 2 (maxillary sinuses grafted with bioactive glass mixed with autogenous bone graft 1:1) at 15 days (T1) and 6 months (T2) after maxillary sinus augmentation, and the resorption rate.

Maxillary sinus	T1 (mm ³)	T2 (mm ³)	Difference (mm ³) ^a	Resorption (%) ^a
11L	2204.9	1353.3	-851.6	-38.6
12R	951.1	581.0	-370.1	-38.9
12L	3539.4	1973.5	-1565.9	-44.2
13R	1358.2	877.4	-480.8	-35.4
14L	1586.3	1678.0	91.7	5.8
15R	1908.9	1290.5	-618.4	-32.4
16R	799.7	374.1	-425.6	-53.2
17R	1074.5	398.1	-676.4	-63.0
17L	897.4	529.1	-368.3	-41.0
Mean ± SD	1591.2 ± 874.0	1006.1 ± 589.7	-585.1 ± 451.3	-37.9 ± 18.9

L, left; R, right; SD, standard deviation.

^a Negative values indicate volumetric bone graft loss.

Table 3. Bone graft volume in group 3 (maxillary sinuses grafted with autogenous bone graft) at 15 days (T1) and 6 months (T2) after maxillary sinus augmentation, and the resorption rate.

Maxillary sinus	T1 (mm ³)	T2 (mm ³)	Difference (mm ³) ^a	Resorption (%) ^a
18R	367.7	280.3	-87.4	-23.8
19L	336.1	325.1	-11.0	-3.3
20R	1294.2	804.8	-489.4	-37.8
20L	1374.8	718.5	-656.3	-47.7
21L	1579.9	673.7	-906.2	-57.4
22R	1770.6	923.2	-847.4	-47.9
23R	1247.1	523.9	-723.2	-58.0
24R	1396.4	368.2	-1028.2	-73.6
25R	1103.1	507.1	-596.0	-54.0
25L	1115.1	626.3	-488.8	-43.8
26R	453.4	274.8	-178.6	-39.4
27L	816.1	313.7	-502.4	-61.6
Mean ± SD	1071.2 ± 477.8	528.3 ± 221.2	-542.9 ± 321.7	-45.7 ± 18.5

L, left; R, right; SD, standard deviation.

^a Negative values indicate volumetric bone graft loss.

in group 1, 0.19 mm in group 2, and 0.38 mm in group 3 ($P > 0.05$). The trabecular numbers (Tb.N) for the biomaterials evaluated were 2.70 1/mm, 2.86 1/mm, and 2.04 1/mm for groups 1, 2, and 3, respectively. Trabecular separation (Tb.Sp) was 0.13 mm in group 1, 0.18 mm in group 2, and 0.38 mm in group 3 (Table

4). Statistically significant differences in Tb.N were found between groups 1 and 3 ($P = 0.02$) and between groups 2 and 3 ($P = 0.01$); furthermore, a significant difference was also found between groups 1 and 3 for Tb.Sp ($P = 0.02$) (Fig. 2). Thus, hypothesis H1 was accepted.

Discussion

Bioactive glass is an osteoconductive biomaterial that has been used as a bone substitute for periodontal defects, alveolar filling, and in apical resections³¹⁻³⁶. However, few prospective clinical studies have demonstrated the behaviour of this material in maxillary sinus augmentation with a sufficiently large number of patients^{37,38}.

Reconstruction of the posterior maxilla was a challenge for oral surgeons during the first studies on dental implants³⁹. Although advances have been made in surgical procedures and the development of bone substitutes, the final result has to offer new bone formation and, in particular, sufficient volume to allow the placement of implants^{12,40}. Thus, studies evaluating the bone volume resorption and the new bone microarchitecture in maxillary sinus bone augmentation are required to determine the ideal amount of bone graft to be inserted.

Arasawa et al. demonstrated that the autogenous bone graft undergoes progressive resorption following maxillary sinus augmentation²¹. Although this material is the 'gold standard' for the restoration of bone defects, the occurrence of volumetric changes due to bone remodelling is con-

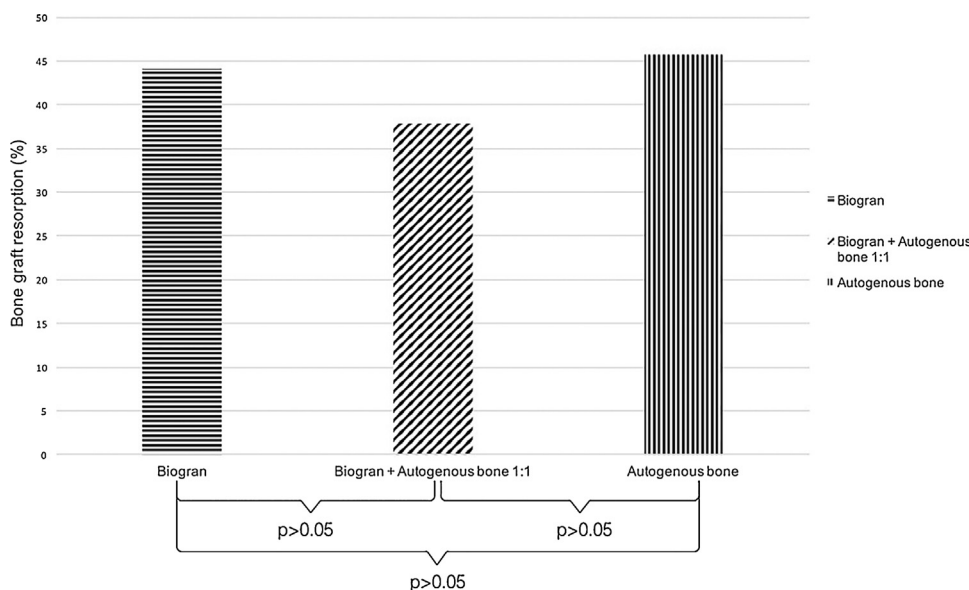


Fig. 1. Graph demonstrating the resorption rates of Biogran (bioactive glass), Biogran in combination with autogenous bone graft 1:1, and autogenous bone graft after 6 months of human maxillary sinus augmentation.

Table 4. Micro-computed tomography outcomes for the three bone substitutes used for maxillary bone augmentation evaluated after 6 months of bone graft healing^a.

Variables	Abbreviations (units)	Group 1	Group 2	Group 3
Bone volume fraction	BV/TV (%)	52.06 (A)	57.04 (A)	57.19 (A)
Trabecular thickness	Tb.Th (mm)	0.14 (A)	0.19 (A)	0.38 (A)
Trabecular number	Tb.N (1/mm)	2.70 (A)	2.86 (AB)	2.04 (C)
Trabecular separation	Tb.Sp (mm)	0.13 (A)	0.18 (AB)	0.38 (B)

^aNo statistically significant difference between data with the same letters in each row ($P > 0.05$).

siderable. Nevertheless, the use of non-resorbable biomaterials alone in these surgical procedures is questionable. Thus, some authors have proposed the combination of autogenous bone graft and synthetic biomaterials to improve the new bone formation and osseointegration, and to decrease bone shrinkage⁴⁰⁻⁴².

In a study by Cosso et al., hydroxyapatite added to autogenous bone graft in maxillary sinus lifting presented resorption of 25.8% compared to 42.3% for autogenous bone graft alone⁴⁰. This is due to the low resorption of hydroxyapatite⁴³. When demineralized bovine bone mineral was used alone for maxillary sinus lifting, Gultekin et al. found a lower

resorption rate of just 8.14%⁴⁴. Similar results were reported by Jensen et al., who demonstrated that the addition of Bio-Oss to autogenous bone graft in different proportions reduced the resorption of the grafted bone⁴⁵. Moreover, Lee et al. demonstrated a bone volume augmentation of 1.70 cm³ with the same biomaterial, confirming that this biomaterial maintains a reliable volume after the healing period⁴⁶.

In the present study, Biogran (bioactive glass) presented a similar resorption rate to autogenous bone graft in maxillary sinus augmentation. However, a combination of the two biomaterials in a 1:1 ratio demonstrated a lower rate of volumetric reduc-

tion; there was even a 5.8% bone augmentation in a single case. Similar results were found with the use of beta-tricalcium phosphate added to autogenous bone graft in a 1:1 ratio⁴⁷. Thus, these results demonstrate that bioactive glass alone, or in combination with autogenous bone graft 1:1, shows the same volumetric change behaviour as autogenous bone graft, making both options favourable bone substitutes.

The use of micro-CT to evaluate bone samples allows 3D morphological measurements and has a high correlation with 2D analysis, even though it is not possible to show the cells⁴⁸. As well as allowing the 3D assessment of trabecular bone morphology, it allows a non-destructive evaluation of the biopsy specimen and more rapid measurement compared to histological analysis²⁹. Caubet et al. evaluated the bone morphometric parameters of Bio-Oss and BoneCeramic in maxillary sinus augmentation²⁴. At 6-8 months, the BV/TV using Bio-Oss was 48.2% and using BoneCeramic was 43.2%. Higher BV/TV values were found in both bioactive glass

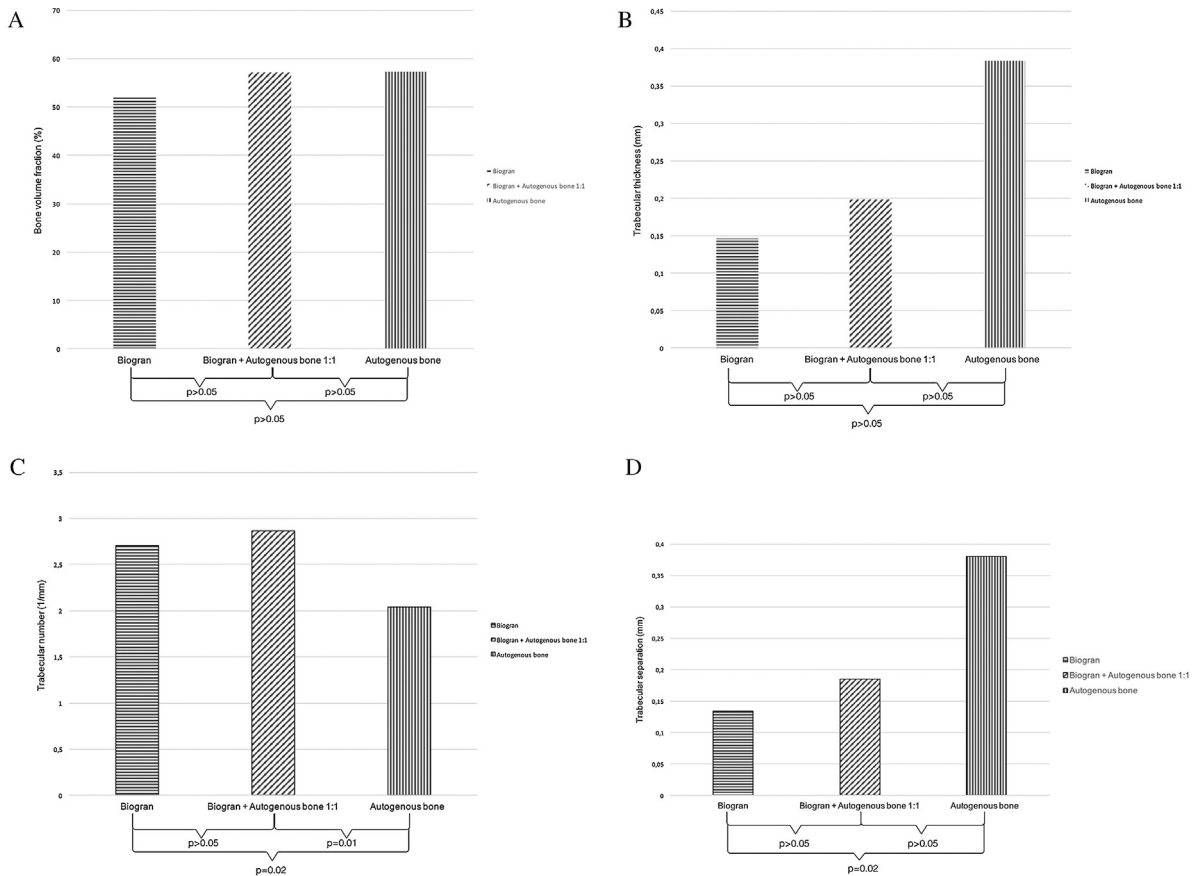


Fig. 2. Graphs demonstrating the trabecular bone microarchitecture in human maxillary sinus augmentation with Biogran (bioactive glass), Biogran in combination with autogenous bone graft 1:1, and autogenous bone graft, after 6 months: (A) bone volume fraction (BV/TV); (B) trabecular thickness (Tb.Th); (C) trabecular number (Tb.N); (D) trabecular separation (Tb.Sp).

groups in the present study, particularly in group 2. Lower BV/TV values have been reported in the literature with the use of beta-tricalcium phosphate as the bone substitute in maxillary sinus augmentation⁴⁹. Thus, the groups tested in this study (groups 1 and 2) presented more reliable 3D bone microarchitecture parameters than cases in which other biomaterials were used to re-establish bone height in the posterior maxilla. Both bone substitutes showed positive results and similar values for trabecular thickness and trabecular separation. Nevertheless, when Biogran was mixed with autogenous bone graft in a 1:1 ratio, an increase in trabecular number occurred and consequently an improvement in bone volume fraction.

In conclusion, the findings of this study showed that Biogran has similar outcomes compared to autogenous bone graft in maxillary sinus bone augmentation. Nevertheless, the mixture of Biogran and autogenous bone graft in a 1:1 ratio decreased the resorption volume and improved the trabecular bone microarchitecture. Further studies are necessary to demonstrate the cellular activity and the osteogenic potential of these biomaterials.

Funding

None declared.

Competing interests

None declared.

Ethical approval

This study followed the ethical principles for human experimentation of the Araçatuba Dental School, UNESP, and was approved by the institutional ethics committee (number 47711015.4.0000.5420).

Patient consent

Not required.

Acknowledgement. We thank CAPES (Coordenação de Aperfeiçoamento de Pessoal de Nível Superior) for financial support, which enabled the authors to develop this study.

References

- Yildirim M, Spiekermann H, Handt S, Edelhoff D. Maxillary sinus augmentation with the xenograft Bio-Oss and autogenous intraoral bone for qualitative improvement of the implant site: a histologic and histomorphometric clinical study in humans. *Int J Oral Maxillofac Implants* 2001;**16**:23–33.
- Furusawa T, Mizunuma K. Osteoconductive properties and efficacy of resorbable bioactive glass as a bone-grafting material. *Implant Dent* 1997;**6**:93–101.
- Lundgren S, Moy P, Johansson C, Nilsson H. Augmentation of the maxillary sinus floor with particulated mandible: a histologic and histomorphometric study. *Int J Oral Maxillofac Implants* 1996;**11**:760–6.
- Rickert D, Vissink A, Slot WJ, Sauerbier S, Meijer HJ, Raghoobar GM. Maxillary sinus floor elevation surgery with BioOss mixed with a bone marrow concentrate or autogenous bone: test of principle on implant survival and clinical performance. *Int J Oral Maxillofac Surg* 2014;**43**:243–7.
- Szabó G, Huys L, Coulthard P, Maiorana C, Garagiola U, Barabás J, Németh Z, Hrabák K, Suba Z. A prospective multicenter randomized clinical trial of autogenous bone versus beta-tricalcium phosphate graft alone for bilateral sinus elevation: histologic and histomorphometric evaluation. *Int J Oral Maxillofac Implants* 2005;**20**:371–81.
- Torrecillas-Martínez L, Galindo-Moreno P, Ávila-Ortiz G, Ortega-Oller I, Monje A, Hernández-Cortés P, Aguilar D, O'Valle F. Significance of the immunohistochemical expression of bone morphogenetic protein-4 in bone maturation after maxillary sinus grafting in humans. *Clin Implant Dent Relat Res* 2016;**18**:717–24.
- Valentini P, Abensur D. Maxillary sinus floor elevation for implant placement with demineralized freeze-dried bone and bovine bone (Bio-Oss): a clinical study of 20 patients. *Int J Periodontics Restorative Dent* 1997;**17**:233–41.
- Cypher TJ, Grossman JP. Biological principles of bone graft healing. *J Foot Ankle Surg* 1996;**35**:413–7.
- Misch CE. Maxillary sinus augmentation for endosteal implants: organized alternative treatment plans. *Int J Oral Implantol* 1987;**4**:49–58.
- Cordaro L. Bilateral simultaneous augmentation of the maxillary sinus floor with particulated mandible. Report of a technique and preliminary results. *Clin Oral Implants Res* 2003;**14**:201–6.
- Niedhart C, Pingsmann A, Jurgens C, Marr A, Blatt R, Niethard FU. Complications after harvesting of autologous bone from the ventral and dorsal iliac crest—a prospective, controlled study. *Z Orthop Ihre Grenzgeb* 2003;**141**:481–6.
- Moy PK, Lundgren S, Holmes RE. Maxillary sinus augmentation—histomorphometric analysis of graft materials for maxillary sinus floor augmentation. *J Oral Maxillofac Surg* 1993;**51**:857–62.
- Jones JR. Review of bioactive glass: from Hench to hybrids. *Acta Biomater* 2013;**9**:4457–86.
- Suba Z, Takacs D, Matusovits D, Barabas J, Fazekas A, Szabo G. Maxillary sinus floor grafting with beta-tricalcium phosphate in humans: density and microarchitecture of the newly formed bone. *Clin Oral Implants Res* 2006;**17**:102–8.
- Hench LL. The story of bioglass. *J Mater Sci Mater Med* 2006;**17**:967–78.
- Cordioli G, Mazzocco C, Schepers E, Brugnolo E, Majzoub Z. Maxillary sinus floor augmentation using bioactive glass granules and autogenous bone with simultaneous implant placement. Clinical and histological findings. *Clin Oral Implants Res* 2016;**2001**(12):270–8.
- Schepers EJ, Ducheyne P. Bioactive glass particles of narrow size range for the treatment of oral bone defects: a 1–24 month experiment with several materials and particle sizes and size ranges. *J Oral Rehabil* 1997;**24**:171–81.
- Abdulkarim HH, Miley DD, McLeod DE, Garcia MN. Short-term evaluation of bioactive glass using the modified osteotome sinus elevation technique. *Implant Dent* 2013;**22**:491–8.
- Diserens V, Mericske E, Mericske-Stern R. Radiographic analysis of the transcrestal sinus floor elevation: short-term observations. *Clin Implant Dent Relat Res* 2005;**7**:70–8.
- Sbordone L, Levin L, Guidetti F, Sbordone C, Glikman A, Schwartz-Arad D. Apical and marginal bone alterations around implants in maxillary sinus augmentation grafted with autogenous bone or bovine bone material and simultaneous or delayed dental implant positioning. *Clin Oral Implants Res* 2011;**22**:485–91.
- Arasawa M, Oda Y, Kobayashi T, Uoshima K, Nishiyama H, Hoshina H, Saito C. Evaluation of bone volume changes after sinus floor augmentation with autogenous bone grafts. *Int J Oral Maxillofac Surg* 2012;**41**:853–7.
- Xavier SP, Silva ER, Kahn A, Chaushu L, Chaushu G. Maxillary sinus grafting with autograft versus fresh-frozen allograft: a split-mouth evaluation of bone volume dynamics. *Int J Oral Maxillofac Implants* 2015;**30**:1137–42.
- Trisi P, Rebaudi A, Calvari F, Lazzara RJ. Sinus graft with Biogran, autogenous bone, and PRP: a report of three cases with histology and micro-CT. *Int J Periodontics Restorative Dent* 2006;**26**:113–25.
- Caubet J, Ramis JM, Ramos-Murguialday M, Morey MA, Monjo M. Gene expression and morphometric parameters of human bone biopsies after maxillary sinus floor elevation with autologous bone combined with Bio-Oss(R) or BoneCeramic(R). *Clin Oral Implants Res* 2015;**26**:727–35.
- Feldkamp LA, Goldstein SA, Parfitt AM, Jesion G, Kleerekoper M. The direct examination of three-dimensional bone architecture in vitro by computed tomography. *J Bone Miner Res* 1989;**4**:3–11.

26. Spin-Neto R, Stavropoulos A, Pereira LA, Marcantonio Jr E, Wenzel A. Fate of autologous and fresh-frozen allogeneic block bone grafts used for ridge augmentation. A CBCT-based analysis. *Clin Oral Implants Res* 2016;**2011**(21):167–73.
27. Pereira RS, Gorla LF, Boos FB, Okamoto R, Garcia Júnior IR, Hochuli-Vieira E. Use of autogenous bone and beta-tricalcium phosphate in maxillary sinus lifting: histomorphometric study and immunohistochemical assessment of RUNX2 and VEGF. *Int J Oral Maxillofac Surg* 2017;**46**:503–10.
28. Boyne PJ, James RA. Grafting of the maxillary sinus floor with autogenous marrow and bone. *J Oral Surg* 1980;**38**:613–6.
29. Gorla LF, Spin-Neto R, Boos FB, Pereira Rdos S, Garcia-Junior IR, Hochuli-Vieira E. Use of autogenous bone and beta-tricalcium phosphate in maxillary sinus lifting: a prospective, randomized, volumetric computed tomography study. *Int J Oral Maxillofac Surg* 2015;**44**:1486–91.
30. Bouxsein ML, Boyd SK, Christiansen BA, Guldberg RE, Jepsen KJ, Muller R. Guidelines for assessment of bone microstructure in rodents using micro-computed tomography. *J Bone Miner Res* 2010;**25**:1468–86.
31. Clozza E, Pea M, Cavalli F, Moimas L, Di Lenarda R, Biasotto M. Healing of fresh extraction sockets filled with bioactive glass particles: histological findings in humans. *Clin Implant Dent Relat Res* 2014;**16**:145–53.
32. Dybvik T, Leknes KN, Boe OE, Skavland RJ, Albandar JM. Bioactive ceramic filler in the treatment of severe osseous defects: 12-month results. *J Periodontol* 2007;**78**:403–10.
33. Froum SJ, Weinberg MA, Tarnow D. Comparison of bioactive glass synthetic bone graft particles and open debridement in the treatment of human periodontal defects. A clinical study. *J Periodontol* 1998;**69**:698–709.
34. Nevins ML, Camelo M, Nevins M, King CJ, Oringer RJ, Schenk RK, Fiorellini JP. Human histologic evaluation of bioactive ceramic in the treatment of periodontal osseous defects. *Int J Periodontics Restorative Dent* 2000;**20**:458–67.
35. Suzuki KR, Misch CE, Arana G, Rams TE, Suzuki JB. Long-term histopathologic evaluation of bioactive glass and human-derived graft materials in *Macaca fascicularis* mandibular ridge reconstruction. *Implant Dent* 2011;**20**:318–22.
36. Thronson RR, Sexton SB. Grafting mandibular third molar extraction sites: a comparison of bioactive glass to a nongrafted site. *Oral Surg Oral Med Oral Pathol Oral Radiol Endod* 2002;**94**:413–9.
37. Tadjodin ES, de Lange GL, Holzmann PJ, Kuiper L, Burger EH. Histological observations on biopsies harvested following sinus floor elevation using a bioactive glass material of narrow size range. *Clin Oral Implants Res* 2000;**11**:334–44.
38. Turunen T, Peltola J, Yli-Urpo A, Happonen RP. Bioactive glass granules as a bone adjunctive material in maxillary sinus floor augmentation. *Clin Oral Implants Res* 2004;**15**:135–41.
39. Somanathan RV, Simunek A. Evaluation of the success of beta-tricalcium phosphate and deproteinized bovine bone in maxillary sinus augmentation using histomorphometry: a review. *Acta Medica (Hradec Kralove)* 2006;**49**:87–9.
40. Cosso MG, de Brito RB, Piattelli A, Shibli JA, Zenobio EG. Volumetric dimensional changes of autogenous bone and the mixture of hydroxyapatite and autogenous bone graft in humans maxillary sinus augmentation. A multislice tomographic study. *Clin Oral Implants Res* 2014;**25**:1251–6.
41. Jensen T, Schou S, Svendsen PA, Forman JL, Guundersen HJ, Terheyden H, Holmstrup P. Bone-to-implant contact after maxillary sinus floor augmentation with Bio-Oss and autogenous bone in different ratios in mini pigs. *Clin Oral Implants Res* 2013;**24**:634–5.
42. Block MS, Kent JN. Sinus augmentation for dental implants: the use of autogenous bone. *J Oral Maxillofac Surg* 1997;**55**:1281–6.
43. Nagahara K, Isogai M, Shibata K, Meenaghan MA. Osteogenesis of hydroxyapatite and tricalcium phosphate used as a bone substitute. *Int J Oral Maxillofac Implants* 1992;**7**:72–9.
44. Gultekin BA, Cansiz E, Borahan O, Mangano C, Kolerman R, Mijiritsky E, Yalcin S. Evaluation of volumetric changes of augmented maxillary sinus with different bone grafting biomaterials. *J Craniofac Surg* 2016;**27**:e144–8.
45. Jensen T, Schou S, Svendsen PA, Forman JL, Guundersen HJ, Terheyden H, Holmstrup P. Volumetric changes of the graft after maxillary sinus floor augmentation with Bio-Oss and autogenous bone in different ratios: a radiographic study in minipigs. *Clin Oral Implants Res* 2012;**23**:902–10.
46. Lee JS, Shin HK, Yun JH, Cho KS. Randomized clinical trial of maxillary sinus grafting using deproteinized porcine and bovine bone mineral. *Clin Implant Dent Relat Res* 2017;**19**:140–50.
47. Dos Santos Pereira R, Boos FB, Gorla LF, Garcia Jr IR, Okamoto R, Hochuli-Vieira E. Maxillary sinus elevation surgery with ChronOS and autogenous bone graft: analysis of histometric and volumetric changes. *Int J Periodontics Restorative Dent* 2016;**36**:885–92.
48. Muller R, Van Campenhout H, Van Damme B, Van Der Perre G, Dequeker J, Hildebrand T, Ruegsegger P. Morphometric analysis of human bone biopsies: a quantitative structural comparison of histological sections and micro-computed tomography. *Bone* 1998;**23**:59–66.
49. Chappard D, Guillaume B, Mallet R, Pascaretti-Grizon F, Basle MF, Libouban H. Sinus lift augmentation and beta-TCP: a microCT and histologic analysis on human bone biopsies. *Micron* 2010;**41**:321–6.

Address:

Rodrigo dos Santos Pereira

Zeferino Street 243

Mesquita

Rio de Janeiro 26551-081

Brazil

Tel.: +55 021 96937 5841

E-mail: dr.pereira@live.com