



Bone repair with raloxifene and bioglass nanoceramic composite in animal experiment

Paulo N. Lisboa-Filho, Pedro Henrique S. Gomes-Ferreira, Fábio R. S. Batista, Gustavo A. C. Momesso, Leonardo P. Faverani & Roberta Okamoto

To cite this article: Paulo N. Lisboa-Filho, Pedro Henrique S. Gomes-Ferreira, Fábio R. S. Batista, Gustavo A. C. Momesso, Leonardo P. Faverani & Roberta Okamoto (2018) Bone repair with raloxifene and bioglass nanoceramic composite in animal experiment, Connective Tissue Research, 59:sup1, 97-101, DOI: [10.1080/03008207.2018.1430143](https://doi.org/10.1080/03008207.2018.1430143)

To link to this article: <https://doi.org/10.1080/03008207.2018.1430143>



Published online: 10 May 2018.



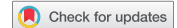Submit your article to this journal [↗](#)




Article views: 306



View Crossmark data [↗](#)



Bone repair with raloxifene and bioglass nanoceramic composite in animal experiment

Paulo N. Lisboa-Filho ^a, Pedro Henrique S. Gomes-Ferreira^b, Fábio R. S. Batista^b, Gustavo A. C. Momesso^b, Leonardo P. Faverani^b, and Roberta Okamoto^c

^aDepartment of Physics, UNESP - São Paulo State University, School of Sciences, Bauru, SP, Brazil; ^bDepartment of Surgery and Integrated Clinic, UNESP - São Paulo State University, Araçatuba Dental School, Araçatuba, SP, Brazil; ^cDepartment of Basic Sciences UNESP - São Paulo State University, School of Sciences, Bauru, SP, Brazil

ABSTRACT

OBJECTIVE: This study proposes to evaluate, by means of microtomographic analysis, the topical potential of raloxifene combined with BioGran[®] through the sonochemical method in the repair of critical bone defects in the calvaria of rats. The hypothesis was that the homogenization of Raloxifene to Biogran at the 20% concentration would improve the bone repair at the grafted site.

MATERIALS AND METHODS: A 5-mm calvaria bone defect was induced in three groups: CTR (100% BioGran[®]); RAL10 (90% BioGran[®] and 10% raloxifene), and RAL20 (80% BioGran[®] and 20% raloxifene). The animals were euthanized after 30 days and the microCT analysis was then performed to evaluate the parameters bone volume (BV), bone volume percentage (BV/TV), trabecular bone thickness (Tb.Th), and the separation and number of trabeculae (Tb.Sp and Tb.N). The obtained results were compared using ANOVA and Tukey test ($p < 0.05$).

RESULTS: The best results were found for the CTR and RAL20 groups, in which the BV, BV/TV, Tb.Sp, and Tb.N parameters were statistically significant in comparison with RAL10 ($p < 0.05$).

CONCLUSIONS: In view of the results obtained in this experiment, we can conclude that BioGran[®] alone or in an 80/20 mass concentration with raloxifene can lead to favorable bone formation.

ARTICLE HISTORY

Received 23 August 2017
Revised 27 October 2017
Accepted 11 December 2017

KEYWORDS

Bioglass; in vivo experiment; osteoporosis; raloxifene; Calvaria; Raloxifene; Biomaterials

Introduction

The development of biomaterials to accelerate bone repair without impairing bone quality and achieving ideal graft properties during the filling of bone defects is a field facing constant challenges (1,2). Currently, the field is trending toward attempts to create a biomaterial with conductive or inductive properties for bone formation to approach or even exceed the growth rate of autogenous bone (3).

BioGran[®] (BioGran, Inc.; USA) is an alloplastic biomaterial, osteoconductive and composed of bioactive glass that has shown good results in bone regeneration (4,5). However, these osteoconductive materials are related to bone formation. In cases of compromised or deficient bone tissue formation, such as in osteoporosis, the tissue is reabsorbed when new bone is formed. In such cases, antiresorptive medications such as raloxifene (selective modulator of estrogen receptors) (Evista[®], Lilly, USA) can be used systemically, targeting the endogenous regulation of the complex osteogenesis versus osteoclastogenesis (6–8). Although the systemic results of raloxifene are known to be promising (6–8),

its topical application also shows interesting results (9); however, no report in the specialized literature discussed the combined effect of raloxifene and a bioactive glass in improving bone regeneration and possible collateral systemic effects.

This study proposes to evaluate, by means of microtomographic analysis, the topical potential of raloxifene combined with BioGran[®] through the sonochemical method in the repair of critical bone defects in the calvaria of rats. The initial hypothesis was that the homogenization of Raloxifene to Biogran at the 20% concentration would improve the bone repair at the grafted site.

Materials and methods

Preparation of biomaterials

The materials used for this study were BioGran[®] and raloxifene in solid form, which were homogenized by the sonochemical method using a Sonics[®] VCX-750 (Sonics & Materials, Inc., USA) with 750 W of power at a frequency of 20 kHz for 30 minutes and a variable amplitude of up to 40% of the nominal amplitude of

the equipment (10). Ultra-pure Milli-Q® (Millipore, USA) water was used as a medium to obtain a homogeneous mixture and decrease particle size.

Experimental design

After approval by the Committee of Ethics in Animal Experimentation of the Faculty of Dentistry of Araçatuba-UNESP (process 00235–2017), 24 rats (*Rattus norvegicus albinus*, Wistar), male, adult (3 months), and weighing approximately 250 g each, were submitted to a 5-mm critical defect in the calvaria. These animals were divided into three groups ($n = 8$): **CTR**, in which the defect was filled with 100% BioGran®; **RAL10**, in which the defect was filled with 90% BioGran® and 10% raloxifene; and **RAL20**, in which the defect was filled with 80% BioGran® and 20% raloxifene.

The animals were anesthetized with xylazine (Coopazine®; Coopers, Ltda; Brazil) and intravenous ketamine hydrochloride (Vetasept®; Fort Dodge Saúde Animal, Ltda; Brazil), and trichotomy of the calvaria region and local antisepsis were performed, followed by the placement of sterile fields. Local anesthesia was performed with lidocaine (without a vasoconstrictor) diluted to 0.5% in a saline solution, 1–3 mg/kg (11).

For each animal, a U-shaped incision was made in the occipitofrontal direction, and the tissue was detached. Using a 5 mm-diameter inner drill bit (3i Implant Innovations, Inc.; USA), a 5 mm-diameter surgical defect was made in the left parietal bone, maintaining the integrity of the dura mater. Prior to synthesis of the biomaterials, the defects were covered with resorbable bovine bone membrane (Baumer®, Gen Derm; Brazil), and the soft tissues were carefully repositioned and sutured. The defect fills were performed on the CTR, RAL10, and RAL20 groups using the materials as described above. In the immediate post-operative period, each animal received a single intramuscular dose of 0.2 mL of penicillin G benzathine

(Pentabiótico Veterinário Pequeno Porte; Fort Dodge Saúde Animal, Ltda.; Brazil).

The animals were euthanized 30 days after surgery through an excessive dose of anesthetic (Sodium thio-pental—dose 100 mg/kg intraperitoneally).

Microct

The rat calvaria were removed, reduced, and fixed in a 10% formaldehyde solution for 48 hours, washed in running water for 24 hours, and then kept in a 70% alcohol solution.

Using the SkyScan microtograph (SkyScan 1272, Bruker MicroCT, Belgium, 2003), the pieces were scanned (Figure 1) in 11 μm slices with a 0.5 mm Al filter and a 0.6 mm rotation step. The scanning was done at 180° with a frame of 2, a resolution of 2016 \times 1344, and an acquisition time of approximately 50 minutes. The images, obtained by X-ray, were stored and reconstructed by determining the area of interest with NRecon software (SkyScan, version 1.6.6.0, 2011) using a smoothing of 2, an artifact ring correction of 5, a beam-hardening correction of 20%, and an image-conversion range varying from 0.007 to 0.061. The images were reconstructed in Data Viewer (SkyScan, version 1.4.4, 64-bit) and observed on three planes (transversal, longitudinal, and sagittal). Then, using CT analyzer software (CTAn, 2003–11 and SkyScan, 2012; Bruker MicroCT; version 1.12.4.0), the region of the created defect (40 slices for each sample) was evaluated, using a histogram of 110–205 to remove the denser material. The parameters evaluated were bone volume (BV), bone volume percentage (BV/TV), trabecular bone thickness (Tb.Th), and the separation and number of trabeculae (Tb.Sp and Tb.N).

Statistical analysis

The statistical analysis was performed using GraphPad Prism software (GraphPad Software, Inc.; USA; 2017).



Figure 1. Images obtained by microCT of CTR, RAL10, and RAL20.

An analysis of homoscedasticity was performed using the Shapiro-Wilk test to distinguish parametric and nonparametric data. For the analysis of the microCT data, the one-way ANOVA test and Tukey post-test were used. A significance level of $p < 0.05$ was adopted for all tests.

Results

Microct

Among the results obtained in the microtomographic evaluation, the highest BV values were found to be for the CTR group (3.03 mm^3), followed by those for RAL20 (2.54 mm^3), while the worst result was for RAL10 (1.28 mm^3), as shown in Figure 2. The same pattern was found in the BV percentages (BV/TV), with the highest results being for CTR (23.70%) and RAL20 (19.98%) and the lowest results being for RAL10 (10.05%), as seen in Figure 3. For BV and BV/TV, there were statistically significant differences between CTR and RAL10 and between RAL20 and RAL10 ($p < 0.05$, Tukey).

Testing the thickness of the trabecular bone formed around the biomaterial particles (Tb.Th) showed approximate averages of 0.054 mm for CTR and 0.050 mm for RAL10, with a smaller value of 0.044 mm for RAL20; however, there were no statistically significant differences among the three groups, as seen in Figure 4.

Testing the separations between the trabeculae (Tb.Sp) showed approximate average values of 0.1487 mm (CTR), 0.1544 mm (RAL20), and 0.2746 mm (RAL10) (Figure 5). Testing the number of trabeculae (Tb.N) showed an average of 4.642 for the CTR group, which was close to the RAL20 value of 4.535, while a smaller value of 2.002 was obtained for the RAL10 group ($p < 0.05$, Tukey) (Figure 6). For both Tb.Sp and Tb.N, the results presented statistically significant

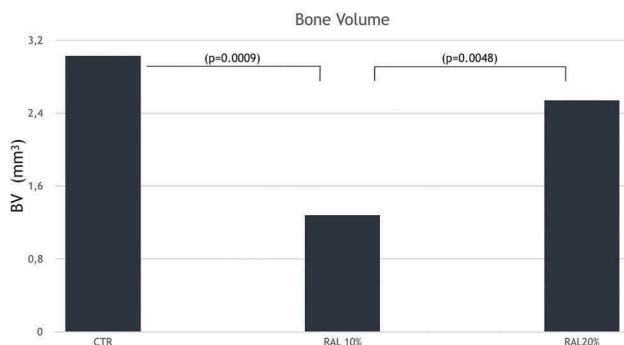


Figure 2. Quantification of bone volume. Approximately, equivalent volumes in the CTR and RAL20 groups and a lower volume for the RAL10 group ($p < 0.05$).

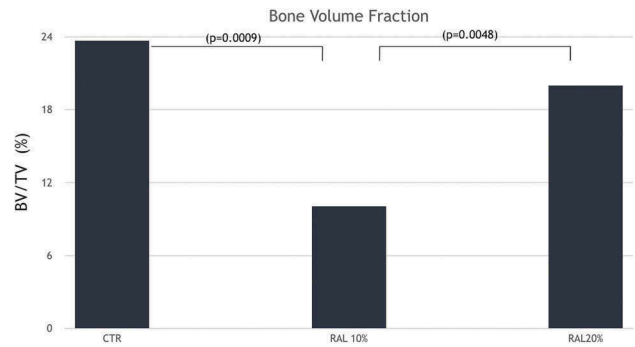


Figure 3. Quantification of the percentage of bone volume. Approximately, equivalent percentages in the CTR and RAL20 groups and a lower percentage for the RAL10 group ($p < 0.05$).

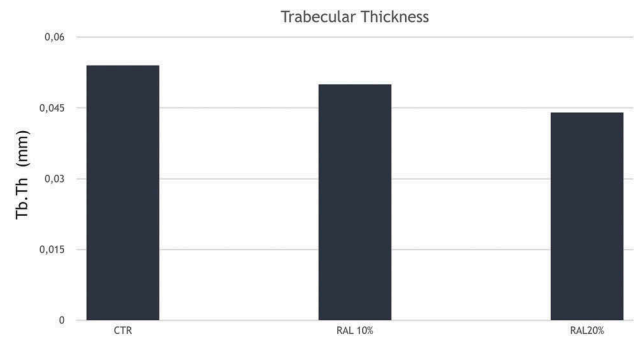


Figure 4. Quantification of trabeculae thickness. Approximately, equivalent values for CTR, RAL10, and RAL20 ($p < 0.05$).

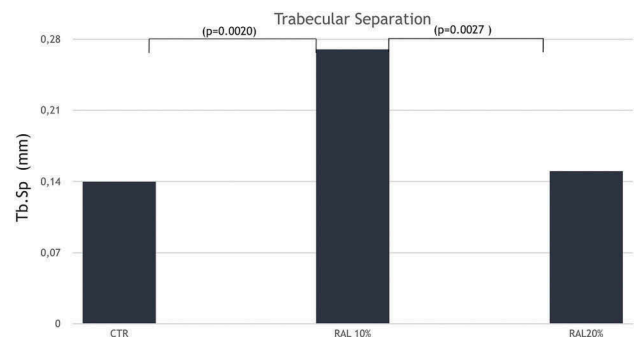


Figure 5. Quantification of the separations between the trabeculae. Larger values for RAL10 and smaller values for the CTR and RAL20 groups ($p < 0.05$).

differences between CTR and RAL10 and between RAL20 and RAL10 ($p < 0.05$, Tukey).

Discussion

The obtained results pointed that the initial hypothesis was acceptable. Among the biomaterials described in the literature, BioGran®, an alloplastic material composed of bioactive glass, was chosen for this research because the positive results of its osteoconductive

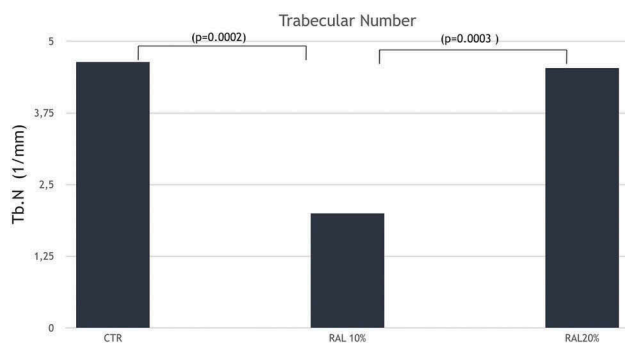


Figure 6. Quantification of the number of trabeculae. Higher value for CTR and RAL20 with significantly lower values for RAL10 ($p < 0.05$).

properties have already been described (4,5). In a clinical study, it was possible to evaluate that its characteristics can promote results comparable to the autogenous graft in sinus lift surgeries (12). Moreover, its physical and structural characteristics can be easily reduced and homogenized through the sonochemical process. Raloxifene was chosen because it has shown the best results among antiresorptive medications in alveolar and peri-implant bone repair (6–8).

During the evaluation of a homogeneous nanoparticle mixture of BioGran® and raloxifene in different concentrations, it was observed that the 80/20 concentration was most effective in the formation of high volumes of good quality new bone, while the 90/10 concentration delivered an unfavorable result compared to BioGran® alone or in combination with 20% raloxifene. This was confirmed by evaluating the volume and percentage of new bone (BV and BV/TV), for which the CRT and RAL20 groups presented the best results, while RAL10 presented the worst ($p < 0.05$, Tukey).

Bone quality was evaluated by trabecular thickness, separation, and number. The best trabecular thickness results were observed in the CTR group, followed by RAL10 and RAL20, but there were no statistically significant differences among the groups. On the other hand, trabecular separations were larger for the RAL10 group, while a smaller number of trabeculae were observed, thus showing that RAL10 presented the worst bone characteristics of all three groups, with a lower volume and a higher porosity (fewer trabeculae with more space between them) than the other two groups.

Thus, the results show both higher BV and better bone quality for the CTR and RAL20 groups. There was no statistically significant difference in trabecular bone thickness among the three groups, and CTR and RAL20 presented a higher number of trabeculae with less spacing between them; thus, a greater trabecular volume than RAL10.

Conclusion

In view of the results obtained in this experiment, we can conclude that BioGran® alone or in an 80/20 mass concentration with raloxifene can lead to favorable bone formation, nevertheless future in-vitro studies are necessary to evaluate this combination for further clinical evaluation.

Declaration of interests

The authors declare that they have no competing interests.

ORCID

Paulo N. Lisboa-Filho  <http://orcid.org/0000-0002-7734-4069>

References

- Blank BS, Levy AR. Combined treatment of a large periodontal defect using GTR and DFDBA. *Int J Periodontics Restorative Dent.* 1999 Oct;19(5):481–487.
- Young C, Sandstedt P, Skoglund A. A comparative study of anorganic xenogenic bone and autogenous bone implants for bone regeneration in rabbits. *Int J Oral Maxillofac Implants.* 1999 Jan–Feb;14(1):72–76.
- Luvizuto ER, Tangl S, Zanoni G, Okamoto T, Sonoda CK, Gruber R, Okamoto R. The effect of BMP-2 on the osteoconductive properties of beta-tricalcium phosphate in rat calvaria defects. *Biomaterials.* 2011 May;32(15):3855–3861.
- Santos FA, Pochapski MT, Martins MC, Zenóbio EG, Spolidoro LC, Marcantonio E Jr. Comparison of biomaterial implants in the dental socket: histological analysis in dogs. *Clin Implant Dent Relat Res.* 2010 Mar;12(1):18–25.
- Pereira RDS, Menezes JD, Bonardi JP, Griza GL, Okamoto R, Hochuli-Vieira E. Histomorphometric and immunohistochemical assessment of RUNX2 and VEGF of Biogran™ and autogenous bone graft in human maxillary sinus bone augmentation: A prospective and randomized study. *Clin Implant Dent Relat Res.* 2017 Oct;19(5):867–875. doi: 10.1111/cid.12507.
- Ramalho-Ferreira G, Faverani LP, Grossi-Oliveira GA, Okamoto T, Okamoto R. Alveolar bone dynamics in osteoporotic rats treated with raloxifene or alendronate: confocal microscopy analysis. *J Biomed Opt.* 2015 Mar;20(3):038003.
- Ramalho-Ferreira G, Faverani LP, Momesso GAC, Luvizuto ER, de Oliveira Puttini I, Okamoto R. Effect of antiresorptive drugs in the alveolar bone healing. A histometric and immunohistochemical study in ovariectomized rats. *Clin Oral Investig.* 2017 Jun;21(5):1485–1494.
- Kavas A, Keskin D, Altunbaş K, Tezcaner A. Raloxifene-/raloxifene-poly(ethylene glycol) conjugate-loaded microspheres: A novel strategy for drug delivery

- to bone forming cells. *Int J Pharm.* **2016** Aug 20;510(1):168–183.
9. Arruda LB, Orlandi MO, Lisboa-Filho PN. Morphological modifications and surface amorphization in ZnO sonochemically treated nanoparticles. *Ultrason Sonochem.* **2013** May;20(3):799–804.
 10. Flecknell P. *Laboratory animal anaesthesia.* 3rd ed. London, UK: Elsevier Inc; **2009**.
 11. Pereira RDS, Menezes JD, Bonardi JP, Griza GL, Okamoto R, Hochuli-Vieira E. Histomorphometric and immunohistochemical assessment of RUNX2 and VEGF of Biogran™ and autogenous bone graft in human maxillary sinus bone augmentation: A prospective and randomized study. *Clin Implant Dent Relat Res.* **2017** Oct;19(5):867–875.
 12. Faverani LP, Polo TO, Ramalho-Ferreira G, Momesso GA, Hassumi JS, Rossi AC, Freire AR, Prado FB, Luvizuto ER, Gruber R, Okamoto R. Raloxifene but not alendronate can compensate the impaired osseointegration in osteoporotic rats. *Clin Oral Investig.* **2017** Mar 29. doi:10.1007/s00784-017-2106-2.