

# Toxicologic Pathology

<http://tpx.sagepub.com/>

---

## Comparison of Uroplakin Expression During Urothelial Carcinogenesis Induced by N-Butyl-N-(4-Hydroxybutyl)Nitrosamine in Rats and Mice

Kumiko Ogawa, Margaret St. John, Maria Luiza De Oliveira, Lora Arnold, Tomoyuki Shirai, Tung-Tien Sun and Samuel M. Cohen

*Toxicol Pathol* 1999 27: 645

DOI: 10.1177/019262339902700606

The online version of this article can be found at:

<http://tpx.sagepub.com/content/27/6/645>


---

Published by:



<http://www.sagepublications.com>

On behalf of:



<http://www.sagepub.com>

Additional services and information for *Toxicologic Pathology* can be found at:

**Email Alerts:** <http://tpx.sagepub.com/cgi/alerts>

**Subscriptions:** <http://tpx.sagepub.com/subscriptions>

**Reprints:** <http://www.sagepub.com/journalsReprints.nav>

**Permissions:** <http://www.sagepub.com/journalsPermissions.nav>

**Citations:** <http://tpx.sagepub.com/content/27/6/645.refs.html>

>> [Version of Record](#) - Nov 1, 1999

[What is This?](#)

# Comparison of Uroplakin Expression During Urothelial Carcinogenesis Induced by *N*-Butyl-*N*-(4-Hydroxybutyl)Nitrosamine in Rats and Mice\*

KUMIKO OGAWA,<sup>1,2</sup> MARGARET ST. JOHN,<sup>1</sup> MARIA LUIZA DE OLIVEIRA,<sup>1,4</sup> LORA ARNOLD,<sup>1</sup> TOMOYUKI SHIRAI,<sup>2</sup> TUNG-TIEN SUN,<sup>3</sup> AND SAMUEL M. COHEN<sup>1</sup>

<sup>1</sup>Department of Pathology and Microbiology and the Eppley Institute for Research in Cancer, University of Nebraska Medical Center, Omaha, Nebraska 68198-3135, USA,

<sup>2</sup>First Department of Pathology, Nagoya City University Medical School, Nagoya 454, Japan, and

<sup>3</sup>Epithelial Biology Unit, The Ronald O. Perleman Department of Dermatology, Department of Pharmacology and Kaplan Comprehensive Cancer Center, New York University School of Medicine, New York, New York 10016, USA

## ABSTRACT

The expression of uroplakins, the tissue-specific and differentiation-dependent membrane proteins of the urothelium, was analyzed immunohistochemically in *N*-butyl-*N*-(4-hydroxybutyl)nitrosamine (BBN)-treated rats and mice during bladder carcinogenesis. Male Fischer 344 rats were treated with 0.05% BBN in the drinking water for 10 wk and were euthanized at week 20 of the experiment. BBN was administered to male B6D2F<sub>1</sub> mice; it was either provided at a rate of 0.05% in the drinking water (for 26 wk) or 5 mg BBN was administered by intragastric gavage twice weekly for 10 wk, followed by 20 wk without treatment. In rats, BBN-induced, noninvasive, low-grade, papillary, transitional cell carcinoma (TCC) showed decreased uroplakin-staining of cells lining the lumen but showed increased expression in some nonluminal cells. In mice, nonpapillary, high-grade dysplasia, carcinoma *in situ*, and invasive carcinoma were induced. There was a marked decrease in the number of uroplakin-positive cells lining the lumen and in nonluminal cells. This occurred in normal-appearing urothelium in BBN-treated mice and in dysplastic urothelium, in carcinoma *in situ*, and in invasive TCC. The percentage of uroplakin-positive nonluminal cells was higher in control mice than in rats, but it was lower in the mouse than in the rat after BBN treatment. Uroplakin expression was disorderly and focal in BBN-treated urothelium in both species. These results indicate that BBN treatment changed the expression of uroplakins during bladder carcinogenesis, with differences in rats and mice being related to degree of tumor differentiation.

**Keywords.** Uroplakins; differentiation; bladder cancer; cell membranes

## INTRODUCTION

Uroplakins are the major protein components of the asymmetric unit membrane (AUM). The AUM is a specialized plasma membrane representing urothelial terminal differentiation, which is unique to the luminal surface of superficial cells and of the intracytoplasmic vesicles (17, 20). Possible functions of the AUM include the following: it may act as a permeability barrier; it may act as a means of stabilizing the apical bladder surface; and it may act as a supramolecular device to change the surface area of the plasma membrane during expansion or contraction of the bladder. Uroplakins are synthesized in the endoplasmic reticulum, concentrated and modified in the Golgi complex, and then incorporated into the membrane of intracytoplasmic fusiform vesicles and into the plasmalemma. Uroplakins are mainly produced in cells of the superficial layer of the urothelium. Uroplakins consist of 4 components: the 27-kDa uroplakin Ia; the 28-kDa uroplakin Ib; the 15-kDa uroplakin II; and the 47-kDa uroplakin III (10, 17–20). Together they form 16-

nm twisted ribbon-shaped particles that are arranged in a well-ordered, hexagonal lattice with p6 symmetry (15). These 4 uroplakins are conserved through a broad range of mammalian species, including human, monkey, cattle, sheep, pig, dog, rabbit, rat, and mouse (16).

Previous experiments investigating uroplakins in various carcinogen-treated rat bladders showed that the patterns of expression of these proteins were modified during carcinogenesis (13). In the control bladder, the luminal surface membrane of the superficial cells stains strongly positive for uroplakins, but there is no cytoplasmic staining and no staining of basal intermediate cells. The genotoxic carcinogen *N*-[4-(5-nitro-2-furyl)-2-thiazolyl]formamide (FANFT) induces simple hyperplasia, in which uroplakin expression is discontinuous and disorderly, not only in the superficial cells but also in the intermediate cells. The nongenotoxic carcinogens uracil, sodium saccharin, and sodium ascorbate also induce simple hyperplasia, but the staining of the superficial cells remains continuous and orderly. Occasional intermediate cells of the bladder also stained positive for uroplakins in uracil-fed rats (13). In carcinoma induced by FANFT in rats, uroplakin expression is scarce, disorderly, and focal and is usually not present in the cells lining the bladder lumen (13).

*N*-Butyl-*N*-(4-hydroxybutyl)nitrosamine (BBN), like

\* Address correspondence to: Dr. Samuel M. Cohen, Department of Pathology and Microbiology, University of Nebraska Medical Center, 983135 Nebraska Medical Center, Omaha, Nebraska 68198-3135; e-mail: scohen@unmc.edu.

<sup>4</sup> Present address: Departamento de Patologia, Faculdade de Medicina, Unesp, Botucatu-SP, Brazil, CEP, 18618-000.

FANFT (4–6), is a genotoxic carcinogen that is widely used in animal bladder–carcinogenesis studies (2, 8). Several investigators have demonstrated that bladder carcinomas in rats are generally multiple, papillary, and non-invasive until late in the rat's life (greater than 1 yr of age) (4, 6, 8). In contrast, bladder carcinomas in mice tend to be nonpapillary, invasive, and high grade (2). Dysplasia and carcinoma *in situ* occur early in the treatment (by 12 wk) (2).

In the present study, the expression patterns of uroplakins were immunohistochemically compared in rats and mice during bladder carcinogenesis induced by BBN.

#### MATERIALS AND METHODS

The use of animals in these studies followed the guidelines provided in the National Research Council's (1996) *The Guide for Care and Use of Laboratory Animals* and was approved by the University of Nebraska Medical Center Institutional Animal Care and Use Committee.

**Rat Study.** Ten male Fischer 344 (F344) rats (Charles River Japan, Inc., Atsugi, Japan) (4 wk of age) were housed 5 to a plastic cage with hard-wood chip bedding under environmental conditions maintained at 21°C and 55% humidity. Basal diet (pelleted Oriental MF, Oriental Yeast Co., Ltd., Tokyo, Japan) was provided *ad libitum*. The BBN was obtained from Izumi Chemical Research Laboratory (Yokohama, Japan), diluted to 0.05% with tap water, and this mixture was then provided as drinking water (*ad libitum*) for 10 wk. After withdrawal of BBN administration, tap water without added chemicals was available *ad libitum*. At 20 wk, the rats were euthanized, and urinary bladders were inflated *in situ* with 10% phosphate-buffered formalin, divided into longitudinal strips, and processed for routine paraffin embedding; 4–6- $\mu$ m sections were stained either with hematoxylin and eosin or using immunohistochemical methods.

**Mouse Study.** Male 4-wk-old B6D2F<sub>1</sub> mice (Charles River Breeding Laboratories, Inc., Kingston, NY) were housed in plastic cages (4–6/cage) with dry corn-cob bedding. At 5 wk of age, using a weight-stratification method (12), they were randomly divided into 3 groups of 45 each. The animal room was maintained at a temperature of 22°C and a relative humidity of 50%. The BBN was purchased from the same company as was used for the rat study. BBN was administered to 2 different groups by different routes. In group 1, BBN was diluted with tap water to a concentration of 0.05%, and this mixture was given (*ad libitum*) in the drinking water during the entire 26 wk during which this group was maintained in the study. In group 2, 5 mg of BBN was administered by gastric gavage (in 0.1 ml of 20% ethanol) to each mouse twice per week for 10 wk. These mice were then maintained without treatment for an additional 20 wk (total of 30 wk for this group). As a control, the same amount of 20% ethanol was administered to mice in group 3 (twice weekly for 10 wk), and the mice were then maintained for an additional 20 wk without gavage (total of 30 wk, as in group 2). Basal diet (Prolab 3200, Agway, St. Mary's, OH) was provided *ad libitum*. Ten mice from each group were euthanized at week 12 of the experiment. Since few mice in group 1 remained alive

and because they were all showing evidence of bladder tumors (hematuria) and/or weight loss, all surviving mice from the BBN–drinking water group were sacrificed at week 26 of the experiment. The remaining mice in groups 2 and 3 were sacrificed at week 30. The bladders were inflated *in situ* using Bouin's fixative, removed, and placed in Bouin's fixative. After fixation, the bladders were rinsed with 70% ethanol, cut longitudinally into strips, processed for routine embedding in paraffin, and stained with hematoxylin and eosin or immunohistochemical procedures.

**Immunohistochemical Analysis.** The avidin–biotin–peroxidase complex method (7) using the ABC kit (Vector Laboratories, Inc., Burlingame, CA) was performed to detect uroplakin expression. After deparaffinization, formalin-fixed rat bladder sections were heated by microwave with antigen-retrieval solution (BioGenex Laboratories, San Ramon, CA). Bouin's-fixed mouse sections were incubated with 1% nonfat skim-milk solution. Anti-AUM antibody consisted of rabbit antiserum made against highly purified bovine AUM (17), which reacts with all 4 uroplakins and cross-reacts with the uroplakins in all other species evaluated, including rats and mice. It was applied to tissue sections at a 1:10<sup>4</sup> dilution for 2 hr. Diaminobenzidine was used as a substrate, and hematoxylin was used as a nuclear counterstain.

Typical lesions were diagnosed as simple hyperplasia, papillary and nodular (PN) hyperplasia, dysplasia, papilloma, carcinoma *in situ*, papillary carcinoma, and invasive carcinoma (2, 3). The percentage of uroplakin-positive cells was determined by evaluating approximately 300 superficial and 1,200 intermediate bladder urothelial cells in rats and approximately 100 superficial and 400 intermediate cells in mice. Statistical analyses were performed with a generalized linear model procedure (SAS Institute, Inc., Cary, NC). Multivariate analysis of variance (14) was used for multiple comparison of means for percentage data.

#### RESULTS

##### Rat Study

The typical pattern for uroplakins in control rat bladders was limited to staining of the luminal membrane of the superficial cells (Fig. 1a). The normal-appearing rat urothelium of the BBN-treated group showed the same staining pattern as was seen in control rats. In the simple hyperplasia and PN hyperplasia (Fig. 1b) that were induced in the BBN–drinking water group of rats, almost all superficial cells showed uroplakin expression. Occasional expression was also observed in intermediate cells, even when these cells were not directly adjacent to superficial cells. In rat papillary transitional cell carcinoma (Fig. 1c), which is low grade and noninvasive, some cells lining the lumen did not express uroplakins, whereas several nonluminal cells did express uroplakins. As has been shown by scanning electron microscopy (1, 9), the cells at the luminal surface of these bladder tumors are not terminally differentiated superficial cells but, rather, have microvilli on their surfaces instead. The rate of positive-staining nonluminal cells varied depending on histology.

Essentially, the more differentiated (lower grade) the tumor, the greater the expression of uroplakins that was observed in luminal cells.

#### Mouse Study

In control mice, there was staining of superficial cells similar to that seen in the rat, but there was also staining of some intermediate cells (Fig. 2a). These positive-staining intermediate cells have been reported by Lin et al (11) and were directly adjacent to positive-staining superficial cells. In contrast to the rat, there was a lack of uroplakin expression in intermediate cells and also in some superficial cells in the bladders of both groups of BBN-treated mice at week 12, even when the histology was normal by light microscopy. Further decreases in the proportion of uroplakin-positive superficial cells were seen in the simple hyperplasia in the BBN-treated groups (Fig. 2b). In the rat, the sequence of bladder carcinogenesis progresses through PN hyperplasia, papillomas, and finally, through low-grade, papillary carcinomas. In contrast, bladder carcinogenesis in mice administered BBN in the drinking water or by gavage progresses through a sequence characterized by mild simple hyperplasia, dysplasia, flat carcinoma *in situ*, and then invasive, nonpapillary, high-grade carcinoma. Three carcinomas *in situ* were found in the BBN-drinking water group at week 12, and invasive carcinoma was observed in 1 BBN-gavage-treated mouse at week 12 and in most mice of both BBN-treated groups at the end of the experiment. Only a few uroplakin-positive cells were observed in any of these *in situ* or invasive carcinomas (Fig. 2c).

Severe hydronephrosis was often found in mice that had been treated with BBN and that died during the course of the experiment, and by the end of the experiment, renal pelvic carcinomas also developed in response to both routes of BBN treatment. The uroplakin-expression pattern in the renal pelvis lesions was similar to that seen in the bladder—characterized by occasional luminal-lining cells that did not stain for uroplakins and few positive-staining intermediate cells in the early hyperplastic lesions (Fig. 2d). Cells in the pelvic carcinomas rarely stained for uroplakins. A similar pattern of staining was seen in the ureter. Occasional uroplakin expression was also observed in the cells lining the renal papilla.

The percentages of uroplakin-positive cells in the various bladder lesions are summarized in Table I. At the luminal surface, 100% of the superficial cells of control animals were uroplakin positive in the rat and mouse. BBN treatment caused a significant decrease in uroplakin expression in mouse urothelium in all lesions through carcinoma. Normal-appearing epithelium in these mice also showed significantly decreased uroplakin expression. The decreased expression was greater in the mouse than in the rat.

In nonluminal urothelial cells, the percentages of uroplakin-positive cells in control mice were higher than those in rats. Following BBN treatment, the number of uroplakin-positive cells significantly increased in the rat, but this number decreased in the mouse.

In the rat, several luminal-lining cells of papillary carcinomas showed uroplakin expression. Dysplasia and car-

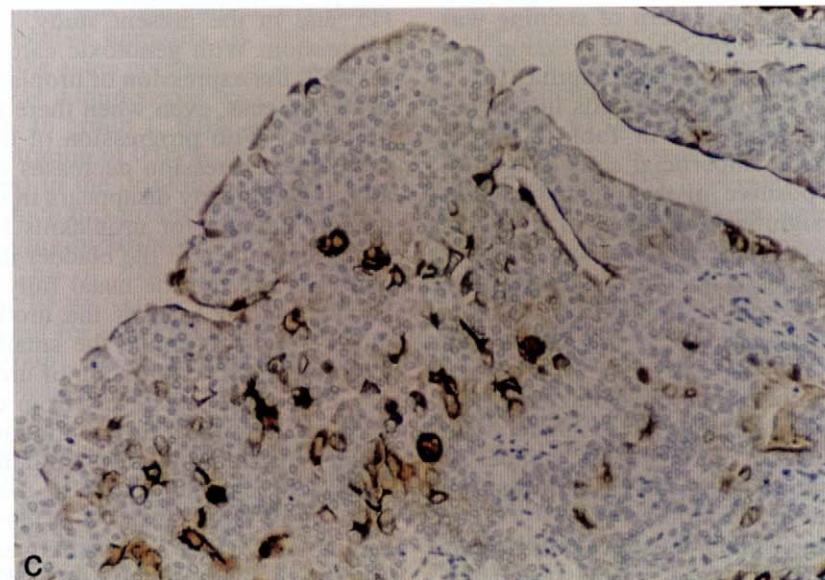
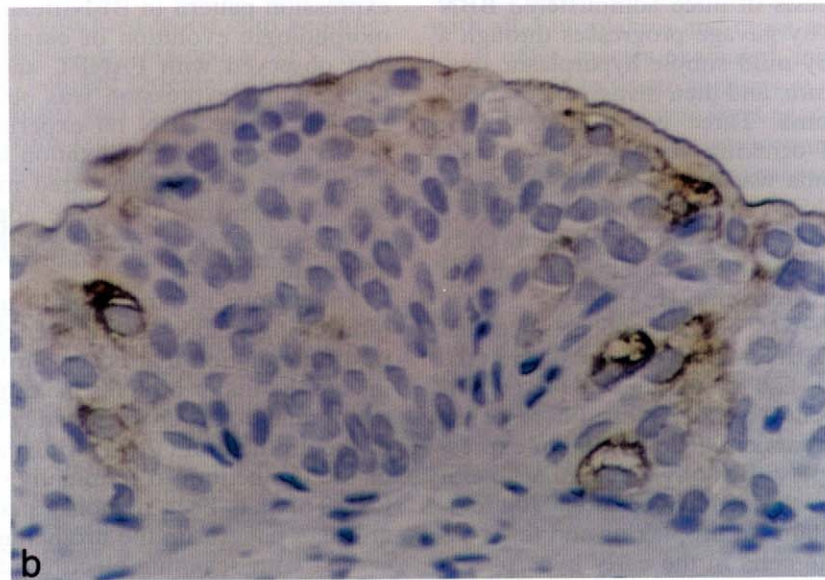
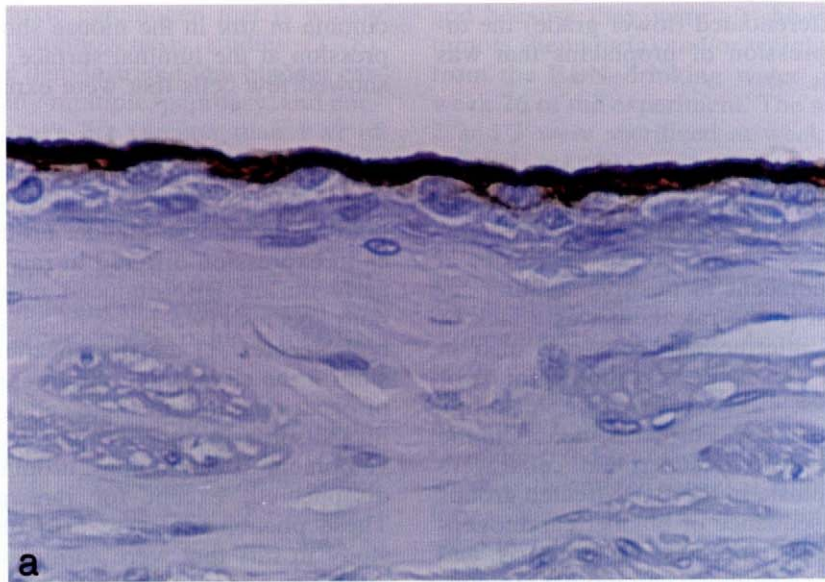
cinoma *in situ* in the mouse showed some uroplakin expression at the luminal surface, but invasive carcinomas showed few cells that were expressing uroplakin.

#### DISCUSSION

In the present experiment, we demonstrated alterations in uroplakin expression following BBN administration in both rat and mouse bladder urothelium. Although changes in expression differed in rats and mice, they appeared early during BBN-induced urothelial carcinogenesis in both species. Two types of changes were recognized in both species: 1) the disappearance of uroplakin expression in the cells lining the lumen; and 2) the appearance of occasional intermediate cells that expressed uroplakins in a disorderly and discontinuous pattern. With the development of carcinomas, uroplakin expression gradually disappeared, except for rare positively stained cells. These phenomena were also observed in our previous study in rats that were administered FANFT, uracil, sodium saccharin, or sodium ascorbate (13). The uroplakin-expression pattern in BBN-treated rat bladder during the morphologic evolution of carcinogenesis was similar to that observed with FANFT, another genotoxic carcinogen. Similar expression was observed, despite formalin fixation, in the BBN rat experiment, in contrast to that observed with Bouin's fixation in the FANFT rat experiment. The changes appeared more gradually and were less severe in rats that were administered nongenotoxic chemicals, such as uracil, sodium saccharin, or sodium ascorbate.

The change in expression of uroplakins in the urothelium during bladder carcinogenesis represents alterations in differentiation that occur during the process. Uroplakins are the major proteins making up the asymmetric unit membrane that is characteristic of terminal differentiation of the urothelium (17). During carcinogenesis, the ability of the urothelium to terminally differentiate is gradually lost. This has been demonstrated by the loss of the microridge pattern on the urothelial luminal surface, as observed with scanning electron microscopy (1, 9), by the loss of fusiform vesicles with asymmetric unit membrane (1), and in the present study, by the loss of uroplakin expression. With genotoxic carcinogens such as BBN or FANFT, the expression of uroplakins decreases very early in the process, even when there is only slight simple hyperplasia. With progression of the lesions to carcinoma, uroplakin expression decreases markedly, and occasionally, it completely disappears in invasive carcinomas. Although staining for uroplakins is discontinuous in cells lining the lumen of the bladder in hyperplasia, these cells generally are not the usual fully differentiated "umbrella" superficial cells of the urothelium, but rather, they more closely resemble the smaller intermediate cells of the urothelium. Expression of uroplakins in these cells or in intermediate cells away from the lumen may represent aborted attempts at differentiation. The lack of AUM indicates that terminal differentiation has not occurred.

Bladder carcinogenesis in the rat, when induced by BBN or FANFT, usually produces low-grade papillary carcinomas. These only infrequently become invasive or high-grade in nature, and they do so at much later times



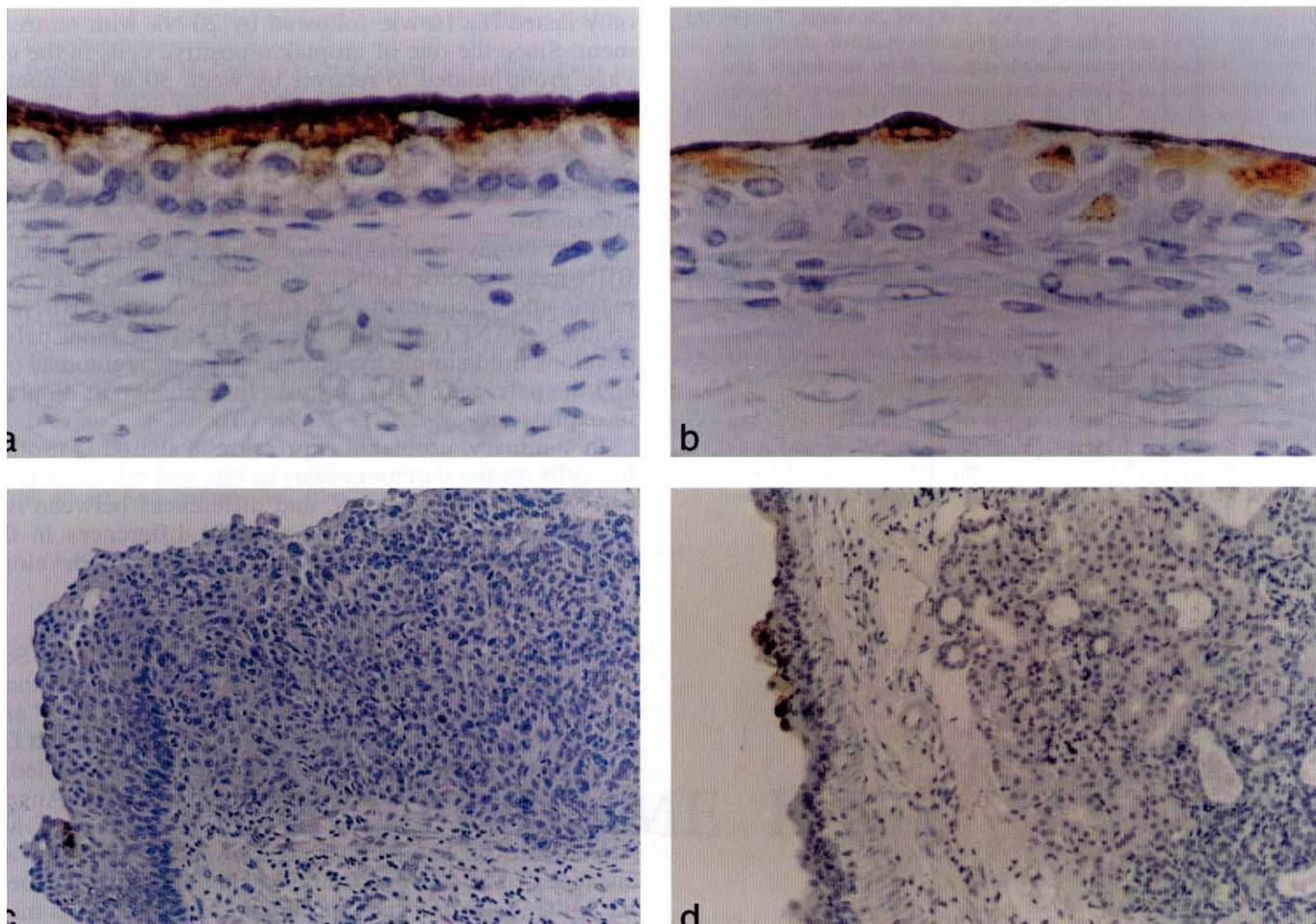


FIG. 2.—Immunohistochemical staining for uroplakins in mice: (a) In control bladder, not only superficial cells but also intermediate cells express uroplakins; (b) in a bladder with simple hyperplasia induced by BBN administration by gastric gavage, lack of expression in the luminal-lining cells and intermittent expression in the intermediate cells is observed; (c) in bladder with invasive TCC induced by BBN administration in the drinking water, some positive-staining luminal-lining cells are seen in the hyperplasia but not in the TCC; (d) in renal pelvis with hyperplasia induced by BBN administration by drinking water, discontinuous staining for uroplakins is observed in the urothelium.

than the length of time of the present experiment allowed (3, 8). These tumors most closely resemble low-grade papillary bladder carcinomas in humans. The presence of some uroplakin expression in these tumors is indicative of the well-differentiated nature of the lesions. In contrast, bladder carcinogenesis in BBN-treated mice, whether the BBN is administered in the drinking water or by gavage, produces hyperplasia, with the rapid appearance of dysplasia and carcinoma *in situ*. The bladder tumors that result are high-grade, nonpapillary, invasive carcinomas (2) that are similar to the nonpapillary bladder tumors of humans. Given the poorly differentiated nature of these lesions, even early on during carcinogenesis, it

is not surprising that uroplakin expression is more severely and more rapidly lost than in the rat model.

In the present study, the loss of uroplakin expression appeared to be more severe in the mice given BBN by drinking water than in those given BBN by gavage. BBN administration via drinking water also caused a higher incidence of invasive bladder carcinoma, compared with BBN administered by gavage. This might be related to the total doses of BBN that were provided by administration of BBN in the drinking water compared with the doses provided by gavage administration. Also, BBN was continuously administered for the entire experiment in the drinking water group, whereas the gavage treatment

←

FIG. 1.—Immunohistochemical staining for uroplakins in rats: (a) In control bladder, expression is clearly observed at the luminal surface and occasionally in the cytoplasm of superficial cells; (b) in a bladder with PN-hyperplasia induced by BBN administration in the drinking water, most superficial cells and some intermediate cells express uroplakins; and (c) in a bladder with papillary TCC induced by BBN administration in the drinking water, disorderly expression is observed in nonluminal cells.

TABLE I.—The percentage of uroplakin-positive cells in the various lesions in rats and mice.

Species	Week	Treatment	Percentage of labeled cells lining the lumen				Percentage of labeled cells that are nonluminal			
			Normal	Simple hyperplasia	PN hyperplasia or dysplasia	TCC	Normal	Simple hyperplasia	PN hyperplasia or dysplasia	TCC
Rat	20	BBN drinking	100 ± 0	94.4 ± 14.2	95.8 ± 5.9	82.3 ± 13.8 <sup>b,c</sup>	4.5 ± 2.1	14.7 ± 5.8 <sup>d,e</sup>	15.2 ± 7.8 <sup>d,e</sup>	13.4 ± 12.4 <sup>b,c</sup>
Rat	11–20	Control	100 ± 0	—	—	—	7.7 ± 5.2	—	—	—
Mouse	12	BBN drinking	42.0 ± 38.7 <sup>d</sup>	33.2 ± 25.6 <sup>d</sup>	2.3 ± 4.9 <sup>d,e</sup>	11.5 ± 10.0 <sup>a,d,f</sup>	0.8 ± 1.6 <sup>d</sup>	1.1 ± 2.2 <sup>d</sup>	0 ± 0 <sup>d</sup>	0.8 ± 1.4 <sup>d,f</sup>
Mouse	12	BBN gavage	63.3 ± 26.7 <sup>d</sup>	63.7 ± 26.4 <sup>d</sup>	14.0 ± 16.9 <sup>d,e</sup>	0 <sup>d,e,g</sup>	0.9 ± 0.7 <sup>d</sup>	5.0 ± 6.4 <sup>d</sup>	0.3 ± 0.5 <sup>d</sup>	0 <sup>d,g</sup>
Mouse	12	Control	100 ± 0	—	—	—	44.0 ± 6.1	—	—	—
Mouse	26	BBN drinking	6.2 <sup>d</sup>	17.3 ± 19.6 <sup>d</sup>	0 <sup>d</sup>	2.4 ± 5.3 <sup>d,g</sup>	0 <sup>d</sup>	0.4 ± 0.8 <sup>d</sup>	0 ± 0 <sup>d</sup>	0.6 ± 2.7 <sup>d,g</sup>
Mouse	30	BBN gavage	100	82.3 ± 19.2 <sup>b</sup>	11.6 ± 16.4 <sup>d,e</sup>	0 ± 0 <sup>d,e</sup>	20.5 <sup>d</sup>	12.2 ± 7.5 <sup>d</sup>	0 ± 0 <sup>d,h</sup>	0 ± 0 <sup>d,g,h</sup>
Mouse	30	Control	100 ± 0	—	—	—	48.4 ± 7.0	—	—	—

<sup>a</sup> Papillary tumor.

<sup>b</sup> Significantly different ( $p < 0.01$ ) from control group of same species.

<sup>c</sup> Significantly different ( $p < 0.05$ ) from normal-appearing urothelium of same treatment.

<sup>d</sup> Significantly different ( $p < 0.001$ ) from control group of same species.

<sup>e</sup> Significantly different ( $p < 0.001$ ) from normal-appearing urothelium of same treatment.

<sup>f</sup> Carcinoma *in situ*.

<sup>g</sup> Invasive tumor.

<sup>h</sup> Significantly different ( $p < 0.01$ ) from normal-appearing urothelium of same treatment.

only lasted for 10 wk, followed by 20 wk with no treatment. Since the rate of uroplakin-positive cells in the gavage group tended to recover by week 30 in the nontumorous epithelium, compared with what was observed at week 12, the alteration of uroplakin expression in simple hyperplasia appears to be partially reversible, which corresponds to the reversibility of the early histopathologic alterations.

Interestingly, uroplakin expression was also altered in BBN-treated mouse kidney pelvis, which reflects the dysplastic and carcinomatous changes produced by BBN. In contrast, FANFT- or BBN-treated F344 rat renal pelvis develops mild simple hyperplasia but not carcinomas (4), and the pelvic urothelium shows little change in uroplakin expression.

In summary, uroplakin expression is altered in urothelial cells during carcinogenesis in rats and mice and is an early event in the process, and differences between rats and mice correlate with the striking differences in the grade (differentiation) of the malignancies that develop.

#### ACKNOWLEDGMENTS

This work was supported by U.S. Public Health Service grants CA32513 and CA36727 from the National Cancer Institute as well as grants DK39753 and DK47529 from the National Institute of Diabetes and Digestive and Kidney Diseases. We gratefully acknowledge the advice and constructive comments of Drs. Angela Mann and Eva Uzvolgyi, the technical support of Mr. Mohamad Khachab and Ms. Traci Anderson, and the assistance of Ms. Carolyn Clark, Michelle Moore, and Denise Miller, who assisted with the preparation of this manuscript.

#### REFERENCES

1. Arai M, Kani T, Sugihara S, Matsumura K, Miyata Y, Shinohara Y, and Ito N (1974). Scanning and transmission electron microscopy of changes in the urinary bladder in rats treated with *N*-butyl-*N*-(4-hydroxybutyl)nitrosamine. *Gann* 65: 529–540.
2. Becci PJ, Thompson HJ, Strum JM, Brown CC, Sporn MB, and Moon RC (1981). *N*-butyl-*N*-(4-hydroxybutyl)nitrosamine-induced urinary bladder cancer in C57BL/6 X DBA/2F<sub>1</sub> mice as a useful model for study of chemoprevention of cancer with retinoids. *Cancer Res.* 41: 927–932.
3. Cohen SM (1983). Pathology of experimental bladder cancer in rodents. In: *The Pathology of Bladder Cancer*, Vol. 2, GT Bryan and SM Cohen (eds), CRC Press, Boca Raton, Florida, pp. 1–40.
4. Cohen SM, Ellwein LB, Okamura T, Masui T, Johansson SL, Smith RA, Wehner JM, Khachab M, Chappel CI, Schoenig GP, Emerson JL, and Garland EM (1991). Comparative bladder tumor promoting activity of sodium saccharin, sodium ascorbate, related acids, and calcium salts in rats. *Cancer Res.* 51: 1766–1777.
5. Ertürk E, Cohen SM, and Bryan GT (1970). Urinary bladder carcinogenicity of *N*-[4-(5-nitro-2-furyl)-2-thiazolyl]formamide in female Swiss mice. *Cancer Res.* 30: 1309–1311.
6. Ertürk E, Price JM, Morris JE, Cohen S, Leith RS, Von Esch AM, and Crovetti AJ (1967). The production of carcinoma of the urinary bladder in rats by feeding *N*-[4-(5-nitro-2-furyl)-2-thiazolyl]formamide. *Cancer Res.* 27: 1998–2002.
7. Hsu SM, Raine L, and Fanger H (1981). Use of avidin-biotin-peroxidase complex (ABC) in immunoperoxidase techniques: A comparison between ABC and unlabeled antibody (PAP) procedures. *J. Histochem. Cytochem.* 29: 577–580.
8. Ito N, Hiasa Y, Tamai A, Okajima E, and Kitamura H (1969). His-

- togenesis of urinary bladder tumors induced by *N*-butyl-*N*-(4-hydroxybutyl)nitrosamine in rats. *Gann* 60: 401–410.
9. Jacobs JB, Arai M, Cohen SM, and Friedell GH (1976). Early lesions in experimental bladder cancer: Scanning electron microscopy of cell surface markers. *Cancer Res.* 36: 2512–2517.
  10. Lin J-H, Wu X-R, Kreibich G, and Sun T-T (1994). Precursor sequence, processing, and urothelium-specific expression of a major 15-kDa protein subunit of asymmetric unit membrane. *J. Biol. Chem.* 269: 1775–1784.
  11. Lin J-H, Zhao H, and Sun T-T (1995). A tissue-specific promoter that can drive a foreign gene to express in the suprabasal urothelial cells of transgenic mice. *Proc. Natl. Acad. Sci. USA* 92: 679–683.
  12. Martin RA, Daly AM, Difonzo CJ, and de la Iglesia FA (1984). Randomization of animals by computer program for toxicity studies. *J. Am. Coll. Toxicol.* 3: 1–11.
  13. Ogawa K, Sun T-T, and Cohen SM (1996). Analysis of differentiation associated proteins in rat bladder carcinogenesis. *Carcinogenesis* 17: 961–965.
  14. SAS Institute, Inc. (1989). *SAS/STAT User's Guide*, version 6, Vol. 2, 4th ed. SAS Institute, Inc., Cary, North Carolina.
  15. Walz T, Häner M, Wu X-R, Henn C, Engel A, Sun T-T, and Aebi U (1995). Towards the molecular architecture of the asymmetric unit membrane of the mammalian urinary bladder epithelium: A closed "twisted ribbon" structure. *J. Mol. Biol.* 248: 887–900.
  16. Wu X-R, Lin J-H, Walz T, Häner M, Yu J, Aebi U, and Sun T-T (1994). Mammalian uroplakins: A group of highly conserved urothelial differentiation-related membrane proteins. *J. Biol. Chem.* 269: 13716–13724.
  17. Wu X-R, Manabe M, Yu J, and Sun T-T (1990). Large scale purification and immunolocalization of bovine uroplakins I, II and III. *J. Biol. Chem.* 265: 19170–19179.
  18. Wu X-R and Sun T-T (1993). Molecular cloning of a 47 kDa tissue-specific and differentiation-dependent urothelial cell surface glycoprotein. *J. Cell Sci.* 106: 31–43.
  19. Yu J, Lin J-H, Wu X-R, and Sun T-T (1994). Uroplakins Ia and Ib, two major differentiation products of bladder epithelium, belong to a family of four transmembrane domain (4TM) proteins. *J. Cell Biol.* 125: 171–182.
  20. Yu J, Manabe M, Wu X-R, Xu C, Surya B, and Sun T-T (1990). Uroplakin I: A 27-kDa protein associated with the asymmetric unit membrane of mammalian urothelium. *J. Cell Biol.* 111: 1207–1216.



## STP HOME PAGE

Visit the World Wide Web Home Page for the  
Society of Toxicologic Pathologists:

<http://www.toxpath.org>

Contents include: headline news; information about membership; a listing of upcoming meetings; and information about *Toxicologic Pathology*, the official publication of the Society; as well as other STP publications.

