

Açaí (*Euterpe oleracea* Mart.) feeding attenuates dimethylhydrazine-induced rat colon carcinogenesis



Mariana F. Fragoso^a, Guilherme R. Romualdo^b, Daniel A. Ribeiro^c, Luis F. Barbisan^{b,*}

^aUNESP - Univ. Estadual Paulista, School of Medicine, Program of Post-Graduation in Pathology, Botucatu 18618-970, SP, Brazil

^bUNESP - Univ. Estadual Paulista, Institute of Biosciences, Department of Morphology, Botucatu 18618-970, SP, Brazil

^cUNIFESP, Federal University of Sao Paulo, Department of Biosciences, 11060-001 Santos, SP, Brazil

ARTICLE INFO

Article history:

Received 29 January 2013

Accepted 2 April 2013

Available online 15 April 2013

Keywords:

Aberrant crypt foci

Spray-dry

Açaí pulp

Colon carcinogenesis

ABSTRACT

This study investigated the protective effect of spray-dried açai powder (AP) intake on colon carcinogenesis induced by 1,2-dimethylhydrazine (DMH) in male Wistar rats. After 4 weeks of DMH administrations, the groups were fed with standard diet, a diet containing 2.5% or 5.0% AP or a diet containing 0.2% N-acetylcysteine (NAC) for 10 weeks, using aberrant crypt foci (ACF) as the endpoint. Additionally, two groups were fed with standard diet or a diet containing 5.0% AP for 20 weeks, using colon tumors as the endpoint. In ACF assay, a reduction in the number of aberrant crypts (ACs) and ACF (1–3 AC) were observed in the groups fed with 5.0% AP (37% AC and 47% ACF inhibition, $p = 0.036$) and 0.2% NAC (39% AC and 41% ACF inhibition, $p = 0.042$). In tumor assay, a reduction in the number of invasive tumors ($p < 0.005$) and tumor multiplicity ($p = 0.001$) was observed in the group fed with 5.0% AP. Also, a reduction in tumor Ki-67 cell proliferation ($p = 0.003$) and net growth index ($p = 0.001$) was observed in the group fed with 5.0% AP. Therefore the findings of this study indicate that AP feeding may reduce the development of chemically-induced rat colon carcinogenesis.

© 2013 Elsevier Ltd. All rights reserved.

1. Introduction

Colon cancer is a significant cause of cancer mortality among men and women in industrialized societies, including Australia, New Zealand, Europe and North America (Siegel et al., 2012). In Brazil, this malignancy is the third and fourth most frequent cancer diagnosed in women and men, respectively (INCA, 2012). This disease emerges through a multi-step process via a hyperplasia–adenoma–carcinoma sequence, involving the accumulation of numerous genetic and epigenetic alterations (Cappell, 2008; Watson and Collins, 2011). Experimental and epidemiologic evidence indicate that lifestyle and dietary habits have been associated with up- or down-regulation of the risk factors for colon cancer development (Watson and Collins, 2011; Lofano et al., 2012). Furthermore, there are several non-modified risk factors that include genetic predispositions (i.e., Lynch Syndrome and Familial Adenomatous Polyposis) and chronic inflammation of the bowel, such as ulcerative colitis and Crohn's disease) and diabetes (Watson and Collins, 2011; ACS, 2011).

During chemically induced colon carcinogenesis, ACF has been recognized as an early surrogate preneoplastic lesion (Bird and

Good, 2000; Yoshimi et al., 2004; Mori et al., 2004; Alrawi et al., 2006). In addition, ACF has been identified in human post-mortem and colonoscopy screening studies. Therefore, ACF may be considered a suitable biomarker for adenoma recurrence in high-risk patients (Pretlow et al., 1992; Takayama et al., 2005; Gupta and Schoen, 2009). Due to morphological and genetic similarities in ACF development between rodents and humans, this preneoplastic lesion may be used in cancer screening and prevention studies for the detection of risk factors and protective factors associated with colon cancer progression or recurrence (Corpet and Taché, 2002; Corpet and Pierre, 2005; Femia and Caderni, 2008). Colon cancer chemoprevention may be achieved by consumption of dietary substances that prevent, inhibit or reverse the risk of developing this malignancy (Corpet and Taché, 2002; Das et al., 2007). Because various compounds from fruits and vegetables have antioxidant and anti-inflammatory properties, they are believed to be protective against colon cancer initiation and progression (Das et al., 2007; Arikawa and Gallaher, 2008; Dias et al., 2010; Moura et al., 2012). Especially, some *in vitro* and *in vivo* studies have been focused on the anti-tumor properties of food-derived polyphenols (D'Archivio et al., 2008; Guo et al., 2009; Link et al., 2010; Araújo et al., 2011).

In the family Arecaceae and genus *Euterpe*, the species *Euterpe oleracea*, *Euterpe edulis* and *Euterpe precatória* are referred to as “açai” (Poulose et al., 2012). The açai species *E. oleracea* Mart. is an exotic fruit that, when mature, turns from green to dark purple

* Corresponding author. Address: Departamento de Morfologia, Instituto de Biociências, Universidade Estadual Paulista (UNESP), 18618-0970 Botucatu, SP, Brazil. Tel.: +55 14 38800469.

E-mail address: barbisan@ibb.unesp.br (L.F. Barbisan).

with a single seed covered by a small edible pulp that represents approximately 13–15% of the fruit (Schauss et al., 2006a,b). It is originally a native of Central and South America and grows in the foodplains of the Amazon region (Rodrigues et al., 2006; Carvalho, 2010). It has become an important crop produced and consumed in Brazil and one of the main exports of the Amazon estuary (Schauss et al., 2006a,b; Carvalho, 2010). Over the past years, açai has gained popularity as a functional food ingredient that can be consumed *in natura* or in a variety of beverages and food preparations (Mertens-Talcott et al., 2008; Schauss et al., 2010) because of its colorant and antioxidant/anti-inflammatory properties (Hogan et al., 2010; Poulouse et al., 2012). Açai is known to possess high amounts of polyphenols, especially anthocyanin and proanthocyanidin (mainly cyanidin 3-O-glucoside and cyanidin 3-O-rutinoside) (Gallori et al., 2004; Schauss et al., 2006a,b; Rodrigues et al., 2006; Poulouse et al., 2012). Given its benefits to human health, in order to extend the shelf life and preserve the pigment stability of açai, which is otherwise a highly perishable fruit, a spray-drying technique can be used to produce açai powder with high anthocyanin content (Tonon et al., 2010).

Due to the increased popularity of açai consumption (Vidigal et al., 2011; Menezes et al., 2011) and the lack of studies on its anti-tumor property in chemically induced rodent cancer models (Stoner et al., 2010; Fragoso et al., 2012), the present study was conducted to investigate the potential protective effect of spray-dried açai powder (AP) against rat colon carcinogenesis using ACF formation and tumor development as the end-points.

2. Materials and methods

2.1. Animals and treatment

All experiments were conducted in accordance with the Ethical Principles for Animals Research adopted by the Brazilian College of Animal Experimentation (COBEA). The experimental protocols were approved by the local University Ethics Committee for Animal Research (protocol number CEEA 881-2011). Male Wistar rats with 4-week-old were obtained from Centro de Tecnologia do Paraná (TECPAR, Araucaria PR, Brazil). The animals were housed in polypropylene cages covered with metallic grids in a room maintained at $22 \pm 2^\circ\text{C}$ and $55 \pm 10\%$ humidity under a 12-h light–dark cycle. After a 2-week acclimation period, the animals were randomly distributed based on the age and body weight into groups for two experiments (Fig. 1): For the 14-week ACF assay, groups G1–G4 (10 rats/group) received four s.c. injections of DMH (40 mg/kg) twice a week for 2 weeks and group G5 (05 rats) received similar injections of EDTA (DMH vehicle). After 4 weeks of initiation of colon carcinogenesis, the groups were fed with standard diet (G1), standard diet containing 2.5% AP (G2), standard diet containing 5.0% AP (G3 and G5) or standard diet containing 0.2% N-acetylcysteine (NAC) (G4), which is an antioxidant and anticarcinogenic agent (Seril et al., 2002; Amrouche-Mekkioui and Djerdjouri, 2012), for 10 weeks. At the end of the dietary açai regimen, groups G1–G5 were sacrificed for the ACF assay. For the 24-week tumor assay, groups G6 and G7 (10 rats/group) were induced to initiation of colon carcinogenesis as described above. After 4 weeks of tumor initiation, the animals were maintained on the standard diet (G6) or the standard diet containing 5.0% AP (G7) for 20 weeks. Groups G6 and G7 were then sacrificed for histopathology analysis and the colon tumor assay. A cereal-based commercial diet that was specifically formulated according to National Research Council's recommendation to supply rodent nutritional needs (National Research Council, 1995) was purchased from Nuvital (NUVILAB CR1, chow, Pr, Brazil). The animals in both experiments were sacrificed by exsanguination under sodium pentobarbital anaesthesia (45 mg/kg body weight). Individual body weight and food consumption were recorded twice a week throughout the two experimental periods.

Frozen açai pulps were obtained from Belém, PA, Brazil and spray-dried using an industrial scale spray-dryer system with maltodextrin DE10 as a carrier agent (Fig. 2). Açai pulp powder was produced and kindly donated by Centroflora Group Brazil (Botucatu, SP, Brazil) with the following characteristics: moisture at 6%, volumetric density at 350–650 g/l and total polyphenol content at $\geq 0.5\%$ (Fragoso et al., 2012).

2.2. Colon processing and histopathological analysis

At necropsy, the colon was removed, opened longitudinally and rinsed with saline to eliminate residual bowel contents. It was then flattened and fixed in 10% buffered formalin for 24 h at room temperature. Afterwards, the colon was stained

with 1.0% methylene blue dissolved in phosphate-buffered saline (PBS) for the quantitative analysis of classical ACF (Dias et al., 2010; Moura et al., 2012). ACF were identified according to Bird's criteria (Bird and Good, 2000). The number of ACF with 1–3 aberrant crypts (ACs) or ≥ 4 AC, as well as the number of total ACs and total ACF were analyzed. In addition, all of the colons were Swiss-rolled (4–6 segments with 2-mm widths) and embedded in paraffin.

Histological evaluation was carried out on haematoxylin–eosin (HE)-stained colon sections and ACF were classified as conventional or dysplastic lesions according to Yoshimi et al. (2004). The tumors were classified as adenomas or adenocarcinomas according to Hamilton and Aaltonen (2000). In addition, the colonic adenocarcinomas were sub-classified into invasive and non-invasive types (i.e., based on tumor cell invasion into the submucosa and muscularis) and their incidences (% rats with tumor) were assessed.

2.3. Immunohistochemistry protocol

The protein expression levels of Ki-67 (i.e., cell proliferation marker), cleaved caspase-3 (i.e., apoptosis marker) and β -catenin and connexin 43 (Cx43) (i.e., tumor progression markers) in the colon tumors were detected immunohistochemically using a polymer system (MACH 4 Universal HRP polymer Detection, Biocare, CA, USA). Briefly, deparaffinated 5 μm colon tumor sections on silanized slides were treated sequentially with 0.01 M citrate buffer (pH 6.0) at 120°C for 5 min in a Pascal Pressure Chamber (Dako Cytomation Denmark A/S), 3% H_2O_2 in PBS for 10 min, nonfat milk for 60 min, either mouse anti-Ki-67 (1:100 dilution, Abcam ab16667, Cambridge, MA 02139), rabbit polyclonal cleaved anti-caspase-3 (clone Asp 175, 1:100 dilution, Cell Signaling Technology, Inc., Danvers, MA, USA), rabbit polyclonal anti- β -catenin (clone ab6302, Abcam, MA, USA) or rabbit polyclonal anti-Cx43 (clone GJA1, Abcam, MA, USA) antibodies overnight at 4°C , the mouse probe for 30 min at room temperature and the HRP polymer for another 30 min at room temperature (Moura et al., 2012). Chromogenic development was accomplished with 3,3'-diaminobenzidine tetrahydrochloride (Sigma–Aldrich, Co, USA). The slides were counterstained with Harris's haematoxylin.

2.4. Ki-67, cleaved caspase-3, β -catenin and connexin 43 analysis

Ki-67 and cleaved caspase-3 were evaluated by counting at least 500 tumor cells. The indices of cell proliferation and apoptosis were calculated as percentages of positively stained cells in each tumor sample. To assess the degree to which cellular proliferation and apoptosis changes may affect the net growth potential of a colon tumor, a net Growth Index (GI%) was established as the cell proliferation index minus the apoptosis index (Cormier and Dove, 2000).

The *in situ* expression of β -catenin and Cx43 was evaluated in each colon tumor based on staining intensity and cellular localization (i.e., membrane, cytoplasm and nucleus) (Buhmeida et al., 2008; Kanczuga-Koda et al., 2010).

2.5. Statistical analysis

The data for body weight gain, food consumption, ACF and tumor multiplicity, were compared among the groups using one-way ANOVA test. Differences among the groups were analyzed by the Tukey method. The cell proliferation and apoptosis indexes and tumor multiplicity were compared between groups using *t*-test or Mann–Whitney test. In addition, the incidences of conventional and dysplastic ACF, altered β -catenin and Cx43 expression were compared using Chi-square test, whereas the incidence of non-invasive and invasive colon tumors was analyzed using Fischer exact test. The differences among the groups were considered significant when $p < 0.05$. All statistical analyses were performed using the Jandel Sigma Stat software (Jandel Corporation, San Rafael, CA, USA).

3. Results

3.1. General findings

The AP-fed animals looked healthy throughout the experimental period. No significant alterations in body weight, body weight gain or food consumption associated with AP feeding (G2, G3 and G7) were observed when compared to the groups receiving only standard diet (G1 and G6) in both ACF and Tumor assays (Table 1). Macroscopic examinations of the stomach, intestines, kidneys and liver did not reveal any apparent toxicity associated with AP after the 14- and 24-week feeding studies.

3.2. Colonic preneoplastic lesions (ACF assay)

The data on the modifying effect of AP powder intake on colonic ACF development are summarized in Table 2. All DMH-initiated

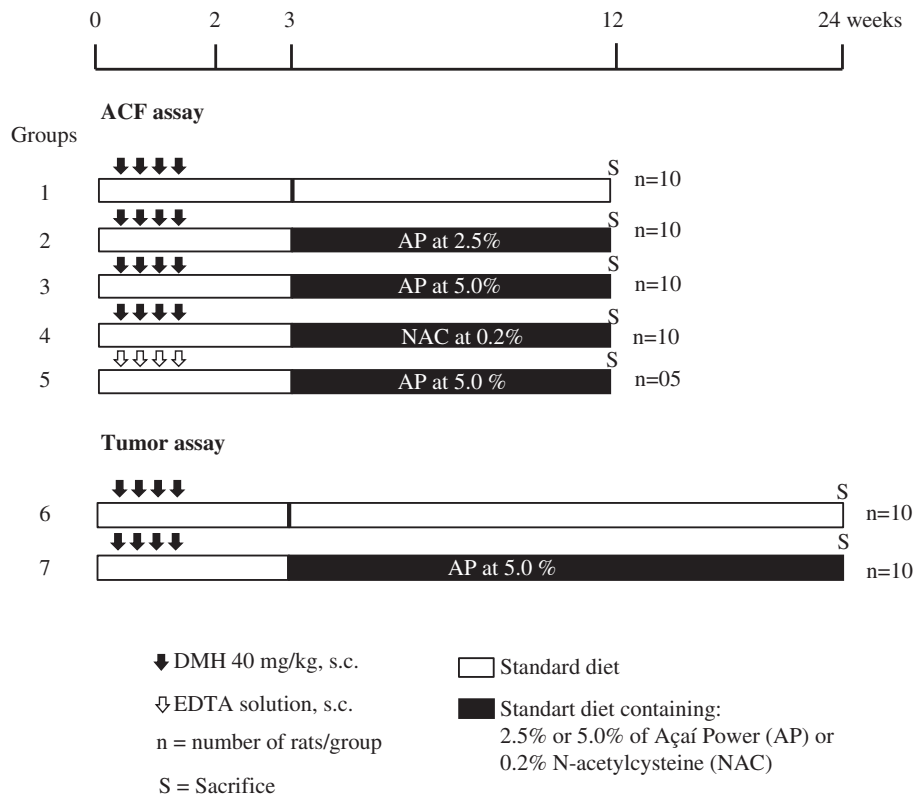


Fig. 1. Experimental design (for details see Materials and Methods).

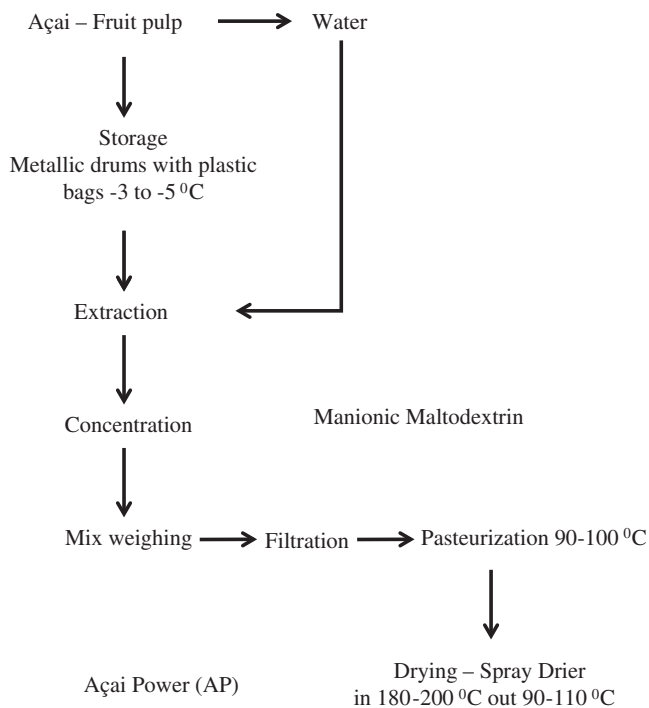


Fig. 2. Flow chart of the spray-dried açai powder production, provided by the CENTROFLORA – ANIDRO DO BRASIL Company.

groups developed ACF in the colons (G1–G4) (Fig. 3A) whereas no evidence of ACF formation was detected in the colons from the vehicle-treated group receiving only 5.0% AP (G5). In the 14-week ACF assay, AP feeding significantly reduced the number of total AC

in the groups that received 5.0% AP (G3) (37% inhibition) and 0.2% NAC (G4) (39% inhibition) when compared with the untreated group (G1) ($p = 0.036$). Furthermore, the development of ACF (1–3 AC) was significantly reduced in groups G3 and G4 by 47% and 41%, respectively ($p = 0.042$). In addition to the ACF stereological analysis, five macroscopic tumors were collected and histologically analyzed (Table 3).

3.3. Histopathological analysis (tumor assay)

The numbers and incidences of non-invasive and invasive colon tumors are presented in Table 3. The data on the colon tumors detected in the ACF assay were also included.

At the time of sacrifice, the tumors were collected for histopathological analysis. They were classified into invasive, noninvasive, well-differentiated or poorly differentiated tumors. A total of five tumors were obtained in the ACF assay (14 week-study). They belonged to the untreated group (G1) (4 tumors) and the group that was fed with 2.5% AP (G2) (1 tumor), and 75% of them were classified as noninvasive tumors. In the 24-week tumor assay, the untreated group (G6) developed invasive (80%) (Fig. 3B) and noninvasive (20%) tumors whereas the group that received 5.0% AP (G7) developed only noninvasive tumors (100%) ($p = 0.005$). Additionally, most of the tumors in the untreated group (G6) were histologically classified as high-grade tumors (Fig. 3C). A significant reduction ($p = 0.001$) in tumor multiplicity (noninvasive and invasive tumors) was observed in the group that received 5.0% AP (G7) when compared with the untreated group (G6) (14 and 24-week studies). Furthermore, premalignant dysplastic ACF were observed in both the untreated group (G6) and the group fed with 5.0% AP (G7) without any statistically significant difference by Chi-square test (data not shown).

Table 1

Effects of spray-dried açai powder (AP) intake on body weight and food and water consumption parameters in different groups.

Parameters	Treatment ^a				
	DMH-initiated				Non-initiated
	Untreated	2.5% AP	5.0% AP	NAC	AP 5.0%
Groups	G1	G2	G3	G4	G5
14-week study	10 ^b	10	10	10	05
Final body weight (g)	352.85 ± 16.57	354.18 ± 16.42	352.70 ± 16.25	352.00 ± 16.22	353.24 ± 16.31
Body-weight gain (g)	174.09 ± 4.53	183.55 ± 7.96	201.50 ± 11.66	207.5 ± 8.87	200.00 ± 11.17
Food consumption (g/rat/day) ^c	27.60 ± 0.29	27.49 ± 0.42	27.24 ± 0.55	27.58 ± 0.461	27.42 ± 0.60
Water consumption (mL/rat/day)	67.59 ± 8.02	69.23 ± 5.55	70.76 ± 6.40	69.68 ± 3.73	66.99 ± 5.81
AP consumption (g/rat/day)	0	0.69 ± 0.03	1.36 ± 0.11	0	1.37 ± 0.10
Groups	G6		G7		
24-week study	10		10		
Final body weight (g)	416.47 ± 14.83	–	420.48 ± 15.45	–	–
Body-weight gain (g)	230.90 ± 16.56	–	248.10 ± 14.71	–	–
Food consumption (g/rat/day) ^c	25.52 ± 0.41	–	27.39 ± 0.39	–	–
Water consumption (mL/rat day)	56.20 ± 2.04	–	52.21 ± 2.06	–	–
AP consumption (g/rat/day)	0	–	1.35 ± 0.07	–	–

Values are mean ± S.E.

^a DMH = 1,2-dimethylhydrazine dihydrochloride (4 × 40 mg/kg b.wt., s.c.); AP = 2.5% or 5.0% spray-dried açai powder in the standard diet for 10 or 20 weeks.^b Final number of animals.^c Measure introduced at the beginning of dietary AP administration. For all parameters, $p > 0.05$ using one-way ANOVA.**Table 2**

Effects of spray-dried açai pulp (AP) intake on the development of colonic aberrant crypt foci (ACF) in a 14-week study.

Group/treatment ^a	Number of rats	Number of ACF		Total number	
		1–3 AC ^b /colon	≥4 AC/colon	AC/colon	ACF/colon
<i>DMH-initiated</i>					
(G1) Untreated	10	201.45 ± 28.22	75.90 ± 10.20	735.00 ± 96.58	251.00 ± 37.07
(G2) 2.5% AP	10	163.20 ± 21.99	72.95 ± 14.35	700.35 ± 63.03	228.80 ± 31.37
(G3) 5.0% AP	10	105.90 ± 9.33*	50.35 ± 11.35	460.75 ± 102.20**	180.05 ± 15.65
(G4) 0.2% NAC	10	119.15 ± 13.33*	46.35 ± 7.82	449.10 ± 57.93**	158.15 ± 18.21
<i>Non-initiated</i>					
(G5) 5.0% AP	05	0	0	0	0

Values are mean ± S.E.

^a DMH = 1,2-dimethylhydrazine dihydrochloride (4 × 40 mg/kg b.wt., s.c.); AP = 2.5% and 5.0% spray-dried açai powder in the standard diet for 10 weeks; NAC = 0.2% N-acetylcysteine in the standard diet for 10 weeks.^b AC = aberrant crypt.* Different from the G1 group, $p = 0.042$, using one-way ANOVA test.** Different from the G1 group, $p = 0.036$, using one-way ANOVA test.

3.4. Analyses of β -catenin, connexin 43, cell proliferation and apoptosis

The in situ expression of Ki-67, cleaved caspase-3, β -catenin and Cx43 was analyzed in all colon tumor sections (Figs. 3D2, E2 and F, 4A and B). β -catenin and Cx43 were markedly expressed in the cell membrane of epithelial cells in the normal colonic mucosa (Fig. 3D1 and E1), as previously described (Buhmeida et al., 2008; Kanczuga-Koda et al., 2010). Also in accordance with previous studies, most of the tumors showed altered expression of β -catenin and Cx43 (Fig. 3D2, E2 and F).

Most of the colon tumors expressed altered levels of β -catenin in the cytoplasm and the nucleus. However, there was no significant difference in β -catenin expression between colon tumor samples from the untreated group (G6) and the group that was fed with 5.0% AP (G7) using Chi-square test (data not shown). A reduced expression of Cx43 was observed in both noninvasive and invasive colon tumors in comparison with its membranous expression in normal colon mucosa (Fig. 3E2 and F). Additionally, aberrant cytoplasmic β -catenin and Cx43 expression in the colon tumors was frequently observed at the borders of invasion (Fig. 3D2, E2 and F).

The indices of positivity for both tumor Ki-67 ($p = 0.003$) and cleaved caspase-3 ($p = 0.041$) were lower in the group that received 5.0% AP (G7) when compared with the untreated group (G6) (Fig. 4C

and D). Moreover, a lower growth index ($p = 0.001$) was registered in the group fed with 5.0% AP (G7, GI% = 47.45 ± 6.34) when compared to the untreated group (G6, GI% = 69.51 ± 6.03).

4. Discussion

The findings of the present study provide the first evidence that AP feeding attenuates the colon carcinogenesis process. Our findings consist of two main points: First, the magnitude of the inhibitory effect on ACF development was very similar to that of the classic antioxidant and anticarcinogenic agent N-acetylcysteine (Seril et al., 2002; Amrouche-Mekkioui and Djerdjouri, 2012); Second, a clear anti-tumor effect was specifically characterized by a reduction in the cell proliferation, multiplicity and invasiveness of chemically induced colon tumors. In addition, AP intake did not show any signs of toxicity on the animals according to their weight gain profiles and food consumption, further demonstrating that AP is a safe and functional food ingredient for cancer chemoprevention studies, as we previously described (Fragoso et al., 2012).

Among the natural products that can potentially inhibit the multistage process of colon carcinogenesis, polyphenols have been considered a suitable choice for cancer prevention especially

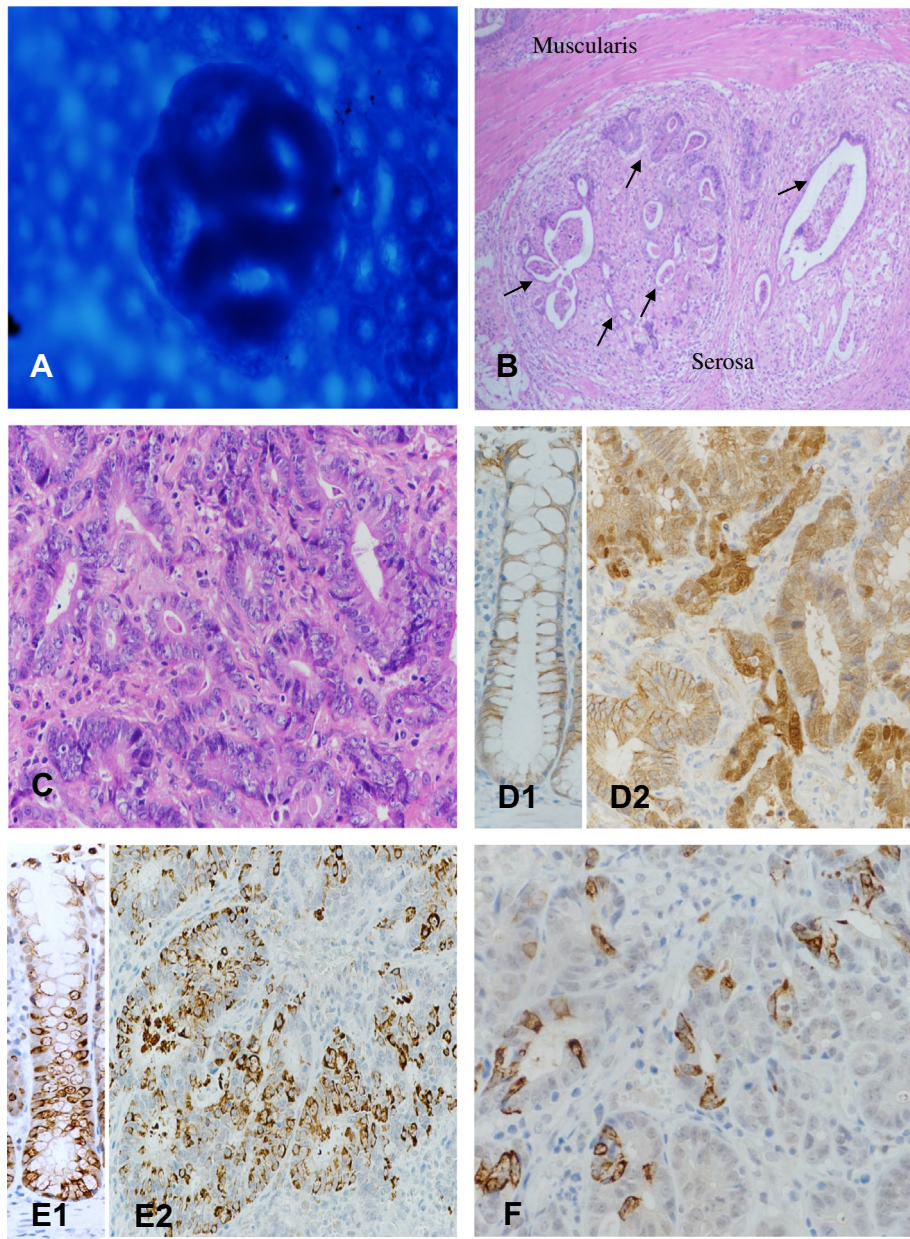


Fig. 3. (A) Representative topographic view of classic ACF in a methylene blue-stained colon whole-mount containing five aberrant crypts; (B) representative microscopic view of one invasive colon tumor detected in HE-stained sections, showing small tubular units lined by tumor cells (arrows) (20× objective); (C) detailed microscopic view of a histologically high-grade invasive colon tumor; (D1) typical cell membrane expression of β -catenin in a non-altered colonic crypt; (D2) aberrant β -catenin expression in an invasive colon tumor; (E1) typical cell membrane expression of connexin 43 in a non-altered colonic crypt; (E2) altered connexin 43 expression in a non-invasive colon tumor; (F) reduced expression of connexin 43 in an invasive colon tumor. A 20× objective was used in B photomicrography picture and a 40× objective was used for the others photomicrographs.

because of their antioxidant properties (Kang et al., 2011; Gollucke et al., 2013). Polyphenols, including anthocyanins, are categorized as chemopreventive agents because they can quench or prevent the formation of reactive oxygen and nitrogen species that can drive genetic mutations, genomic instability and ultimately carcinogenesis in different target organs (Tsao, 2010; Kang et al., 2011; Gollucke et al., 2013).

Açaí is an exotic fruit rich in polyphenols and known to possess proper anti-oxidant and anti-inflammatory properties (Schauss et al., 2006a,b; Mertens-Talcott et al., 2008; Hogan et al., 2010). Its major polyphenolic compound is anthocyanin, which is the water-soluble pigment that accounts for the fruit's attractive color and that has shown many biological activities including antioxidant,

anti-inflammatory and anticancer activities in different *in vivo* and *in vitro* systems (Wang and Stoner, 2008; He and Giusti, 2010). Thus, the high anthocyanin content in açaí pulps may be responsible for the potential cancer-preventive activity of AP, as observed in this chemically induced rat colon carcinogenesis model. In fact, others studies using anthocyanin-rich extracts have demonstrated protective effects against development of ACF and colon tumor (Lala et al., 2006; Cai et al., 2010) and antiproliferative effects in different colon tumor cell lines (Kang et al., 2003; Jing et al., 2008; Wang et al., 2013), including potential to reduction in mRNA expression of β -catenin and c-Myc, downstream of Wnt pathway (Wingless and Integration = Wnt) (Wang et al., 2013). These colon biomarkers (i.e., ACF, tumor development, cell proliferation and β -catenin

Table 3
Effects of spray-dried açai powder (AP) intake on colon tumor development in the DMH-initiated animals.

Group/treatment ^a	Number of rats ^b	14-Week study		24-Week study		Multiplicity 14/24-week study (mean ± S.E)
		Non-invasive (%)	Invasive (%)	Non-invasive (%)	Invasive (%)	
(G1/G6) Untreated	10/10	75 (3) ^c	25 (1)	20 (2)	80 (8)	0.73 ± 0.10 (14)
(G3/G7) 5.0% AP	10/10	0	0	100 (4)	0*	0.20 ± 0.09** (4)
(G2) 2.5% AP	10/0	100 (1)	0	–	–	–
(G4) 0.2% NAC	05/0	0	0	–	–	–

^a DMH = 1,2-dimethylhydrazine dihydrochloride (4 × 40 mg/kg b.wt., s.c.); AP = 2.5% and 5.0% spray-dried açai powder in the standard diet for 20 weeks; NAC = 0.2% N-acetylcysteine in the standard diet for 20 weeks.

^b Number of animals at 14/24-week study.

^c Total number of colon tumors.

* Different from G1 group, $p = 0.005$ using Fisher Exact test (incidence of non-invasive and invasive tumors) and Mann–Whitney test (tumor multiplicity), respectively.

** Different from G1 group, $p < 0.001$ using Fisher Exact test (incidence of non-invasive and invasive tumors) and Mann–Whitney test (tumor multiplicity), respectively.

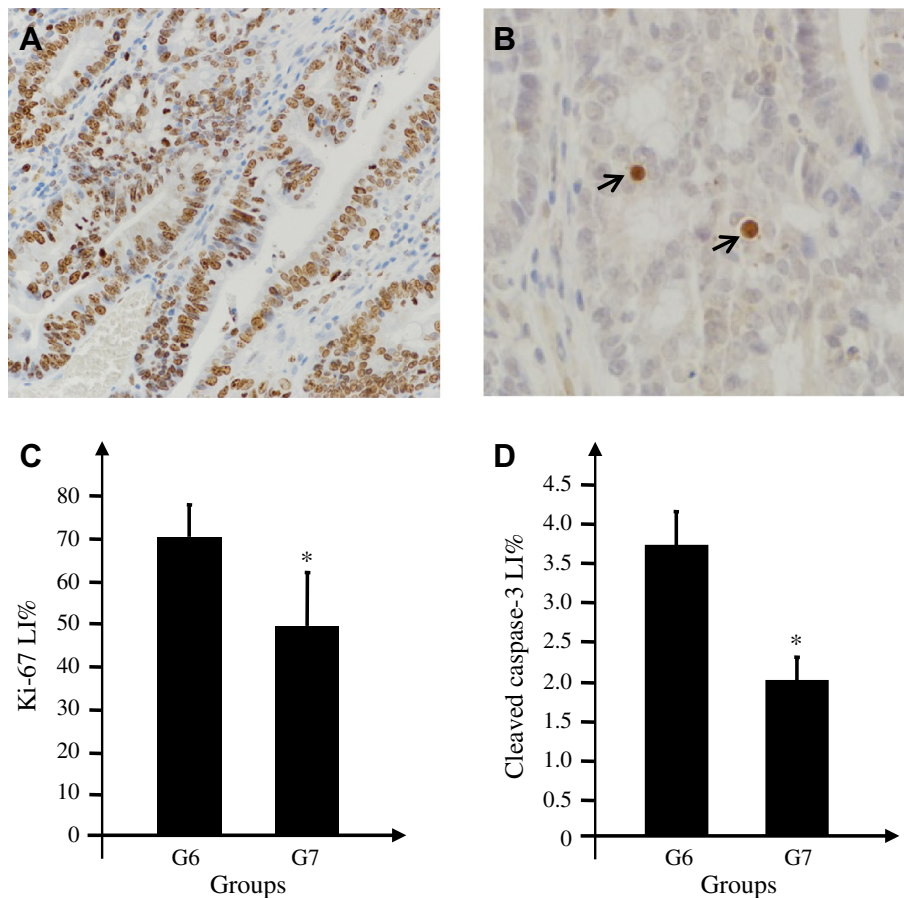


Fig. 4. (A) Representative Ki-67 immunostaining (brown nuclei) in a colon tumor (40× objective); (B) representative cleaved caspase-3 immunostaining (brown apoptotic cells or apoptotic bodies) in a colon tumor (60× objective, arrows); (C) Ki-67 labelling indices in tumor sections from the untreated group (G6) and the group fed with 5.0% AP (G7); (D) cleaved caspase-3 labelling indices in tumor sections from the untreated group (G6) and the group fed with 5.0% AP (G7). *Different from the G6 group, $p = 0.003$ (Ki-67) and $p = 0.041$ (cleaved caspase-3), using *t*-test.

expression were endpoints used here to characterize the beneficial effects from AP against rat colon carcinogenesis.

The detection of colonic preneoplastic/precancerous lesions is essential for clarification of the mechanisms of tumor progression or prevention of colon cancer occurrence (Bird and Good, 2000; Corpet and Taché, 2002; Mori et al., 2004; Femia and Caderni, 2008). ACF are putative preneoplastic lesions easily detected in unsectioned colons under methylene-blue staining and have been fairly consistent predictors of colon tumor outcomes in cancer prevention studies in rodents (Corpet and Taché, 2002; Femia and Caderni, 2008; Arikawa and Gallaher, 2008). In the 14-week ACF

assay, a significant reduction in ACF development was observed in the animals fed with 5.0% AP (G3) or 0.2% NAC (G4), especially in terms of the number of ACFs. Therefore, our results demonstrate that dietary intake of 5.0% AP attenuates the promotion stage of DMH-induced colon carcinogenesis in male Wistar rats.

The number and multiplicity of ACF are major determinants of the risk for developing colon cancer (Takayama et al., 2005; Alrawi et al., 2006). Although numerical reductions in both AC and small ACF (1–3 AC) were observed in the group of animals fed with 5.0% AP, a few ACF may still give rise to putative dysplastic lesions and colon tumors (Mori et al., 2004). Thus, the effectiveness of AP's

influence on colon cancer promotion should be further investigated, mainly with long-term bioassays for tumor development because a low number of colon tumors were detected in our 14-week feeding study.

DMH is a potent mutagen and carcinogen used in different chemically induced colon carcinogenesis rodent models (Newell and Heddle, 2004; Femia and Caderni, 2008). Mimicking the development of sporadic human colon cancer, DMH exposure induces adenomas and adenocarcinomas in the middle and distal colon rather than the proximal colon (Bird and Good, 2000; Yoshimi et al., 2004; Femia and Caderni, 2008). Cell proliferation may lead to an increased risk of developing cancer whereas apoptosis is a protective innate mechanism for eliminating cells with DNA damage or genomic instability (Hanahan and Weinberg, 2011). In addition, an increase in both cell proliferation and apoptosis relative to the normal mucosa during the development of colon tumors in rats has been documented (Meleń-Mucha and Niewiadomska, 2002). In our 24-week tumor assay, a significant reduction in the cell proliferation indices and in incidence of invasive tumors and tumor multiplicity were observed in the groups fed with 5.0% AP compared with the control group. Thus, dietary açai at 5.0% has the potential to inhibit tumor growth and invasiveness by reducing the imbalance between cell proliferation and cell loss because these processes play key roles in carcinogenesis and tumor progression (Hanahan and Weinberg, 2011).

The progressive imbalance between cell proliferation and apoptosis during the transformation of colonic epithelium into the malignant phenotype has been described (Anti et al., 2001). In addition, high apoptotic cell counts have been associated with high histological grades and poor prognoses in colon cancer (Hilksa et al., 2005). The present study showed that apoptotic indices were lower in colon tumors from the 5.0% AP group than from the untreated group. Since that the apoptotic index increases with tumor grade and aggressiveness in certain cancers (Liu et al., 2001; Hilksa et al., 2005), it is possible that a lower apoptotic index in colon tumors from the 5.0% AP group indirectly corroborates with the conventional morphology-based histological grading system.

The Wnt pathway is one of the main pathways linked to colon cancer development (Klaus and Birchmeier, 2008; Burgess et al., 2011). It is directly associated with cell proliferation and activated as soon as β -catenin is translocated to the nucleus. The pathway is aberrantly activated when APC is mutated and becomes inefficient in degrading the β -catenin complex (Akiyama, 2000). Once inside the nucleus, β -catenin can bind to TCF (T Cell Factor) and LEF1 (Lymphoid Enhancer-binding Factor 1) to signal cell proliferation (Klaus and Birchmeier, 2008; Jamieson et al., 2012). In the 24-week feeding study, the colon tumors showed altered β -catenin expression characterized by a loss or reduction of the protein at the cell-to-cell borders but an over-expression in the cytoplasm and nucleus. No significant difference in the *in situ* expression of β -catenin was observed in the colon tumors between the untreated group and the group fed with 5.0% AP, which is most likely due to the small number of tumors observed in the latter group.

Connexins are a family of gap junction proteins that form intermembranous aqueous channels for the exchange of ions, metabolites, nucleotides and other small signalling molecules between cells (Trosko and Ruch, 2002; Cronier et al., 2009). The gap junctional intercellular communication (GJIC) is an important factor in the maintenance of tissue homeostasis, proliferation, differentiation and development (Trosko and Ruch, 2002; Cronier et al., 2009). GJIC is characterized by an intercellular channel formatted by two hemichannels, the connexons, and their six transmembrane protein subunits called the connexins (Trosko and Ruch, 2002; Cronier et al., 2009). There are six different connexins (Cx26, Cx30, Cx32, Cx40, Cx43 and Cx45), which are responsible for the selective permeability of the plasma membrane in a tissue-specific fashion

(van der Heyden et al., 1998; Trosko and Ruch, 2002; Cronier et al., 2009).

Aberrant Cx43 expression has been found in different types of tumors, including lung, mammary, colon and liver (Yamasaki and Naus, 1996; van der Heyden et al., 1998; Trosko and Ruch, 2002; Cronier et al., 2009; Sirnes et al., 2012). In all the cited cases, Cx43 expression in tumor cells was either lost or aberrantly expressed (Yamasaki and Naus, 1996; Kanczuga-Koda et al., 2010). The most studied connexins in colon cancer are Cx32 and Cx43 (Kanczuga-Koda et al., 2010; Han et al., 2011; Sirnes et al., 2012). Cx43 appears to be downregulated in colon tumors, which may lead to a loss of cell-cell communication. Thus, Cx43 is classified as a tumor suppressor protein due to the loss of its function in regulating intercellular trafficking activity during carcinogenesis (Han et al., 2011; Sirnes et al., 2012). Aberrant expression and activity of Cx43 might be caused by many factors in addition to gene mutations, such as (i) the loss of connexin transcriptional genes; (ii) the loss of connexin mRNA; and (iii) the accumulation of Cx43 in the cytoplasm due to a loss of its membrane targeting signal (van der Heyden et al., 1998; Han et al., 2011). In our 24-week feeding study, the colon tumors exhibited altered Cx43 expression characterized by a loss or reduction of the protein at the cell membrane, but an anomalous expression pattern in the cytoplasm was clearly detected in both the untreated group and the group receiving 5.0% AP.

Sirnes and collaborators (2012) have demonstrated that colon cancer cells cannot form Cx43 gap junction channels and that the loss of Cx43 expression is correlated with a poor prognosis in patients with colorectal cancer. When Cx43 is absent from the membrane, it can be localized in the cytoplasm in a granular form and, then, may be degraded by lysosomes, leading to the aberrant regulation of intercellular trafficking (Sirnes et al., 2012). As detected in our study, the cytoplasmic accumulation of Cx43 was frequently observed at the borders of invasion in the tumor samples from the untreated group, indicating that this abnormality may be associated with tumor invasiveness and may serve as a potential target for cancer prevention measures (Trosko and Ruch, 2002).

A relationship between Cx43 and the Wnt pathway has been previously described, showing that Cx43 colocalises with β -catenin in HT29 cells and that Cx43 is also capable of reducing β -catenin-mediated gene transcription (Sirnes et al., 2012). Thus, both Cx43 and β -catenin expression changes are early events in colon carcinogenesis (Kanczuga-Koda et al., 2010; Sirnes et al., 2012). In the present study, there was either a lack of membranous distribution of Cx43 or a shift to predominantly cytoplasmic accumulation of Cx43 in both the untreated group and the group receiving 5.0% AP. In contrast, cytoplasmic accumulations of both β -catenin and Cx43 were frequently observed at the borders of invasion from the tumor samples of the untreated group, indicating that such changes may be associated with tumor progression and invasiveness (van der Heyden et al., 1998).

In summary, our findings suggest that spray-dried açai powder, when fed at the concentration of 5.0%, significantly attenuates DMH-induced early and late colon carcinogenesis in male rats. Further investigations on the chemopreventive mechanisms against colon carcinogenesis by dietary açai must still be conducted.

Conflict of Interest

The authors declare that there are no conflicts of interest.

Acknowledgments

This study was supported by Coordenação de Aperfeiçoamento de Pessoal de Nível Superior (CAPES). Mariana F. Fragoso and Guilherme R. Romualdo were recipients of fellowships from CAPES and

Conselho Nacional de Desenvolvimento Científico e Tecnológico (CNPq/PIBIC), respectively.

References

- American Cancer Society. Colorectal Cancer: Facts and Figures 2011–2013. United States of America, 2011. <<http://www.cancer.org/Research/CancerFactsFigures/ColorectalCancerFactsFigures/colorectal-cancer-facts-figures-2011-2013>> (accessed in 2.8.11).
- Akiyama, T., 2000. Wnt/ β -catenin signaling. *Cytokine & Growth Factors Reviews* 11, 273–282.
- Alrawi, S.J., Schiff, M., Carroll, R.E., Dayton, M., Gibbs, J.F., Kulavlat, M., Anderson, G.R., 2006. Aberrant Crypt Foci. *Anticancer Research* 120, 107–119.
- Amrouche-Mekkioui, I., Djerdjouri, B., 2012. N-acetylcysteine improves redox status, mitochondrial dysfunction, mucin-depleted crypts and epithelial hyperplasia in dextran sulfate sodium-induced oxidative colitis in mice. *European Journal of Pharmacology* 691, 209–217.
- Anti, M., Armuzia, A., Morinid, S., Iaconea, E., Pignataro, G., Cocob, C., Lorenzetti, R., Paoluccia, M., Covino, M., Gasbarrina, A., 2001. Severe imbalance of cell proliferation and apoptosis in the left colon and in the rectosigmoid tract in subjects with a history of large adenomas. *Gut* 48, 238–246.
- Araújo, J.R., Gonçalves, P., Martel, F., 2011. Chemopreventive effect of dietary polyphenols in colorectal cancer cell lines. *Nutrition Research* 31, 77–87.
- Arikawa, A.Y., Gallaher, D.D., 2008. Cruciferous vegetables reduce morphological markers of colon cancer risk in dimethylhydrazine-treated rats. *Journal of Nutrition* 138, 526–532.
- Bird, R.P., Good, C.K., 2000. The significance of aberrant crypt foci in understanding the pathogenesis of colon cancer. *Toxicology Letters* 112–113, 395–402.
- Buhmeida, A., Elzagheid, A., Algars, A., Collan, Y., Syrjänen, K., Pyrhönen, S., 2008. Expression of the cell–cell adhesion molecule β -catenin in colorectal carcinomas and their metastases. *APMIS: Acta Pathologica, microbiologica, et Immunologica Scandinavica* 116, 1–9.
- Burgess, A.W., Faux, M.C., Layton, M.J., Ramsay, R.G., 2011. Wnt signaling and colon tumorigenesis – a view from the periphery. *Experimental Cell Research* 317, 2748–2758.
- Cai, H., Marcylo, T.H., Teller, N., Brown, K., Stward, W.P., Marko, D., Gescher, A.J., 2010. Anthocyanin-rich red grape extract impedes adenoma development in the Apc (Min) mouse: pharmacodynamic changes and anthocyanin levels in the murine biophase. *European Journal of Cancer* 46, 811–817.
- Cappell, M.S., 2008. Pathophysiology, clinical presentation, and management of colon cancer. *Gastroenterology Clinics of North America* 37, 1–24.
- Carvalho, A.V. (Ed.), 2010. Agência de Informação Embrapa: açaí. <<http://www.agencia.cnptia.embrapa.br/gestor/acai/Abertura.html>> (accessed in 18.2.11).
- Cormier, R.T., Dove, W.F., 2000. Dnmt1N/1 reduces the net growth rate and multiplicity of intestinal adenomas in C57BL/6-multiple intestinal neoplasia (Min)/1 mice independently of p53 but demonstrates strong synergy with the modifier of Min 1AKR resistance allele. *Cancer Research* 60, 3965–3970.
- Corpet, D.E., Pierre, F., 2005. How good are rodent models of carcinogenesis in predicting efficacy in humans? A systematic review and meta-analysis of colon chemoprevention in rats, mice and men. *European Journal of Cancer* 41, 1911–1922.
- Corpet, D.E., Taché, S., 2002. Most effective colon cancer chemopreventive agents in rats: a systematic review of aberrant crypt foci and tumor data, ranked by potency. *Nutrition and Cancer* 43, 1–21.
- Cronier, L., Crespin, S., Strale, P.O., Defamie, N., Mesnil, M., 2009. Gap junctions and cancer: new functions for an old story. *Antioxidants & Redox Signaling* 11, 323–338.
- D'Archivio, M., Santangelo, C., Scazzocchio, B., Vari, R., Filesi, C., Masella, R., Giovannini, C., 2008. Modulatory effects of polyphenols on apoptosis induction: relevance for cancer prevention. *International Journal of Molecular Sciences* 9, 213–228.
- Das, D., Arber, N., Jankowski, J.A., 2007. Chemoprevention of colorectal cancer. *Digestion* 76, 51–67.
- Dias, M.C., Vieira, N.F.L., Gomes, M.I.F.V., Salvadori, D.M.F., Rodrigues, M.A.M., Barbisan, L.F., 2010. Effects of lycopene, synbiotic and their association on early biomarkers of rat colon carcinogenesis. *Food and Chemical Toxicology* 48, 772–780.
- Femia, A.P., Caderni, G., 2008. Rodent models of colon carcinogenesis for the study of chemopreventive activity of natural products. *Planta Medica* 74, 1602–1607.
- Fragoso, M.F., Prado, M.G., Barbosa, L., Rocha, N.S., Barbisan, L.F., 2012. Inhibition of mouse urinary bladder carcinogenesis by açai fruit (*Euterpe oleracea* Martius) intake. *Plant Foods for Human Nutrition* 67, 235–241.
- Gallori, S., Bilia, A.R., Bergonzi, M.C., Barbosa, W.L.R., Vincieri, F.F., 2004. Polyphenolic constituents of fruit pulp of *Euterpe oleracea* Mart. (açai palm). *Chromatographia* 59, 739–743.
- Gollucke, A.P.B., Aguiar Jr, O., Barbisan, L.F., Ribeiro, D.A., 2013. Use of grape polyphenols against carcinogenesis: putative molecular mechanisms of action using in vitro and in vivo systems. *Journal of Medicinal Food* 16, 199–205.
- Guo, W., Kong, E., Meydani, M., 2009. Dietary polyphenols, inflammation, and cancer. *Nutrition and Cancer* 61, 807–810.
- Gupta, A.K., Schoen, R.E., 2009. Aberrant crypt foci: are they intermediate endpoints of colon carcinogenesis in humans? *Current Opinion in Gastroenterology* 25, 59–65.
- Hamilton, S.R., Aaltonen, L.A., 2000. World Health Organization Classification of Tumors Pathology and Genetics, vol. 6. IARC Press, pp. 103.
- Han, Y., Zhang, P.J., Chen, T., Yum, S.W., Pasha, T., Furth, E.E., 2011. Connexin 43 expression increases in the epithelium and stroma along the colonic neoplastic progression pathway: implications for its oncogenic role. *Gastroenterology Research and Practice* 2011, 5617–5619.
- Hanahan, D., Weinberg, R.A., 2011. Hallmarks of cancer: the next generation. *Cell* 144, 646–674.
- He, J., Giusti, M.M., 2010. Anthocyanins: natural colorants with health-promoting properties. *Annual Review of Food Science and Technology* 1, 163–187.
- Hilska, M., Collan, Y.U., O Laine, V.J., Kössi, J., Hirsimäki, P., Laato, M., Roberts, P.J., 2005. The significance of tumor markers for proliferation and apoptosis in predicting survival in colorectal cancer. *Disease of the Colon and Rectum* 48, 2197–2208.
- Hogan, S., Chung, H., Zhang, L., Li, J., Lee, Y., Dai, Y., Zhou, K., 2010. Antiproliferative and antioxidant properties of anthocyanin-rich extract from açai. *Food Chemistry* 118, 208–214.
- INCA – Instituto Nacional do Câncer – Estatística sobre a incidência de câncer colorretal na população brasileira, 2012. Brasil. <http://www.inca.gov.br/estimativa/2010/index.asp?link=conteudo_view.asp&ID=5> (Accessed 2.8.12).
- Jamieson, C., Sharma, M., Henderson, B.R., 2012. Wnt signaling from membrane to nucleus: β -Catenin caught in a loop. *The International Journal of Biochemistry & Cell Biology* 44, 847–850.
- Jing, P., Bomser, J.A., Schwartz, S.J., He, J., Magnuson, B.A., Giusti, M.M., 2008. Structure-function relationships of anthocyanins from various anthocyanin-rich extracts on the inhibition of colon cancer cell growth. *Journal of Agricultural and Food Chemistry* 56, 9391–9398.
- Kanczuga-Koda, L., Koda, M., Sulkowicz, S., Winiewicz, A., Zalewski, B., Sulkowska, M., 2010. Gradual loss of functional gap junction within progression of colorectal cancer – a shift from membranous CX32 and CX43 expression to cytoplasmic pattern during colorectal carcinogenesis. *In Vivo* 24, 101–107.
- Kang, S.Y., Seeram, N.P., Nair, M.G., Bourquin, L.D., 2003. Tart cherry anthocyanins inhibit tumor development in Apc (Min) mice and reduce proliferation of human colon cancer cells. *Cancer Letters* 194, 13–19.
- Kang, N.J., Shin, S.H., Lee, H.J., Lee, K.W., 2011. Polyphenols as small molecular inhibitors of signaling cascades in carcinogenesis. *Pharmacology & Therapeutics* 130, 310–324.
- Klaus, A., Birchmeier, W., 2008. Wnt signalling and its impact on development and cancer. *Nature reviews Cancer* 8, 387–398.
- Lala, G., Malik, M., Zhao, C., He, J., Kwon, Y., Giusti, M.M., Magnuson, B.A., 2006. Anthocyanin-rich extracts inhibit multiple biomarkers of colon cancer in rats. *Nutrition and Cancer* 54, 84–93.
- Link, A., Balaguer, F., Goel, A., 2010. Cancer chemoprevention by dietary polyphenols: promising role for epigenetics. *Biochemical Pharmacology* 80, 1771–1792.
- Liu, S., Edgerton, S.M., Moore 2nd, D.H., Thor, A.D., 2001. Measures of cell turnover (proliferation and apoptosis) and their association with survival in breast cancer. *Clinical Cancer Research* 7, 1716–1723.
- Lofano, K., Principi, M., Scavo, M.P., Pricci, M., Ierardi, E., Di Leo, A., 2012. Dietary lifestyle and colorectal cancer onset, recurrence, and survival: myth or reality? *Journal of Gastrointestinal Cancer (Epub ahead of print)*.
- Melen-Mucha, G., Niewiadomska, H., 2002. Frequency of proliferation, apoptosis, and their ratio during rat colon carcinogenesis and their characteristic pattern in the dimethylhydrazine-induced colon adenoma and carcinoma. *Cancer Investigation* 20, 700–712.
- Menezes, E., Deliza, R., Chan, H.L., Guinard, J.-X., 2011. Preferences and attitudes towards açai-based products among North American consumers. *Food Research International* 44, 1997–2008.
- Mertens-Talcott, S.U., Rios, J., Jilma-Stohlawetz, P., Pacheco-Palencia, L.A., Meibohm, B., Talcott, S.T., Derendorf, H., 2008. Pharmacokinetics of anthocyanins and antioxidant effects after the consumption of anthocyanin-rich açai juice and pulp (*Euterpe oleracea* Mart.) in human healthy volunteers. *Journal of Agricultural and Food Chemistry* 56, 7796–7802.
- Mori, H., Yamada, Y., Kuno, T., Hirose, Y., 2004. Aberrant crypt foci and β -catenin accumulated crypts; significance and roles for colorectal carcinogenesis. *Mutation Research* 566, 191–208.
- Moura, N.A., Caetano, B.F.R., Sivieri, K., Urbano, L.H., Cabello, C., Rodrigues, M.A.M., Barbisan, L.F., 2012. Protective effects of yacon (*Smallanthus sonchifolius*) intake on experimental colon carcinogenesis. *Food and Chemical Toxicology* 50, 2902–2910.
- National Research Council, 1995. Nutrient requirements of the laboratory rat. In: National Research Council. *Nutrient Requirements of Laboratory Animals*, fourth ed. National Academy Press, Washington, DC, pp. 11–79.
- Newell, L.E., Heddle, J.A., 2004. The potent colon carcinogen, 1,2-dimethylhydrazine induces mutations primarily in the colon. *Mutation Research* 564, 1–7.
- Poulouse, S.M., Fisher, D.R., Larson, J., Bielinski, D.F., Rimando, A.M., Carey, A.N., Shukitt-Hale, B., 2012. Anthocyanin-rich açai (*Euterpe oleracea* Mart.) fruit pulp fractions attenuate inflammatory stress signaling in mouse brain BV-2 microglial cells. *Journal of Agricultural and Food Chemistry* 60, 1084–1093.
- Pretlow, T.P., O'Riordan, M.A., Pretlow, T.G., Stellato, T.A., 1992. Aberrant crypts in human colonic mucosa: putative preneoplastic lesions. *Journal of Cellular Biochemistry* 16G (Suppl), 55–62.
- Rodrigues, R.B., Lichtenthaler, R., Zimmermann, B.F., Papagiannopoulos, M., Fabricius, H., Marx, F., Almeida, O., 2006. Total oxidant scavenging capacity of *Euterpe oleracea* Mart. (açai) seeds and identification of their polyphenolic compounds. *Journal of Agricultural and Food Chemistry* 54, 4162–4167.

- Schauss, A.G., Wu, X., Prior, R.L., Ou, B., Huang, D., Owens, J., Shanbrom, E., 2006a. Antioxidant capacity and other bioactivities of the freeze-dried Amazonian palm berry, *Euterpe oleracea* mart. (acai). *Journal of Agricultural and Food Chemistry* 54, 8604–8610a.
- Schauss, A.G., Wu, X., Prior, R.L., Ou, B., Patel, D., Huang, D., Kababick, J.P., 2006b. Phytochemical and nutrient composition of the freeze-dried Amazonian palm berry, *Euterpe oleracea* mart. (acai). *Journal of Agricultural and Food Chemistry* 54, 8598–8603b.
- Schauss, A.G., Clewell, A., Balogh, L., Szakonyi, I.P., Financsek, I., Horváth, J., Hirka, G., 2010. Safety evaluation of an açai-fortified fruit and berry functional juice beverage (MonaVie Active®). *Toxicology* 278, 46–54.
- Seril, D.N., Liao, J., Ho, K.-L.K., Yang, C.S., Yang, G.-Y., 2002. Inhibition of chronic ulcerative colitis-associated colorectal adenocarcinoma development in a murine model by N-acetylcysteine. *Carcinogenesis* 23, 993–1001.
- Siegel, R., Naishadham, D., Jemal, A., 2012. Cancer statistics. *CA: A Cancer Journal for Clinician* 62, 10–29.
- Sirnes, S., Bruun, J., Kolberg, M., Kjenseth, A., Lind, G.E., Svindland, A., Brech, A., Nesbakken, A., Lothe, R.A., Leithe, E., Rivedal, E., 2012. Connexin 43 acts as a colorectal cancer tumor suppressor and predicts disease outcome. *International Journal of Cancer* 131, 570–581.
- Stoner, G.D., Wang, L.-S., Seguin, C., Rocha, C., Stoner, K., Chiu, S., Kinghorn, A.D., 2010. Multiple berry types prevent N-nitrosomethylbenzylamine-induced esophageal cancer in rats. *Pharmaceutical Research* 27, 1138–1145.
- Takayama, T., Miyanishi, K., Hayashi, T., Kukitsu, T., Takanashi, K., Ishiwatari, H., Kogawa, T., Abe, T., Niitsu, Y., 2005. Aberrant crypt foci: detection, gene abnormalities, and clinical usefulness. *Clinical Gastroenterology and Hepatology* 3, S42–45.
- Tonon, R.V., Brabet, C., Hubinger, M.D., 2010. Anthocyanin stability and antioxidant activity of spray-dried açai (*Euterpe oleracea* Mart.) juice produced with different carrier agents. *Food Research International* 43, 907–914.
- Trosko, J.E., Ruch, R.J., 2002. Gap junctions as targets for cancer chemoprevention and chemotherapy. *Current Drug Targets* 3, 465–482.
- Tsao, R., 2010. Chemistry and biochemistry of dietary polyphenols. *Nutrients* 2, 1231–1246.
- van der Heyden, M.A., Rook, M.B., Hermans, M.M., Rijkse, G., Boonstra, J., Defize, L.H., Destree, O.H., 1998. Identification of connexin 43 as a functional target for Wnt signalling. *Journal of Cell Science* 111, 1741–1749.
- Vidigal, M.C.T.R., Minim, V.P.R., Carvalho, N.B., Milagres, M.P., Gonçalves, A.C.A., 2011. Effect of a health claim on consumer acceptance of exotic Brazilian fruit juices: Açai (*Euterpe oleracea* Mart.), Camu-camu (*Myrciaria dubia*), Cajá (*Spondias lutea* L.) and Umbu (*Spondias tuberosa* Arruda). *Food Research International* 44, 1988–1996.
- Wang, L.S., Stoner, G.D., 2008. Anthocyanins and their role in cancer prevention. *Cancer Letters* 269, 281–290.
- Wang, L.S., Kuo, C.T., Cho, S.J., Seguin, C., Siddiqui, J., Stoner, K., Weng, Y.I., Huang, T.H., Tichelaar, J., Yearsley, M., Stoner, M.D., Huang, Y.W., 2013. Black raspberry-derived anthocyanins demethylate tumor suppressor genes through the inhibition of DNMT1 and DNMT3B in colon cancer cells. *Nutrition and Cancer* 65, 118–125.
- Watson, A.J., Collins, P.D., 2011. Colon cancer: a civilization disorder. *Digestive Disease* 29, 222–228.
- Yamasaki, H., Naus, C.C., 1996. Role of connexin genes in growth control. *Carcinogenesis* 17, 1199–1213.
- Yoshimi, N., Morioka, T., Kinjo, T., Inamine, M., Kaneshiro, T., Shimizu, T., Mori, H., 2004. Histological and immunohistochemical observations of mucin-depleted foci (MDF) stained with Alcian blue, in rat colon carcinogenesis induced with 1,2-dimethylhydrazine dihydrochloride. *Cancer Science* 95, 792–797.