

RESEARCH

Open Access

# The H<sub>2</sub>S-releasing naproxen derivative, ATB-346, inhibits alveolar bone loss and inflammation in rats with ligature-induced periodontitis

Bruno Schneider Herrera<sup>1,2</sup>, Leila Santana Coimbra<sup>2</sup>, Agatha Ribeiro da Silva<sup>1</sup>, Simone Aparecida Teixeira<sup>1</sup>, Soraia Katia Pereira Costa<sup>1</sup>, John Lawrence Wallace<sup>3</sup>, Luis Carlos Spolidorio<sup>2</sup> and Marcelo Nicolas Muscara<sup>1\*</sup>

## Abstract

**Background:** In experimental periodontitis, non-steroidal antiinflammatory drugs (NSAIDs) effectively inhibit the resultant alveolar bone loss. However, their deleterious gastric effects, observed in both animals and humans, dramatically limit their long-term use. It has been proven that the addition of a hydrogen sulfide (H<sub>2</sub>S)-releasing moiety to classical NSAID structures results in antiinflammatory compounds with improved gastric safeness. In this way, we decided to compare the effects of naproxen with its H<sub>2</sub>S-releasing derivative ATB-346 on ligature-induced periodontitis in rats.

**Methods:** Male Holtzman rats had a cotton ligature placed subgingivally around the lower right first molar during 7 days. During this period, groups of animals were daily treated with Na<sub>2</sub>S (a spontaneous H<sub>2</sub>S donor) or equimolar oral doses of naproxen (10 mg/kg) or ATB-346 (16 mg/kg). The mandibles were finally collected for histological analysis, radiographical measurements of alveolar bone loss and micro-computed tomography (μCT) analysis. Interleukin (IL)-1β, IL-6 and IL-10 were quantified in gingiva samples, and the stomachs were also collected for scoring of tissue damage and measurement of myeloperoxidase (MPO, a marker of granulocyte infiltration).

**Results:** Ligature-induced bone loss was significantly inhibited by all the treatments, although only ATB-346 treatment resulted in significant inhibition of bone defect and other histological characteristics (such as flatness of the gingival epithelium, chronic inflammatory cell infiltration and loss of connective tissue in the gingival papillae). Both naproxen and ATB-346 inhibited the increase of gingival IL-1β and IL-6 secondary to periodontitis, but IL-10 was unaffected. Significant damage and increased MPO contents were only found in the stomachs of the naproxen-treated animals.

**Conclusion:** The H<sub>2</sub>S-releasing moiety in the ATB-346 compound not only does not impair the effects of the parent naproxen on periodontitis, but also improves bone quality and prevents the gastric mucosa damage due to prostaglandin inhibition, thus configuring a potentially new adjuvant therapy for periodontal diseases.

**Keywords:** Periodontitis, Bone loss, ATB-346, H<sub>2</sub>S-releasing NSAID, Inflammation

\* Correspondence: muscara@usp.br

<sup>1</sup>Department of Pharmacology, Institute of Biomedical Sciences, University of Sao Paulo (USP), Sao Paulo, SP, Brazil

Full list of author information is available at the end of the article

## Introduction

Periodontitis is a chronic inflammatory disease and a major public health concern considering that it is among the most prevalent human diseases [1]. It is triggered by bacterial biofilms and, with other periodontal diseases, comprise a unique and complex group of inflammatory conditions that result in the destruction of the supporting structures of the dentition [2]. While the etiology of periodontitis is bacterial, it is becoming clear that the pathogenesis of disease is mediated by the host response [3].

Some studies show that periodontitis is associated with other several inflammatory conditions, such as arthritis, type-II diabetes, preeclampsia, preterm low birth weight, and cardiovascular diseases [4-9]. Since the pathogenesis of periodontitis shares similar aspects with many other inflammatory diseases, animal models of the disease are recognized as valid tools for the study of effector cell mediated inflammation [10].

In inflamed periodontal tissues, cyclooxygenase-2 (COX-2) expression is significantly up-regulated [11] and COX-2-derived prostaglandin E<sub>2</sub> (PGE<sub>2</sub>), produced by activated macrophages and fibroblasts, is present in the crevicular fluid of patients with periodontitis and considered as one of the major inflammatory mediators of alveolar bone destruction [12,13]. In fact, alveolar bone loss secondary to ligature-induced periodontitis in rats is significantly reduced during treatment with either selective COX-2 inhibitors [14,15] or traditional non-selective NSAIDs [16-18]. In humans, PGE<sub>2</sub> is associated with disease aggressiveness and can be used as a reliable indicator of current clinical periodontal destruction [19].

In this way, COX inhibition by NSAIDs would be an attractive clinical pharmacological approach aimed to reduce both PGE<sub>2</sub> production at the site of inflammation and tissue destruction [14,15]. However, the chronic use of NSAIDs is limited by the well-known, and clinically relevant, renal and cardiovascular occurrences, in addition to gastrointestinal ulceration and bleeding [20,21].

In this way, new classes of NSAIDs capable of releasing nitric oxide (NO) [22] or H<sub>2</sub>S [23-27] *in vivo* have been developed, with basis on the ability of these mediators to effectively antagonize many of the deleterious side-effects of traditional NSAIDs. For example, several studies show that the new H<sub>2</sub>S-releasing NSAIDs, such as those derived from mesalamine [23,24], indometacin [27], diclofenac [26] or naproxen [25,28-30], present significant advantages over the parent NSAIDs, with no impact on cardiovascular system, decreased gastric effects, and even accelerated healing activity of pre-existing gastric ulcers [25].

Using a rat model of knee joint synovitis, we have recently shown that, despite the similar effects of both naproxen and its H<sub>2</sub>S-releasing derivative ATB-346 on

inhibiting joint pain, edema and inflammatory cell recruitment to the knee-joint cavity, the H<sub>2</sub>S-releasing NSAID exerted no significant gastric damage, thus making of ATB-346 an interesting therapeutic alternative to traditional naproxen [30].

Regarding the relationship between H<sub>2</sub>S and periodontitis, published studies show discrepant results depending on the H<sub>2</sub>S donor employed, the administration route and doses [31-33].

Based on the considerations above, we thus decided to study the effects of the administration of Na<sub>2</sub>S (an H<sub>2</sub>S donor), naproxen and its H<sub>2</sub>S-releasing derivative ATB-346 in rats with ligature-induced periodontitis.

## Material and methods

### Animals

All the experimental protocols were approved by the local Ethics Committee for Animal Experimentation and performed in accordance with the guidelines of the Brazilian College for Animal Experimentation (COBEA). Male adult Holtzman rats (*Rattus norvegicus albinus*) weighing 250–300 g, were used in the experiments. During the length of the experimental protocol, the rats were kept in a quiet room with controlled temperature (22 ± 1°C), humidity (65-75%) and a 12-h light–dark cycle, and they were fed standard rat chow and received tap water *ad libitum*.

### Chemicals

All the drugs and reagents were purchased from Sigma-Aldrich (Brazil), unless otherwise stated.

### Induction of periodontitis, treatments and sample collection

The rats were anesthetized with ketamine (80 mg/kg, i. p.; Francotar, Virbac do Brasil Ind. e Com. Ltda, Brazil) and xylazine (16 mg/kg, i.p.; Kensol, König S.A., Brazil) and a 3–0 cotton ligature was placed subgingivally around the lower right first molar, as previously described [34]. Sham-operated animals had the ligature immediately removed after the procedure.

Following ligature placement, groups of animals started to receive daily oral doses of Na<sub>2</sub>S (dissolved in the drinking water at 45 mg/L, equivalent to a daily dose of approximately 10–12 mg/kg/day), equimolar doses of naproxen (10 mg/kg) or ATB-346 (16 mg/kg; Antibe Therapeutics Inc., Toronto, ON, Canada), or vehicle (1 ml/kg of 0.5% CMC). Treatments continued during the next 7 days, when the animals were euthanised.

Samples of gingiva surrounding the ligatured tooth were collected for measurement of cytokine contents, and the corpus region of the stomachs were also excised for assessment of macroscopical tissue damage and myeloperoxidase activity content (see below). The mandibles were removed for bone loss and histological analysis as shown below.

### Bone loss analysis

Digital X-ray images were also obtained for alveolar bone loss estimation by measurement of the distance between the cement-enamel junction (CEJ) and the alveolar bone crest at the mesial face of the ligatured tooth.

### Histological analysis

The mandibles were kept in 10% formaldehyde solution during 48 h, followed by decalcification of the right hemi-mandibles in 4.13% EDTA (pH 7.2) at 4°C for approximately 3 months. Serial paraffin sections of 5 µm thickness were made on the mesial-distal aspects of the whole first lower right molars and stained with hematoxylin and eosin (H&E). Morphological studies were made on the buccal and lingual gingiva and alveolar bone.

### Micro-computed tomography (µCT) analysis

For quantitative and qualitative three-dimensional (3D) analysis of the alveolar bone defect, right hemi-mandibles of 5 rats per group were scanned dorso-ventrally using a microfocuss X-ray CT system (Skyscan, Aartselaar, Belgium, 2003). The sagittal plane of the specimens was set parallel to the X-ray beam axis. The specimens were scanned at a resolution of 8.8 µm in all three spatial dimensions. The scans were gaussian-filtered and segmented using a multilevel global thresholding procedure for the segmentation of enamel, dentin, and bone [35]. CTan/CTvol software (Skyscan, Aartselaar, Belgium, 2003) was used for imaging and analysis. The volume of interest (VOI) was drawn with a slice-based method starting from the first slice containing the cement-enamel junction of the first molar and moving dorsally for 168 slices in the area 3 mm above the cement enamel junction. On the original 3D image, the microstructural variables, area and volume of bone defect, were calculated directly from the binarized VOI.

### Analysis of gingival cytokine contents

Interleukin (IL)-1β, IL-6 and IL-10 were measured in the collected gingiva samples by ELISA using commercial kits (R&D Systems Inc., Minneapolis, MN, USA) following the manufacturer instructions. Total protein contents were quantified according to the method described by Bradford et al. [36].

### Gastric damage assessment

At the end of the 7-day treatment period, the rats were euthanized and the stomachs were excised. The severity of damage was blindly scored as described in detail previously [37]. The length of each hemorrhagic erosion (in mm) was measured from the digitalized pictures using the software ImageJ (NIH, USA), and a gastric damage score was calculated by summing the lengths of all erosions in each stomach.

In addition, the activity of myeloperoxidase (MPO), a hemoprotein located in azurophilic granules of neutrophils, was used as a biochemical marker of neutrophil infiltration into the collected stomach samples, and was spectrophotometrically measured as previously described [38].

### Statistical analysis

All data are expressed as mean ± SEM. Differences among the group means were analyzed by one-way ANOVA followed by Tukey's test for multiple comparisons. Values of  $P < 0.05$  were considered as statistically significant.

## Results

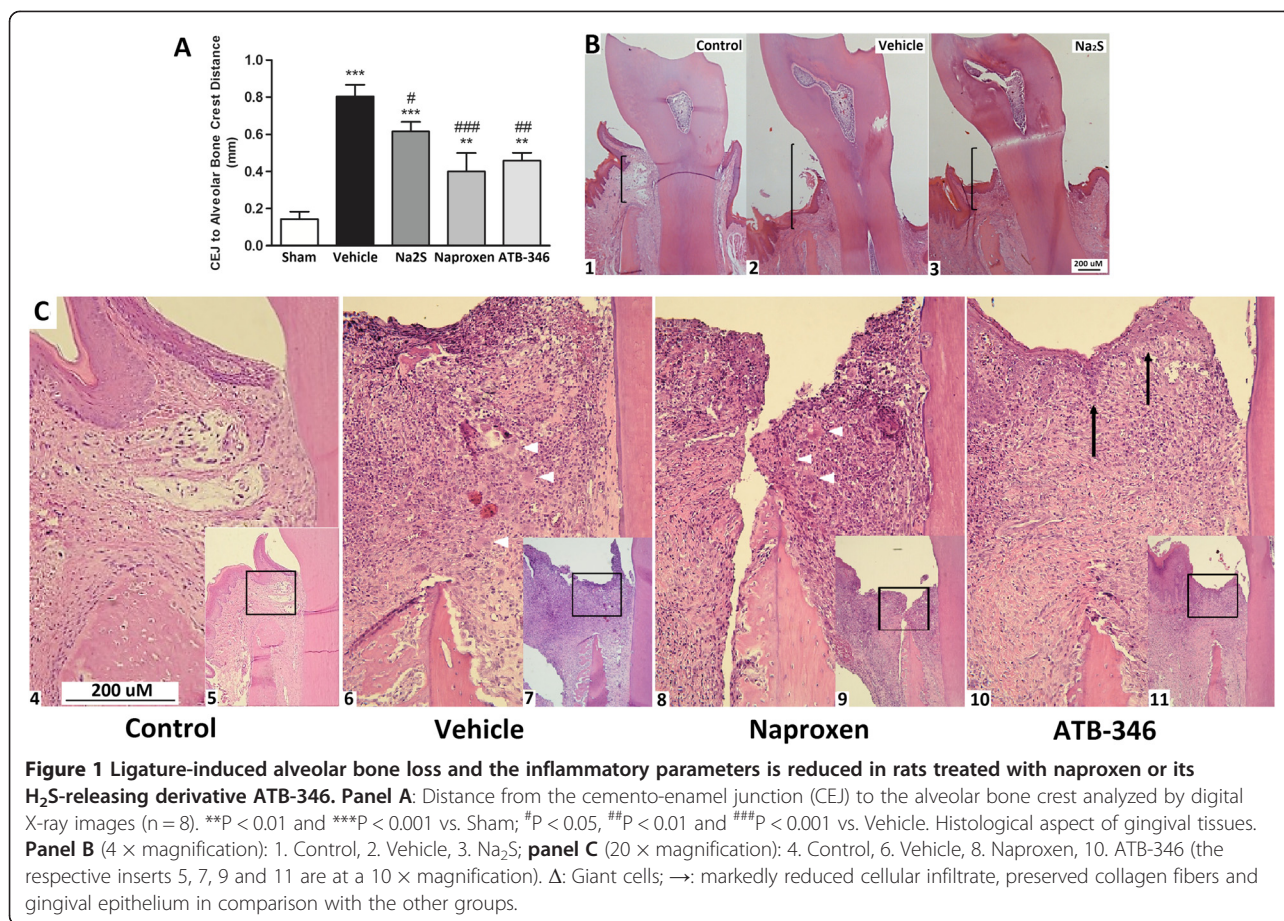
### Ligature induced bone loss

As shown in Figure 1 (panel A), after 7-day ligature, significant alveolar bone resorption was observed in the vehicle-treated animals in comparison with the Sham group, as radiographically assessed by measurement of the distances between the CEJ and the alveolar bone crest ( $0.80 \pm 0.06$  vs.  $0.14 \pm 0.04$  mm,  $P < 0.001$ ). Bone loss was significantly inhibited by all of the treatments (naproxen:  $0.62 \pm 0.05$  mm,  $P < 0.05$ ; ATB-346:  $0.46 \pm 0.04$  mm,  $P < 0.01$ ; Na<sub>2</sub>S:  $0.4 \pm 0.1$  mm,  $P < 0.001$ ).

### Histological analysis

Figure 1 also shows that normal morphology was observed in the Sham rat gingiva obtained from both the vestibular and lingual faces of the lower first molar. The oral, sulcular and junctional epithelium presented classical structures, and the connective tissue was dense, formed by thick collagen fibers, interspersed with delicate vessels and fibroblasts. Few inflammatory cells were found in the junctional epithelium region (panel B1).

The presence of a cotton ligature in a submarginal position around the lower first molar induced the classical microscopic characteristics of periodontitis, such as flatness of gingival epithelium, intense infiltration of chronic inflammatory cells, presence of giant cells, loss of connective tissue in the gingival papillae and evident alveolar bone resorption activity (panels B2 and C1). Na<sub>2</sub>S treated rats presented with evident decrease of the extension of chronic inflammation and partially conserved the connective tissue papillae, which is associated with milder bone resorption activity (panel B3). Naproxen treatment did not result in microscopic changes of the aspect of ligature-induced host response when compared with the vehicle-treated rats (panels B2 and C2). However, the administration of ATB-346 resulted in marked inhibition of the ligature-induced host response in the gingival tissues, characterized by the evident decrease of the extension of chronic inflammatory cells, giant cells and partially conserved connective tissue



**Figure 1 Ligature-induced alveolar bone loss and the inflammatory parameters is reduced in rats treated with naproxen or its H<sub>2</sub>S-releasing derivative ATB-346.** Panel A: Distance from the cemento-enamel junction (CEJ) to the alveolar bone crest analyzed by digital X-ray images (n=8). \*\*\*P < 0.01 and \*\*\*\*P < 0.001 vs. Sham; #P < 0.05, ##P < 0.01 and ###P < 0.001 vs. Vehicle. Histological aspect of gingival tissues. Panel B (4 × magnification): 1. Control, 2. Vehicle, 3. Na<sub>2</sub>S; panel C (20 × magnification): 4. Control, 6. Vehicle, 8. Naproxen, 10. ATB-346 (the respective inserts 5, 7, 9 and 11 are at a 10 × magnification). Δ: Giant cells; →: markedly reduced cellular infiltrate, preserved collagen fibers and gingival epithelium in comparison with the other groups.

papillae, as indicated by the preservation of collagen fibers and gingival epithelium (panel C4).

#### Bone defect area and volume values analyzed by $\mu$ CT

In addition to the inflammation and bone loss caused by the presence of the ligature around the first molar during 7 days, significant defects were induced in bone area and volume (area:  $0.50 \pm 0.13$  vs.  $0 \pm 0$  mm<sup>2</sup>,  $P < 0.001$ ; volume:  $3.24 \pm 0.24$  vs.  $0 \pm 0$  mm<sup>3</sup>,  $P < 0.001$ ; Figure 2, panels A and B, respectively). Treatment of the animals with naproxen potentiated these ligature-induced defects (area:  $0.95 \pm 0.03$  mm<sup>2</sup>,  $P < 0.001$ ; volume:  $4.58 \pm 0.07$  mm<sup>3</sup>,  $P < 0.001$ ). However, these bone defect parameters were significantly reduced in the ATB-346-treated rats (area  $0.21 \pm 0.05$  mm<sup>2</sup>,  $P < 0.001$ ; volume:  $2.17 \pm 0.2907$  mm<sup>3</sup>,  $P < 0.01$ ).

#### Gingival inflammatory cytokines

As shown in Figure 3, the presence of ligature induced significant increases in the gingival contents of IL-1 $\beta$  and IL-6, as well as decreased IL-10, in comparison with the Sham animals (IL-1 $\beta$ :  $134.8 \pm 29.1$  vs.  $15.3 \pm 1.5$  pg/mg of protein; IL-6:  $13.7 \pm 1.2$  vs.  $5.6 \pm 0.5$  pg/mg of protein; IL-10:  $0.6 \pm 0.2$  vs.  $2.9 \pm 0.4$  pg/mg of protein;  $P < 0.001$  for

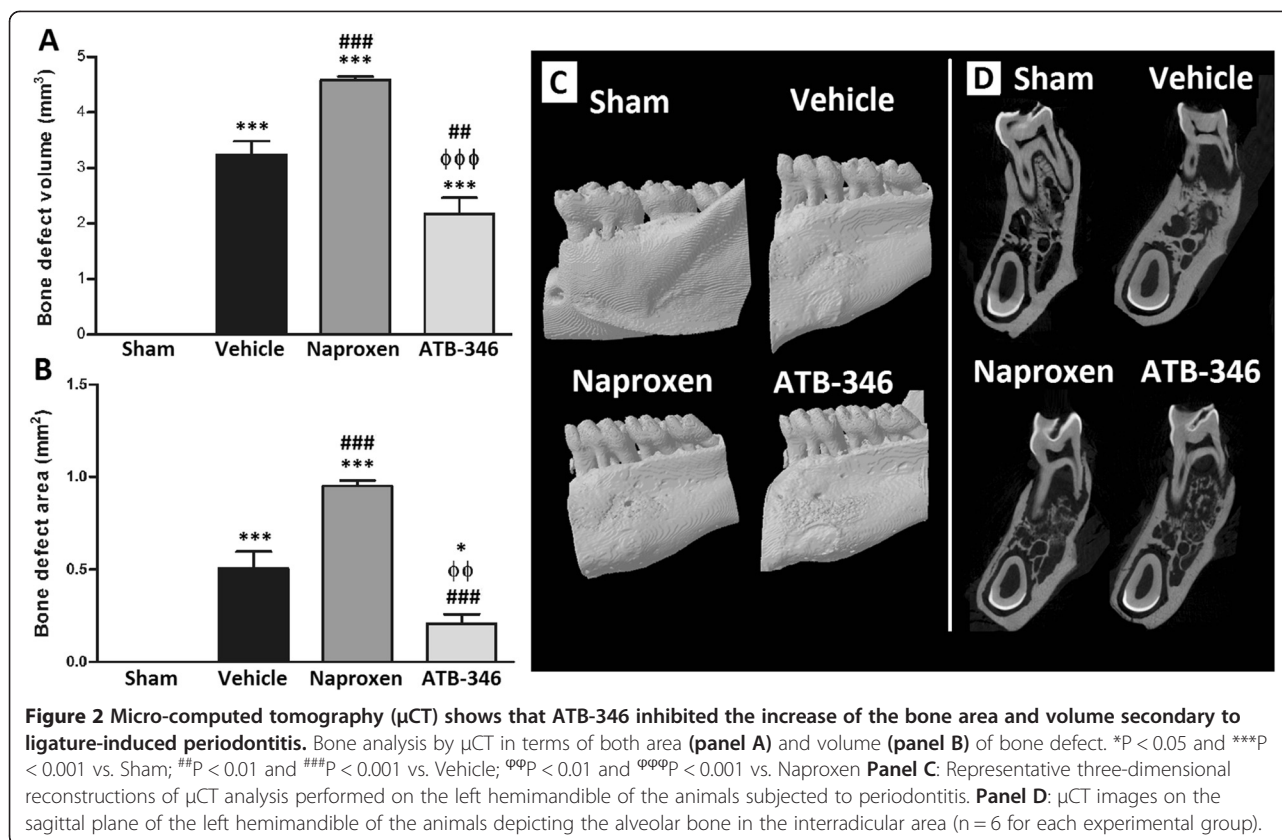
all the three cytokines). Treatment with either naproxen, ATB-346 or Na<sub>2</sub>S resulted in significant decrease of gingival IL-1 $\beta$  contents ( $61.4 \pm 7.8$ ,  $33.3 \pm 6.0$  and  $31.2 \pm 2.6$  pg/mg of protein, respectively; panel A), but only naproxen and ATB-346 resulted in decreased IL-6 ( $6.8 \pm 0.8$  and  $6.1 \pm 1.0$ , respectively; panel B). Regarding IL-10 contents, none of the treatments affected the ligature-induced decrease; panel C).

#### Gastric effects

As shown in Figure 4, the presence of ligature had no gastric effect, as assessed by either MPO activity (panel A) or macroscopical damage assessment (panels B and C). Only the naproxen-treated animals showed significantly increased gastric MPO activity ( $16.1 \pm 3.8$  U/mg tissue;  $P < 0.001$  vs. all the remaining groups), which was paralleled by the gastric damage score ( $17 \pm 3$  vs. 0 for all the remaining groups;  $P < 0.001$ ).

#### Discussion

During the development of periodontal disease, bacteria and their products form a biofilm covering the tooth surface in the subgingival area, which can have direct deleterious effects on periodontal tissues [2]. In susceptible



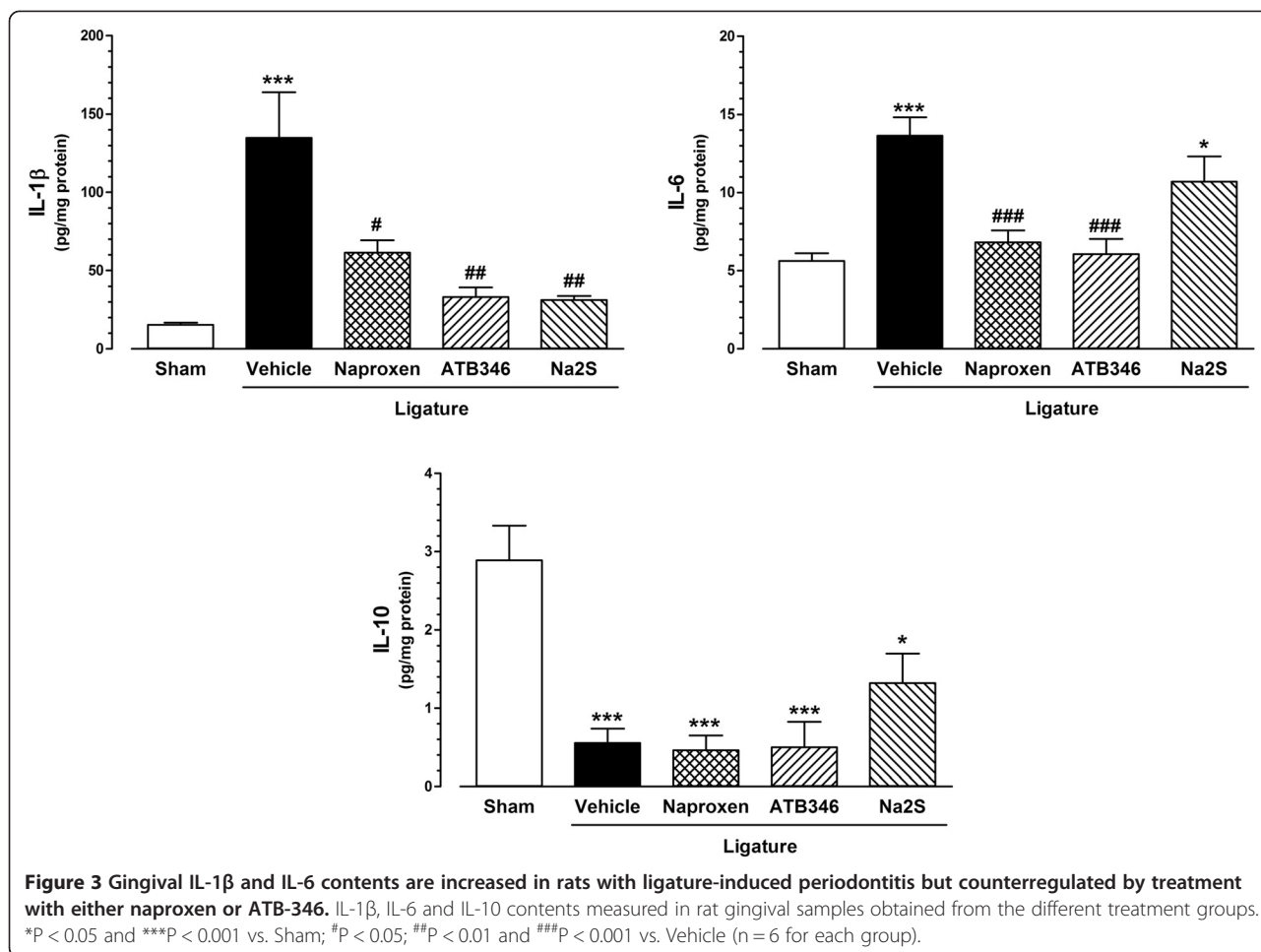
individuals, the host-mediated response to the pathogenic flora is subsequently responsible for the destruction of periodontal connective tissues, including alveolar bone [39,40].

The use of NSAIDs is one of the most widely used pharmacological tools to intervene and inhibit an inflammatory response, by antagonizing pro-inflammatory pathways and/or signaling, mainly dependent on COX-derived eicosanoids [41]. Although previous reports show that the NSAID treatment of rats with experimentally induced periodontitis leads to inhibition of periodontium inflammation and bone loss [14,15], NSAID therapy is not applicable for treatment of clinical periodontitis [42]. Unfortunately, and despite the magnitude of the clinical improvement is measurable, the need for prolonged therapy discourages the long-term use of NSAIDs in face of their severe cardiovascular, renal and gastric side effects [20,21].

One proposed strategy to avoid systemic complications and, at the same time, achieving high concentrations of the drug at the diseased site, has been the development of topical NSAID formulations (such as gels, toothpastes or mouth rinses) to be locally applied on a daily basis. However, evidence shows that just transient effects occur after the NSAID is withdrawn; in addition, no long-term or multicenter prospective clinical trials have

been performed to date examining whether the therapeutic effects of topical NSAIDs can be retained on a long-term basis [16].

In this study, we show that the development of experimental periodontitis in rats was significantly inhibited by treatment of the animals with a new H<sub>2</sub>S-releasing naproxen derivative - ATB-346, as clearly evidenced by the diminished alveolar bone loss, defect volume and area. In addition, we also show that the intense infiltration of chronic inflammatory cells and loss of connective tissue in the gingival papilla secondary to the presence of periodontitis was inhibited not only by treatment with ATB-346, but also with the inorganic H<sub>2</sub>S donor Na<sub>2</sub>S, thus reflecting the importance that exogenous H<sub>2</sub>S has by itself in the control and progression of periodontal disease in rats. Furthermore, the stomachs from animals treated with ATB-346 did not show the increased neutrophil contents (i.e., MPO activity) or tissue damage observed in the stomachs from the naproxen treated animals, thus demonstrating clear beneficial effects of ATB-346 over the parent drug. Indeed, it is based on these gastric protective properties without loss of its antiinflammatory activity that has led ATB-346 to undergo a phase I clinical trial for safety and pharmacokinetic evaluations in healthy human subjects (Antibe Press Release, Oct. 6, 2014).



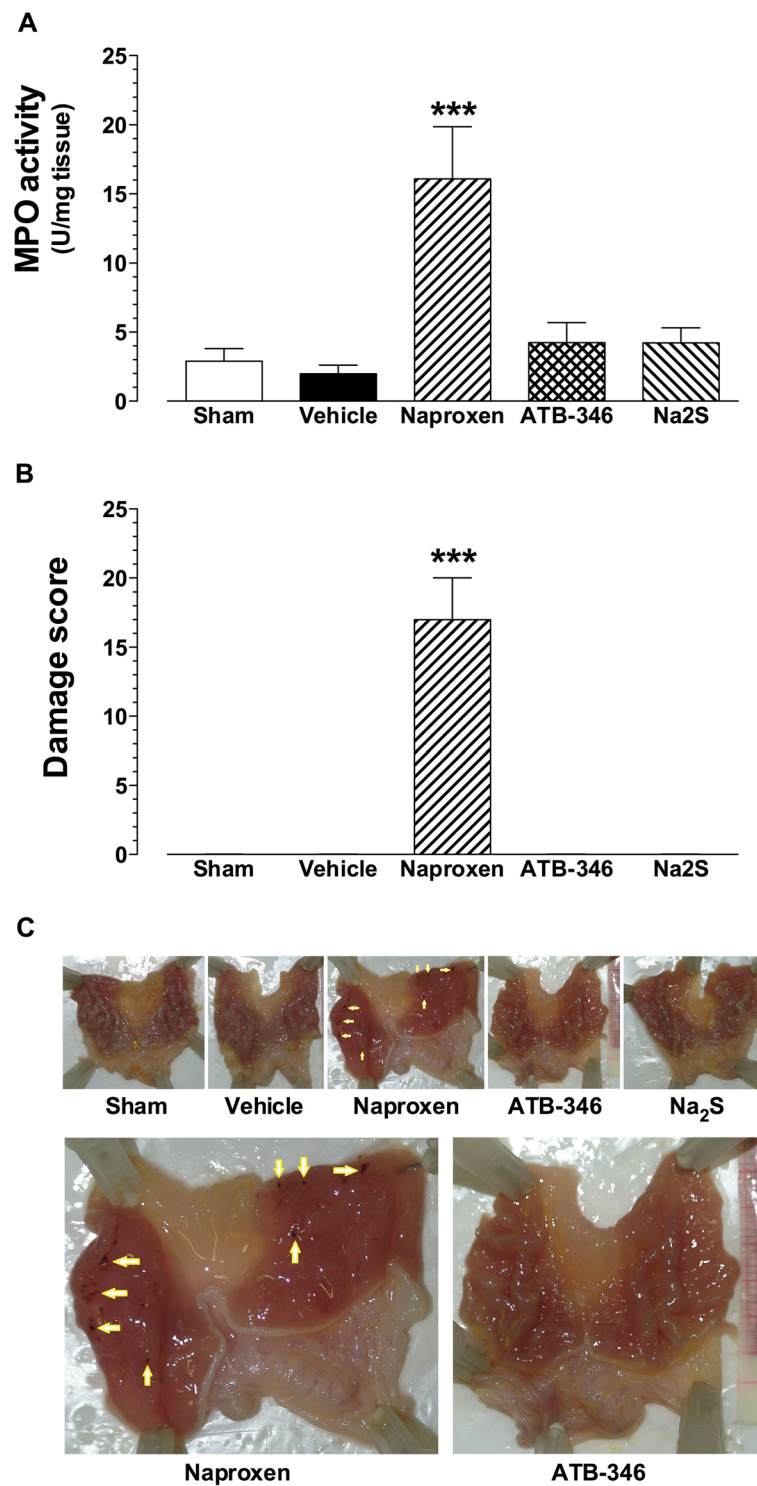
H<sub>2</sub>S is produced in virtually every organ system in the body [43,44], and some studies show that H<sub>2</sub>S contributes to the maintenance of tissue and organ integrity during inflammation by acting as resolution mediator [25,45,46]. Resolution of inflammation is an active, agonist-mediated and well-orchestrated process that drives the return to tissue homeostasis [47], and emerging evidence suggests that non-resolving inflammation is a critical underlying component of many prevalent chronic diseases, including periodontal disease [9]. In fact, El-Sharkawy et al. [48], showed that the adjunctive treatment of chronic periodontitis (i.e. scaling and root planning) with a daily dietary supplementation with omega-3 fatty acids and low-dose aspirin, increase the production a variety of pro-resolution lipid mediators, leading to a reduction in probing depths and a significant attachment gain, as assessed after 3- or 6-month treatment.

The observation that ATB-346 is capable of decreasing periodontal inflammation and also prevent the occurrence of deleterious effects on the gastric mucosa secondary to the naproxen moiety, can thus be explained,

at least in part, by the release of H<sub>2</sub>S, which can induce a shift from a pro-inflammatory to a pro-resolution status, both locally and systemically (i.e., in the stomach and periodontium, respectively).

The mechanisms and pathways of H<sub>2</sub>S signaling are not yet completely understood and its regulation is so complex that new mechanisms are continuously discovered before the former mechanisms are fully understood [49]. For example, it has been shown that H<sub>2</sub>S can not only activate ATP-sensitive K<sup>+</sup> (K<sub>ATP</sub>) channels (involved in vascular relaxation [50] and myocardial protection [51]), but also close T-type calcium channels (involved in visceral pain-like nociception and somatic hyperalgesia [52]), inhibit NF-κB signaling pathway (downregulating the expression of cytokines, chemokines, adhesion molecules and apoptosis [53]), inhibit cytochrome oxidase [54] and scavenge reactive oxygen and nitrogen species (thus inhibiting oxidative stress and regulating NO vascular effects [44]).

Regarding the effects of the administration of inorganic sulfide salts on periodontal tissues, a previous study from Irie et al. [31] shows that the topical application of 3 μmol



**Figure 4** Seven-day treatment with naproxen, but not ATB-346, induces gastric mucosa damage and increased myeloperoxidase activity (MPO). MPO activity content (**panel A**) and tissue damage score (**panel B**), determined in rat stomach samples obtained from the different treatment group. **Panel C**: Representative pictures of stomachs obtained from each experimental group (pictures corresponding to the naproxen and ATB-346 groups are also shown at higher magnification); yellow arrows indicate the presence of erosions. \*\*\* $P < 0.001$  vs. all the remaining experimental groups ( $n = 5$  for each group).

NaHS into the gingival sulcus of the rat first molar induces a transient increase of osteoclast differentiation with up-regulation of RANKL expression in osteoblasts, thus allowing the authors to conclude that H<sub>2</sub>S may contribute to alveolar bone resorption through RANKL expression. However, it is worth noticing that in the referred study, the employed NaHS dose was the result of applying 3 μL of a 1 M NaHS solution, a concentration that more resembles H<sub>2</sub>S toxicology than the concentrations at which H<sub>2</sub>S occurs under physiological conditions.

On the other hand, more recent studies using inorganic sulfide doses within the μmol/kg/day range (as used in this work), or *in vitro* concentrations within the μM range (that usually occur in biological fluids), show results in line with ours, in terms of H<sub>2</sub>S inhibiting activity on bone resorption. For example, Toker et al. [33] showed that the systemic administration of NaHS at three different doses (14, 28 or 70 μmol/kg/day) had no impact on the alveolar bone loss, but a significantly lower number of osteoclasts was observed by the authors at the highest NaHS dose. Moreover, Lee et al. [55] showed that NaHS inhibited the differentiation of mouse bone marrow cells into multinucleated TRAP-positive osteoclasts *in vitro*, in addition to reducing the mRNA expression of molecules involved in both nicotine- and LPS-induced osteoclastogenesis (such as RANKL, OPG, M-CSF, MMP-9, TRAP, and cathepsin K), thus suggesting that H<sub>2</sub>S has a potential therapeutic value for treatment of bone diseases, such as periodontitis.

## Conclusions

Despite the well-known beneficial effects of NSAIDs during inflammatory conditions, their use as adjuvants in the treatment of clinical periodontitis is not applicable, as the need for prolonged therapy would expose the patient to the risk of severe cardiovascular, renal and gastric side effects. From the results shown in this study, we provide the first evidence that the presence of the H<sub>2</sub>S-releasing moiety in the ATB-346 compound structure not only inhibits bone loss and inflammation in experimental periodontitis but, more importantly, it also prevents the occurrence of deleterious effects on the gastric mucosa due to prostaglandin inhibition. We thus believe that these findings could further encourage clinical studies looking for the impact of H<sub>2</sub>S-releasing NSAID compounds as potential adjuvants for classical periodontal treatment.

## Abbreviations

ANOVA: Analysis of variance; ATB-346: The H<sub>2</sub>S-releasing naproxen derivative [2-(6-methoxy-naphthalen-2-yl)-propionic acid 4-thiocarbamoyl-phenyl ester]; CEJ: Cement-enamel junction; CMC: Carboxymethyl cellulose; MPO: Myeloperoxidase; COBEA: Brazilian College for Animal Experimentation; COX-2: Type-2 cyclooxygenase; EDTA: Ethylenediamine tetraacetic acid; ERK: Extracellular signal-regulated kinase; H<sub>2</sub>S: Hydrogen sulfide; Ip: Intraperitoneal; IL-10: Interleukin 10; IL-1β: Interleukin 1β; IL-6: Interleukin 6; M-CSF: Macrophage

colony-stimulating factor; MKP-1: Mitogen-activated protein kinase phosphatase-1; MMP-9: Matrix metalloproteinase 9; Na<sub>2</sub>S: Sodium sulfide; NaHS: Sodium hydrosulfide; NF-κB: Nuclear factor kappa B; NO: Nitric oxide; NSAID: Non-steroidal antiinflammatory drug; OPG: Osteoprotegerin; PGE<sub>2</sub>: Prostaglandin E<sub>2</sub>; PIP3K: Phosphatidylinositol 3-kinase; PKC: Protein kinase C; RANKL: Receptor activator of nuclear factor kappa-B ligand; SEM: Standard error of the mean; TRAP: Tartrate-resistant acid phosphatase; μCT: Micro-computed tomography.

## Competing interests

JLW is a founder and shareholder of Antibe Therapeutics, Inc. All the other authors have no competing interests.

## Authors' contributions

Study design: BSH, SKPC, JLW, LCS & MNM. Experimental execution: BSH, LCS, ARC & SAT. Data analysis and interpretation of the results: BSH, LCS, ARC, SAT, LCS & MNM. Manuscript writing: BSH & MNM. Project funding applicant: MNM. All the authors have read and approved the final form of the manuscript.

## Acknowledgements

This study has been supported by the State of São Paulo Research Foundation (FAPESP); LCS, SKPC and MNM are recipients of fellowships from the Brazilian National Council for Scientific and Technological Development (CNPq).

## Author details

<sup>1</sup>Department of Pharmacology, Institute of Biomedical Sciences, University of Sao Paulo (USP), Sao Paulo, SP, Brazil. <sup>2</sup>Department of Physiology and Pathology, Araraquara School of Dentistry, Sao Paulo State University (UNESP), Araraquara, SP, Brazil. <sup>3</sup>Department of Pharmacology and Toxicology, University of Toronto, Toronto, ON, Canada.

Received: 11 November 2014 Accepted: 14 February 2015

Published online: 27 February 2015

## References

- Page RC, Eke PI. Case definitions for use in population-based surveillance of periodontitis. *J Periodontol*. 2007;78(7 Suppl):1387–99.
- Van Dyke TE, Serhan CN. Resolution of inflammation: a new paradigm for the pathogenesis of periodontal diseases. *J Dent Res*. 2003;82:82–90.
- Kantarci A, Hasturk H, Van Dyke TE. Host-mediated resolution of inflammation in periodontal diseases. *Periodontology* 2000. 2006;40:144–63.
- The J, Ebersole JL. Rheumatoid factor (RF) distribution in periodontal disease. *J Clin Immunol*. 1991;11:132–42.
- Bogges KA, Lief S, Murtha AP, Moss K, Beck J, Offenbacher S. Maternal periodontal disease is associated with an increased risk for preeclampsia. *Obstet Gynecol*. 2003;101:227–31.
- Offenbacher S, Bogges KA, Murtha AP, Jared HL, Lief S, McKaig RG, et al. Progressive periodontal disease and risk of very preterm delivery. *Obstet Gynecol*. 2006;107:29–36.
- Taylor GW, Burt BA, Becker MP, Genco RJ, Shlossman M, Knowler WC, et al. Severe periodontitis and risk for poor glycemic control in patients with non-insulin-dependent diabetes mellitus. *J Periodontol*. 1996;67(10 Suppl):1085–93.
- Friedewald VE, Kornman KS, Beck JD, Genco R, Goldfine A, Libby P, et al. The American journal of cardiology and journal of periodontology editors' consensus: periodontitis and atherosclerotic cardiovascular disease. *J Periodontol*. 2009;80:1021–32.
- Fredman G, Oh SF, Ayilavarapu S, Hasturk H, Serhan CN, Van Dyke TE. Impaired phagocytosis in localized aggressive periodontitis: rescue by resolvins E1. *PLoS One*. 2011;6:e24422.
- Hasturk H, Kantarci A, Ohira T, Arita M, Ebrahimi N, Chiang N, et al. RvE1 protects from local inflammation and osteoclast-mediated bone destruction in periodontitis. *FASEB J*. 2006;20:401–3.
- Morton RS, Dongari-Bagtzoglou AI. Cyclooxygenase-2 is upregulated in inflamed gingival tissues. *J Periodontol*. 2001;72:461–9.
- Offenbacher S, Heasman PA, Collins JG. Modulation of host PGE<sub>2</sub> secretion as a determinant of periodontal disease expression. *J Periodontol*. 1993;64(5 Suppl):432–44.
- Drisko CH. Non-surgical pocket therapy: pharmacotherapeutics. *Ann Periodontol*. 1996;1:491–566.



14. Holzhausen M, Spolidorio DM, Muscara MN, Hebling J, Spolidorio LC. Protective effects of etoricoxib, a selective inhibitor of cyclooxygenase-2, in experimental periodontitis in rats. *J Periodontol Res.* 2005;40:208–11.
15. Holzhausen M, Rossa Junior C, Marcantonio Junior E, Nassar PO, Spolidorio DM, Spolidorio LC. Effect of selective cyclooxygenase-2 inhibition on the development of ligature-induced periodontitis in rats. *J Periodontol.* 2002;73:1030–6.
16. Salvi GE, Lang NP. The effects of non-steroidal anti-inflammatory drugs (selective and non-selective) on the treatment of periodontal diseases. *Curr Pharm Des.* 2005;11:1757–69.
17. Howell TH, Jeffcoat MK, Goldhaber P, Reddy MS, Kaplan ML, Johnson HG, et al. Inhibition of alveolar bone loss in beagles with the NSAID naproxen. *J Periodontol Res.* 1991;26:498–501.
18. Aras H, Caglayan F, Guncu GN, Berberoglu A, Kilinc K. Effect of systemically administered naproxen sodium on clinical parameters and myeloperoxidase and elastase-like activity levels in gingival crevicular fluid. *J Periodontol.* 2007;78:868–73.
19. Tsai CC, Hong YC, Chen CC, Wu YM. Measurement of prostaglandin E2 and leukotriene B4 in the gingival crevicular fluid. *J Dent.* 1998;26:97–103.
20. Grosser T, Fries S, FitzGerald GA. Biological basis for the cardiovascular consequences of COX-2 inhibition: therapeutic challenges and opportunities. *J Clin Invest.* 2006;116:4–15.
21. Wallace JL. Prostaglandins, NSAIDs, and gastric mucosal protection: why doesn't the stomach digest itself? *Physiol Rev.* 2008;88:1547–65.
22. Muscara MN, Wallace JL. COX-inhibiting nitric oxide donors (CINODs): potential benefits on cardiovascular and renal function. *Cardiovasc Hematol Agents Med Chem.* 2006;4:155–64.
23. Distrutti E, Sediari L, Mencarelli A, Renga B, Orlandi S, Russo G, et al. 5-Amino-2-hydroxybenzoic acid 4-(5-thioxo-5H-[1,2]dithiol-3-yl)-phenyl ester (ATB-429), a hydrogen sulfide-releasing derivative of mesalamine, exerts antinociceptive effects in a model of postinflammatory hypersensitivity. *J Pharmacol Exp Ther.* 2006;319:447–58.
24. Fiorucci S, Orlandi S, Mencarelli A, Caliendo G, Santagada V, Distrutti E, et al. Enhanced activity of a hydrogen sulphide-releasing derivative of mesalamine (ATB-429) in a mouse model of colitis. *Br J Pharmacol.* 2007;150:996–1002.
25. Wallace JL, Caliendo G, Santagada V, Cirino G. Markedly reduced toxicity of a hydrogen sulphide-releasing derivative of naproxen (ATB-346). *Br J Pharmacol.* 2010;159:1236–46.
26. Wallace JL, Caliendo G, Santagada V, Cirino G, Fiorucci S. Gastrointestinal safety and anti-inflammatory effects of a hydrogen sulfide-releasing diclofenac derivative in the rat. *Gastroenterology.* 2007;132:261–71.
27. Wallace JL. Hydrogen sulfide-releasing anti-inflammatory drugs. *Trends Pharmacol Sci.* 2007;28:501–5.
28. Blackler R, Syer S, Bolla M, Ongini E, Wallace JL. Gastrointestinal-sparing effects of novel NSAIDs in rats with compromised mucosal defence. *PLoS One.* 2012;7:e35196.
29. Campolo M, Esposito E, Ahmad A, Di Paola R, Wallace JL, Cuzzocrea S. A hydrogen sulfide-releasing cyclooxygenase inhibitor markedly accelerates recovery from experimental spinal cord injury. *FASEB J.* 2013;27:4489–99.
30. Ekundi-Valentim E, Mesquita FP, Santos KT, de Paula MA, Florenzano J, Zanoni CI, et al. A comparative study on the anti-inflammatory effects of single oral doses of naproxen and its hydrogen sulfide (H2S)-releasing derivative ATB-346 in rats with carrageenan-induced synovitis. *Med Gas Res.* 2013;3:24.
31. Irie K, Ekuni D, Yamamoto T, Morita M, Yaegaki K, Ii H, et al. A single application of hydrogen sulphide induces a transient osteoclast differentiation with RANKL expression in the rat model. *Arch Oral Biol.* 2009;54(8):723–9.
32. Irie K, Ekuni D, Tomofuji T, Endo Y, Kasuyama K, Yaegaki K, et al. Combined effects of hydrogen sulfide and lipopolysaccharide on osteoclast differentiation in rats. *J Periodontol.* 2012;83:522–7.
33. Toker H, Balci Yuce H, Goze F, Ozdemir H, Akpınar A, Bostanci V. The effects of hydrogen sulphide on alveolar bone loss in periodontitis. *Minerva Stomatol.* 2014;63:103–10.
34. Sallay K, Sanavi F, Ring I, Pham P, Behling UH, Nowotny A. Alveolar bone destruction in the immunosuppressed rat. *J Periodontol Res.* 1982;17:263–74.
35. Wilensky A, Gabet Y, Yumoto H, Hourii-Haddad Y, Shapira L. Three-dimensional quantification of alveolar bone loss in *Porphyromonas gingivalis*-infected mice using micro-computed tomography. *J Periodontol.* 2005;76:1282–6.
36. Bradford MM. A rapid and sensitive method for the quantitation of microgram quantities of protein utilizing the principle of protein-dye binding. *Anal Biochem.* 1976;72:248–54.
37. Wallace JL, McCafferty DM, Carter L, McKnight W, Argentieri D. Tissue-selective inhibition of prostaglandin synthesis in rat by tepoxalin: anti-inflammatory without gastropathy. *Gastroenterology.* 1993;105:1630–6.
38. Herrera BS, Martins-Porto R, Campi P, Holzhausen M, Teixeira SA, Mendes GD, et al. Local and cardiorenal effects of periodontitis in nitric oxide-deficient hypertensive rats. *Arch Oral Biol.* 2011;56:41–7.
39. Page RC, Kornman KS. The pathogenesis of human periodontitis: an introduction. *Periodontology* 2000. 1997;14:9–11.
40. Herrera BS, Martins-Porto R, Maia-Dantas A, Campi P, Spolidorio LC, Costa SK, et al. iNOS-derived nitric oxide stimulates osteoclast activity and alveolar bone loss in ligature-induced periodontitis in rats. *J Periodontol.* 2011;82:1608–15.
41. Serhan CN, Brain SD, Buckley CD, Gilroy DW, Haslett C, O'Neill LA, et al. Resolution of inflammation: state of the art, definitions and terms. *FASEB J.* 2007;21:325–32.
42. Ciancio SG. Systemic medications: clinical significance in periodontics. *J Clin Periodontol.* 2002;29 Suppl 2:17–21.
43. Wang R. Physiological implications of hydrogen sulfide: a whiff exploration that blossomed. *Physiol Rev.* 2012;92:791–896.
44. Kimura H. Hydrogen sulfide: its production, release and functions. *Amino Acids.* 2011;41:113–21.
45. Flannigan KL, Ferraz JG, Wang R, Wallace JL. Enhanced synthesis and diminished degradation of hydrogen sulfide in experimental colitis: a site-specific, pro-resolution mechanism. *PLoS One.* 2013;8:e71962.
46. Dufton N, Natividad J, Verdu EF, Wallace JL. Hydrogen sulfide and resolution of acute inflammation: A comparative study utilizing a novel fluorescent probe. *Scientific Reports.* 2012;2:499.
47. Van Dyke TE. The management of inflammation in periodontal disease. *J Periodontol.* 2008;79(8 Suppl):1601–8.
48. El-Sharkawy H, Aboelsaad N, Eliwa M, Darweesh M, Alshahat M, Kantarci A, et al. Adjunctive treatment of chronic periodontitis with daily dietary supplementation with omega-3 fatty acids and low-dose aspirin. *J Periodontol.* 2010;81(11):1635–43.
49. Guo W, Cheng ZY, Zhu YZ. Hydrogen sulfide and translational medicine. *Acta Pharmacol Sin.* 2013;34:1284–91.
50. Wang R. Signaling pathways for the vascular effects of hydrogen sulfide. *Curr Opin Nephrol Hypertens.* 2011;20:107–12.
51. Szabo G, Veres G, Radovits T, Gero D, Modis K, Miesel-Groschel C, et al. Cardioprotective effects of hydrogen sulfide. *Nitric Oxide.* 2011;25:201–10.
52. Matsunami M, Kirishi S, Okui T, Kawabata A. Chelating luminal zinc mimics hydrogen sulfide-evoked colonic pain in mice: possible involvement of T-type calcium channels. *Neuroscience.* 2011;181:257–64.
53. Chattopadhyay M, Kodela R, Nath N, Barsegian A, Boring D, Kashfi K. Hydrogen sulfide-releasing aspirin suppresses NF-kappaB signaling in estrogen receptor negative breast cancer cells in vitro and in vivo. *Biochem Pharmacol.* 2012;83:723–32.
54. Caro AA, Thompson S, Tackett J. Increased oxidative stress and cytotoxicity by hydrogen sulfide in HepG2 cells overexpressing cytochrome P450 2E1. *Cell Biol Toxicol.* 2011;27:439–53.
55. Lee SK, Chung JH, Choi SC, Auh QS, Lee YM, Lee SI, et al. Sodium hydrogen sulfide inhibits nicotine and lipopolysaccharide-induced osteoclastic differentiation and reversed osteoblastic differentiation in human periodontal ligament cells. *J Cell Biochem.* 2013;114:1183–93.

**Submit your next manuscript to BioMed Central and take full advantage of:**

- Convenient online submission
- Thorough peer review
- No space constraints or color figure charges
- Immediate publication on acceptance
- Inclusion in PubMed, CAS, Scopus and Google Scholar
- Research which is freely available for redistribution

Submit your manuscript at  
[www.biomedcentral.com/submit](http://www.biomedcentral.com/submit)

