

## CASE REPORT

# Effect of Acupuncture on Post-implant Paresthesia



Crischina Branco Marques Sant'Anna <sup>1,\*</sup>,  
Paulo Renato Junqueira Zuim <sup>1</sup>, Daniela Atili Brandini <sup>2</sup>,  
Aimée Maria Guiotti <sup>1</sup>, Joao Batista Vieira <sup>3</sup>,  
Karina Helga Leal Turcio <sup>1</sup>

<sup>1</sup> Department of Dental Materials and Prosthodontics, Dental School of Araçatuba, Univ Estadual Paulista—UNESP, Brazil

<sup>2</sup> Department of Integrated Clinic, Dental School of Araçatuba, Univ Estadual Paulista—UNESP, Brazil

<sup>3</sup> Department of Pathology and Clinical Propedeutics, Dental School of Araçatuba, Univ Estadual Paulista—UNESP, Brazil

Available online 12 January 2017

Received: Aug 22, 2016

Revised: Dec 6, 2016

Accepted: Jan 6, 2017

### KEYWORDS

acupuncture therapy;  
dental implants;  
facial pain;  
paresthesia

### Abstract

Paresthesia is defined as an alteration in local sensibility, associated with numbness, tingling, or unpleasant sensations caused by nerve lesions or irritation. It can be temporary or permanent. The treatment protocol for facial paresthesia is primarily based on the use of drugs and implant removal, which may not be completely effective or may require other risk exposure when there is no spontaneous regression. However, other therapeutic modalities such as acupuncture can be used. The aim of this study is to report a case of a patient with paresthesia of the inferior alveolar nerve and pain caused by an implant surgery performed 2 years earlier. The patient received acupuncture treatment during 4 months of weekly sessions. Six points were used: Large Intestine (LI4), Large Intestine (LI11), Stomach (ST36), Liver (LR3), Extra Head and Neck (E-HN-18), and Stomach (ST5). The visual analog scale was used before and after each session for the analysis of paresthesia and pain, together with assessment of the paresthesia by delimitation of the desensitized region of the skin and presented discomfort. Pain remission and reduction in the size of the paresthesia area occurred after four sessions.

\* Corresponding author. Aguapei, 3300, Araçatuba, São Paulo, CEP 16025-455, Brazil.

E-mail: [crischina.s@terra.com.br](mailto:crischina.s@terra.com.br) (C.B.M. Sant'Anna).

## 1. Introduction

Surgical procedures have increased in dentistry as has the risk of consequences, such as paresthesia (3.6–11.9%) [1], with transitional (23%) or persistent complications (13%) [2,3], with 64.4% of these in the inferior alveolar nerve [4]. Paresthesia is a sensibility disorder with strange or unpleasant sensations. It can produce a partial loss of sensitivity or spontaneous abnormal sensations such as tingling. It is caused by mechanical factors, such as direct or indirect trauma, and pathological, physical, chemical, and microbiological alterations. It is a traumatic, painful, peripheral postimplant neuropathy, which may be associated with hypoesthesia, hyperalgesia, dysesthesia, allodynia, and pain. The amount of alteration is proportional to the fiber type, amount of tissue loss, and intensity of injury suffered [5].

Imaging tests are important to prevent accidents [6]. Medications to reduce postoperative edema and inflammation are also preconized. These include nonsteroidal anti-inflammatory drugs, injectable steroids, and physical resources, such as heat, transcutaneous electrical nerve stimulation, lasers, and acupuncture [7–9].

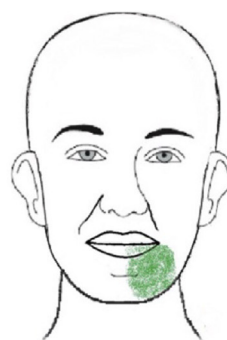According to Traditional Chinese Medicine (TCM), the organism works correctly when there is a dynamic balance between two fundamental aspects: Qi (energy) and matter (organic part) [10,11]. The energy is absorbed and distributed throughout the organism through energy channels, and the material portion is distributed through the circulatory system [10]. All innate factors, unruly feeding, and suppressed or intense emotion can lead to disharmony of the systems, provoking illness [10–12]. Surgical trauma causes blockages that cause pain [10,11], tingling, and heavy (numbness) sensations, which are characteristics of paresthesia [13]. By TCM theory, when inserting needles in specific points, analgesic mechanisms are unleashed [14] through the release of endogenous substances, improving the tissue healing response, nerve conduction [15], and local blood flow [16]. Based on the TCM perspective, paresthesia results from the stagnation and blocking of the Qi (energy or flow of nerve signals) [12].

The aim of this study is to report a case of a patient with paresthesia of the inferior alveolar nerve caused by an implant surgery performed 2 years earlier. The patient received acupuncture treatment for the condition.

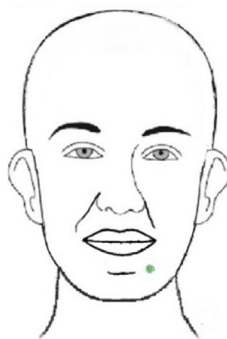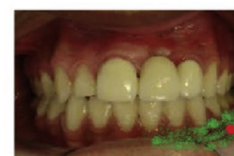## 2. Case presentation

A 56-year-old female patient came to the Temporomandibular Disorders Diagnosis and Treatment Center (TMD) at the Aracatuba Dental School, Araçatuba, São Paulo, Brazil, reporting a strange sensation in the lower lip and in the delimited region of the mental foramen and mucosa hemiarch [from the median line up to the left mandibular second molar (Tooth 36)]. She also reported acute pain in the mucosa at a specific point within the paresthesia area (region of Tooth 35). The symptoms appeared after implant surgeries for Teeth 36 and 37 (Fig. 1).

The patient reported pain during suturing and subsequent removal. While yawning 3 days after the surgery, she felt an acute sensation in the region that developed into a



Aspect of the dysesthesia after acupuncture



Aspect of the dysesthesia before acupuncture

**Figure 1** Dysesthesia before and after the acupuncture treatment in the green area.

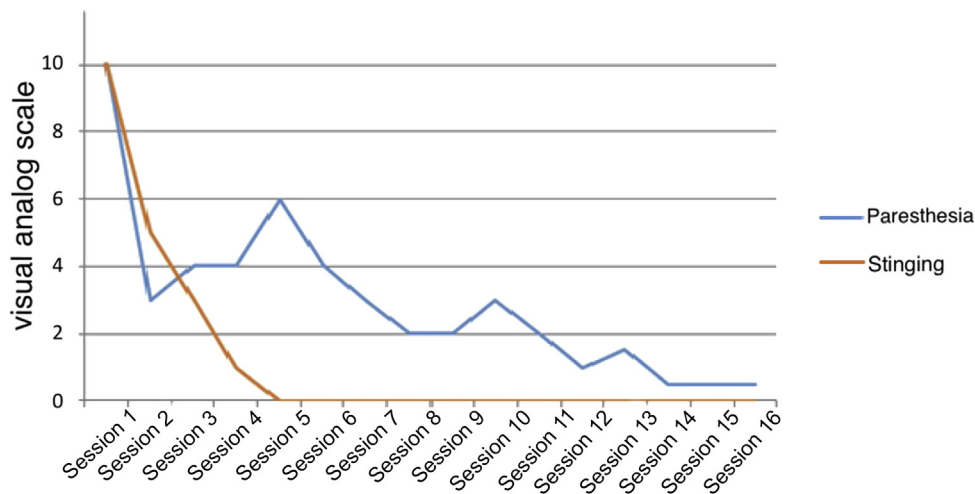
burning sensation which occurred sporadically while brushing teeth, talking, or sometimes spontaneously. Over time, this area developed a painful, unpleasant sensation described as numbness (paresthesia).

The predominance of the earth element, which includes discomfort with humidity, preference for sweet foods, presence of anxiety and preoccupation, yellowing of the skin, and darkening around the eyes, was observed in the patient. Additionally, a normal colored, tapered tongue without coating, which had a slight deviation to the right, a red tip, and indentations on the side, was observed.

The patient did not use medication for the symptoms. The study was conducted in accordance with ethical criteria and the Declaration of Helsinki.

Weekly acupuncture sessions were held for 4 months. Six points were used: Large Intestine (LI4), Large Intestine (LI11), Stomach (ST36), Liver (LR3), Extra Head and Neck (EHN-18), and Stomach (ST5). These points were selected according to the characteristics of the patient and the clinical features observed (paresthesia and muscle pain—TMD) [10]. The visual analog scale was used before and after each session for the analysis of paresthesia and pain, together with the assessment of the paresthesia by delimitation of the desensitized region of the skin and presented discomfort.

After the first session, a decrease in the intensity of pain was observed. After three sessions, acute pain became less frequent, disappearing after the fourth session.



**Figure 2** Paresthesia and pain sensations reported by the patient during acupuncture sessions.

The numbness (paresthesia) in an area of approximately 3 cm × 3 cm (around the foramen region of the inferior alveolar nerve toward the jaw angle) diminished to a single point after each session (very close to the mental foramen), remaining this way for approximately 3 days. According to the visual analog scale used, the patient had a high pain score (10) at the initial consultation which decreased after each session (4 in the 2<sup>nd</sup>, 2 in the 3<sup>rd</sup>, and 0 in the 4<sup>th</sup> session). The patient remained pain-free for the next six sessions. After 10 sessions, paresthesia occurred at only one point, and after 1 year of follow-up, it remained the same (Fig. 2).

### 3. Discussion

TCM explains that by inserting needles in acupoints, interference occurs in the channel energy flow to which the point belongs [10]. This is caused by the physical element (needle) generating energy flow. Paresthesia is related to the humidity–heat invasion in the energy channel, obstructing it and stagnating energy (ethereal and physical–blood) [10]. The choice of general energy flow points near the region of paresthesia and in the regional energy channel.

The effectiveness of acupuncture includes regeneration process, tissue repair, and reduction of pain [14]. When compared with massage and heat, the use of acupuncture becomes an alternate treatment choice [17–19]. The use of points in the affected local region is also justified due to the access to peripheral nerve fibers and muscle receptors (AGama) [20]. These points generate muscle relaxation and help to restore function and tissues, allowing the circulation of energy through the stomach meridian. The use of acupuncture points IG4 and IG11 is important in head and neck pain/inflammatory conditions [10,15].

In the present case, the surgical site presents tissue injury, with probable formation of compressive fibrosis over the nerve, altering the passage of stimulus. The use of acupuncture promoted tissue healing, local muscle relaxation with nerve release, and the return of sensitivity.

Published studies show that nerve cells return to normal function [21] and repair ability [22] as responses after acupuncture. Systematic reviews demonstrate an effectiveness of up to 73%, making acupuncture an adequate treatment option [23,24].

The patient exhibited a 50% reduction in pain after the first session, a reduction in pain from 9 to 5 in the visual analog scale score, and a 100% reduction after the fifth session (reduction to 0). A 70% reduction was observed in paresthesia (reduction from 10 to 3) in the first session, and a 95% reduction at the follow-up period (after 13 sessions), demonstrating the effectiveness of the treatment.

It can be concluded that the recommended treatment with acupuncture progressively reduced the pain from a high score in the visual analog scale (10) at the initial consultation to lower scores of 4 in the second and 2 in the third sessions, with a reduction to 0 in the fourth session. The patient remained free of pain for the next six acupuncture sessions. After 10 sessions, paresthesia occurred at only one point, which remained the same after 1 year of follow-up.

### Disclosure statement

The authors have no source of financial support to declare.

### References

- [1] Tay AB, Zuniga JR. Clinical characteristics of trigeminal nerve injury referrals to a university centre. *Int J Oral Maxillofac Surg.* 2007;36:922–927.
- [2] Juodzbaly G, Wang H, Sabalys G, Sidlankas A, Galindo-Moreno P. Inferior alveolar nerve injury associated with implant surgery. *Clin Oral Implants Res.* 2013;24:183–190.
- [3] Libersa P, Savignat M, Tonnel A. Neurosensory disturbances of the inferior alveolar nerve: a retrospective study of complaints in a 10-year period. *J Oral Maxillofac Surg.* 2007;65:1486–1489.
- [4] Juodzbaly G, Wang H, Sabalys G. Injury of the inferior nerve during Implant placement: a literature review. *J Oral*

- Maxillofac Res.* 2011 Apr 1;2(1):e1. <http://dx.doi.org/10.5037/jomr.2011.2101>. eCollection 2011.
- [5] Wright PE, Jobe M. Lesões dos nervos periféricos. In: Crenshaw AH, ed. *Cirurgia ortopédica de Campbell*. São Paulo: Manole; 1997:1054 [In Portuguese].
- [6] Madeira MC. *Anatomia da face: bases anatomo-funcionais para a prática odontológica*. São Paulo: Sarvier; 1995:217 [In Portuguese].
- [7] Romero-Reyes M, Uyanik J. Orofacial pain management: current perspectives. *J Pain Res.* 2014;7:99–115.
- [8] Mourão LC, Moutinho HM, Canabarro A. Role of homeopathy in post-surgical dental implants paresthesia—a case report. *J Case Studies Homeopathy.* 2013;1:6–10.
- [9] Seo K, Tanaka Y, Terumitsu M, Someya G. Efficacy of steroid treatment for sensory impairment after orthognathic surgery. *J Oral Maxillofac Surg.* 2004;62:1193–1197.
- [10] Yamamura Y. *Acupuntura tradicional—a Arte de Inserir*. 2nd ed. São Paulo: Roca; 2001 [In Portuguese].
- [11] Cheng JK. Neurobiological mechanisms of acupuncture for some common illnesses: a clinician's perspective. *J Acupunct Meridian Stud.* 2014;7:105–114.
- [12] Shen J. Research on the neurophysiological mechanisms of acupuncture: review of selected studies and methodological issues. *J Altern Complement Med.* 2001;7:S121–S127.
- [13] Fabrin S, Soares N, Regalo SC, Verri ED. The effects of acupuncture on peripheral facial palsy sequelae after 20 years via electromyography. *J Altern Complement Med.* 2015. <http://dx.doi.org/10.1016/j.jams.2015.01.006> [Date accessed November 11, 2015].
- [14] Cheng KJ. Neuroanatomical basis of acupuncture treatment for some common illnesses. *Acupunct Med.* 2009;27:61–64.
- [15] Pomeranz B. Acupuncture analgesia basic research. In: Stux G, Hammerschlag R, eds. *Clinical Acupuncture, Scientific Basis*. Berlin: Springer; 2000:1–28.
- [16] Inque M, Hojo T, Nakajima M, Kitakoji H, Itoi M, Katsumi Y. The effect of electrical stimulation of the pudendal nerve on sciatic nerve blood flow in animals. *Acupunct Med.* 2008;26:145–148.
- [17] Sandberg M, Lindberg LG, Gerdl B. Peripheral effects of needle stimulation (acupuncture) on skin and muscle blood flow in fibromyalgia. *Eur J Pain.* 2004;8:163–167.
- [18] Kimura K, Masuda K, Wakayama I. Changes in skin blood flow and skin sympathetic nerve activity in response to manual acupuncture stimulation in humans. *Am J Chin Med.* 2006;34:189–196.
- [19] Ross R, Vogel A. The platelet-derived growth factor. *Cell.* 1978;14:203–210.
- [20] Fishie J, White A. *Acupuntura Médica: um enfoque científico do ponto de vista Ocidental*. São Paulo: Roca. 2002;12 [In Portuguese].
- [21] Hsing WT. *Modificações clínicas e cintilográficas de pacientes com acidente cerebral isquêmico crônico tratados pela estimulação elétrica subcutânea*. São Paulo, 111p. Tese (Doutorado)—Faculdade de Medicina de São Paulo. 2001.
- [22] Thayer T. Acupuncture in dentistry. *SAAD Dig.* 2001;18:3–8.
- [23] Rosted P. Practical recommendations for the use of acupuncture in the treatment of temporomandibular disorders based on the outcome of published controlled studies. *Oral Dis.* 2001;7:109–115.
- [24] Santiago MV, Tumilty S, Macznik A, Mani R. Does acupuncture alter pain-related functional connectivity of the central nervous system? A systematic review. *J Acupunct Meridian Stud.* 2016; 9(4):167–177. <http://dx.doi.org/10.1016/j.jams.2015.11.038>.