

The use of tubular subdermal and axial flaps in the correction of four cases of extensive lesions

Rafael Ricardo Huppel¹ Josiane Morais Pazzini^{2*} Andriago Barboza De Nardi²
Jorge Luiz Costa Castro³ Cristiano Gomes⁴ Arícia Gomes Sprada² Ana Lúcia Pascolli²

¹Departamento de Clínica e Cirurgia Veterinária, Universidade Cesumar (Unicesumar), Maringá, PR, Brasil.

²Departamento de Clínica e Cirurgia Veterinária, Faculdade de Ciências Agrárias e Veterinárias (FCAV), Universidade Estadual de São Paulo (UNESP), Av. Jaime Ribeiro, 988, apto 221, bloco 3, Distrito Industrial, 14884-900, Jaboticabal, SP, Brasil. E-mail: josipazzini@hotmail.com.

*Corresponding author.

³Departamento de Clínica e Cirurgia Veterinária, Universidade Pontifícia Católica (PUC), Curitiba, PR, Brasil.

⁴Departamento de Clínica e Cirurgia Veterinária, Universidade Federal de Santa Maria (UFSM), Santa Maria, RS, Brasil.

ABSTRACT: *The most common skin lesions in small animals result from trauma, burns, or surgical resection of large tumors. Given the high importance of reconstructive surgery associated with tumors in small animals, this study reports four cases of reconstructive surgery using subcutaneous and axial tubular flaps in animals with neoplastic lesions. Subdermal and axial tubular flaps are healthy alternatives for reconstructing wounds caused by large tumor resection in areas with poor tissue elasticity.*

Key words: reconstructive surgery, axial flap, subdermal flap, cancer, canine.

Retalhos tubulares subdérmicos e axiais utilizados em quatro casos de correção de lesões extensa

RESUMO: *As lesões mais comuns na pele de animais de pequeno porte são causadas por trauma, queimaduras ou ressecção cirúrgica de grandes tumores, sendo as doenças oncológicas as principais causas para a utilização de técnicas de cirurgia reconstrutiva. Entretanto, os cirurgiões precisam ter um sólido domínio de técnicas de excisão e reconstrução, compreender a biologia do tumor e aplicar terapias adjuvantes ou alternativas, garantindo o sucesso da cirurgia. Dada a grande importância de cirurgias reconstrutivas associadas a tumores em animais de pequeno porte, este estudo teve como objetivo relatar quatro casos utilizando técnicas de cirurgia reconstrutiva por meio de retalhos tubulares subcutâneos, bem como retalhos tubulares axiais como opção de tratamento em pacientes com lesões neoplásicas. Sendo assim, o emprego de retalhos tubulares subcutâneos e de retalhos tubulares axiais, são boas alternativas para a reconstrução de feridas criadas pela ressecção de grandes tumores em áreas com baixa elasticidade do tecido.*

Palavras-chave: cirurgia reconstrutiva, retalho axial, retalho subdérmico, câncer, canino.

INTRODUCTION

Skin defects in small animals are caused by traumatic injuries, burns, or surgical resection of large tumors (MAYHEW, 2009). Importantly, oncologic diseases are the primary cause of death in canines and felines (VAIL, 2008); thus, reconstructive surgery is necessary for correcting defects resulting from extensive injuries.

Surgery is the oldest and most successful method for treating neoplasms, and may also be used to facilitate prevention, diagnosis, and palliative care (DUPRE, 2008). Tumoral excisions, with margins wide enough to avoid residual disease, commonly result in the formation of large skin defects that represent challenges to surgeons (FISHER, 2008).

A thorough knowledge of species anatomy and physiology, command of excision and reconstruction techniques, understanding of tumoral biology, and competent use of adjuvant or alternative therapies are all essential for surgical success (HEDLUND, 2007).

Reconstruction of large skin defects after trauma or radical excision of neoplastic masses may be problematic, especially when wounds are located on extremities where there is insufficient skin for primary closure. For such cases, options include the creation of axial or local subdermal flaps, skin grafts, or secondary wound healing (MAYHEW, 2009). We currently understand the importance of surgery for reconstructing defects resulting from neoplastic injuries, but prior knowledge of neoplasms during surgery is mandatory (DUPRE, 2008).

Skin blood flow is similar in canines and felines; a series of well-documented direct cutaneous arteries transport blood to the subdermal plexus, which in turn supplies blood to the dermis and epidermis. When skin dissection is needed, dissection below the subdermal plexus is essential to maintain blood flow and avoid necrosis (MAYHEW, 2009).

Pedicle flaps are defined as portions of skin and subcutaneous tissue, partially separated from underlying tissues, which are transferred from one location of the body to another. The base, or pedicle, maintains blood flow, ensuring flap survival (PAVLETIC, 1999; HEDLUND, 2007).

Flaps are classified as subdermal or axial, according to the blood flow configuration in the pedicle (VASCONCELLOS et al., 2005). Subdermal flaps do not include direct cutaneous vessels in the pedicle, but depend on the (usually small) subdermal plexus to ensure blood flow to the entire area (STANLEY, 2007; HEDLUND, 2007). Therefore, this study reports four cases in which tubular subdermal and axial skin flaps were used to treat animals with neoplastic wounds.

MATERIALS AND METHODS

Animals attending the veterinary hospital oncology sector, diagnosed with neurofibrosarcoma carcinoma solid mammary or neurofibrosarcoma hemangiopericytoma, underwent surgical tumor removal together with skin reconstruction. Table 1 provides data for each case.

Complete blood tests, kidney and liver biochemical assessments, ultrasounds, chest x-rays, and cardiologic assessments were carried out for all animals. X-rays and ultrasounds revealed no evidence of metastasis in the lungs or other abdominal organs, and blood, biochemical, and cardiologic tests did not reveal alterations.

In *case one*, we made two parallel skin incisions in the flank, 6cm apart. We then carried out an in-depth dissection, preserving the subdermal plexus, and created marginal tube sutures (3-0 non-absorbable thread) in a simple, continuous pattern. We subsequently repaired the donor area, reducing the dead space using a simple interrupted running suture (3-0 absorbable thread). Fifteen days later, we performed tumor resection and removed the dorsal extremity of the tube, implanting it on the defect caused by tumor removal. During this time, we observed small cyanosites, controlled by local application of a diethyl ammonium salicylate solution (Reparil® Gel). Only one cyanosite progressed to superficial necrosis, which was treated by cleaning the region with a physiological solution and applying 2.5% silver sulfadiazine ointment that did not compromise tube viability. During implantation, the tube's free extremity was cut with a scalpel to open the lumen and increase coverage in the receiving area. The donor area was repaired with simple running interrupted sutures (3-0 absorbable thread) whilst skin sutures (3-0 non-absorbable thread) were applied in a simple interrupted pattern.

Table 1 - Accurate information on the four cases presented.

	Case 1	Case 2	Case 3	Case 4
Sex	Male	Female	Female	Male
Breed	Mixed	Mixed	Labrador retriever	Labrador retriever
Age	12 years	10 years-	8 years	8 years
Neoplasms of the location	Skin tumors in the pelvic member, knee region	Inguinal near the vulva	Nodule in the region of the left elbow	Nodule in the region of the right elbow
Neoplasia type	Neurofibrosarcoma	Solid mammary carcinoma	Neurofibrosarcoma	Hemangiopericytoma
Type of surgery	Subdermal tube near the flank region. Tumor resection and removal of the dorsal extremity of the tube and implantation on the defect created by the tumor removal.	Subdermal tube near the inguinal region (in the lateral region of the flank).	Thoracodorsal axial flap.	Tubular indirect pedicle flap using skin tissue from the scapular region around the thoracodorsal vascular plexus.
Complication	Cyanosite progressed into superficial necrosis	Small cyanosites	Not present	Small necrotic area near the center

The animal returned for a follow-up examination 10 days post surgery, and no necrotic areas were observed in the healing process. The stitches were removed after 15 days, and the animal was released with no evidence of local recurrence one year postoperatively.

In *case two*, we made two parallel skin incisions in the flank, 5cm apart. We then carried out a deep dissection preserving the subdermal plexus and created marginal tube sutures (3-0 non-absorbable thread) in a simple, continuous pattern (Figure 1). We subsequently repaired the donor area, reducing the dead space (102) using a simple interrupted running suture (3-0 non-absorbable thread). Fifteen days later, we performed the tumor resection and removed the

dorsal extremity of the tube, implanting it on the defect caused by tumor deletion. During this time, we observed small cyanosites, controlled by local application of a diethyl ammonium salicylate solution (Reparil® Gel). In the second procedure, which consisted of removing and implanting the tube, the free extremity was relocated to cover the receiving location. The donor area was repaired with simple running interrupted sutures (3-0 absorbable thread) whilst skin sutures (3-0 non-absorbable thread) were applied in a simple interrupted pattern.

The animal returned for follow-up examination 10 days post surgery, and no necrotic areas were observed in the healing process. The stitches were removed after 15 days, and the animal

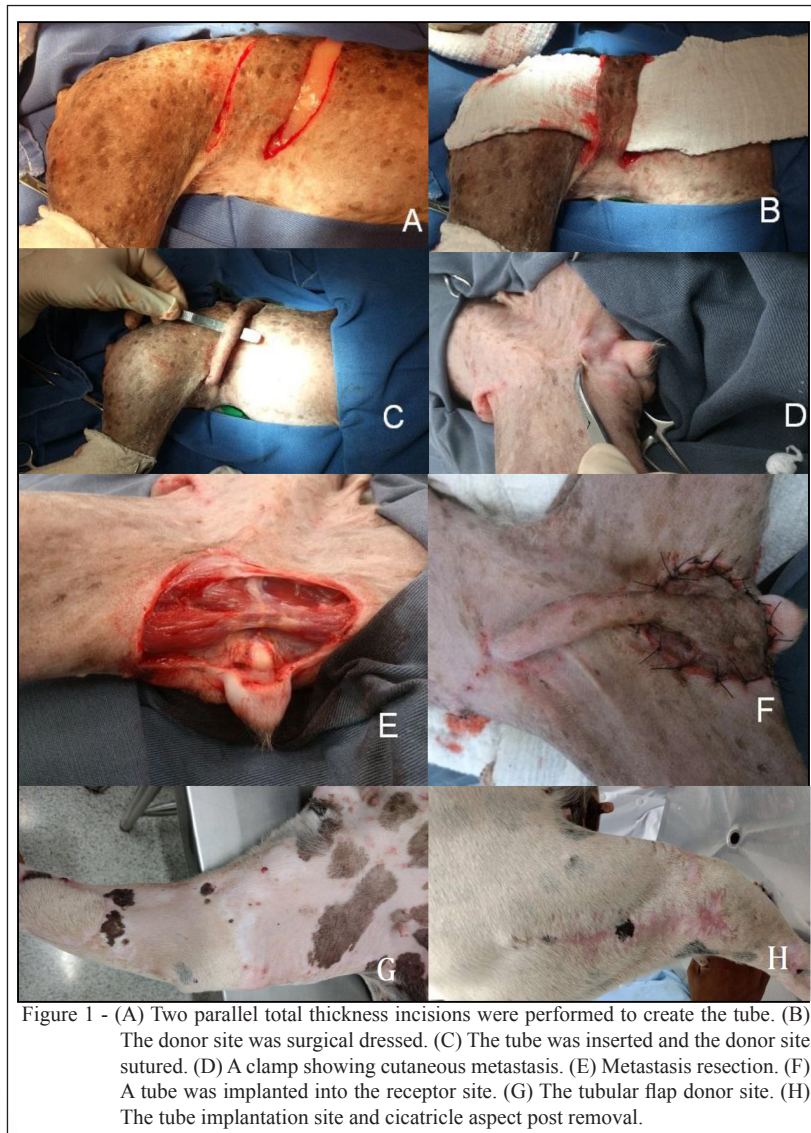


Figure 1 - (A) Two parallel total thickness incisions were performed to create the tube. (B) The donor site was surgical dressed. (C) The tube was inserted and the donor site sutured. (D) A clamp showing cutaneous metastasis. (E) Metastasis resection. (F) A tube was implanted into the receptor site. (G) The tubular flap donor site. (H) The tube implantation site and cicatricial aspect post removal.

was released with complete healing of the wound and no evidence of local recurrence two years postoperatively. In this case, we opted not to remove the tube in a third procedure (described in the pre-surgery plan), but this did not compromise the animal's deambulation.

In *case three*, we opted for reconstructive surgery to ensure adequate surgical margins. A thoracodorsal axial flap was chosen to repair the defect. We used the flap to create a thoracodorsal tube over the receiving area. The surgical technique required the animal to be positioned in lateral decubitus, with the leg slightly raised. After marking the incision points, we created the flap with two parallel incision lines over the scapular spine, at lengths twice the distance from the acromion to the caudal scapular depression. When the incisions were complete, creating a rectangle, we made a deep dissection up to the myocutaneous muscle, careful not to traumatize the thoracodorsal artery and accessory vessels. Once the flap was released, it was rotated distally to the member. We then created the resulting thoracodorsal defect, using sutures (3-0 non-absorbable thread) in a simple interrupted pattern, starting from the defect margins and advancing towards the center until total reduction of the wound was achieved. Skin sutures were then applied in the same pattern. With the aid of the flap, we created a communicant tube between the donor and receiving areas using simple continuous sutures (3-0 absorbable thread), leaving an unsutured section for implantation into the new bed, in the elbow region. During the synthesis of the tubular flap, we reduced the dead space using sutures (3-0 absorbable thread) in a simple interrupted pattern, and the skin was synthesized using sutures (3-0 non-absorbable thread) in a simple interrupted pattern.

The animal returned for a follow-up examination 10 days post surgery, and no necrotic areas were observed in the healing process. Stitches were removed after 15 days, and the animal was discharged once the wound completely healed and if no local recurrence was noted for one year post operation.

In *case four*, we conducted surgical resection with a safety margin of approximately 2cm around the tumor, and chose a tubular indirect pedicle flap to close the wound using skin tissue from the scapular region around the thoracodorsal vascular plexus. Sutures were removed from the flap 15 days post surgery, revealing proper healing in the margins and only a small necrotic area near the center, where there was inadequate muscular coverage to prevent friction between the bone and skin. Thirty days after the procedure, a resection of the tube loop was

indicated, due to the remaining ulcerated area caused by friction, despite complete healing of the flap. We conducted local cleaning, applied softer protection with cotton and bandages, and left the animal in an area with delicate flooring. Upon removing the second procedure sutures, all areas of the wound had already healed. No recurrence was observed two years post operation.

RESULTS AND DISCUSSION

Subdermal and axial flaps are classified as local when transferred from an area adjacent to the defect, and distant when further away from the donor site (HEDLUND, 2007). In the cases reported, we employed distant tubular flaps, due to the location of the tumors, and obtained favorable results. Therefore, techniques used were in accordance with those described in the literature (PAVLETIC, 1999; HEDLUND, 2007).

Distant flaps (tubes) are often used to repair wounds formed after tumor resection, causing extensive defects in the extremities or sites where skin has poor elasticity. Flaps are subdivided into direct or indirect (PAVLETIC, 2003). In the cases presented, we used subdermal; and therefore, indirect flaps in two animals and direct axial flaps in two animals.

To avoid necrosis in subdermal tubular flaps, we conducted the procedures in two phases. Whilst, this approach was favorable for relocating the flap to the receiving site (HEDLUND, 2007), it can be complicated and time-consuming (PAVLETIC, 1999; PARGANA, 2009), as well as, uncomfortable for animal due to the necessity of multiple surgical procedures. Moreover, axial tubular flaps may be relocated during tumor resection (HEDLUND, 2007). Tubular subdermal and axial flaps were created as recommended in the literature (PAVLETIC, 1999; PARGANA, 2009). According to the authors, the major benefit of tubular axial flaps, compared with that of tubular subdermal flaps, is flap relocation during tumor resection, eradicating the need for tube creation in the first procedure, but necessitating time for healing and subsequent flap relocation to the receiving site. However, one of the problems with axial flaps is that the technique requires an angiosome, containing an artery and a vein, while subdermal flaps may be created from any cutaneous region of the skin.

The use of tubular skin flaps is limited to the distal portion of members. A bipedicular flap is prepared from a piece of skin with two parallel incisions, after deep dissection of the plexus, by suturing the margins to each other (PAVLETIC, 1999). The tube is made 2 or 3cm larger than the receiving

site, as they contract due to the healing process and fibrosis before the transference (HEDLUND, 2007). For animals with subdermal tubular flaps, we recommended sufficient planning before tumor resection. We measured the length of the flap, and determined the base of the tube at a site 5cm from the tumor. Once the base was determined, we measured the distance from this site to the most distal region of the tumor, adding a 4cm safety margin. This is necessary due to skin retraction during healing, and a safety margin of 2 to 3cm is recommended for tumor resections to obtain free margins. For axial flaps, there is no need to add safety margins, as flaps are relocated during tumor resection. Thus, in this procedure, we first removed the tumor and then measured the length of the tube. The width of this tube pattern differs from subdermal patterns, in which the tube is created by measuring the tumor and adding 2 or 3 centimeters at either side. For axial tubes, the width is dependent on anatomical points that have the donor angiosome.

Tube relocation across the animal's body may be conducted via a transversal cut of the base located farthest away from the tumor, and moving the base to a region closer to the wound (tumor). However, this technique necessitates several surgical phases, to cover the defect near the tumor and suture the relocated base to the new site. After this stage, a waiting period of 15 days is required for healing prior to the second surgical procedure, for repairs after tumor resection (HEDLUND, 2007). However, this technique was not used in the current cases as, in two cases, the wounds were in the elbow region, in one case, the wounds were in the knee region, and in the remaining case, the wounds were in the inguinal region. According to the authors, this maneuver is only indicated for defects in member extremities, or at sites with low skin availability.

The healing times required for creation of the subdermal tubular flaps and following phase were lower than those described in the literature (HEDLUND, 2007). According to VASCONCELLOS et al. (2005) and DE NARDI et al. (2015), a healing time of 21 days is indicated for this type of flap, but in the current cases, only 15 days were required after tumor resection, from tube creation to healing and subsequent relocation to the implant site. Despite the recommended period of 21 days being different from the time observed in the current cases, our results were favorable.

Flap margin sutures were made in simple interrupted patterns with 3-0 non-absorbable thread, according to the specifications recommended by PAVLETIC (1999), HEDLUND (2007), and DE

NARDI et al. (2015). Use of this suture is necessary to avoid necrosis; it inflicts fewer wounds on the tissue and thus does not compromise local flow and angiogenesis.

Axial flap transference success (i.e. avoidance of excessive tension, rotation (over 180 degrees), and vascular impairment) depends on precise and non-traumatic surgical technique, as described by PAVLETIC (1999), VASCONCELLOS et al. (2005), HUPPES et al. (2015) and DE NARDI et al. (2015). Therefore, the technique was conducted carefully, without excessive tension or sutures for dead space reduction on the implant site. Vascular impairment was avoided, but in two cases, cyanosis progression into superficial necrosis was observed. This situation can progress to necrosis and death of the flap, but in this case, only a minor impairment of the flap was observed. Therefore, the procedures were successful.

The use of subdermal and axial tubular flaps are good alternatives for the reconstruction of wounds created by large tumor resections in areas with low tissue elasticity. However, to ensure success, subdermal flap procedures must be conducted in several phases. For procedures employing axial flaps, vascularization must be preserved.

BIOETHICS AND BIOSECURITY COMMITTEE APPROVAL

The authors of the current article, titled "The use of tubular subdermal and axial flaps in the correction of four cases of extensive lesions" declare, for all due purposes, that the project giving rise to the present data has not been submitted for evaluation to the Ethics Committee of Faculdade de Ciências Agrárias e Veterinárias (FCAV), Universidade Estadual Paulista (UNESP), Jaboticabal, SP. However, we are aware of the content of the Brazilian resolutions of the Conselho Nacional de Controle de Experimentação Animal (CONCEA).

ACKNOWLEDGEMENTS

The Universidade Pontifícia Católica (PUC), Curitiba; Universidade Federal de Santa Maria (UFSM), Santa Maria; Faculdade de Ciências Agrárias e Veterinárias, Universidade Estadual Paulista (UNESP), Jaboticabal and Unicesumar, Maringá.

REFERENCES

- DUPRE, G. Success in oncological surgery [versão electrónica]. In: CONGRESS OF THE WORLD SMALL ANIMAL VETERINARY ASSOCIATION, 33., 2008, Dublin, Ireland. **Proceedings...** Dublin: WSAVA, 2008. Available from: <<http://www.vin.com/proceedings/Proceedings.plx?CID=WSAVA2008&Category=3882&PID=23883&O=Generic>>. Accessed: May 03, 2009.
- DE NARDI, A.B. et al. Técnicas reconstrutivas em membros torácicos. In: CASTRO, J. L. C. et al. **Princípios e técnicas de cirurgias reconstrutivas da pele de cães e gatos (Atlas Colorido)**. Curitiba: Medvop, 2015. Cap.12.

- FISHER, B. Biological research in the evolution of cancer surgery: A personal perspective [abstract] [versão electrónica]. **Cancer Research**, v.68, p.24, 2008. Available from: <<http://cancerres.aacrjournals.org/cgi/content/abstract/68/24/10007>>. Accessed: May 03, 2009. doi: 10.1158/0008-5472.
- HEDLUND, C.S. Surgery of the integumentary system. In: FOSSUM, T.W. **Small animal surgery**. 3.ed. St. Louis: Missouri: Mosby, Elsevier, 2007. p.94.
- PAVLETIC, M.M. **Atlas of small animal reconstructive surgery**. 2.ed. Philadelphia, Pennsylvania: Saunders, 1999. Total de p.696.
- PAVLETIC, M.M. Pedicle grafts. In: SLATTER, D. **Textbook of small animal surgery**. 3.ed. Philadelphia: Saunders, Elsevier Science, 2003. p.585-603.
- STANLEY, B.J. Reconstructive surgery [versão electrónica]. In: CONGRESS OF THE WORLD SMALL ANIMAL VETERINARY ASSOCIATION, 32., 2007, Sydney, Australia. **Proceedings...** Sydney: WSAVA, 2007. Available from: <<http://www.vin.com/proceedings/Proceedings.plx?CID=WSAVA2007&Category=2996&PID=18149&O=Generic>>. Accessed: May 03, 2009.
- VAIL, D.M. Introduction to practical oncology & horizon therapies. In: JORNADAS INTERNACIONAIS DE MEDICINA VETERINÁRIA DA UTAD, 12., 2008, Vila Real, Portugal. **Livro de comunicações...** Vila Real: JIMV-UTD, 2008. p.39-43.
- VASCONCELLOS, C.H. de C. Clinical evaluation of random skin flaps based on the subdermal plexus secured with sutures or sutures and cyanoacrylate adhesive for reconstructive surgery in dogs. **Veterinary Surgery**, v.34, p.59-63, 2005. Available from: doi:10.1111/j.1532-950X.2005.00011.x. Accessed: May 03, 2009.