UNIVERSIDADE ESTADUAL PAULISTA
"JÚLIO DE MESQUITA FILHO"
FACULDADE DE MEDICINA

SHAIRA FERRARI RODOR BISSOLI

MAPEAMENTO DAS EVIDÊNCIAS DAS REVISÕES SISTEMÁTICAS DE OFTALMOLOGIA DA BASE DE DADOS COCHRANE.

Dissertação apresentada à Faculdade de Medicina, Universidade Estadual Paulista "Júlio de Mesquita Filho", Campus de Botucatu, para obtenção do título de Mestre em Medicina.

Orientadora: Profª. Drª. Eliane Chaves Jorge

Botucatu

2018

SHAIRA FERRARI RODOR BISSOLI

MAPEAMENTO DAS EVIDÊNCIAS DAS REVISÕES SISTEMÁTICAS DE OFTALMOLOGIA DA BASE DE DADOS COCHRANE.

Dissertação apresentada à Faculdade de Medicina, Universidade Estadual Paulista "Júlio de Mesquita Filho", Campus de Botucatu, para obtenção do título de Mestre em Medicina.

Orientadora: Prof[a.] Dr[a.] Eliane Chaves Jorge

Botucatu

2018

Ficha catalográfica

FICHA CATALOGRÁFICA ELABORADA PELA SEÇÃO TÉC. AQUIS. TRATAMENTO DA INFORM.
DIVISÃO TÉCNICA DE BIBLIOTECA E DOCUMENTAÇÃO - CÂMPUS DE BOTUCATU - UNESP
BIBLIOTECÁRIA RESPONSÁVEL: ROSANGELA APARECIDA LOBO-CRB 8/7500

Bissoli, Shaira Ferrari Rodor.
Mapeamento das evidências das revisões sistemáticas de oftalmologia da base de dados Cochrane / Shaira Ferrari Rodor Bissoli. - Botucatu, 2018

Dissertação (mestrado) - Universidade Estadual Paulista "Júlio de Mesquita Filho", Faculdade de Medicina de Botucatu
Orientador: Eliane Chaves Jorge
Capes: 40101177

1. Medicina baseada em evidências. 2. Revisão. 3. Pesquisa. 4. Banco de dados. 5. Oftalmologia.

Palavras-chave: Cochrane; Evidências; Mapeamento; Revisão; Sistemática.

Dedicatória

Ao André, meu querido companheiro de medicina e de vida nesses 10 anos. À minha família, sobretudo meus pais, avós e irmãos que aprenderam a conviver com a distância e se mantiveram presentes em cada dia desses anos que passamos longe. Aos meus sogros, pela sempre pronta palavra de apoio e incentivo. Ao Tio, fonte de inspiração na escolha da medicina.

Agradecimentos

À Dra Eliane Chaves Jorge, minha orientadora, pela atenção, paciência e infinda prestatividade.

À minha amiga Tâmata, por me incetivar a realizar este trabalho e nunca me deixar desistir.

Aos meus queridos Maria Júlia, Lívia, Gabriel, Marjorie e Lidiane por serem mais que amigos, mas a minha família Botucatuense.

Às queridas funcionárias do Bloco IV e Hospital Estadual de Botucatu pelo imenso carinho, cooperatividade e espírito de equipe.

Aos meus “R mais, R iguais e R menos” pelo companheirismo de sempre, por tornarem nosso dia-a-dia leve e prazeroso.

À minha professora da graduação, Dra Diusete Maria Pavan, por ter me incetivado e por me fazer apaixonar pela especilidade que hoje exerço.

Aos queridos tutores da Oftalmologia de Botucatu, preceptores e professores, pelos ensinamentos diários nas discussões de caso a beira do paciente, da lâmpada de fenda e ao microscópio quando em cirurgia.

RESUMO

Bissoli SFR. Mapeamento das evidências das revisões sistemáticas de oftalmologia da base de dados Cochrane. [dissertação]. Botucatu, SP: Faculdade de Medicina, Universidade Estadual Paulista; 2018.

Justificativa e objetivos: A Colaboração Cochrane visa oferecer, por meio da publicação de revisões sistemáticas, informações atualizadas, objetivas e com evidências consistentes para a prática clínica e para o estabelecimento de políticas de saúde. Entretanto, verifica-se, frequentemente, uma inconsistência de evidências e incapacidade de gerar recomendações. O objetivo desse estudo foi analisar as revisões sistemáticas do Grupo Oftalmologia da Colaboração Cochrane e mapear sua utilidade para a prática clínica e para a pesquisa científica. **Método:** Realizou-se estudo transversal com análise de todas as revisões sistemáticas publicadas no Grupo Oftalmologia da Colaboração Cochrane até maio de 2018, verificando-se qual o tipo de recomendação para a prática clínica e para a pesquisa científica, por meio da análise das conclusões de seus autores. Além disso, computou-se o número de ensaios clínicos e meta-análises por revisão sistemática e por subespecialidade, por ano. **Resultados:** 202 revisões foram obtidas no período. Evidências que apoiam a intervenção, com recomendação para a realização de mais estudos ou sem recomendação para mais estudos: 36,3% [IC 95% 36,2-36,4] e 5,0% [IC 95% 4,8-5,1], respectivamente. Evidências contrárias à intervenção, com recomendação para realização de mais estudos ou sem recomendação para mais estudos: 3,0% [IC 95% 2,8-3,1] e 3,5% [IC 95% 3,3-3,6], respectivamente. Ausência de evidências, com recomendação para a realização de mais estudos ou sem recomendação para mais estudos: 51,2% [IC 95% 55,1-55,3] e 1% [IC 95% 0,9-1,1], respectivamente. Do total, 90,5% das revisões sugerem a realização de mais estudos independentemente dos resultados obtidos. O número médio de ensaios clínicos nas revisões foi de 7,4, variando entre zero e 137, e o número médio de meta-análises foi igual a 3,1, variando entre zero e 26. **Conclusão:** A maioria das revisões sistemáticas do Grupo de Oftalmologia da Cochrane apresenta insuficiência ou ausência de evidências para recomendar determinada intervenção na prática clínica e recomenda a realização de novos estudos clínicos controlados e aleatorizados. **Palavras-chave:** Oftalmologia, Revisão Sistemática, Meta-análise, Colaboração Cochrane, Pesquisa Científica

ABSTRACT

Bissoli SFR. Mapping of the evidences of systematic reviews of Ophthalmology Cochrane database. [dissertation]. Botucatu, SP: Botucatu Medical School, State University of São Paulo 2018.

Rationale and objectives: The Cochrane Collaboration aims to provide, through the publication of systematic reviews, up-to-date, objective information and with consistent evidence for clinical practice and for the establishment of health policies. However, there is often an inconsistency of evidence and inability to generate recommendations. The objective of this study was to analyze the systematic reviews of the Cochrane Collaboration Ophthalmology Group and to map its usefulness to clinical practice and to scientific research. **Methods**: A cross-sectional study was carried out with an analysis of all the systematic reviews published in the Ophthalmology Group of the Cochrane Collaboration until May 2018, confirming the type of recommendation for clinical practice and for scientific research, through analysis of the conclusions of its authors. In addition, we counted the number of clinical trials and meta-analyzes by systematic review and by subspecialty, per year. **Results**: 202 revisions were obtained in the period. Evidence that supports the intervention, with recommendation for further studies: 36.3% [CI 95% 36.2-36.4] or no recommendation for further studies: 5.0% [CI 95% 4.8-5.1]. Evidence contrary to intervention, with recommendation for further studies 3.0% [CI 95% 2.8-3.1] or no recommendation for further studies 3.5% [CI 95% 3.3-3.6). Absence of evidence, with recommendation for further studies: 51.2% [CI 95% 55.1-55.3] or no recommendation for further studies 1% [CI 95% 0.9-1.1] . Of the total, 90.5% of the reviews suggest further studies regardless of the results obtained. The mean number of clinical trials in the reviews was 7.4 (ranging from zero to 137), and the mean number of meta-analyzes was 3.1 (ranging from zero to 26).**Conclusion**: Most systematic reviews of the Cochrane Ophthalmology Group show insufficiency or lack of evidence to recommend a particular intervention in clinical practice and recommends further controlled and randomized clinical trials.

Keywords: Ophthalmology, Systematic review, Meta-analysis, Cochrane, collaboration, Scientific research.

Lista de Figuras

Figura 1	Demonstrativo dos níveis de evidências segundo o tipo de estudo, para a tomada de decisão nos cuidados com a saúde para tratamento e prevenção	20
Figura 2	Figura ilustrativa do logotipo da Colaboração Cochrane	23
Figura 3	Modelo de tabela padrão para registro dos resultados coletados no estudo	33
Figura 4	Número de revisões sistemáticas publicadas anualmente a partir de 2005, no Grupo Oftalmologia da Colaboração Cochrane.	40
Figura 5	Número de meta-análises publicadas anualmente a partir de 2005, no Grupo Oftalmologia da Colaboração Cochrane.	41
Figura 6	Número de estudos incluídos e meta-nálises publicadas a cada ano, a partir de 2005, no Grupo Oftalmologia da Colaboração Cochrane.	41
Figura 7	Percentagens de desfechos avaliados como benéficos, nocivos, inconclusivos com ou sem recomendação para novos estudos.	43
Figura 8	Número de revisões sistemáticas publicadas por subáreas da Oftalmologia.	45
Figura 9	Classificação das revisões sistemáticas por subárea da Oftalmologia conforme evidência e recomendação de novos estudos.	46

Lista de Tabelas e Quadro

Quadro 1	Classificação comparativa dos resultados de estudos de diversas áreas de saúde com revisões sistemáticas da Colaboração Cochrane.	26
Tabela 1	Exemplo das três combinações possíveis como resultado para prática clínica.	34
Tabela 2	Dados estatísticos relacionados aos estudos incluídos e metanálises nas revisões sistemáticas analisadas.	39
Tabela 3	Dados dos desfechos das 201 revisões sistemáticas analisadas	44

Lista de Abreviaturas

BMJ – British Medical Journal

CC – Colaboração Cochrane

IC – Intervalo de Confiança

ECR – Ensaio Clínico Randomizado

ECRs – Ensaios Clínicos Randomizados

MBE – Medicina Baseada em Evidência

RS – Revisão Sistemática

RSs – Revisões Sistemáticas

Sumário

1. INTRODUÇÃO..... 15

1.1 Medicina Baseada em evidência ……..... 15

1.2 Níveis de evidência e qualidade dos estudos..... 18

1.3 A Colaboração Cochrane e as Revisões Sistemáticas..... 21

1.4 Meta-análise……..... 22

1.5 Revisões Sistemáticas e Evidência..... 24

1.6 Pergunta Científica……..…… 27

1.7 Hipótese..... 27

2. OBJETIVOS 28

2.1 Objetivo geral..... 29

2.2 Objetivos específicos..... 29

3. MÉTODO..... 30

3.1 Tipo de estudo..... 31

3.2 Local do estudo..... 31

3.3 Critérios de inclusão..... 31

3.4 Critérios de exclusão..... 31

3.5 Tamanho da amotra …… 32

3.6 Definições dos eventos a serem computados..... 32

3.6.1 Benefício..... 32

3.6.2 Malefício..... 32

3.6.3 Objetivos especificos/Desfechos 32

3.6.3.1 Proporção das revisões sistemáticas que permitem concluir pelos beneficios ou malefícios da intervenção (classificação A ou B)……..……..... 32

3.6.3.2 Proporção das revisões sistemáticas que sugeriram recomendações de estudos para pesquisa cientifica ……..... 34

3.6.3.3 Quantidade de meta-análises existentes em cada revisão sistemática..... 36

3.6.3.4 Quantidade de meta-análises existentes em cada revisão sistemática..... 37

3.6.4 Desfechos…….. 37

3.7 Análise estatística..... 37

4. RESULTADOS..... 38

5. DISCUSSÃO..... 47

5.1 Discussão do método..... 48

5.2 Discussão dos resultados..... 48

6. CONCLUSÕES..... 56

7.REFERÊNCIAS.BIBLIOGRÁFICAS..... 58

8. APÊNDICE..... 65

8.1 **Apêndice 1 -** *Abstract* das revisões sistemáticas da Colaboração Cochrane com desfechos que apoiam a intervenção com recomendação de novos estudos (A1) 66

8.2 **Apêndice 2 –** *Abstract* das revisões sistemáticas da Colaboração Cochrane com desfechos que apoiam a intervenção sem recomendação de novos estudos (A2)... 135

8.3 **Apêndice 3 –** *Abstract* das revisões sistemáticas da Colaboração Cochrane com desfechos que não apoiam a intervenção com recomendação de novos estudos (B1)…..... 140

8.4 **Apêndice 4 –** *Abstract* das revisões sistemáticas da Colaboração Cochrane com desfechos que não apoiam a intervenção, sem recomendação de novos estudos (B2)…..... 145

8.5 **Apêndice 5 –** *Abstract* das revisões sistemáticas da Colaboração Cochrane com ausência de evidências ou evidências insuficientes, com recomendação de novos estudos (C1)…..... 154

8.6 **Apêndice 6 –** *Abstract* das revisões sistemáticas da Colaboração Cochrane com ausência de evidências ou evidências insuficientes, sem recomendação de novos estudos (C2)…..... 265

9. ANEXOS…..... 267

9.1 Anexo 1. Parecer do comitê de ética..... 268

INTRODUÇÃO

1. Introdução

Nos últimos anos houve um extraordinário avanço nas pesquisas destinadas ao conhecimento médico. O número de subcategorias de doenças, testes diagnósticos e práticas terapêuticas aumentou dramaticamente, assim como o número de publicações científicas (1).

Quando se compara a produção científica conjunta de duas relevantes revistas inglesas, a BMJ e a *New England Journal of Medicine* durante todo o ano de 1992 (1100 artigos), com a incorporação média de 800 referências e 350 ensaios clínicos randomizados (ECR) ao *Medline* a cada semana, verifica-se a sobrecarga de informações geradas continuamente (2).

O desenvolvimento tecnológico ocorreu paralelamente à explosão das publicações científicas, proporcionando acesso mais abrangente e rápido para toda a comunidade científica. Entretanto, nem todas as pesquisas tem o mesmo nível de qualidade e validação e, muitas vezes, há dificuldade de identificação da informação correta diante das mais variadas fontes e recursos de pesquisas (3).

1.1. Medicina Baseada em Evidências

Até alguns anos atrás, a prática clínica era embasada somente em estudos fisiopatológicos, opiniões de especialistas, livros texto, pesquisa *in vitro* e estudos experimentais em animais. A medicina baseada em evidências (MBE) mudou este cenário, e se tornou o elo entre a boa pesquisa científica e a prática clínica. O conceito MBE foi criado pelo epidemiologista Gordon Guyatt em 1992,

mas sua definição clássica foi creditada à David Sackett como sendo o uso criterioso, judicioso e consciencioso da melhor evidência científica na administração dos cuidados médicos aos pacientes (4-7).

A MBE utiliza as evidências científicas com boa qualidade metodológica existentes e disponíveis na literatura para a aplicação de seus resultados na prática clínica (8). As evidências relacionadas aos procedimentos clínicos e tratamentos são expressadas por meio de fundamentos essenciais da MBE que são: eficácia, efetividade, eficiência e segurança (9).

A efetividade diz respeito ao tratamento que funciona em condições de mundo real enquanto a eficácia, ao tratamento que funciona em condições de mundo ideal. A eficiência avalia o custo e a acessibilidade do tratamento. E, por último, a segurança do procedimento atesta que uma intervenção possui características confiáveis que tornam improvável a ocorrência de algum efeito indesejável para o paciente (10).

A MBE é um processo abrangente que envolve algumas etapas (11, 12):

- definição do problema, por meio da formulação da questão clínica;
- busca das evidências disponíveis;
- avaliação crítica e imparcial dos dados obtidos em relação à validade interna (metodologia) e aplicabilidade na prática clínica (validade externa);
- implementação das evidências na prática e avaliação dos resultados.

A formulação de uma questão clínica é o alicerce da boa pesquisa, pois maximiza a recuperação de evidências nas bases de dados (13). Perguntas clínicas bem formuladas necessitam de quatro componentes essenciais:

- P, patients, pacientes, ou seja, a situação clínica (qual é a doença);

- I, intervention, intervenção (qual é o tratamento de interesse a ser testado);
- C, control group, grupo-controle (placebo, nenhuma intervenção ou outra intervenção); e
- O, outcome, desfecho clínico.

As quatro iniciais formam a sigla PICO.

Com a pergunta em mãos, classifica-se o tipo de estudo: etiologia, diagnóstico, terapêutica, prognóstico, profilaxia ou custo-benefício. Uma vez formulada a pergunta, saber-se-á qual o melhor desenho de pesquisa para respondê-la (14).

1.2. Níveis de evidências e qualidade dos estudos

O termo “nível de evidências” refere-se ao grau de informação proporcionada pelos diferentes desenhos de estudos como, por exemplo, os experimentais (modelos animais e *in vitro),* relatos de casos, série de casos, estudos caso-controle, coorte, estudos controlados e ensaios clínicos randomizados. Sabe-se que a metodologia de um estudo exerce grande influência nos seus resultados. Portanto, quanto maior o rigor e a qualidade metodológica da pesquisa, maior será o nível de evidências, a qualidade e a confiabilidade das informações geradas (15).

O melhor desenho de estudo para responder as questões sobre tratamento e prevenção são os ensaios clínicos randomizados (ECRs), pois são prospectivos, possuem pelo menos um grupo controle, são randomizados, o que possibilita a todos os indivíduos a mesma chance de

serem alocados tanto no grupo experimental como no grupo controle, e são mascarados para indivíduos, pesquisadores e avaliadores de desfechos (12,16).

Entretanto, existem algumas questões clínicas em que o processo de randomização esbarra em questões éticas como, por exemplo, quando envolvem não tratar um grupo ou expor indivíduos a risco. Outra dificuldade dos ECRs, principalmente nas áreas cirúrgicas, é o duplo cegamento, o que leva os pesquisadores a utilizarem a simulação (*sham, fake ou dunny*) de um procedimento cirúrgico na tentativa de mascará-lo, o que também pode ser considerado antiético em função da exposição dos participantes a riscos, como, por exemplo, os relacionados ao ato anestésico (17). Outro fator que pode interferir na força da evidência obtida no ECR é o tamanho amostral, que, em determinadas doenças mais raras, dificilmente será adequado. A variabilidade na qualidade metodológica e, muitas vezes, a ausência de evidências confiáveis nos ECRs dificultam a identificação da melhor conduta a ser seguida na prática clínica (16).

As revisões sistemáticas (RS), principalmente as com meta-análises, conseguem identificar e sintetizar as melhores evidências disponíveis sobre uma questão clínica e por este motivo são consideradas o nível I de evidência científica (18). São revisões da literatura baseadas em uma metodologia explícita, rigorosa e transparente que apresentam vantagens em relação às revisões narrativas tradicionais por utilizarem métodos que diminuem a ocorrência de viéses.

Nas revisões sistemáticas, o uso de dados quantitativos gera resultados otimizados e concretos, enquanto nas narrativas, os resultados são

inespecificos e amplos (19). Quanto maior a qualidade e menor a heterogeneidade dos estudos primários, particularmente dos ensaios clínicos randomizados, mais forte e mais confiável será a conclusão das revisões sistemáticas, com menor ocorrência de vieses em seus resultados (20).

A figura 1 descreve a hierarquia dos níveis de evidências para a tomada de decisões relacionadas aos cuidados dos pacientes para estudos relacionados a tratamento e prevenção (20).

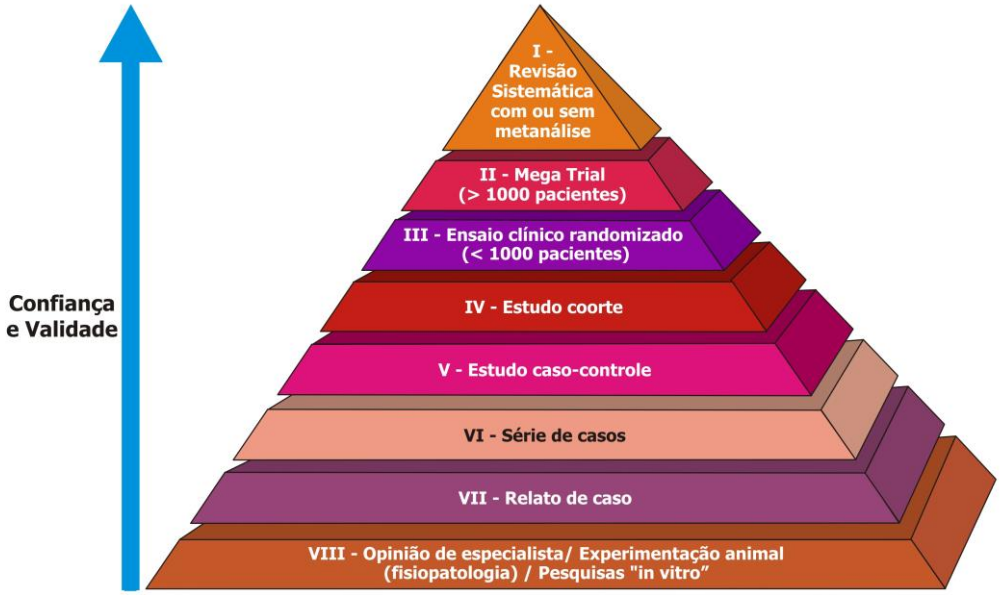

Figura 1. Demonstrativo dos níveis de evidências segundo o tipo de estudo, para a tomada de decisão nos cuidados com a saúde para tratamento e prevenção . Fonte: Cook *et al.,* 1995 (20).

No topo da pirâmide encontram-se as revisões sistemáticas com ou sem meta-análises, seguidas dos grandes ensaios clínicos randomizados, sendo que os mega *trials* (estudos com mais de 1000 pacientes) são classificados como de nível II de evidência, e os menores, de nível III.

Na sequência vêm os estudos observacionais sem randomização (coorte), estudos caso-controle (restrospectivos), séries de casos, relatos de caso, opiniões de especialistas, pesquisas com animais e pesquisas *in vitro* .

Se a questão clínica for relacionada a fatores de risco, prevalência de doenças ou sensibilidade e especificidade de um teste diagnóstico, a ordem dos níveis de evidência na pirâmide é diferente, ou seja, a hierarquia não é estática, variando conforme a pergunta clínica elaborada (8).

1.3. A Colaboração Cochrane e as Revisões Sistemáticas

A Colaboração Cochrane (CC) é uma organização internacional que tem como objetivo facilitar e coordenar a preparação e a atualização de revisões sistemáticas de ensaios clinicos randomizados sobre intervenções e atenção à saúde, bem como de estudos de acurácia e prognóstico, visando ajudar os profissionais da área da saúde a tomarem decisões clínicas bem informadas.

A CC foi criada em 1993 no Reino Unido, como uma empresa sem fins lucrativos, pelo Dr. Iain Chalmers, a pedido do Dr. Archie L. Cochrane, médico e pesquisador britânico que muito contribuiu para o desenvolvimento da Epidemiologia clínica (21,22). Atualmente, a Colaboração Cochrane possui

centros em vários países, inclusive no Brasil (Centro Cochrane do Brasil), fundado em 1997 na Universidade Federal de São Paulo.

A divulgação das evidências científicas dentro da CC é feita pela Cochrane Library, uma biblioteca virtual que mapeia os Ensaios Clínicos existentes sobre cada conduta, sendo, portanto, um banco de dados atualizado periodicamente e composto pelas seguintes bases de dados: Base de Dados Cochrane de Revisões Sistemáticas, Registro Cochrane de Ensaios Clínicos Controlados, Base de Dados de Avaliação Tecnológica em Saúde, Base de Dados de Metodologia de Revisões e Base de Dados NHS (*National Health Service*) de Avaliação Econômica (23).

A Cochrane Library também armazena as revisões sistemáticas com alta qualidade metodológica, confeccionadas pelos 53 grupos da CC, que abragem todas as especialidades médicas. O trabalho realizado pela Colaboração Cochrane tem causado profundo impacto na prática médica e nas políticas de saúde, e é de suma importância para a prática médica mundial (24).

1.4 Meta-análise

Meta-análise é um cálculo estatístico que integra os resultados de estudos primários para combinar os efeitos de determinado tratamento na área da saúde. As meta-análises podem aumentar o poder estatístico e a precisão da estimativa do efeito de um determinado tratamento, melhorando a confiança nos resultados. Tal ferramenta tem o potencial de resolver controvérsias da literatura, de chegar a conclusões que podem ser estatisticamente significantes, ou até mesmo inconclusivas (25).

Um exemplo claro para descrever o poder das meta-análises é demonstrado no logotipo da Colaboração Cochrane (Figura 2).

O símbolo da CC é formado por uma figura que representa, em sua parte central, um gráfico de meta-análise de sete ensaios clínicos randomizados.

Figura 2. Logotipo da Colaboração Cochrane (26).

Cada linha horizontal representa os resultados de um ensaio clínico e o diamante representa o resultado combinado de todos os ensaios clínicos. A posição do diamante para a esquerda da linha vertical indica que o tratamento estudado é benéfico. Se estivesse à direita, demonstraria que o tratamento é desfavorecido em relação ao grupo controle (24, 25).

Cada linha horizontal também expressa o intervalo de confiança (IC) a 95% de um ECR e representa o efeito do tratamento. Quanto maior o tamanho da amostra e a quantidade de eventos, menor é o IC e sempre que ele não ultrapassar a linha vertical, a probabilidade de acaso é menor que 5% (24).

A linha vertical, que marca o efeito nulo, ou seja, o *odds ratio* ou risco relativo, é igual a 1 e a diferença de risco absoluto, igual a zero. Isso quer dizer

que não houve diferença estatisticamente significante (24). À esquerda do eixo vertical encontram-se os resultados que apresentaram redução do risco devido ao tratamento estudado, ou um efeito benéfico do tratamento em relação ao grupo controle. À direita estão os resultados que significam ineficiência ou aumento de risco decorrente do tratamento, o que significa que o grupo controle obteve melhores resultados do que o grupo submetido ao novo tratamento (25). Quando a linha horizontal cruza a linha vertical significa que o resultado não é estatisticamente significante e o acaso pode ser responsável pela diferença encontrada (24, 25).

A meta-análise que serviu de modelo para o símbolo da CC, na época da criação do logotipo, foi relativa a um estudo sobre gravidez e cuidados perinatais. Eles procuravam responder à pergunta: o uso de corticosteroides no período próximo ao nascimento de bebês prematuros diminui a mortalidade neonatal? O resultado indicou o benefício do tratamento e permitiu adotar essa prática clínica como conduta baseada em evidências, com um saldo de muitas vidas salvas em todo o mundo (26).

1.5. Revisões Sistemáticas e Evidências

Apesar das numerosas vantagens, as revisões sistemáticas podem, com certa frequência, apresentar vieses e falhas, em função principalmente da baixa qualidade dos estudos originais incluídos, o que pode comprometer de forma crucial a estimativa de efeito do tratamento. Como consequência, o resultado

das meta-análises também pode ser afetado, levando à inconsistência das evidências e indução de erro nas implicações para a prática clínica (26).

Estudos recentes também mapearam as revisões da CC com o intuito de avaliar a qualidade das evidências geradas e sua aplicabilidade e verificaram a constante ausência ou insuficiência de evidências para a tomada de decisão clínica (27-32) .

Em 2007, uma pesquisa analisou 1.016 revisões sistemáticas de 50 grupos da CC, constatando alta prevalência de ausência ou pobreza de evidências relacionadas aos cuidados de saúde (27). Um segundo estudo, com a mesma metodologia, foi feito em 2012 com o intuito de verificar se o cenário havia mudado e se a produção de ensaios clínicos com evidências havia aumentado. Os autores encontraram menos de 5% de revisões sistemáticas com evidências suficientes para recomendar ou refutar o tratamento testado sem recomendação de novos estudos, demonstrando que o alto índice de incertezas se manteve acerca das recomendações clínicas (28).

Estudos semelhantes têm sido feitos com revisões sistemáticas de áreas da saúde, como a fisioterapia e odontologia e algumas especialidades médicas, como anestesiologia e moléstias infecciosas (29-32), apresentando também resultados que atestam a falta de evidências científicas e a necessidade de produção de estudos primários de qualidade (Quadro 1).

Quadro 1. Classificação comparativa dos resultados de estudos de diversas áreas de saúde com revisões sistemáticas da Colaboração Cochrane.

Estudo	Classificação das revisões sistemáticas					
	A1	**A2**	**B1**	**B2**	**C1**	**C2**
El Dib et al. 2007 (Especialidades médicas)	43,0%	1,4%	5,1%	1,7%	47,8%	1,0%
Villas Boas et al. 2012 (Especialidades médicas)	43,3%	2,0%	7,9%	1,8%	44,2%	0,8%
Almeida, et al. 2013 (Doenças Infecciosas)	46,1%	1,7%	8,2%	2,6%	40,9%	0,4%
Versiani et al. 2013 (Fisioterapia)	46%	0,5%	5,6%	0%	45,9%	1%
Santos, et al. 2013 (Anestesiologia)	37,2%	2,6%	7,7%	1,3%	51,3%	0%
Furtado et al, 2013 (Odontologia)	22,4%	0%	6,3%	0%	69,2%	2,1%

A1: Evidências que apoiam a intervenção, com recomendação para mais estudos.
A2: Evidências que apoiam a intervenção, sem recomendação para mais estudos.
B1: Evidências contra a intervenção, com recomendação para mais estudos.
B2: Evidências contra a intervenção, sem recomendação para mais estudos.
C1: Ausência de evidências ou evidências insuficientes, com recomendação para mais estudos.
C2: Ausência de evidências ou evidências insuficientes, sem recomendação para mais estudos.

A oftalmologia é uma especialidade médica caracterizada pela diversidade de subáreas, procedimentos cirúrgicos altamente tecnológicos e com grande número de publicações científicas.

O grupo Oftalmologia da Colaboração Cochrane (*Cochrane Eyes and Vision Review Group*) tem alcance globalizado assim como todos os outros grupos da organização e produz revisões sistemáticas da mais alta qualidade em todo o mundo. No entanto, não há na literatura nenhum estudo sistemático sobre a qualidade das evidências científicas disponíveis na área de Oftalmologia e as implicações destas para a prática clínica e pesquisa.

1.6 Pergunta científica

Diante do cenário atual das revisões sistemáticas, a questão emergente é: qual a proporção de incertezas nas revisões sistemáticas do Grupo Oftalmologia da Colaboração Cochrane no que diz respeito à aplicabilidade clínica dos resultados e sua implicação para as pesquisas científicas?

1.7 Hipótese

Como já verificado em estudo contemplando todos os grupos de revisão da base de dados Cochrane, será testada a hipótese de que a maioria das revisões sistemáticas do Grupo Oftalmologia da Colaboração Cochrane apresenta ausência de evidências para recomendar ou refutar as determinadas intervenções, quando comparadas ao grupo controle, e os autores, em sua maioria, recomendam a realização de mais estudos clínicos aleatorizados.

OBJETIVOS

2. Objetivos

2.1. - Objetivo geral

Verificar a proporção de revisões sistemáticas completas do Grupo Oftalmologia da base de dados Cochrane que permitem ou não a aplicação prática dos resultados, cujos autores consideram reunir evidências suficientes para recomendá-las ou refutá-las.

2.2. Objetivos específicos:

A) Verificar as revisões sistemáticas que fazem recomendações para a tomada de decisão em Oftalmologia, ou seja, implicações que concluem tanto pelo benefício quanto malefício em relação ao grupo controle.

B) Verificar a proporção de revisões sistemáticas que recomendam novos estudos para a pesquisa científica.

C) Verificar quantos estudos existem em média, em cada revisão sistemática.

D) Verificar quantas meta-análises existem em média, em cada revisão sistemática.

E) Verificar quantas revisões sistemáticas existem por subárea da oftalmologia e classificá-las conforme as evidências e a recomendação de novos estudos.

MÉTODOS

3. Métodos

Este estudo foi submetido ao Comitê de Ética em Pesquisa (CEP) da Faculdade de Medicina de Botucatu - UNESP, e dispensado do parecer por se tratar de estudo sistemático (Anexo 1).

3.1. Tipo de estudo

Estudo transversal sistemático.

3.2. Local do estudo

O estudo foi desenvolvido no Departamento de Oftalmologia. Otorrinolaringologia e Cirurgia de Cabeça e Pescoço da Faculdade de Medicina de Botucatu – UNESP.

3.3. Critérios de inclusão

Foram incluídas todas as revisões sistemáticas de ensaios clínicos randomizados do grupo Oftalmologia (*Eyes and Vision),* da Colaboração Cochrane, de acordo com a última atualização da Biblioteca Cochrane, datada de maio de 2018.

3.4. Critérios de exclusão

Foram excluídos protocolos de revisões sistemáticas, representações de meta-análises com apenas um estudo, revisões de estudos coortes e revisões sistemáticas removidas da Biblioteca Cochrane.

3.5. Tamanho da amostra

Foi considerada amostra de conveniência.

3.6. Definições dos eventos a serem computados

3.6.1. Benefício

Definiu-se como benefício a evidência de que a intervenção testada é mais eficiente ou eficaz, superior nos resultados dos desfechos em análise, ou mais vantajosa do que nociva quando comparada ao grupo controle.

3.6.2. Malefício:

Definiu-se como malefício a evidência de que a intervenção testada apresenta resultado inferior quanto aos desfechos em análise, é refutada pelo grupo controle, ou traz mais prejuízo do que benefício quando comparada ao grupo controle.

3.6.3. Objetivos específicos / desfechos

3.6.3.1. Proporção de revisões sistemáticas que permitem concluir pelos benefícios ou malefícios da intervenção (classificação A ou B).

Uma tabela padrão foi utilizada para classificar as RS quanto aos benefícios e malefícios (Figura 3). A coluna “evidências que apoiam a intervenção” foi preenchida com o número 1, quando as RS permitiram fazer recomendações sobre benefícios significantes para a aplicação prática. Da mesma forma, a coluna “evidências contra a intervenção” recebeu o número 1, quando as RS permitiram fazer recomendações significantes contra a intervenção testada

Título da revisão sistemática	Evidências que apoiam a intervenção “A”	Evidências contra a intervenção “B”	Recomendação de futuros estudos “1” ou “0”	Número de estudos incluídos	Número de meta-análises

Figura 3. Modelo de tabela padrão para registro dos resultados coletados no estudo.

Quando um estudo demonstrou não haver diferença entre as intervenções, ou seja, quando não houve evidências para responder à questão clínica, as colunas “*evidências que apoiam a intervenção*” e “*evidências contra a intervenção*” receberam o número zero (ausência de resposta). Consideramos esse preenchimento como falta de evidências, ou ausência de estudos para responder à pergunta da RS. Desta forma, foram obtidas três possíveis combinações:

1 e 0 □ Evidências que apoiam a intervenção testada (classificação A);

0 e 1 □ Evidência contra a intervenção testada (classificação B);

0 e 0 □ Ausência de evidências (classificação C).

A Tabela 1 ilustra as três combinações possíveis (A, B ou C) com exemplos de títulos de revisões sistemáticas na área de Oftalmologia.

Tabela 1. Exemplo das três combinações possíveis como resultado para prática clínica.

Classificação	Título da Revisão sistemática	Evidências que apoiam a intervenção	Evidências contra a intervenção
A: evidências favoráveis ao uso da intervenção	Antibióticos no momento da cirurgia de catarata para prevenir infecção bacteriana no olho (33)	1	0
B: evidências contrárias ao uso da intervenção	Laser no tratamento da degeneração macular relacionada à idade (34)	0	1
C: ausência de evidências	Trabeculoplastia a laser para glaucoma de ângulo aberto (35)	0	0

3.6.3.2. Proporção de revisões sistemáticas que sugeriram recomendações de futuros estudos para a pesquisa científica.

Quando as RS sugeriram recomendações de futuras pesquisas voltadas para a questão abordada enfatizando a necessidade de mais estudos para obterem melhores evidências, a coluna da tabela padrão "*recomendações para futuros estudos*" foi preenchida com o número 1**.** Entretanto, se o autor não sugeriu a realização de mais estudos, essa mesma coluna recebeu o número zero.

Dessa maneira, tivemos seis possíveis combinações do cruzamento das colunas "*evidências que apoiam a intervenção*", "*evidências contra a intervenção*" e "*recomendação de futuros estudos*":

1 e 0 e 1 → Evidências que apoiam a intervenção, com recomendação para mais estudos (**classificação A1**): Provas científicas que apoiam a utilização da intervenção testada, apesar de os autores não estarem muito certos do benefício da intervenção, quando comparada ao grupo controle, e recomendarem mais estudos para confirmar ou não o efeito da intervenção testada.

1 e 0 e 0 → Evidências que apoiam a intervenção, sem recomendação para mais estudos (**classificação A2**): Provas científicas suficientes que apoiam a utilização da intervenção testada, em que os autores estão confiantes do benefício da intervenção, quando comparada ao grupo controle, e dispensam a realização de mais estudos voltados para a mesma questão clínica.

0 e 1 e 1 → Evidências contra a intervenção, com recomendação para mais estudos (**classificação B1**): Provas científicas que contraindicam a utilização da intervenção testada, embora os autores não estejam muito certos do malefício da intervenção, quando comparada ao grupo controle, e recomendem mais estudos para refutar ou não o efeito da intervenção testada.

0 e 1 e 0 → Evidências contra a intervenção, sem recomendação para mais estudos (**classificação B2**): Provas científicas que contraindicam a utilização da intervenção testada, os autores estão confiantes do malefício da intervenção, quando comparada ao grupo controle, e dispensam a realização de mais estudos voltados para a mesma questão clínica.

0 e 0 e 1 → Ausência de evidências, com recomendação para mais estudos (**classificação C1**): Não há provas científicas de que uma intervenção traga mais benefícios ou malefícios, quando comparada ao grupo controle. Portanto, os autores recomendam a realização de estudos para responderem à questão abordada.

0 e 0 e 0 → Ausência de evidências, sem recomendação para mais estudos (**classificação C2**): Não há provas científicas de que uma intervenção traga mais benefícios ou malefícios, quando comparada ao grupo controle. Entretanto os autores, ao conduzirem a RS, perceberam que não seria viável economicamente a realização de mais estudos, ou em casos em que a pergunta não foi mais relevante e, dessa forma, desaprovaram a produção de novos estudos para a mesma questão.

"A", "B" e "C" são classificações das implicações para a prática clínica e "1" e "2", para a pesquisa científica.

3.6.3.3 Quantidade de estudos existentes em cada revisão sistemática

Como suporte para compreendermos as diferentes implicações nas revisões sistemáticas, computamos o número de ensaios clínicos incluídos em cada revisão sistemática. A contagem foi checada tanto na sessão resultados como nas tabelas de "características dos estudos incluídos". Quando houve discordância no relato da quantidade de ensaios clínicos, confrontamos também as referências dos estudos incluídos. Inserimos os dados na penúltima coluna da tabela padrão (Figura 3), denominada "número de estudos incluídos".

3.6.3.4. Quantidade de meta-análises existentes em cada revisão sistemática

Computamos as meta-análises que existiam em cada revisão sistemática e obtivemos a contagem no tópico "*Data and Analyses"* das mesmas. Inserimos os dados na última coluna da tabela padrão (Figura 3), denominada "número de meta-análises".

3.6.4 Desfechos

Os dados computados foram inseridos em um quadro final (Anexo 2), de acordo com as combinações descritas anteriormente.

No caso em que o tratamento favoreceu o desfecho primário e refutou o desfecho secundário, a classificação A foi estabelecida de acordo com a conclusão do desfecho primário. Da mesma forma, nos casos em que o tratamento refutou o desfecho primário e recomendou o desfecho secundário, foi considerada a classificação B, ou seja, evidências que contraindicam a intervenção.

3.7. Análise estatística

As proporções de implicações para a prática clínica e para a pesquisa científica foram representadas por números reais, porcentagens e 95% de IC da totalidade das RSs. As meta-análises e estudos incluídos em todos as RSs foram expressos em valor total, média, desvio-padrão, mediana e moda.

RESULTADOS

4. Resultados

Foram selecionadas 202 revisões sistemáticas publicadas no Grupo Oftalmologia da Colaboração Cochrane de janeiro de 2005 a maio de 2018. Uma revisão foi excluída por ter sido realizada somente com estudos observacionais não randomizados (Coorte). Desta forma, analisou-se um total de 201 RSs.

Na Tabela 2 são descritos os dados estatísticos referentes aos estudos incluídos (ECRs) e meta-análises nas RSs analisadas.

A média de ECRs por revisão sistemática foi 7,4 de um total de 1500 estudos (ECRs) e a de meta-análises por revisão sistemática foi de 3,1 (total de 634). Os dados demonstram uma variação considerável na quantidade de ECRs (0-137) sendo o valor mais frequente, o zero (moda).

Tabela 2. Dados estatísticos relacionados aos estudos incluídos e meta-análises nas revisões sistemáticas analisadas.

	Estudos incluídos (ECRS)	**Meta-análises**
Média	7,4 ± 13,4	3,1 ± 3,1
Mediana	3	1
Variação	0 a 137	0 a 29
Moda	0	0
Total	1500	634

Com relação às meta-análises, os resultados foram semelhantes aos dos estudos, com uma variação relativamente alta, entre 0 e 29, com um valor de moda zero.

A Figura 4 mostra a análise estratificada da distribuição anual de todas as revisões sistemáticas de Oftalmologia a partir do ano de 2005 até maio de 2018.

Observou-se número baixo de publicações entre 2005 e 2010, com duas a cinco revisões sistemáticas publicadas em cada ano e depois um aumento significativo no número de revisões nos últimos 7 anos.

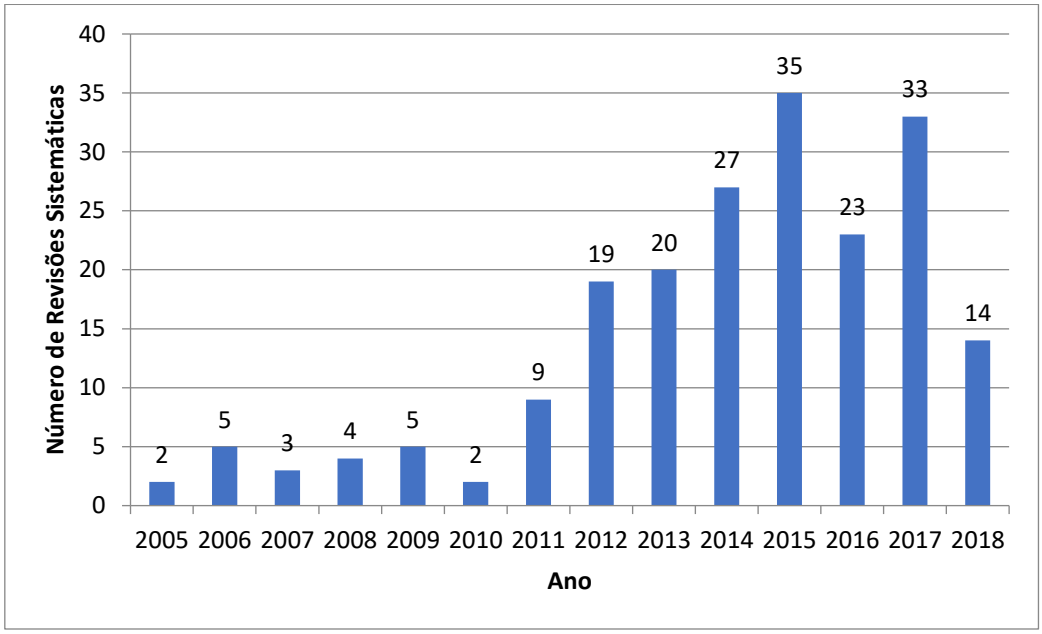

Figura 4. Número de revisões sistemáticas publicadas anualmente a partir de 2005, no Grupo Oftalmologia da Colaboração Cochrane.

A Figura 5 mostra o número de meta-análises publicadas anualmente a partir de 2005 no Grupo Oftalmologia da Colaboração Cochrane, podendo-se observar a baixa produção dos primeiros anos (2005-2010) e um aumento do volume relacionado ao crescimento do número de revisões, a partir do ano de 2011. O maior volume de publicações de metanálises, ocorreu no ano de 2017 (118).

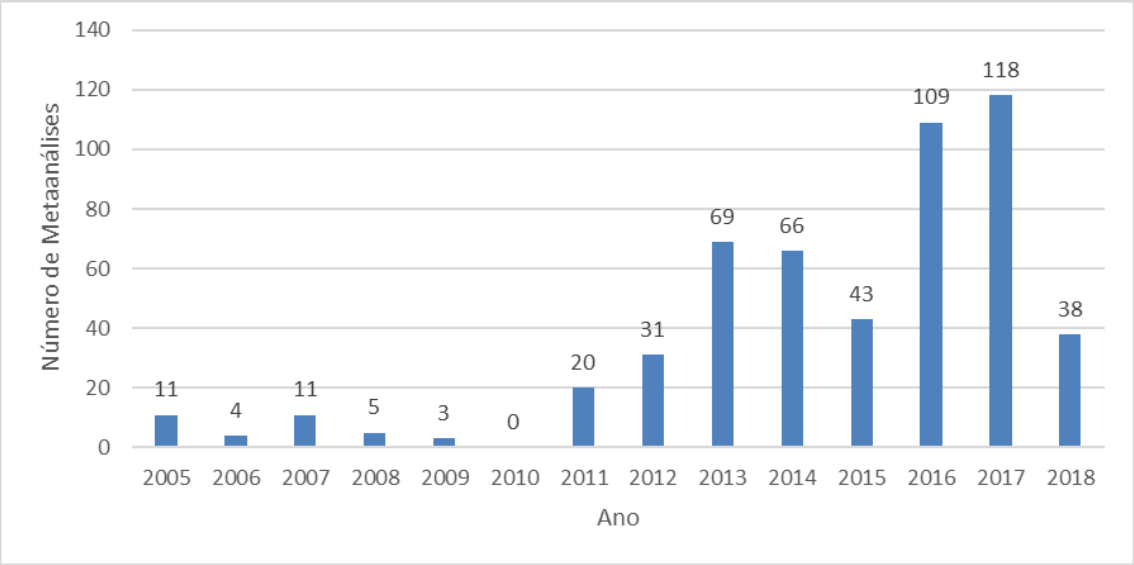

Figura 5. Número de meta-análises publicadas anualmente a partir de 2005 no Grupo Oftalmologia da Colaboração Cochrane.

A Figura 6 demonstra a relação entre o número de estudos (ECRs) incluídos nas revisões e o número de meta-análises publicadas anualmente desde 2005 até a finalização da coleta de dados do presente estudo.

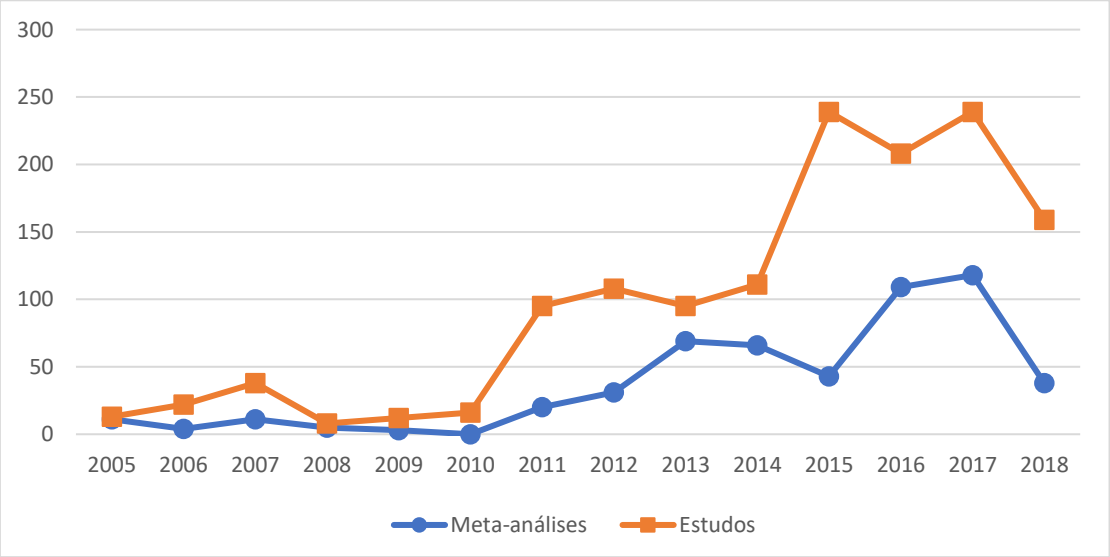

Figura 6. Número de estudos incluídos e meta-nálises publicadas a cada ano, a partir de 2005, no Grupo Oftalmologia da Colaboração Cochrane.

Com relação aos desfechos avaliados, a percentagem deles e a subdivisão nas seis classificações previstas (A1, A2, B1, B2, C1, C2) são apresentadas na Tabela 3 e na Figura 7.

O evento mais comumente observado no presente estudo foi a “ausência de evidências suficientes para dar suporte ou refutar a intervenção de interesse, quando comparado com o grupo controle”, 105 de 201 RSs de Oftalmologia (52,2%), que receberam a classificação C. Destas, houve recomendação de mais estudos em 103 (classificação C1). Somente em duas revisões as evidências foram suficientes para não recomendar a realização de novos estudos (classificação C2).

A proporção de evidências que “apoiam a intervenção quando comparada ao grupo controle” (classificação A) foi de 41,3% correspondendo a 83 revisões sistemáticas sendo: 36,3% de intervenções provavelmente benéficas, com necessidade de mais estudos (A1) e 5,0% de intervenções benéficas sem recomendação para novos estudos (A2).

A proporção de evidências que “contraindicam o uso de determinada intervenção” (classificação B) foi de 6,5%, perfazendo um total de 13 revisões sistemáticas, sendo que 3,0% recomendaram novos estudos (B1) e 3,5% das intervenções foram menos eficientes ou efetivas em relação ao grupo controle, com evidências suficientes para não recomendar a realização de novos estudos (B2).

No geral, em 182 de 201 revisões da CC analisadas (90,5%), houve recomendação de novas pesquisas para melhorar as evidências,

independentemente dos resultados obtidos (benefício, malefício ou ausência de evidência).

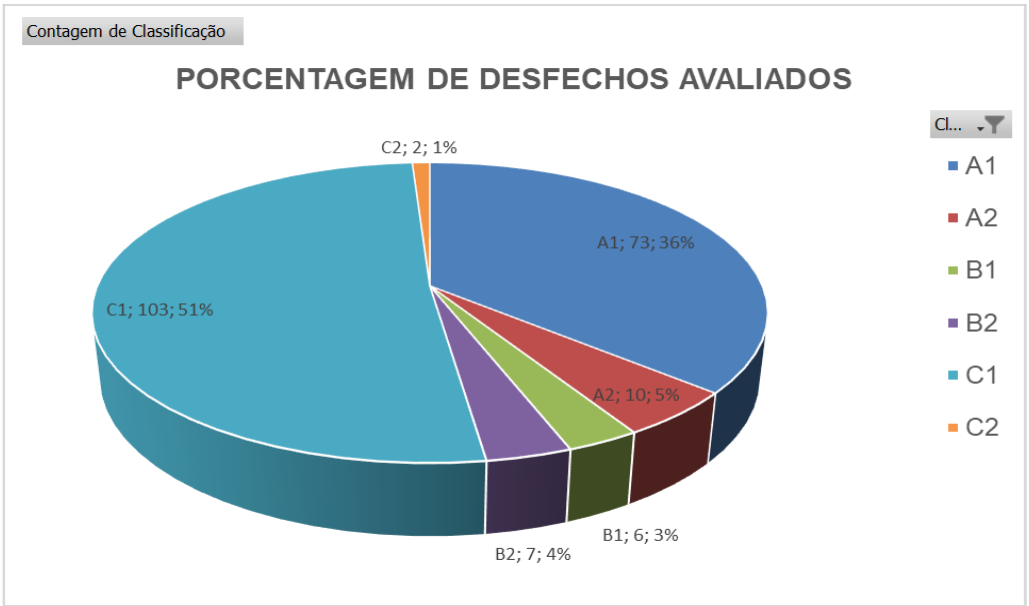

A1 apoiam com recomendação (ECRs) A2 apoiam sem recomendação ECRs
B1 contra, com recomendação (ECRs) B2 contra, sem recomendação de ECRs
C1 ausência, com recomendação de ECRs C2 ausência sem recomendação de ECRs

Figura 7. Percentagens de desfechos avaliados como benéficos, nocivos, inconclusivos com ou sem recomendação para novos estudos.

Tabela 3. Dados dos desfechos das 201 revisões sistemáticas analisadas

Implicações para a Prática Clínica e Pesquisa Científica		Número	Percentual (%)	Intervalo de confiança 95%
A	**Evidências que apoiam a intervenção**	**83**	**41,3**	**41,2-41,4**
A1	Evidências que apoiam a intervenção, com recomendação para mais estudos	73	36,3	36,2-36,4
A2	Evidências que apoiam a intervenção, sem recomendação para mais estudos	10	5,0	4,8-5,1
B	**Evidências contra a intervenção**	**13**	**6,5**	**6,3-6,6**
B1	Evidências contra a intervenção, com recomendação para mais estudos	6	3,0	2,8-3,1
B2	Evidências contra a intervenção, sem recomendação para mais estudos	7	3,5	3,3-3,6
C	**Ausência de evidências suficientes para sugerir benefício ou malefício**	**105**	**52,2**	**52,1-52,3**
C1	Ausência de evidências, com recomendação para mais estudos	103	51,2	51,1,-51,3
C2	Ausência de evidências, sem recomendação para mais estudos	2	1,0	0,9-1,1
Número e porcentagem de revisões sistemáticas que recomendaram mais estudos (A1 + B1+ C1)		182	90,5	90,5-90,6

A Figura 8 representa o panorama das revisões sistemáticas publicadas pelo Grupo Oftalmologia da Colaboração Cochrane quando analisadas por subáreas

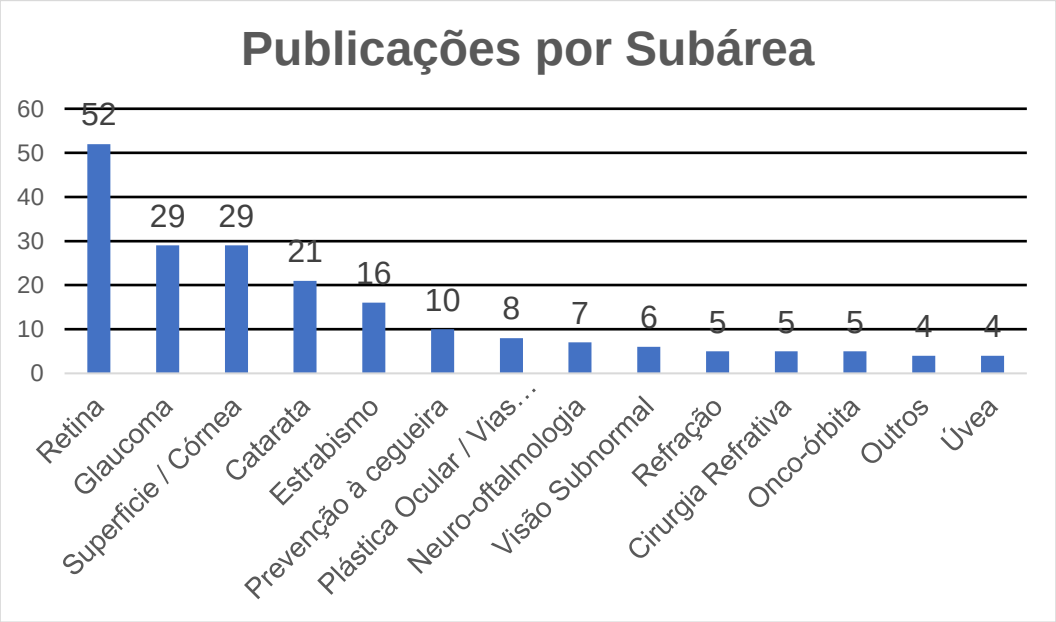

Figura 8. Número de revisões sistemáticas publicadas por subáreas da Oftalmologia

Observou-se na Figura 8 que a subárea mais produtiva foi a de Retina, com 52 revisões sistemáticas, seguida pelas de Glaucoma e Superfície Ocular/Córnea com 29, Catarata (21), Estrabismo (16), Prevenção à cegueira (10), Plástica Ocular/Vias Lacrimais (8), Neuro-Oftalmologia (7) e Visão Subnormal (6). As subáreas de Refração, cirurgia Refrativa, Onco-órbita originaram poucas revisões (5) e a de úvea foi a que menos produziu (4). Revisões que abordaram temas mistos foram agrupadas como “outros”(4).

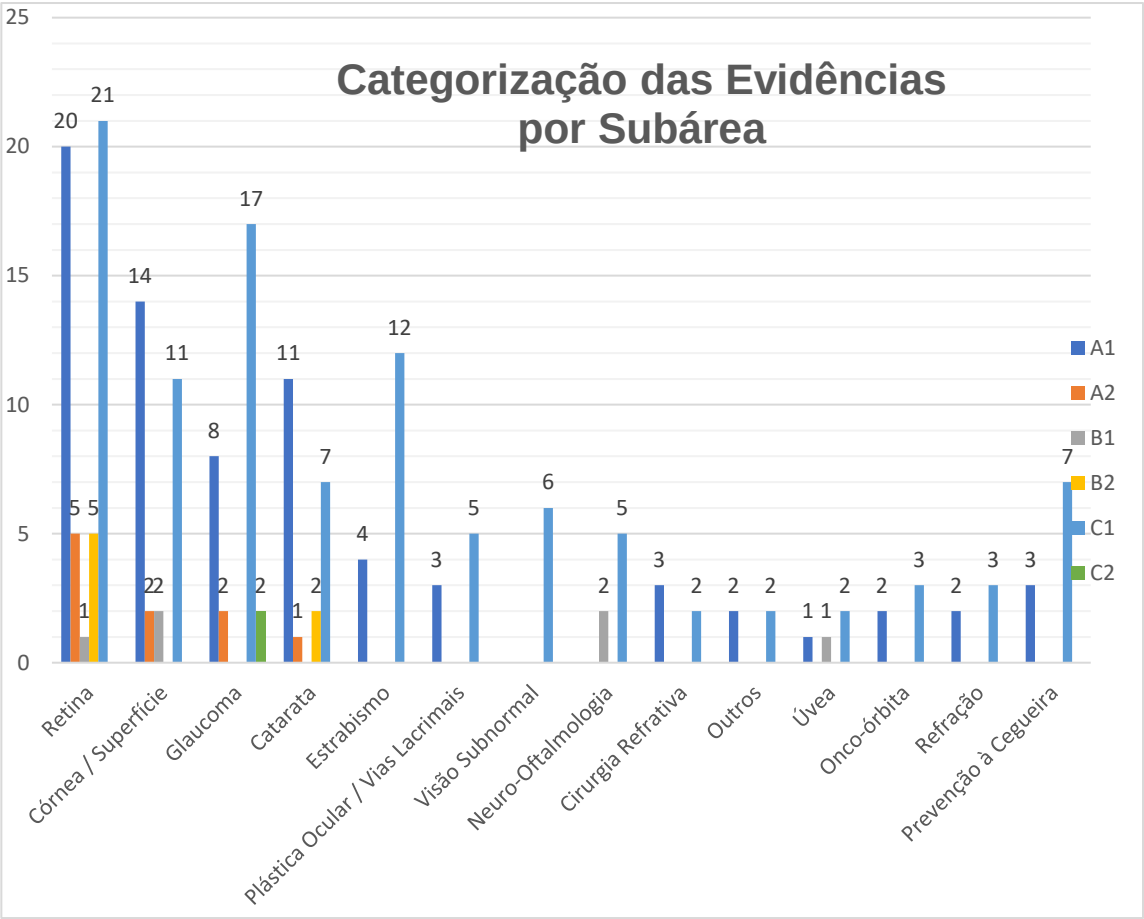

A1 apoiam com recomendação (ECRs) A2 apoiam sem recomendação ECRs
B1 contra, com recomendação (ECRs) B2 contra, sem recomendação de ECRs
C1 ausência, com recomendação (ECRs) C2 ausência sem recomendação de ECRs

Figura 9. Classificação das revisões sistemáticas por subárea da Oftalmologia conforme evidência e recomendação de novos estudos.

A Figura 9 demonstra a classificação das revisões sistemáticas em cada subárea da Oftalmologia nas categorias A1, A2, B1, B2, C1, e C2. **V**erificamos a predominância da cor azul no gráfico (C1 e A1), evidenciando a existência de evidências insuficientes e a necessidade de novos estudos.

DISCUSSÃO

5. Discussão

5.1 Discussão do método

O presente trabalho foi um estudo transversal sistemático, ou seja, aquele voltado para a análise da metodologia de estudos ou revisões publicadas (6). A metodologia seguiu padronização de El Dib *et al*., 2007 que já foi validada por outros estudos semelhantes na literatura (27-32).

A coleta de dados das revisões do Grupo de Oftalmologia da CC (*Eyes and Vision Group*) foi feita de maneira cuidadosa por dois revisores (SFRB e ECJ), no site da Cochrane *Library*. Um ponto crítico nesta fase do estudo foi a dificuldade em classificar revisões com temática muito ampla e com diversas intervenções de tratamento, dificultando a conclusão final em relação à questão original. Para classificá-las, os revisores levaram em consideração não só a conclusão, como também a "implicação para a pesquisa" e as "implicações para a prática clínica", declaradas pelos autores.

Outro obstáculo encontrado foi a falta de informações importantes para o presente estudo no *abstract* e nas conclusões de algumas revisões, o que dificultou a classificação das evidências.

6.2 Discussão dos resultados

Revisões sistemáticas e meta-análises se tornaram extremamente importantes na assistência à saúde e são instrumentos da Medicina Baseada em Evidência. Profissionais de saúde as lêem para se manterem atualizados em suas áreas e elas são frequentemente utilizadas como ponto de partida para o

desenvolvimento de instruções sobre práticas clínicas (36). Organizações governamentais de saúde, agências de fomento e até periódicos podem solicitar uma revisão sistemática para se assegurarem de que há necessidade de pesquisas adicionais em determinado assunto.

Como em toda pesquisa, o valor da revisão sistemática depende do que foi feito, do que foi descoberto e da clareza do relato. Assim como em outras publicações, a qualidade dos relatos das revisões sistemáticas varia, limitando a habilidade dos leitores de avaliar os pontos fortes e fracos dessas revisões (37).

A Colaboração Cochrane tem, há mais de 25 anos, a missão de fornecer a informação acessível e confiável para apoiar a tomada de decisão e as condutas clínicas, porém as evidências geradas tem sido, muitas vezes, insuficientes, o que tem sido motivo de severas críticas e constantes controvérsias (38).

Os resultados do presente estudo demonstraram a escassez de evidências sólidas produzidas pela maioria das revisões sistemáticas do Grupo Oftalmologia da Colaboração Cochrane. Mais da metade delas (52,2%) receberam a classificação C, ou seja, os ECRs incluídos nas revisões não tinham evidências suficientes para suportar ou refutar a intervenção de interesse e, por consequência, recomendaram mais estudos.

Estes achados refletem a inconsistência dos dados para a tomada de condutas na prática clínica diária. Podemos atribuir essa escassez de evidência a fatores comumente encontrados nos ECRs, como a baixa qualidade metodológica, a alta heterogeneidade de dados entre os estudos, a falta de padronização nos procedimentos e desfechos avaliados, e o tamanho amostral não representativo da população estudada (39-41). Com relação a este último

fator, uma análise meta-epidemiológica com 93 meta-análises de 735 ensaios randomizados controlados, oriundos de revistas de diversas especialidades (incluindo a base de dados da Colaboração Cochrane), mostrou grande variação no tamanho dos estudos dentro das meta-análises, estando os menores com maior probabilidade de superestimar o efeito positivo do tratamento testado e mais sujeitos a viés de publicação (41).

Um exemplo de revisão sistemática classificada na categoria C1 foi a intitulada “Corticóide associado a antibiótico versus antibiótico isolado para o tratamento de endoftalmite aguda após cirurgia ou injeções intra-oculares” (42). A questão clínica a ser verificada era se o uso de corticóides associados a antibióticos no tratamento da endoftalmite aguda poderiam aumentar a probabilidade de uma melhora na acuidade visual após três meses do quadro. Três estudos foram incluídos e dois entraram na meta-análise, porém não foi possível concluir se o uso de esteróides adjuvantes é efetivo pelas evidências atuais, sendo recomendado mais estudos.

Na categoria C2, classificou-se, por exemplo, a publicação “Acupuntura como modalidade de tratamento em pacientes com glaucoma”, que incluiu somente um ensaio clínico e, portanto, não apresentou meta-análise. Nesta revisão, os autores, por questões éticas relacionadas ao não oferececimento do tratamento padrão de glaucoma, já bem estabelecido ao grupo de intervenção, deseconselhou a realização de novos estudos. Os autores pretendem incluir 7 estudos chineses, que já estão em andamento, na próxima atualização da revisão (43).

Na avaliação dos resultados da proporção de evidências que “apoiam a intervenção quando comparada ao grupo controle” (classificação A), verificou-se

que somente em dez revisões (5%) não houve recomendação de mais estudos por parte dos autores, mostrando que, na maioria vezes, mesmo quando as evidências existiram, elas não foram suficientes para recomendar a intervenção.

Para exemplificar o grupo da classificação A1, temos a revisão intitulada "Antibióticos comparados com não tratamento ou placebo para retinocoroidite por Toxoplasmose". Apesar do uso de antibióticos em toxoplasmose ocular ser uma conduta muito utilizada na prática oftalmológica, os autores concluíram que o tratamento provavelmente reduz a recorrência da doença, mas que não existem boas evidências de melhora do resultado visual, havendo, portanto, necessidade de mais estudos para determinar a real influência do tratamento com antibióticos sobre o prognóstico funcional (44).

Ainda no grupo A1, uma revisão abordou um tema bastante controverso em oftalmologia, que é o uso de "Mitomicina para cirurgia de glaucoma". Apesar da evidência a favor da droga em ensaios clínicos individuais e nesta revisão sistemática, limitações éticas para a realização de estudos futuros envolvendo o não tratamento de pacientes com alto risco de perda visual impedem a comparação da droga com placebo. Conclusões definitivas sobre o risco de efeitos colaterais do uso de mitomicina exigiria uma amostra grande de pacientes no grupo de intervenção e placebo. Assim, a questão de risco e benefício da droga provavelmente não será totalmente respondida (45).

Apenas dez revisões foram classificadas como A2, onde as evidências apoiam a intervenção, sem recomendação para mais estudos. Uma revisão que pode servir de exemplo nesta categoria é a " Medida por tomografia de coerência óptica (OCT) da espessura da retina central para diagnosticar edema macular diabético", onde os autores concluíram que não há mais necessidade de novos

estudos pela existência de evidências fortes de que a OCT tem alta precisão e se tornou o novo padrão de referência para avaliação do edema macular diabético (46).

Nas revisões classificadas como B1 e B2 (evidências contra a intervenção), houve uma mudança no padrão visto nas categorias A e C, com uma percentagem ligeiramente maior de revisões que tiveram evidências suficientes para não recomendar novos estudos (3,5% de B2 contra 3% de B1).

Como exemplo da categoria B1, temos a revisão intitulada "D-Penicilamina para prevenção da retinopatia da prematuridade em prematuros", cujos autores verificaram não haver nenhum benefício com a intervenção testada e concluíram que a D-penicilamina não pode ser recomendada para a prevenção de ROP com base nas evidências disponíveis e por isso novos estudos devem ser planejados, visando principalmente verificar a segurança do uso da droga em prematuros (47).

No grupo B2, a revisão "Vitaminas antioxidantes para prevenir e retardar a progressão da catarata relacionada à idade", verificou que "não há evidências de que a suplementação com vitaminas antioxidantes (beta-caroteno, vitamina C ou vitamina E) previne ou retarda a progressão da catarata relacionada à idade. Não recomendamos estudos adicionais para examinar o papel destas vitaminas na prevenção ou desaceleração da progressão da catarata relacionada à idade. Custos e efeitos adversos devem ser pesados cuidadosamente com benefícios não comprovados, antes de recomendar sua ingestão acima das diárias recomendadas (48).

Avaliando os resultados obtidos nas seis categorias estudadas, em 90,5% das revisões sistemáticas houve recomendação para a realização de novos

estudos. Estes achados na área da Oftalmologia não são isolados e sim compatíveis com os de outros estudos, encontrados na literatura (27-32).

Vlassov et al. em 2004, avaliou 100 revisões Cochrane e descobriu que 93% delas concluíram fazendo recomendação de mais estudos (49). Resultados de mapeamentos feitos em outras áreas médicas variaram de 96 a 98% de recomendação de estudos (29-32).

Segundo El Dib et al., 2012 (27), a grande crítica à "Era da MBE" é a não contribuição da comunidade científica na produção de estudos primários de qualidade, multicêntricos, de acordo com protocolos sugeridos pela Colaboração Cochrane; levando à insuficiência de dados nas revisões sistemáticas e prejuízo para a prática clínica.

Na Oftalmologia, verificamos esta realidade. Os resultados deste estudo mostraram que apesar do número médio de ECRs incluídos por revisão ter sido razoável (sete), a variação foi muito grande e o valor mais encontrado foi zero, revelando um número grande de revisões que não conseguiram encontrar nenhum ECR para incluir. Com as meta-análises a situação foi semelhante, sendo frequente a ausência da análise quantitativa na revisão.

A área de Oftalmologia tem algumas particularidades que podem influir na qualidade dos ensaios clínicos e dificultar a inclusão deles em revisões sistemáticas. O processo de randomização (por olho), muito encontrado nestes estudos, se constitui em causa de viés importante, principalmente em procedimentos envolvendo administração de drogas em um olho, que podem ter absorção sistêmica e influenciar o resultado do olho adelfo. Outra questão alusiva à especialidade é a dificuldade de cegamento em intervenções que deixam marcas visíveis, como as que envolvem a aplicação de laser (47,48).

Os resultados do presente estudo contribuem para o entendimento da situação atual das evidências geradas pelas publicações científicas em Oftalmologia, oriundas de ensaios clínicos randomizados. Verificamos que houve um aumento do volume de publicações e meta-análises a partir de 2011 (Figuras 5 a 7), que pode estar associado ao reconhecimento por parte da comunidade científica da necessidade imperiosa de mais estudos robustos e com qualidade metodológica na área.

Com relação às sub-áreas da Oftalmologia analisadas, o destaque da Retina em número de revisões produzidas pode ser atribuído ao aumento de prevalência de doenças degenerativas, metabólicas e relacionadas ao envelhecimento da população, como, por exemplo, a doença macular relacionada à idade e a retinopatia diabética, temas que correspoderam a 25% dos estudos incluídos. Outro fator que pode estar relacionado é a influência da indústria farmacêutica como incentivadora de estudos com drogas antiangiogênicas, muito utilizadas atualmente no tratamento de doenças retinianas (50-51).

Esta influência provavelmente também está relacionada aos estudos das sub-áreas de glaucoma e córnea/superfície ocular, que têm um número grande de revisões avaliando drogas, como: “Medicamentos antivirais, interferon e remoção da superfície da córnea no tratamento da infecção pelo vírus do herpes simplex do olho”, que foi a que mais incluiu estudos (137).

Outra constatação do presente estudo foi que os resultados das classificações das evidências das sub-áreas isoladas foram semelhantes aos encontrados na análise conjunta das revisões da Oftalmologia, sendo a classificação mais frequente a C1.

Em conclusão, embora tenha havido grandes avanços nos últimos anos, ainda há grandes desafios à frente, a fim de obter um mapeamento das evidências em Oftalmologia. Muitas sub-áreas não foram muito bem pesquisadas, por falta de estudos de qualidade e os desafios da heterogeneidade e do viés de publicação dificulta conclusões firmes sobre muitos aspectos da prática baseada em evidências.

Diante dos dados obtidos neste estudo, fica claro que faltam evidências para a tomada de decisão na prática clínica oftalmológica e que, a realização de novas pesquisas científicas, de melhor qualidade e com maior rigor metodológico é imperiosa .

CONCLUSÕES

6. Conclusões

De acordo com os resultados obtidos neste estudo podemos concluir que:

- A proporção de RSs completas do grupo de Oftalmologia da CC que mostrou evidências suficientes e consistentes para recomendar ou refutar o tratamento de interesse sob investigação foi de 47,8%.

- A grande maioria das revisões avaliadas (90,5%) apontou para a recomendação de futuros estudos controlados e randomizados que forneçam resultados com evidências suficientes e consistentes para a tomada de decisão na prática clínica.

- O número de estudos incluídos e meta-análises por revisão sistemática foi muito baixo e insuficiente para auxiliar nas conclusões.

- As sub-áreas oftalmológicas apresentaram, na grande maioria, insuficiência de evidências, sendo a de Retina, a que mais produziu revisões sistemáticas.

REFERÊNCIAS

BIBLIOGRÁFICAS

7. Referências Bibliográficas

1. Hook O. Scientific communications. History, electronic journals and impact factors. Scand J Rehabil Med 1999; 31:3-7.

2. Mulrow CD. Rationale for systematic reviews. BMJ. 1994;309:597-599.

3. Glasziou P, Ogrinc G, Goodman S. Can evidence-based medicine and clinical quality improvement learn from each other? BMJ Qual Saf 2011;20 Suppl 1:i13-17.

4. Atallah AN. A incerteza, a ciência e a evidência. Diagn Tratamento. 2004; 9:27-28.

5. El Dib RP, Atallah AN. Fonoaudiologia baseada em evidências e o Centro Cochrane do Brasil. Diagn Tratamento. 2006;11:103-106.

6. Guyatt G, Cairns J, Churchill D, Cook D, Haynes B, Hirsh J et al. Evidence-Based Medicine: a new approach to teaching the practice of medicine. JAMA.1992;268(17):2420-2425.

7. Sackett DL, Straus S, Richardson S, Rosenberg W, Haynes RB. Evidence-based medicine: how to practice and teach. EBM. 2ª ed. ed. Londres: Churchill Livingstone; 2000. p.4

8. Modolo NSP. Classificação de eficácia-efetividade em ensaios clínicos/*the grading of efficacy-effectiveness in clinical trials* (*geect*): uma ferramenta *precis* modificada. In: Guia prático de Medicina Baseada em Evidências [recurso eletrônico] / organização Regina El Dib. – 1. ed. – São Paulo: Cultura Acadêmica, 2014.

9. El Dib RP, Atallah NA. Evidence-based speech, Language and hearing therapy and the Cochrane Library's systematic reviews. São Paulo Med J. 2006;124:51-54.

10. Straus SE, McAlister FA. Evidence-based medicine: a commentary on common criticisms. CMAJ. 2000;163:837-841.

11. El Dib RP. Níveis de evidências científicas na prática médica. In: Engelhorn CA, Morais Filho D, Barros FS, Coelho NA. Guia prático de ultrassonografia vascular. Rio de Janeiro: Di Livros; 2011. chap. 1.

12. Wyatt J, Guly H. Identifying the research question and planning the project. Emerg Med J. 2002;19(4):318-321.

13. Richardson WS. Ask, and ye shall retrieve. *Evid Based Med*. 1998;3:100-101.

14. Juni P, Altman DG, Egger M. Systematic reviews in health care: Assessing the quality of controlled clinical trials. BMJ 2001;323:42-46.

15. Jadad A. Randomized controlled trials: a user'"s guide. BMJ 1998; 1:1-3.

16. Hong S, Miller FG. Ethical framework for the use of sham procedures in clinical trials. Crit Care Med. 2003; 31(3 Suppl): S126-130.

17. Greenhalgh T, Robert G, Macfarlane F, Bate P, Kyriakidou O. Diffusion of innovations in service organizations: systematic review and recommendations. Milbank Q. 2004; 82(4):581-629.

1. Montori VM, Wilczynski NL, Morgan D, Haynes RB. Optimal search strategies for retrieving systematic reviews from Medline: analytical survey. BMJ. 2005; 330(7482):68.

19. Mulrow CD. Rationale for systematic reviews. BMJ. 1994;309:597-599.

20. Cook DJ, Guyatt GH, Laupacis A, Sackett DL, Goldberg RJ. Clinical recommendations using levels of evidence for antithrombotic agents. Chest 1995;108:227S-230S.

21. Bero L, Rennie D. The cochrane collaboration. J Am Med Assoc. 1995; 274(24):1935-938.

22. Jadad AR, Haynes RB. The Cochrane Collaboration-advances and challenges in improving evidence-based decision making. Med Decis Making. 1998; 18(1):2-9.

23. El Dib RP, Atallah AN. Cochrane Library: como pesquisar? Diag Tratamento. 2005;101(1):31-34.

24. Atallah AN. revisões sistemáticas da literatura e metanálise. Diagn Tratamento. 1997;2 (*2*):12-15.

25. Rosenthal R, Di Matteo MR. Meta-analysis: recent developments in quantitative methods for literature reviews. Ann Rev Psychol. 2001;52(1):59-82.

26. Cocrhane Brasil [homepage na internet]. Logo Cochrane [acesso em 07 de outubro de 2018]. Disponível em: https://brazil.cochrane.org/logo-cochrane

27. El Dib RP, Atallah AN, Andriolo RB. Mapping the Cochrane evidence for decision making in health care. J Eval Clin Pract 2007;13:689-692.

28. Villas Boas PJ, Spagnuolo RS, Kamegasawa A, Braz LG, Polachini do Valle A, Jorge EC et al. Systematic reviews showed insufficient evidence for clinical practice in 2004: what about in 2011? The next appeal for the evidence-based medicine age. J Eval Clin Pract 2013;19:633-637.

29. Almeida A, Ferreira Filho SP, Cavalcante RS, Nascimento Junior P, El Dib RP. Mapping the Cochrane evidence in infectious diseases. Forthcoming 2013.

30. Versiani AHV, Martimbianco AC, Peccin MS. Mapeamento das evidências de revisões sistemáticas da colaboração cochrane para tomada de decisão em fisioterapia. São Paulo Med J. 2013; 131(1):39-45.

31. Furtado SC. Mapeamento das evidências do grupo de odontologia da Colaboração Cochrane para condutas em saúde. Tese de Doutorado. Botucatu. Faculdade de Medicina de Botucatu - UNESP, 2014.

32. Santos Jr RS. Mapeamento das evidências das revisões sistemáticas do Grupo Anestesiologia da Colaboração Cochrane: entendendo seu valor para a prática clínica. Tese de Mestrado. Botucatu. Faculdade de Medicina de Botucatu – UNESP, 2014.

33. Gower EW, Lindsley K, Tulenko SE, Nanji AA, Leyngold I, McDonnell PJ. Perioperative antibiotics for prevention of acute endophthalmitis after cataract surgery. The Cochrane database of systematic reviews. 2017;2:CD006364.

34. Virgili G, Bini A. Laser photocoagulation for neovascular age-related macular degeneration. Cochrane Database of Systematic Reviews 2007;3: CD004763.

35. Rolim de Moura CR, Paranhos Jr A, Wormald R. Laser trabeculoplasty for open angle glaucoma. Cochrane Database of Systematic Reviews 2007,4: CD003919.

36. Swingler GH, Volmink J, Ioannidis JP. Number of published systematic reviews and global burden of disease: database analysis. BMJ. 2003;327(7423):1083-1084.

37. Young C, Horton R. Putting clinical trials into context. Lancet. 2005 ;366(9480):107-108.

38. Moller AM. How to map the evidence: the development of the systematic review in anaesthesia. Br J Anaesth. 2012;109:32-4.

39. Hopewell S, Dutton S, Yu LM, Chan AW, Altman DG. The quality of reports of randomised trials in 2000 and 2006: comparative study of articles indexed in PubMed. BMJ. 2010;340:c723.

40. Higgins J. The Cochrane Handbook for Systematic Reviews of Interventions, 2008. 633p.

41. Dechartres A Trinquart L Boutron I Ravaud P. Influence of trial sample size on treatment effect estimates: meta-epidemiological study. BMJ. 2013;346:f2304.

42. Mehta H, Hennings C, Gillies MC, Nguyen V, Campain A, Fraser-Bell S. Anti-vascular endothelial growth factor combined with intravitreal steroids for diabetic macular oedema. Cochrane Database of Systematic Reviews. 2018;4: CD011599.

43. Law SK, Li T. Acupuncture for glaucoma. Cochrane Database of Systematic Reviews 2013;5: CD006030.

44. Pradhan E, Bhandari S, Gilbert RE, Stanford M. Antibiotics versus no treatment for toxoplasma retinochoroiditis. Cochrane Database of Systematic Reviews 2016; 5. Art: CD002218.

45. Wilkins M, Indar A, Wormald R. Intraoperative Mitomycin C for glaucoma surgery. Cochrane Database of Systematic Reviews 2005; 4.: CD002897.

46. Virgili G, Menchini F, Casazza G, Hogg R, Das RR, Wang X, Michelessi M. Optical coherence tomography (OCT) for detection of macular oedema in patients with diabetic retinopathy. Cochrane Database of Systematic Reviews. 2015;1.: CD008081.

47. Qureshi MJ, Kumar M. D-Penicillamine for preventing retinopathy of prematurity in preterm infants. Cochrane Database of Systematic Reviews. 2013;9: CD001073.

48. Mathew MC, Ervin A-M, Tao J, Davis RM. Antioxidant vitamin supplementation for preventing and slowing the progression of age-related cataract. Cochrane Database of Systematic Reviews. 2012; 6: CD004567.

49. Vlassov V. Further research is needed? Cochrane Collaboration. Colloquia Abstracts. Ottawa, 2004. p. 155.

50. Tran KD, Cernichiaro-Espinosa LA, Berrocal AM. Management of Retinopathy of Prematurity--Use of Anti-VEGF Therapy. Asia Pac J Ophthalmol. 2018;7(1):56-62.

51. Glassman AR, Stockdale CR, Beck RW, Baker C, Bressler NM. Evaluation of masking study participants to intravitreal injections in a randomized clinical trial. Diabetic Retinopathy Clinical Research Network. Arch Ophthalmol. 2012;130(2):190-194.

APÊNDICE

8.1 Apêndice 1. *Abstracts* das revisões sistemáticas da Colaboração Cochrane com desfechos que apoiam a intervenção com recomendação de novos estudos **(A1)**.

[Intervention Review]

Accommodative intraocular lens versus standard monofocal intraocular lens implantation in cataract surgery

Hon Shing Ong[1], Jennifer R Evans[2], Bruce DS Allan[3]

[1]Moorfields Eye Hospital NHS Foundation Trust, London, UK. [2]Cochrane Eyes and Vision Group, ICEH, London School of Hygiene & Tropical Medicine, London, UK. [3]External Disease Service, Moorfields Eye Hospital NHS Foundation Trust, London, UK

Contact address: Hon Shing Ong, Moorfields Eye Hospital NHS Foundation Trust, 162 City Road, London, EC1V 2PD, UK. honshing@gmail.com.

Editorial group: Cochrane Eyes and Vision Group.
Publication status and date: New, published in Issue 5, 2014.

Citation: Ong HS, Evans JR, Allan BDS. Accommodative intraocular lens versus standard monofocal intraocular lens implantation in cataract surgery. *Cochrane Database of Systematic Reviews* 2014, Issue 5. Art. No.: CD009667. DOI: 10.1002/14651858.CD009667.pub2.

Copyright © 2014 The Cochrane Collaboration. Published by John Wiley & Sons, Ltd.

ABSTRACT

Background

Following cataract surgery and intraocular lens (IOL) implantation, loss of accommodation or postoperative presbyopia occurs and remains a challenge. Standard monofocal IOLs correct only distance vision; patients require spectacles for near vision. Accommodative IOLs have been designed to overcome loss of accommodation after cataract surgery.

Objectives

To define (a) the extent to which accommodative IOLs improve unaided near visual function, in comparison with monofocal IOLs; (b) the extent of compromise to unaided distance visual acuity; c) whether a higher rate of additional complications is associated the use of accommodative IOLs.

Search methods

We searched CENTRAL (which contains the Cochrane Eyes and Vision Group Trials Register) (*The Cochrane Library* 2013, Issue 9), Ovid MEDLINE, Ovid MEDLINE in-Process and Other Non-Indexed Citations, Ovid MEDLINE Daily Update, Ovid OLDMEDLINE (January 1946 to October 2013), EMBASE (January 1980 to October 2013), Latin American and Caribbean Health Sciences Literature Database (LILACS) (January 1982 to October 2013), the *meta*Register of Controlled Trials (*m*RCT) (www.controlled-trials.com), ClinicalTrials.gov (www.clinicaltrial.gov) and the WHO International Clinical Trials Registry Platform (ICTRP) (www.who.int/ictrp/search/en). We did not use any date or language restrictions in the electronic searches for trials. We last searched the electronic databases on 10 October 2013.

Selection criteria

We include randomised controlled trials (RCTs) which compared implantation of accommodative IOLs to implantation of monofocal IOLs in cataract surgery.

Data collection and analysis

Two authors independently screened search results, assessed risk of bias and extracted data. All included trials used the 1CU accommodative IOL (HumanOptics, Erlangen, Germany) for their intervention group. One trial had an additional arm with the AT-45 Crystalens accommodative IOL (Eyeonics Vision). We performed a separate analysis comparing 1CU and AT-45 IOL.

Copyright © 2014 The Cochrane Collaboration. Published by John Wiley & Sons, Ltd.

[Intervention Review]

Acupuncture for acute hordeolum

Ke Cheng[1], Andrew Law[2], Menghu Guo[1], L. Susan Wieland[3], Xueyong Shen[4], Lixing Lao[5]

[1]School of Acupuncture-Moxibustion and Tuina, Shanghai University of Traditional Chinese Medicine, Shanghai, China. [2]Department of Epidemiology, Johns Hopkins Bloomberg School of Public Health, Baltimore, Maryland, USA. [3]Center for Integrative Medicine, University of Maryland School of Medicine, Baltimore, Maryland, USA. [4]School of Acupuncture-Moxibustion and Tuina, Shanghai University of Traditional Chinese Medicine, Shanghai Research Center of Acupuncture & Meridians, Shanghai Key Laboratory of acupuncture mechanism and acupoint function, Shanghai, China. [5]School of Chinese Medicine, The University of Hong Kong, Hong Kong, China

Contact address: Xueyong Shen, School of Acupuncture-Moxibustion and Tuina, Shanghai University of Traditional Chinese Medicine, Shanghai Research Center of Acupuncture & Meridians, Shanghai Key Laboratory of acupuncture mechanism and acupoint function, 1200, Cailun RD, Shanghai, 201203, China. snowysh@hotmail.com.

Editorial group: Cochrane Eyes and Vision Group.
Publication status and date: New, published in Issue 2, 2017.

Citation: Cheng K, Law A, Guo M, Wieland LS, Shen X, Lao L. Acupuncture for acute hordeolum. *Cochrane Database of Systematic Reviews* 2017, Issue 2. Art. No.: CD011075. DOI: 10.1002/14651858.CD011075.pub2.

Copyright © 2017 The Cochrane Collaboration. Published by John Wiley & Sons, Ltd.

ABSTRACT

Background

Hordeolum is an acute, purulent inflammation of the eyelid margin usually caused by obstructed orifices of the sebaceous glands of the eyelid. The condition, which affects sebaceous glands internally or externally, is common. When the meibomian gland in the tarsal plate is affected, internal hordeolum occurs, while when the glands of Zeis or Moll associated with eyelash follicles are affected, external hordeolum, or stye occurs. The onset of hordeolum is usually self limited, and may resolve in about a week with spontaneous drainage of the abscess. When the condition is severe, it can spread to adjacent glands and tissues. Recurrences are very common. As long as an internal hordeolum remains unresolved, it can develop into a chalazion or generalized eyelid cellulitis. Acupuncture is a traditional Chinese medical therapy aimed to treat disease by using fine needles to stimulate specific points on the body. However, it is unclear if acupuncture is an effective and safe treatment for acute hordeolum.

Objectives

The objective of this review was to investigate the effectiveness and safety of acupuncture to treat acute hordeolum compared with no treatment, sham acupuncture, or other active treatment. We also compared the effectiveness and safety of acupuncture plus another treatment with that treatment alone.

Search methods

We searched CENTRAL, Ovid MEDLINE, Ovid MEDLINE In-Process and Other Non-Indexed Citations, Ovid MEDLINE Daily, Ovid OLDMEDLINE, Embase, PubMed, Latin American and Caribbean Health Sciences Literature Database (LILACS), three major Chinese databases, as well as clinical trial registers all through 7 June 2016. We reviewed the reference lists from potentially eligible studies to identify additional randomised clinical trials (RCTs).

Selection criteria

We included RCTs of people diagnosed with acute internal or external hordeola. We included RCTs comparing acupuncture with sham acupuncture or no treatment, other active treatments, or comparing acupuncture plus another treatment versus another treatment alone.

Copyright © 2017 The Cochrane Collaboration. Published by John Wiley & Sons, Ltd.

[Intervention Review]

Aflibercept for neovascular age-related macular degeneration

Salman Sarwar[1], Elizabeth Clearfield[2], Mohamed Kamel Soliman[1], Mohammad Ali Sadiq[1], Andrew J Baldwin[1], Mostafa Hanout[1], Aniruddha Agarwal[1], Yasir J Sepah[1], Diana V Do[1], Quan Dong Nguyen[1]

[1]Stanley M. Truhlsen Eye Institute, University of Nebraska Medical Center, Omaha, Nebraska, USA. [2]Department of Epidemiology, Johns Hopkins Bloomberg School of Public Health, Baltimore, Maryland, USA

Contact address: Salman Sarwar, Stanley M. Truhlsen Eye Institute, University of Nebraska Medical Center, 3902 Leavenworth Street, Omaha, Nebraska, 68105, USA. ss@oirrc.net.

Editorial group: Cochrane Eyes and Vision Group.
Publication status and date: New, published in Issue 2, 2016.

Citation: Sarwar S, Clearfield E, Soliman MK, Sadiq MA, Baldwin AJ, Hanout M, Agarwal A, Sepah YJ, Do DV, Nguyen QD. Aflibercept for neovascular age-related macular degeneration. *Cochrane Database of Systematic Reviews* 2016, Issue 2. Art. No.: CD011346. DOI: 10.1002/14651858.CD011346.pub2.

Copyright © 2016 The Cochrane Collaboration. Published by John Wiley & Sons, Ltd.

ABSTRACT

Background

Central vision loss caused by age-related macular degeneration (AMD) is the leading cause of blindness among the elderly in developed countries. Neovascular AMD is characterized by choroidal neovascularization (CNV). Growth of new blood vessels in patients with neovascular AMD is driven by a complex process that involves a signal protein called vascular endothelial growth factor A (VEGF-A). Anti-VEGF drugs that block this protein include ranibizumab, bevacizumab, and aflibercept.

Objectives

To assess and compare the effectiveness and safety of intravitreal injections of aflibercept versus ranibizumab, bevacizumab, or sham for treatment of patients with neovascular AMD.

Search methods

We searched the Cochrane Central Register of Controlled Trials (CENTRAL) (which contains the Cochrane Eyes and Vision Trials Register) (Issue 11, 2015), Ovid MEDLINE, Ovid MEDLINE In-Process and Other Non-Indexed Citations, Ovid MEDLINE Daily, Ovid OLDMEDLINE (January 1946 to November 2015), EMBASE (January 1980 to November 2015), PubMed (1948 to November 2015), Latin American and Caribbean Health Sciences Literature Database (LILACS) (1982 to November 2015), the *meta*Register of Controlled Trials (*m*RCT) (www.controlled-trials.com) (last searched December 4, 2014), ClinicalTrials.gov (www.clinicaltrials.gov), and the World Health Organization (WHO) International Clinical Trials Registry Platform (ICTRP) (www.who.int/ictrp/search/en). We did not use any date or language restrictions in the electronic search for trials. We last searched the electronic databases on November 30, 2015.

Selection criteria

We included randomized controlled trials (RCTs) in which aflibercept monotherapy was compared with ranibizumab, bevacizumab, or sham for participants with neovascular AMD who were treatment-naive.

Data collection and analysis

We used standard methodological procedures of The Cochrane Collaboration for screening, data abstraction, and study assessment. Two review authors independently screened records, abstracted data, and assessed risk of bias of included studies; we resolved discrepancies by discussion or with the help of a third review author when needed.

[Intervention Review]

Anti-vascular endothelial growth factor for diabetic macular oedema: a network meta-analysis

Gianni Virgili[1], Mariacristina Parravano[2], Jennifer R Evans[3], Iris Gordon[3], Ersilia Lucenteforte[4]

[1]Department of Translational Surgery and Medicine, Eye Clinic, University of Florence, Florence, Italy. [2]Ophthalmology, Fondazione G.B. Bietti per lo studio e la ricerca in Oftalmolologia-IRCCS, Rome, Italy. [3]Cochrane Eyes and Vision, ICEH, London School of Hygiene & Tropical Medicine, London, UK. [4]Department of Neurosciences, Psychology, Drug Research and Children's Health, University of Florence, Florence, Italy

Contact address: Gianni Virgili, Department of Translational Surgery and Medicine, Eye Clinic, University of Florence, Largo Brambilla, 3, Florence, 50134, Italy. gianni.virgili@unifi.it.

Editorial group: Cochrane Eyes and Vision Group.
Publication status and date: New search for studies and content updated (conclusions changed), published in Issue 6, 2017.

Citation: Virgili G, Parravano M, Evans JR, Gordon I, Lucenteforte E. Anti-vascular endothelial growth factor for diabetic macular oedema: a network meta-analysis. *Cochrane Database of Systematic Reviews* 2017, Issue 6. Art. No.: CD007419. DOI: 10.1002/14651858.CD007419.pub5.

Copyright © 2017 The Cochrane Collaboration. Published by John Wiley & Sons, Ltd.

ABSTRACT

Background

Diabetic macular oedema (DMO) is a common complication of diabetic retinopathy. Antiangiogenic therapy with anti-vascular endothelial growth factor (anti-VEGF) modalities can reduce oedema and thereby improve vision and prevent further visual loss. These drugs have replaced laser photocoagulation as the standard of care for people with DMO.

Objectives

The 2014 update of this review found high-quality evidence of benefit with antiangiogenic therapy with anti-VEGF modalities, compared to laser photocoagulation, for the treatment of DMO.The objective of this updated review is to compare the effectiveness and safety of the different anti-VEGF drugs in preserving and improving vision and quality of life using network meta-analysis methods.

Search methods

We searched various electronic databases on 26 April 2017.

Selection criteria

We included randomised controlled trials (RCTs) that compared any anti-angiogenic drug with an anti-VEGF mechanism of action versus another anti-VEGF drug, another treatment, sham or no treatment in people with DMO.

Data collection and analysis

We used standard Cochrane methods for pair-wise meta-analysis and we augmented this evidence using network meta-analysis methods. We focused on the relative efficacy and safety of the three most commonly used drugs as interventions of direct interest for practice: aflibercept and ranibizumab, used on-label; and off-label bevacizumab.

We collected data on three efficacy outcomes (gain of 15 or more Early Treatment Diabetic Retinopathy Study (ETDRS) letters; mean change in best-corrected visual acuity (BCVA); mean change in central retinal thickness (CRT)), three safety outcomes (all severe systemic adverse events (SSAEs); all-cause death; arterial thromboembolic events) and quality of life.

We used Stata '*network*' meta-analysis package for all analyses. We investigated the risk of bias of mixed comparisons based on the variance contribution of each study, having assigned an overall risk of bias to each study.

Copyright © 2017 The Cochrane Collaboration. Published by John Wiley & Sons, Ltd.

[Intervention Review]

Anti-vascular endothelial growth factor for macular oedema secondary to branch retinal vein occlusion

Danny Mitry[1], Catey Bunce[2], David Charteris[1]

[1]Moorfields Eye Hospital NHS Foundation Trust, London, UK. [2]Research and Development Department, Moorfields Eye Hospital NHS Foundation Trust, London, UK

Contact address: Danny Mitry, Moorfields Eye Hospital NHS Foundation Trust, City Road, London, EC1V 2PD, UK. mitryd@gmail.com.

Editorial group: Cochrane Eyes and Vision Group.
Publication status and date: New, published in Issue 1, 2013.
Review content assessed as up-to-date: 7 August 2012.

Citation: Mitry D, Bunce C, Charteris D. Anti-vascular endothelial growth factor for macular oedema secondary to branch retinal vein occlusion. *Cochrane Database of Systematic Reviews* 2013, Issue 1. Art. No.: CD009510. DOI: 10.1002/14651858.CD009510.pub2.

Copyright © 2013 The Cochrane Collaboration. Published by John Wiley & Sons, Ltd.

ABSTRACT

Background

Branch retinal vein occlusion (BRVO) is one of the most common occurring retinal vascular abnormalities. The pathogenesis of BRVO is thought to involve both retinal vein compression and damage to the vessel wall, possibly leading to thrombus formation at sites where retinal arterioles cross retinal veins. The most common cause of visual loss in patients with BRVO is macular oedema (MO). Grid or focal laser photocoagulation has been shown to reduce the risk of visual loss and improve visual acuity (VA) in up to two thirds of individuals with MO secondary to BRVO, however, limitations to this treatment exist and newer modalities have suggested equal or improved efficacy. Recently, antiangiogenic therapy with anti-vascular endothelial growth factor (anti-VEGF) has been used successfully to treat MO resulting from a variety of causes. As elevated intraocular levels of VEGF have been demonstrated in patients with retinal vein occlusions there is a strong basis for the hypothesis that anti-VEGF agents may be beneficial in the treatment of vascular leakage and MO.

Objectives

To investigate the efficacy and safety of intravitreal anti-VEGF agents for preserving or improving vision in the treatment of MO secondary to BRVO.

Search methods

We searched CENTRAL (which contains the Cochrane Eyes and Vision Group Trials Register) (*The Cochrane Library* 2012, Issue 7), Ovid MEDLINE, Ovid MEDLINE In-Process and Other Non-Indexed Citations, Ovid MEDLINE Daily, Ovid OLDMEDLINE (January 1946 to August 2012), EMBASE (January 1980 to August 2012), Latin American and Caribbean Literature on Health Sciences (LILACS) (January 1982 to August 2012, the *meta*Register of Controlled Trials (*m*RCT) (www.controlled-trials.com), ClinicalTrials.gov (www.clinicaltrials.gov) and the WHO International Clinical Trials Registry Platform (ICTRP) (www.who.int/ictrp/search/en). We did not use any date or language restrictions in the electronic searches for trials. We last searched the electronic databases on 7 August 2012 and the clinical trials registers on 10 September 2012.

Selection criteria

We included randomised controlled trials (RCTs) and quasi-RCTS of at least six months duration where anti-VEGF treatment was compared with another treatment, no treatment, or placebo. We excluded trials where combination treatments (anti-VEGF plus other

[Intervention Review]

Anti-vascular endothelial growth factor for macular oedema secondary to central retinal vein occlusion

Tasanee Braithwaite[1], Afshan A Nanji[2], Kristina Lindsley[3], Paul B Greenberg[4]

[1]Moorfields Eye Hospital NHS Foundation Trust, London, UK. [2]Bascom Palmer Eye Institute, Miami, Florida, USA. [3]Department of Epidemiology, Johns Hopkins Bloomberg School of Public Health, Baltimore, Maryland, USA. [4]Division of Ophthalmology, Warren Alpert Medical School of Brown University, Providence, Rhode Island, USA

Contact address: Tasanee Braithwaite, Moorfields Eye Hospital NHS Foundation Trust, 162 City Road, London, EC1V 2PD, UK. tasaneebraithwaite@gmail.com.

Editorial group: Cochrane Eyes and Vision Group.
Publication status and date: New search for studies and content updated (conclusions changed), published in Issue 5, 2014.

Citation: Braithwaite T, Nanji AA, Lindsley K, Greenberg PB. Anti-vascular endothelial growth factor for macular oedema secondary to central retinal vein occlusion. *Cochrane Database of Systematic Reviews* 2014, Issue 5. Art. No.: CD007325. DOI: 10.1002/14651858.CD007325.pub3.

Copyright © 2014 The Cochrane Collaboration. Published by John Wiley & Sons, Ltd.

ABSTRACT

Background

Central retinal vein occlusion (CRVO) is a relatively common retinal vascular disorder in which macular oedema may develop, with a consequent reduction in visual acuity. Until recently there has been no treatment of proven benefit, but growing evidence supports the use of anti-vascular endothelial growth factor (anti-VEGF) agents.

Objectives

To investigate the effectiveness and safety of anti-VEGF therapies for the treatment of macular oedema secondary to CRVO.

Search methods

We searched CENTRAL (which contains the Cochrane Central Register of Controlled Trials (CENTRAL) and the Cochrane Eyes and Vision Group Trials Register) (*The Cochrane Library* 2013, Issue 10), Ovid MEDLINE (January 1950 to October 2013), EMBASE (January 1980 to October 2013), Latin American and Caribbean Health Sciences Literature Database (LILACS) (January 1982 to October 2013), Cumulative Index to Nursing and Allied Health Literature (CINAHL) (January 1937 to October 2013), OpenGrey, OpenSIGLE (January 1950 to October 2013), the *meta*Register of Controlled Trials (*m*RCT) (www.controlled-trials.com), ClinicalTrials.gov (www.clinicaltrials.gov), the WHO International Clinical Trials Registry Platform (ICTRP) (www.who.int/ictrp/search/en) and Web of Science Conference Proceedings Citation Index-Science (CPCI-S). There were no language or date restrictions in the electronic search for trials. The electronic databases and clinical trials registers were last searched on 29th October 2013.

Selection criteria

We considered randomised controlled trials (RCTs) that compared intravitreal anti-VEGF agents of any dose or duration to sham injection or no treatment. We focused on studies that included individuals of any age or gender and a minimum of six months follow-up.

Copyright © 2014 The Cochrane Collaboration. Published by John Wiley & Sons, Ltd.

[Intervention Review]

Anti-vascular endothelial growth factor for neovascular age-related macular degeneration

Sharon D Solomon[1], Kristina Lindsley[2], Satyanarayana S Vedula[3], Magdalena G Krzystolik[4], Barbara S Hawkins[1]

[1]Wilmer Eye Institute, Johns Hopkins University School of Medicine, Baltimore, Maryland, USA. [2]Department of Epidemiology, Johns Hopkins Bloomberg School of Public Health, Baltimore, Maryland, USA. [3]Johns Hopkins University, Baltimore, Maryland, USA. [4]Southern New England Retina Associates, Providence, Rhode Island, USA

Contact address: Kristina Lindsley, Department of Epidemiology, Johns Hopkins Bloomberg School of Public Health, 615 North Wolfe Street, Mail Room E6132, Baltimore, Maryland, 21205, USA. klindsley@jhu.edu.

Editorial group: Cochrane Eyes and Vision Group.
Publication status and date: New search for studies and content updated (conclusions changed), published in Issue 8, 2014.

Citation: Solomon SD, Lindsley K, Vedula SS, Krzystolik MG, Hawkins BS. Anti-vascular endothelial growth factor for neovascular age-related macular degeneration. *Cochrane Database of Systematic Reviews* 2014, Issue 8. Art. No.: CD005139. DOI: 10.1002/14651858.CD005139.pub3.

Copyright © 2014 The Cochrane Collaboration. Published by John Wiley & Sons, Ltd.

ABSTRACT

Background

Age-related macular degeneration (AMD) is the most common cause of uncorrectable severe vision loss in people aged 55 years and older in the developed world. Choroidal neovascularization (CNV) secondary to neovascular AMD accounts for most AMD-related severe vision loss. Anti-vascular endothelial growth factor (anti-VEGF) agents, injected intravitreally, aim to block the growth of abnormal blood vessels in the eye to prevent vision loss and, in some instances, improve vision.

Objectives

To investigate: (1) the ocular and systemic effects of, and quality of life associated with, intravitreally injected anti-VEGF agents (pegaptanib, ranibizumab, and bevacizumab) for the treatment of neovascular AMD compared with no anti-VEGF treatment; and (2) the relative effects of one anti-VEGF agent compared with another when administered in comparable dosages and regimens.

Search methods

We searched Cochrane Central Register of Controlled Trials (CENTRAL) (which contains the Cochrane Eyes and Vision Group Trials Register) (2014, Issue 3), Ovid MEDLINE, Ovid MEDLINE In-Process and Other Non-Indexed Citations, Ovid MEDLINE Daily, Ovid OLDMEDLINE (January 1946 to March 2014), EMBASE (January 1980 to March 2014), Latin American and Caribbean Health Sciences Literature Database (LILACS) (January 1982 to March 2014), the *meta*Register of Controlled Trials (*m*RCT) (www.controlled-trials.com), ClinicalTrials.gov (www.clinicaltrials.gov) and the World Health Organization (WHO) International Clinical Trials Registry Platform (ICTRP) (www.who.int/ictrp/search/en). We used no date or language restrictions in the electronic searches for trials. We last searched the electronic databases on 27 March 2014.

Selection criteria

We included randomized controlled trials (RCTs) that evaluated pegaptanib, ranibizumab, or bevacizumab versus each other or a control treatment (e.g., sham treatment or photodynamic therapy). All trials followed participants for at least one year.

[Intervention Review]

Anti-vascular endothelial growth factor for prevention of postoperative vitreous cavity haemorrhage after vitrectomy for proliferative diabetic retinopathy

Jonathan M Smith[1], David HW Steel[1]

[1]Sunderland Eye Infirmary, Sunderland, UK

Contact address: David HW Steel, Sunderland Eye Infirmary, Queen Alexandra Road, Sunderland, SR2 9HP, UK. David.Steel@chsft.nhs.uk.

Editorial group: Cochrane Eyes and Vision Group.
Publication status and date: New search for studies and content updated (conclusions changed), published in Issue 8, 2015.
Review content assessed as up-to-date: 26 May 2015.

Citation: Smith JM, Steel DHW. Anti-vascular endothelial growth factor for prevention of postoperative vitreous cavity haemorrhage after vitrectomy for proliferative diabetic retinopathy. *Cochrane Database of Systematic Reviews* 2015, Issue 8. Art. No.: CD008214. DOI: 10.1002/14651858.CD008214.pub3.

Copyright © 2015 The Cochrane Collaboration. Published by John Wiley & Sons, Ltd.

ABSTRACT

Background

Postoperative vitreous cavity haemorrhage (POVCH) is a significant complication following vitrectomy for proliferative diabetic retinopathy (PDR). It delays visual recovery and can make further treatment difficult if the view of the fundus is significantly obscured. A number of interventions to reduce the incidence of POVCH have been proposed, including the perioperative use of anti-vascular endothelial growth factor (anti-VEGF). Anti-VEGFs reduce vascular proliferation and the vascularity of neovascular tissue, which is often the source of bleeding following vitrectomy.

Objectives

This updated review aimed to summarise the effects of anti-VEGF use to reduce the occurrence of POVCH after vitrectomy surgery for PDR.

Search methods

We searched CENTRAL (which contains the Cochrane Eyes and Vision Group Trials Register) (2015, Issue 4), Ovid MEDLINE, Ovid MEDLINE In-Process and Other Non-Indexed Citations, Ovid MEDLINE Daily, Ovid OLDMEDLINE (January 1946 to May 2015), PubMed (January 1966 to May 2015), EMBASE (January 1980 to May 2015), Latin American and Caribbean Health Sciences (LILACS) (January 1982 to May 2015), the ISRCTN registry (www.isrctn.com/editAdvancedSearch), ClinicalTrials.gov (www.clinicaltrials.gov), and the the World Health Organization (WHO) International Clinical Trials Registry Platform (ICTRP) (www.who.int/ictrp/search/en). We did not use any date or language restrictions in the electronic searches for trials. We last searched the electronic databases on 26 May 2015.

Selection criteria

We included all randomised controlled trials (RCTs) and quasi-RCTs that looked at the use of anti-VEGFs and the incidence of POVCH in people undergoing vitrectomy for PDR.

[Intervention Review]

Perioperative antibiotics for prevention of acute endophthalmitis after cataract surgery

Emily W Gower[1], Kristina Lindsley[2], Samantha E Tulenko[1], Afshan A Nanji[3], Ilya Leyngold[4], Peter J McDonnell[5]

[1]University of North Carolina, Gillings School of Global Public Health, Chapel Hill, North Carolina, USA. [2]Department of Epidemiology, Johns Hopkins Bloomberg School of Public Health, Baltimore, Maryland, USA. [3]Casey Eye Institute, Oregon Health & Science University, Portland, Oregon, USA. [4]Division of Oculofacial Plastic and Reconstructive Surgery, Duke University Hospital Department of Ophthalmology, Durham, North Carolina, USA. [5]Wilmer Eye Institute, Johns Hopkins University School of Medicine, Baltimore, Maryland, USA

Contact address: Emily W Gower, University of North Carolina, Gillings School of Global Public Health, 135 Dauer Drive, 2102A McGavran Greenberg, CB#7435, Chapel Hill, North Carolina, 27599, USA. egower@unc.edu.

Editorial group: Cochrane Eyes and Vision Group.
Publication status and date: New search for studies and content updated (no change to conclusions), published in Issue 2, 2017.

Citation: Gower EW, Lindsley K, Tulenko SE, Nanji AA, Leyngold I, McDonnell PJ. Perioperative antibiotics for prevention of acute endophthalmitis after cataract surgery. *Cochrane Database of Systematic Reviews* 2017, Issue 2. Art. No.: CD006364. DOI: 10.1002/14651858.CD006364.pub3.

Copyright © 2017 The Cochrane Collaboration. Published by John Wiley & Sons, Ltd.

ABSTRACT

Background

Endophthalmitis is a severe inflammation of the anterior or posterior (or both) chambers of the eye that may be sterile or associated with infection. It is a potentially vision-threatening complication of cataract surgery. Prophylactic measures for endophthalmitis are targeted against various sources of infection.

Objectives

To evaluate the effects of perioperative antibiotic prophylaxis for endophthalmitis following cataract surgery compared with no prophylaxis or other form of prophylaxis.

Search methods

We searched CENTRAL (which contains the Cochrane Eyes and Vision Trials Register) (2016, Issue 12), Ovid MEDLINE, Epub Ahead of Print, In-Process & Other Non-Indexed Citations, Ovid MEDLINE Daily (January 1946 to December 2016), Embase (January 1980 to December 2016), Latin American and Caribbean Health Sciences Literature Database (LILACS) (1982 to December 2016),the ISRCTN registry (www.isrctn.com/editAdvancedSearch), ClinicalTrials.gov (www.clinicaltrials.gov), and the World Health Organization (WHO) International Clinical Trials Registry Platform (ICTRP) (www.who.int/ictrp/search/en). We used no date or language restrictions in the electronic searches for trials. We last searched the electronic databases on 6 December 2016. We also searched for additional studies that cited any included trials using the Science Citation Index.

Selection criteria

We included randomized controlled trials that enrolled adults undergoing cataract surgery (any method and incision type) for lens opacities due to any origin. We included trials that evaluated preoperative antibiotics, intraoperative (intracameral, subconjunctival or systemic), or postoperative antibiotic prophylaxis for acute endophthalmitis. We excluded studies that evaluated antiseptic preoperative preparations using agents such as povidone iodine or antibiotics for treating acute endophthalmitis after cataract surgery.

[Intervention Review]

Antibiotics versus no treatment for toxoplasma retinochoroiditis

Eli Pradhan[1], Sanjeeb Bhandari[1], Ruth E Gilbert[2], Miles Stanford[3]

[1]Tilganga Institute of Ophthalmology, Kathmandu, Nepal. [2]Population, Policy & Practice Programme, University College London, Institute of Child Health, London, UK. [3]Medical Eye Unit, St. Thomas' Hospital, London, UK

Contact address: Ruth E Gilbert, Population, Policy & Practice Programme, University College London, Institute of Child Health, 30 Guilford Street, London, WC1N 1EH, UK. r.gilbert@ucl.ac.uk.

Editorial group: Cochrane Eyes and Vision Group.
Publication status and date: New search for studies and content updated (no change to conclusions), published in Issue 5, 2016.

Citation: Pradhan E, Bhandari S, Gilbert RE, Stanford M. Antibiotics versus no treatment for toxoplasma retinochoroiditis. *Cochrane Database of Systematic Reviews* 2016, Issue 5. Art. No.: CD002218. DOI: 10.1002/14651858.CD002218.pub2.

Copyright © 2016 The Cochrane Collaboration. Published by John Wiley & Sons, Ltd.

ABSTRACT

Background

Acute toxoplasma retinochoroiditis causes transient symptoms of ocular discomfort and may lead to permanent visual loss. Antibiotic treatment aims primarily to reduce the risk of permanent visual loss, recurrent retinochoroiditis, and the severity and duration of acute symptoms. There is uncertainty about the effectiveness of antibiotic treatment.

Objectives

To compare the effects of antibiotic treatment versus placebo or no treatment for toxoplasma retinochoroiditis.

Search methods

We searched CENTRAL (which contains the Cochrane Eyes and Vision group Trials Register) (2016, Issue 1), Ovid MEDLINE, Ovid MEDLINE In-Process and Other Non-Indexed Citations, Ovid MEDLINE Daily, Ovid OLDMEDLINE (January 1946 to February 2016), EMBASE (January 1980 to February 2016), Latin American and Caribbean Health Sciences Literature Database (LILACS) (January 1982 to February 2016), the ISRCTN registry (www.isrctn.com/editAdvancedSearch), ClinicalTrials.gov (www.clinicaltrials.gov), and the World Health Organization (WHO) International Clinical Trials Registry Platform (ICTRP) (www.who.int/ictrp/search/en). We did not use any date or language restrictions in the electronic searches for trials. We last searched the electronic databases on 22 February 2016. We searched the reference lists of identified articles and contacted pharmaceutical companies for unpublished trials.

Selection criteria

We included randomised controlled trials that compared any antibiotic treatment against placebo or no treatment. We excluded trials that included immunocompromised participants. We considered any antibiotic treatment known to be active against *Toxoplasma gondii*. Antibiotic treatment could be given in any dose orally, by intramuscular injection, by intravenous infusion, or by intravitreal injection.

Data collection and analysis

The primary outcomes for this review were visual acuity at least three months after treatment and risk of recurrent retinochoroiditis. Secondary outcomes were improvement in symptoms and signs of intraocular inflammation, size of lesion, and adverse events. We used standard methodological procedures expected by Cochrane.

[Intervention Review]

Antibiotics for trachoma

Jennifer R Evans[1], Anthony W Solomon[1]

[1]Cochrane Eyes and Vision Group, ICEH, London School of Hygiene & Tropical Medicine, London, UK

Contact address: Jennifer R Evans, Cochrane Eyes and Vision Group, ICEH, London School of Hygiene & Tropical Medicine, Keppel Street, London, WC1E 7HT, UK. jennifer.evans@lshtm.ac.uk.

Editorial group: Cochrane Eyes and Vision Group.
Publication status and date: New search for studies and content updated (conclusions changed), published in Issue 3, 2011.

Citation: Evans JR, Solomon AW. Antibiotics for trachoma. *Cochrane Database of Systematic Reviews* 2011, Issue 3. Art. No.: CD001860. DOI: 10.1002/14651858.CD001860.pub3.

Copyright © 2011 The Cochrane Collaboration. Published by John Wiley & Sons, Ltd.

ABSTRACT

Background

Trachoma is the world's leading infectious cause of blindness. In 1997 the World Health Organization (WHO) launched an Alliance for the Global Elimination of Trachoma by the year 2020, based on the 'SAFE' strategy (surgery, antibiotics, facial cleanliness and environmental improvement).

Objectives

To assess the evidence supporting the antibiotic arm of the SAFE strategy by assessing the effects of antibiotics on both active trachoma (primary objective) and on *Chlamydia trachomatis* (*C. trachomatis*) infection of the conjunctiva (secondary objective).

Search methods

We searched CENTRAL (which contains the Cochrane Eyes and Vision Group Trials Register) (*The Cochrane Library* 2010, Issue 11), MEDLINE (January 1950 to December 2010), EMBASE (January 1980 to December 2010), the *meta*Register of Controlled Trials (*m*RCT) (www.controlled-trials.com) (December 2010) and ClinicalTrials.gov (www.clinicaltrials.gov) (December 2010). We used the Science Citation Index to look for articles that cited the included studies. We searched the reference lists of identified articles and we contacted authors and experts for details of further relevant studies. There were no language or date restrictions in the search for trials. The electronic databases were last searched on 12 December 2010.

Selection criteria

We included randomised trials that satisfied either of two criteria: (a) trials in which topical or oral administration of an antibiotic was compared to placebo or no treatment in people or communities with trachoma, (b) trials in which a topical antibiotic was compared with an oral antibiotic in people or communities with trachoma. A subdivision of particular interest was trials in which topical tetracycline or chlortetracycline and oral azithromycin were compared with each other, or in which one of these treatments was compared with placebo or no treatment, as these are the two WHO recommended antibiotics. We considered individually randomised and cluster-randomised trials separately.

Data collection and analysis

Two authors independently assessed trial quality and extracted data. We contacted investigators for missing data. Where appropriate, the effect estimates from the individual studies (risk ratios) were pooled using a random-effects model.

Copyright © 2011 The Cochrane Collaboration. Published by John Wiley & Sons, Ltd.

[Intervention Review]

Antibiotics versus placebo for acute bacterial conjunctivitis

Aziz Sheikh[1], Brian Hurwitz[2], Constant Paul van Schayck[3], Susannah McLean[4], Ulugbek Nurmatov[5]

[1]Centre for Population Health Sciences, The University of Edinburgh, Edinburgh, UK. [2]King's College London, London, UK. [3]Department of General Practice, Maastricht University, Maastricht, Netherlands. [4]Allergy & Respiratory Research Group, Centre for Population Health Sciences, The University of Edinburgh, Edinburgh, UK. [5]Allergy & Respiratory Research Group, Centre for Population Health Sciences, The University of Edinburgh, Edinburgh, UK

Contact address: Aziz Sheikh, Centre for Population Health Sciences, The University of Edinburgh, Medical School, Doorway 3, Teviot Place, Edinburgh, EH8 9AG, UK. Aziz.Sheikh@ed.ac.uk.

Editorial group: Cochrane Eyes and Vision Group.
Publication status and date: New search for studies and content updated (conclusions changed), published in Issue 9, 2012.

Citation: Sheikh A, Hurwitz B, van Schayck CP, McLean S, Nurmatov U. Antibiotics versus placebo for acute bacterial conjunctivitis. *Cochrane Database of Systematic Reviews* 2012, Issue 9. Art. No.: CD001211. DOI: 10.1002/14651858.CD001211.pub3.

Copyright © 2012 The Cochrane Collaboration. Published by John Wiley & Sons, Ltd.

ABSTRACT

Background

Acute bacterial conjunctivitis is an infection of the conjunctiva. Both the palpebral and the bulbar ocular conjunctival surfaces are usually affected and typically become red and inflamed. Antibiotic therapy is widely used for the treatment of acute bacterial conjunctivitis. This Cochrane Review was first published in *The Cochrane Library* in 1999; updated in 2006 and again in 2012.

Objectives

To assess the benefits and harms of antibiotic therapy in the management of acute bacterial conjunctivitis.

Search methods

We searched CENTRAL (which contains the Cochrane Eyes and Vision Group Trials Register) (*The Cochrane Library* 2012, Issue 7), MEDLINE (January 1950 to July 2012), EMBASE (January 1980 to July 2012), OpenGrey (System for Information on Grey Literature in Europe) (www.opengrey.eu/), the *meta*Register of Controlled Trials (*m*RCT) (www.controlled-trials.com), ClinicalTrials.gov (www.clinicaltrials.gov) and the WHO International Clinical Trials Registry Platform (ICTRP) (www.who.int/ictrp/search/en). We did not use any date or language restrictions in the electronic searches for trials. We last searched the electronic databases on 18 July 2012.

Selection criteria

We included double-masked randomised controlled trials (RCTs) in which any form of antibiotic treatment had been compared with placebo/vehicle in the management of acute bacterial conjunctivitis. This included topical, systemic and combination (for example, antibiotics and steroids) antibiotic treatments.

Data collection and analysis

Two authors (UN and SM) independently checked and reviewed the titles and abstracts of identified studies. We assessed the full text of all potentially relevant studies. We graded the included RCTs for methodological quality using Cochrane methodology. We performed data extraction in a standardised manner. We performed random-effects meta-analyses using RevMan.

Copyright © 2012 The Cochrane Collaboration. Published by John Wiley & Sons, Ltd.

[Intervention Review]

Antioxidant vitamin and mineral supplements for slowing the progression of age-related macular degeneration

Jennifer R Evans[1], John G Lawrenson[2]

[1]Cochrane Eyes and Vision, ICEH, London School of Hygiene & Tropical Medicine, London, UK. [2]Centre for Applied Vision Research, School of Health Sciences, City University of London, London, UK

Contact address: Jennifer R Evans, Cochrane Eyes and Vision, ICEH, London School of Hygiene & Tropical Medicine, Keppel Street, London, WC1E 7HT, UK. jennifer.evans@lshtm.ac.uk.

Editorial group: Cochrane Eyes and Vision Group.
Publication status and date: Edited (no change to conclusions), published in Issue 9, 2017.

Citation: Evans JR, Lawrenson JG. Antioxidant vitamin and mineral supplements for slowing the progression of age-related macular degeneration. *Cochrane Database of Systematic Reviews* 2017, Issue 7. Art. No.: CD000254. DOI: 10.1002/14651858.CD000254.pub4.

Copyright © 2017 The Cochrane Collaboration. Published by John Wiley & Sons, Ltd.

ABSTRACT

Background

It has been proposed that antioxidants may prevent cellular damage in the retina by reacting with free radicals that are produced in the process of light absorption. Higher dietary levels of antioxidant vitamins and minerals may reduce the risk of progression of age-related macular degeneration (AMD).

Objectives

The objective of this review was to assess the effects of antioxidant vitamin or mineral supplementation on the progression of AMD in people with AMD.

Search methods

We searched CENTRAL (2017, Issue 2), MEDLINE Ovid (1946 to March 2017), Embase Ovid (1947 to March 2017), AMED (1985 to March 2017), OpenGrey (System for Information on Grey Literature in Europe, the ISRCTN registry (www.isrctn.com/editAdvancedSearch), ClinicalTrials.gov (www.clinicaltrials.gov) and the WHO International Clinical Trials Registry Platform (ICTRP) (www.who.int/ictrp/search/en). We did not use any date or language restrictions in the electronic searches for trials. We last searched the electronic databases on 29 March 2017.

Selection criteria

We included randomised controlled trials (RCTs) that compared antioxidant vitamin or mineral supplementation (alone or in combination) to placebo or no intervention, in people with AMD.

Data collection and analysis

Both review authors independently assessed risk of bias in the included studies and extracted data. One author entered data into RevMan 5; the other author checked the data entry. We graded the certainty of the evidence using GRADE.

Main results

We included 19 studies conducted in USA, Europe, China, and Australia. We judged the trials that contributed data to the review to be at low or unclear risk of bias.

[Intervention Review]

Antiviral treatment and other therapeutic interventions for herpes simplex virus epithelial keratitis

Kirk R Wilhelmus[1]

[1]Cullen Eye Institute, Department of Ophthalmology, Baylor College of Medicine, Houston, Texas, USA

Contact address: Kirk R Wilhelmus, Cullen Eye Institute, Department of Ophthalmology, Baylor College of Medicine, Houston, Texas, USA. kirkw@bcm.edu.

Editorial group: Cochrane Eyes and Vision Group.
Publication status and date: New search for studies and content updated (conclusions changed), published in Issue 1, 2015.

Citation: Wilhelmus KR. Antiviral treatment and other therapeutic interventions for herpes simplex virus epithelial keratitis. *Cochrane Database of Systematic Reviews* 2015, Issue 1. Art. No.: CD002898. DOI: 10.1002/14651858.CD002898.pub5.

Copyright © 2015 The Cochrane Collaboration. Published by John Wiley & Sons, Ltd.

ABSTRACT

Background

Eye disease due to herpes simplex virus (HSV) commonly presents as epithelial keratitis which, though usually self-limiting, may persist or progress without treatment.

Objectives

To compare the relative effectiveness of antiviral agents, interferon, and corneal debridement in the treatment of HSV epithelial keratitis.

Search methods

We searched CENTRAL (which contains the Cochrane Eyes and Vision Group Trials Register) (2014, Issue 12), PubMed (January 1946 to 31 December 2014), EMBASE (January 1980 to 31 December 2014), Latin American and Caribbean Health Sciences Literature Database (LILACS) (January 1982 to 31 December 2014), System for Information on Grey Literature in Europe (OpenGrey) (January 1995 to 31 December 2014), BIOSIS (January 1926 to 5 May 2014), Scopus (January 1966 to 31 December 2014), Japan Science and Technology Institute (J-Global) (January 1975 to 31 December 2014), China National Knowledge Infrastructure (CNKI) (January 1979 to 31 December 2014), British Library's Electronic Table of Contents (Zetoc) (January 1993 to 7 May 2014). We looked for trials listed on the the *meta*Register of Controlled Trials (www.controlled-trials.com), ClinicalTrials.gov (www.clinicaltrials.gov), the World Health Organization (WHO) International Clinical Trials Registry Platform (ICTRP) (www.who.int/ictrp/search/en), Chinese Clinical Trial Registry, the U.S. Food and Drug Administration (FDA) (www.fda.gov/), National Institute for Health and Clinical Excellence (NICE) (www.evidence.nhs.uk) and the European Medicines Agency (EMA) (www.ema.europa.eu/ema/) as of 31 December 2014. There were no language or date restrictions in the search for trials. We also culled literature digests and conference proceedings as of 15 April 2014. There were no language or date restrictions in the search for trials.

Selection criteria

Randomised and quasi-randomised trials of HSV dendritic or geographic epithelial keratitis were included that reported the proportion of eyes healed at one week, two weeks, or both after enrolment.

Data collection and analysis

We tabulated data on study characteristics, risk of bias, and outcomes and used direct comparisons to estimate a risk ratio (RR) and, when feasible, a hazard ratio (HR) with a 95% confidence interval (CI). Heterogeneity was assessed by an inconsistency index. A multiple treatment comparison meta-analysis consolidated direct and indirect comparisons of relative healing at 14 days.

Copyright © 2015 The Cochrane Collaboration. Published by John Wiley & Sons, Ltd.

[Intervention Review]

Beta radiation for glaucoma surgery

James F Kirwan[1], Christina Rennie[2], Jennifer R Evans[3]

[1]Department of Ophthalmology, Queen Alexandra Hospital, Portsmouth, UK. [2]Department of Ophthalmology, Southampton Eye Unit, Southampton General Hospital, Southampton, UK. [3]Cochrane Eyes and Vision Group, ICEH, London School of Hygiene & Tropical Medicine, London, UK

Contact address: James F Kirwan, Department of Ophthalmology, Queen Alexandra Hospital, Cosham, Portsmouth, Hampshire, PO6 3LY, UK. jfkirwan@mac.com.

Editorial group: Cochrane Eyes and Vision Group.
Publication status and date: New search for studies and content updated (no change to conclusions), published in Issue 6, 2012.

Citation: Kirwan JF, Rennie C, Evans JR. Beta radiation for glaucoma surgery. *Cochrane Database of Systematic Reviews* 2012, Issue 6. Art. No.: CD003433. DOI: 10.1002/14651858.CD003433.pub3.

Copyright © 2012 The Cochrane Collaboration. Published by John Wiley & Sons, Ltd.

ABSTRACT

Background

The outcome of glaucoma surgery can be affected by the rate at which the surgical wound heals. Beta radiation has been proposed as a rapid and simple treatment to slow down the healing response.

Objectives

To assess the effectiveness of beta radiation during glaucoma surgery (trabeculectomy).

Search methods

We searched CENTRAL (which contains the Cochrane Eyes and Vision Group Trials Register) (*The Cochrane Library* 2012, Issue 3), MEDLINE (January 1950 to March 2012), EMBASE (January 1980 to March 2012), the *meta*Register of Controlled Trials (*m*RCT) (www.controlled-trials.com), ClinicalTrials.gov (www.clinicaltrials.gov) and the WHO International Clinical Trials Registry Platform (ICTRP) (www.who.int/ictrp/search/en). There were no date or language restrictions in the electronic searches for trials. The electronic databases were last searched on 26 March 2012.

Selection criteria

We included randomised controlled trials comparing trabeculectomy with beta radiation to trabeculectomy without beta radiation.

Data collection and analysis

We collected data on surgical failure (intraocular pressure > 21 mmHg), intraocular pressure and adverse effects of glaucoma surgery. We pooled data using a fixed-effect model.

Main results

We found four trials that randomised 551 people to trabeculectomy with beta irradiation versus trabeculectomy alone. Two trials were in Caucasian people (126 people), one trial in black African people (320 people) and one trial in Chinese people (105 people). People who had trabeculectomy with beta irradiation had a lower risk of surgical failure compared to people who had trabeculectomy alone (pooled risk ratio (RR) 0.23 (95% CI 0.14 to 0.40). Beta irradiation was associated with an increased risk of cataract (RR 2.89, 95% CI 1.39 to 6.0).

Copyright © 2012 The Cochrane Collaboration. Published by John Wiley & Sons, Ltd.

[Intervention Review]

Blood pressure control for diabetic retinopathy

Diana V Do[1], Xue Wang[2], Satyanarayana S Vedula[3], Michael Marrone[2], Gina Sleilati[4], Barbara S Hawkins[5], Robert N Frank[6]

[1]Stanley M. Truhlsen Eye Institute, University of Nebraska Medical Center, Omaha, Nebraska, USA. [2]Department of Epidemiology, Johns Hopkins Bloomberg School of Public Health, Baltimore, Maryland, USA. [3]Johns Hopkins University, Baltimore, Maryland, USA. [4]Clemenceau Medical Center, Beirut, Lebanon. [5]Wilmer Eye Institute, Johns Hopkins University School of Medicine, Baltimore, Maryland, USA. [6]Department of Ophthalmology, Kresge Eye Institute, Detroit, Michigan, USA

Contact address: Diana V Do, Stanley M. Truhlsen Eye Institute, University of Nebraska Medical Center, 985540 Nebraska Medical Center, Omaha, Nebraska, 68198-5540, USA. diana.do@unmc.edu.

Editorial group: Cochrane Eyes and Vision Group.
Publication status and date: New, published in Issue 1, 2015.

Citation: Do DV, Wang X, Vedula SS, Marrone M, Sleilati G, Hawkins BS, Frank RN. Blood pressure control for diabetic retinopathy. *Cochrane Database of Systematic Reviews* 2015, Issue 1. Art. No.: CD006127. DOI: 10.1002/14651858.CD006127.pub2.

Copyright © 2015 The Cochrane Collaboration. Published by John Wiley & Sons, Ltd.

ABSTRACT

Background

Diabetic retinopathy is a common complication of diabetes and a leading cause of visual impairment and blindness. Research has established the importance of blood glucose control to prevent development and progression of the ocular complications of diabetes. Simultaneous blood pressure control has been advocated for the same purpose, but findings reported from individual studies have supported varying conclusions regarding the ocular benefit of interventions on blood pressure.

Objectives

The primary aim of this review was to summarize the existing evidence regarding the effect of interventions to control or reduce blood pressure levels among diabetics on incidence and progression of diabetic retinopathy, preservation of visual acuity, adverse events, quality of life, and costs. A secondary aim was to compare classes of anti-hypertensive medications with respect to the same outcomes.

Search methods

We searched a number of electronic databases including CENTRAL as well as ongoing trial registries. We last searched the electronic databases on 25 April 2014. We also reviewed reference lists of review articles and trial reports selected for inclusion. In addition, we contacted investigators of trials with potentially pertinent data.

Selection criteria

We included in this review randomized controlled trials (RCTs) in which either type 1 or type 2 diabetic participants, with or without hypertension, were assigned randomly to intense versus less intense blood pressure control, to blood pressure control versus usual care or no intervention on blood pressure, or to different classes of anti-hypertensive agents versus placebo.

Data collection and analysis

Pairs of review authors independently reviewed titles and abstracts from electronic and manual searches and the full text of any document that appeared to be relevant. We assessed included trials independently for risk of bias with respect to outcomes reported in this review. We extracted data regarding trial characteristics, incidence and progression of retinopathy, visual acuity, quality of life, and cost-effectiveness at annual intervals after study entry whenever provided in published reports and other documents available from included trials.

Copyright © 2015 The Cochrane Collaboration. Published by John Wiley & Sons, Ltd.

[Intervention Review]

Combined surgery versus cataract surgery alone for eyes with cataract and glaucoma

Mingjuan Lisa Zhang[1], Phenpan Hirunyachote[2], Henry Jampel[3]

[1]Johns Hopkins University School of Medicine, Baltimore, Maryland, USA. [2]Department of Ophthalmology, Eye Ear Nose Throat Hospital, Bangkok, Thailand. [3]Wilmer Eye Institute, Johns Hopkins University School of Medicine, Baltimore, Maryland, USA

Contact address: Henry Jampel, Wilmer Eye Institute, Johns Hopkins University School of Medicine, 600 N. Wolfe Street, Maumenee B-110, Baltimore, Maryland, 21287-9205, USA. hjampel@jhmi.edu.

Editorial group: Cochrane Eyes and Vision Group.
Publication status and date: New, published in Issue 7, 2015.
Review content assessed as up-to-date: 3 October 2014.

Citation: Zhang ML, Hirunyachote P, Jampel H. Combined surgery versus cataract surgery alone for eyes with cataract and glaucoma. *Cochrane Database of Systematic Reviews* 2015, Issue 7. Art. No.: CD008671. DOI: 10.1002/14651858.CD008671.pub3.

Copyright © 2015 The Cochrane Collaboration. Published by John Wiley & Sons, Ltd.

ABSTRACT

Background

Cataract and glaucoma are leading causes of blindness worldwide, and their co-existence is common in elderly people. Glaucoma surgery can accelerate cataract progression, and performing both surgeries may increase the rate of postoperative complications and compromise the success of either surgery. However, cataract surgery may independently lower intraocular pressure (IOP), which may allow for greater IOP control among patients with co-existing cataract and glaucoma. The decision between undergoing combined glaucoma and cataract surgery versus cataract surgery alone is complex. Therefore, it is important to compare the effectiveness of these two interventions to aid clinicians and patients in choosing the better treatment approach.

Objectives

To assess the relative effectiveness and safety of combined surgery versus cataract surgery (phacoemulsification) alone for co-existing cataract and glaucoma. The secondary objectives include cost analyses for different surgical techniques for co-existing cataract and glaucoma.

Search methods

We searched CENTRAL (which contains the Cochrane Eyes and Vision Group Trials Register) (2014, Issue 10), Ovid MEDLINE, Ovid MEDLINE In-Process and Other Non-Indexed Citations, Ovid MEDLINE Daily, Ovid OLDMEDLINE (January 1946 to October 2014), EMBASE (January 1980 to October 2014), PubMed (January 1948 to October 2014), Latin American and Caribbean Health Sciences Literature Database (LILACS) (January 1982 to October 2014), the *meta*Register of Controlled Trials (*m*RCT) (www.controlled-trials.com), ClinicalTrials.gov (www.clinicaltrials.gov), and the World Health Organization (WHO) International Clinical Trials Registry Platform (ICTRP) (www.who.int/ictrp/search/en). We did not use any date or language restrictions in the electronic searches for trials. We last searched the electronic databases on 3 October 2014.

We checked the reference lists of the included trials to identify further relevant trials. We used the Science Citation Index to search for references to publications that cited the studies included in the review. We also contacted investigators and experts in the field to identify additional trials.

Copyright © 2015 The Cochrane Collaboration. Published by John Wiley & Sons, Ltd.

[Intervention Review]

Phacoemulsification with posterior chamber intraocular lens versus extracapsular cataract extraction (ECCE) with posterior chamber intraocular lens for age-related cataract

Samantha R de Silva[1], Yasmin Riaz[1], Jennifer R Evans[2]

[1]Oxford Eye Hospital, Oxford, UK. [2]Cochrane Eyes and Vision Group, ICEH, London School of Hygiene & Tropical Medicine, London, UK

Contact address: Jennifer R Evans, Cochrane Eyes and Vision Group, ICEH, London School of Hygiene & Tropical Medicine, Keppel Street, London, WC1E 7HT, UK. jennifer.evans@lshtm.ac.uk.

Editorial group: Cochrane Eyes and Vision Group.
Publication status and date: New, published in Issue 1, 2014.
Review content assessed as up-to-date: 13 May 2013.

Citation: de Silva SR, Riaz Y, Evans JR. Phacoemulsification with posterior chamber intraocular lens versus extracapsular cataract extraction (ECCE) with posterior chamber intraocular lens for age-related cataract. *Cochrane Database of Systematic Reviews* 2014, Issue 1. Art. No.: CD008812. DOI: 10.1002/14651858.CD008812.pub2.

Copyright © 2014 The Cochrane Collaboration. Published by John Wiley & Sons, Ltd.

ABSTRACT

Background

Age-related cataract is one of the leading causes of blindness worldwide. Therefore, it is important to establish the most effective surgical technique for cataract surgery.

Objectives

The aim of this review is to examine the effects of two types of cataract surgery for age-related cataract: phacoemulsification and extracapsular cataract extraction (ECCE).

Search methods

We searched CENTRAL (which contains the Cochrane Eyes and Vision Group Trials Register) (*The Cochrane Library* 2013, Issue 4), Ovid MEDLINE, Ovid MEDLINE In-Process and Other Non-Indexed Citations, Ovid MEDLINE Daily, Ovid OLDMEDLINE (January 1946 to May 2013), EMBASE (January 1980 to May 2013), Latin American and Caribbean Literature on Health Sciences (LILACS) (January 1982 to May 2013), Web of Science Conference Proceedings Citation Index - Science (CPCI-S) (January 1970 to May 2013), the *meta*Register of Controlled Trials (*m*RCT) (www.controlled-trials.com), ClinicalTrials.gov (www.clinicaltrials.gov) and the WHO International Clinical Trials Registry Platform (ICTRP) (www.who.int/ictrp/search/en). We did not use any date or language restrictions in the electronic searches for trials. We last searched the electronic databases on 13 May 2013.

Selection criteria

We included randomised controlled trials of phacoemulsification compared to ECCE for age-related cataract.

Data collection and analysis

Two authors independently selected and assessed all studies. We defined two primary outcomes: 'good functional vision' (presenting visual acuity of 6/12 or better) and 'poor visual outcome' (best corrected visual acuity of less than 6/60) at three and 12 months after surgery. We also collected data on intra and postoperative complications, and the cost of the procedures.

Copyright © 2014 The Cochrane Collaboration. Published by John Wiley & Sons, Ltd.

[Intervention Review]

Non-penetrating filtration surgery versus trabeculectomy for open-angle glaucoma

Mohamed A Eldaly[1], Catey Bunce[2], Ola Z ElSheikha[1], Richard Wormald[2,3]

[1]Ophthalmology Department, Faculty of Medicine, Cairo University, Cairo, Egypt. [2]Research and Development Department, Moorfields Eye Hospital NHS Foundation Trust, London, UK. [3]Cochrane Eyes and Vision Group, ICEH, London School of Hygiene & Tropical Medicine, London, UK

Contact address: Mohamed A Eldaly, Ophthalmology Department, Faculty of Medicine, Cairo University, Cairo, Egypt. eldaly_mohamed@yahoo.com.

Editorial group: Cochrane Eyes and Vision Group.
Publication status and date: New, published in Issue 2, 2014.
Review content assessed as up-to-date: 27 September 2013.

Citation: Eldaly MA, Bunce C, ElSheikha OZ, Wormald R. Non-penetrating filtration surgery versus trabeculectomy for open-angle glaucoma. *Cochrane Database of Systematic Reviews* 2014, Issue 2. Art. No.: CD007059. DOI: 10.1002/14651858.CD007059.pub2.

Copyright © 2014 The Cochrane Collaboration. Published by John Wiley & Sons, Ltd.

ABSTRACT

Background

Glaucoma is the second commonest cause of blindness worldwide. Non-penetrating glaucoma surgeries have been developed as a safer and more acceptable surgical intervention to patients compared to conventional procedures.

Objectives

To compare the effectiveness of non-penetrating trabecular surgery compared with conventional trabeculectomy in people with glaucoma.

Search methods

We searched CENTRAL (which contains the Cochrane Eyes and Vision Group Trials Register) (*The Cochrane Library* 2013, Issue 8), Ovid MEDLINE, Ovid MEDLINE In-Process and Other Non-Indexed Citations, Ovid MEDLINE Daily, Ovid OLDMEDLINE (January 1946 to September 2013), EMBASE (January 1980 to September 2013), Latin American and Caribbean Literature on Health Sciences (LILACS) (January 1982 to September 2013), the *meta*Register of Controlled Trials (*m*RCT) (www.controlled-trials.com), ClinicalTrials.gov (www.clinicaltrials.gov) and the WHO International Clinical Trials Registry Platform (ICTRP) (www.who.int/ictrp/search/en). We did not use any date or language restrictions in the electronic searches for trials. We last searched the electronic databases on 27 September 2013.

Selection criteria

This review included relevant randomised controlled trials (RCTs) and quasi-RCTs on participants undergoing standard trabeculectomy for open-angle glaucoma compared to non-penetrating surgery, specifically viscocanalostomy or deep sclerectomy, with or without adjunctive measures.

Data collection and analysis

Two review authors independently reviewed the titles and abstracts of the search results. We obtained full copies of all potentially eligible studies and assessed each one according to the definitions in the 'Criteria for considering studies' section of this review. We used standard methodological procedures expected by The Cochrane Collaboration.

[Intervention Review]

Device-modified trabeculectomy for glaucoma

Xue Wang[1], Rabeea Khan[2], Anne Coleman[3]

[1]Department of Epidemiology, Johns Hopkins Bloomberg School of Public Health, Baltimore, Maryland, USA. [2]Internal Medicine, UCLA - Olive View, Sylmar, California, USA. [3]Jules Stein Eye Institute, UCLA, Los Angeles, California, USA

Contact address: Xue Wang, Department of Epidemiology, Johns Hopkins Bloomberg School of Public Health, 615 N. Wolfe Street, Baltimore, Maryland, 21205, USA. xwang@jhu.edu.

Editorial group: Cochrane Eyes and Vision Group.
Publication status and date: New, published in Issue 12, 2015.
Review content assessed as up-to-date: 22 December 2014.

Citation: Wang X, Khan R, Coleman A. Device-modified trabeculectomy for glaucoma. *Cochrane Database of Systematic Reviews* 2015, Issue 12. Art. No.: CD010472. DOI: 10.1002/14651858.CD010472.pub2.

Copyright © 2015 The Cochrane Collaboration. Published by John Wiley & Sons, Ltd.

ABSTRACT

Background

Glaucoma is an optic neuropathy that leads to vision loss and blindness. It is the second most common cause of irreversible blindness worldwide. The main treatment for glaucoma aims to reduce intraocular pressure (IOP) in order to slow or prevent further vision loss. IOP can be lowered with medications, and laser or incisional surgeries. Trabeculectomy is the most common incisional surgical procedure to treat glaucoma. Device-modified trabeculectomy is intended to improve drainage of the aqueous humor to lower IOP. Trabeculectomy-modifying devices include Ex-PRESS, Ologen, amniotic membrane, expanded polytetrafluoroethylene (E-PTFE) membrane, Gelfilm and others. However, the effectiveness and safety of these devices are uncertain.

Objectives

To assess the relative effectiveness, primarily with respect to IOP control and safety, of the use of different devices as adjuncts to trabeculectomy compared with standard trabeculectomy in eyes with glaucoma.

Search methods

We searched CENTRAL (which contains the Cochrane Eyes and Vision Trials Register) (2014, Issue 12), Ovid MEDLINE, Ovid MEDLINE In-Process and Other Non-Indexed Citations, Ovid MEDLINE Daily, Ovid OLDMEDLINE (January 1946 to December 2014), EMBASE (January 1980 to December 2014), PubMed (1948 to December 2014), Latin American and Caribbean Literature on Health Sciences (LILACS) (January 1982 to December 2014), the *meta*Register of Controlled Trials (*m*RCT) (www.controlled-trials.com), ClinicalTrials.gov (www.clinicaltrials.gov), and the World Health Organization (WHO) International Clinical Trials Registry Platform (ICTRP) (www.who.int/ictrp/search/en). We did not use any date or language restrictions in the electronic search for trials. We last searched the electronic databases on 22 December 2014.

Selection criteria

We included randomized controlled trials comparing devices used during trabeculectomy with trabeculectomy alone. We also included studies where antimetabolites were used in either or both treatment groups.

Data collection and analysis

We used standard procedures expected by Cochrane.

Copyright © 2015 The Cochrane Collaboration. Published by John Wiley & Sons, Ltd.

[Intervention Review]

Doxycycline plus ivermectin versus ivermectin alone for treatment of patients with onchocerciasis

Ayokunle T Abegunde[1], Richard M Ahuja[2], Nkem J Okafor[3]

[1]Division of Internal Medicine, John H. Stroger, Jr. Hospital of Cook County, Chicago, IL, USA. [2]Division of Ophthalmology, John H. Stroger, Jr. Hospital of Cook County, Chicago, IL, USA. [3]Kaplan Medical, Chicago, IL, USA

Contact address: Ayokunle T Abegunde, Division of Internal Medicine, John H. Stroger, Jr. Hospital of Cook County, 1900 W. Polk Street, Chicago, IL, 60612, USA. abegx@doctors.org.uk.

Editorial group: Cochrane Eyes and Vision Group.
Publication status and date: New, published in Issue 1, 2016.

Citation: Abegunde AT, Ahuja RM, Okafor NJ. Doxycycline plus ivermectin versus ivermectin alone for treatment of patients with onchocerciasis. *Cochrane Database of Systematic Reviews* 2016, Issue 1. Art. No.: CD011146. DOI: 10.1002/14651858.CD011146.pub2.

Copyright © 2016 The Cochrane Collaboration. Published by John Wiley & Sons, Ltd.

ABSTRACT

Background

Onchocerciasis, also known as "river blindness," is a parasitic disease that is caused by infection from the filarial nematode (roundworm), *Onchocerca volvulus*. Nematodes are transmitted from person to person by blackflies of the *Simulium* genus, which usually breed in fast flowing streams and rivers. The disease is the second leading infectious cause of blindness in endemic areas.

Ivermectin (a microfilaricide) is widely distributed to endemic populations for prevention and treatment of onchocerciasis. Doxycycline, an antibiotic, targets *Wolbachia* organisms that are crucial to the survival of adult onchocerca (macrofilaricide). Combined treatment with both drugs is believed to cause direct microfilarial death by ivermectin and indirect macrofilarial death by doxycycline. Long-term reduction in the numbers of microfilaria in the skin and eyes and in the numbers of adult worms in the body has the potential to reduce the transmission and occurrence of onchocercal eye disease.

Objectives

The primary aim of this review was to assess the effectiveness of doxycycline plus ivermectin versus ivermectin alone for prevention and treatment of onchocerciasis. The secondary aim was to assess the effectiveness of doxycycline plus ivermectin versus ivermectin alone for prevention and treatment of onchocercal ocular lesions in communities co-endemic for onchocerciasis and *Loa loa* (loiasis) infection.

Search methods

We searched CENTRAL (which contains the Cochrane Eyes and Vision Trials Register) (Issue 7, 2015), Ovid MEDLINE, Ovid MEDLINE In-Process and Other Non-Indexed Citations, Ovid MEDLINE Daily, Ovid OLDMEDLINE (January 1946 to July 2015), EMBASE (January 1980 to July 2015), PubMed (1948 to July 2015), Latin American and Caribbean Health Sciences Literature Database (LILACS) (1982 to July 2015), the *meta*Register of Controlled Trials (*m*RCT) (www.controlled-trials.com) (last searched 1 July 2014), ClinicalTrials.gov (www.clinicaltrials.gov) and the World Health Organization (WHO) International Clinical Trials Registry Platform (ICTRP) (www.who.int/ictrp/search/en). We did not use any date or language restrictions in the electronic search for trials. We last searched the electronic databases on 15 July 2015.

Selection criteria

We included randomized controlled trials (RCTs) that had compared doxycycline plus ivermectin versus ivermectin alone. Participants with or without one or more characteristic signs of ocular onchocerciasis resided in communities where onchocerciasis was endemic.

Copyright © 2016 The Cochrane Collaboration. Published by John Wiley & Sons, Ltd.

[Intervention Review]

Over the counter (OTC) artificial tear drops for dry eye syndrome

Andrew D Pucker[1], Sueko M Ng[2], Jason J Nichols[3]

[1]The Ohio State University, Columbus, Ohio, USA. [2]Department of Epidemiology, Johns Hopkins Bloomberg School of Public Health, Baltimore, Maryland, USA. [3]Office of the Vice President for Research and Economic Development, Office of Industry Engagement, Clinical Trials Office, The University of Alabama at Birmingham, Birmingham, Alabama, USA

Contact address: Andrew D Pucker, The Ohio State University, 320 West 10th Avenue, Columbus, Ohio, 43210, USA. pucker.1@osu.edu.

Editorial group: Cochrane Eyes and Vision Group.
Publication status and date: New, published in Issue 2, 2016.

Citation: Pucker AD, Ng SM, Nichols JJ. Over the counter (OTC) artificial tear drops for dry eye syndrome. *Cochrane Database of Systematic Reviews* 2016, Issue 2. Art. No.: CD009729. DOI: 10.1002/14651858.CD009729.pub2.

Copyright © 2016 The Cochrane Collaboration. Published by John Wiley & Sons, Ltd.

ABSTRACT

Background

Over the counter (OTC) artificial tears historically have been the first line of treatment for dry eye syndrome and dry eye-related conditions like contact lens discomfort, yet currently we know little regarding the overall efficacy of individual, commercially available artificial tears. This review provides a much needed meta-analytical look at all randomized and quasi-randomized clinical trials that have analyzed head-to-head comparisons of OTC artificial tears.

Objectives

To evaluate the effectiveness and toxicity of OTC artificial tear applications in the treatment of dry eye syndrome compared with another class of OTC artificial tears, no treatment, or placebo.

Search methods

We searched CENTRAL (which contains the Cochrane Eyes and Vision Trials Register) (2015, Issue 12), Ovid MEDLINE, Ovid MEDLINE In-Process and Other Non-Indexed Citations, Ovid MEDLINE Daily, Ovid OLDMEDLINE (January 1946 to December 2015), EMBASE (January 1980 to December 2015), Latin American and Caribbean Health Sciences (LILACS) (January 1982 to December 2015), the ISRCTN registry (www.isrctn.com/editAdvancedSearch), ClinicalTrials.gov (www.clinicaltrials.gov), the World Health Organization (WHO) International Clinical Trials Registry Platform (ICTRP) (www.who.int/ictrp/search/en) and the US Food and Drugs Administration (FDA) website (www.fda.gov). We did not use any date or language restrictions in the electronic searches for trials. We last searched the electronic databases on 4 December 2015. We searched reference lists of included trials for any additional trials not identified by the electronic searches.

Selection criteria

This review includes randomized controlled trials with adult participants who were diagnosed with dry eye, regardless of race and gender. We included trials in which the age of participants was not reported, and clinical trials comparing OTC artificial tears with another class of OTC artificial tears, placebo, or no treatment. This review did not consider head-to-head comparisons of artificial tears with another type of dry-eye therapy.

Copyright © 2016 The Cochrane Collaboration. Published by John Wiley & Sons, Ltd.

[Intervention Review]

Endothelial keratoplasty versus penetrating keratoplasty for Fuchs endothelial dystrophy

Mayank A Nanavaty[1], Xue Wang[2], Alex J Shortt[3]

[1]Sussex Eye Hospital, Brighton & Sussex University Hospitals NHS Trust, Brighton, UK. [2]Department of Epidemiology, Johns Hopkins Bloomberg School of Public Health, Baltimore, Maryland, USA. [3]The Moorfields Eye Hospital/UCL Institute of Ophthalmology National Institute for Health Research Biomedical Research Centre, London, UK

Contact address: Mayank A Nanavaty, Sussex Eye Hospital, Brighton & Sussex University Hospitals NHS Trust, Eastern Road, Brighton, Sussex, BN2 5BF, UK. mayank.nanavaty@bsuh.nhs.uk. mayank_nanavaty@hotmail.com.

Editorial group: Cochrane Eyes and Vision Group.
Publication status and date: New search for studies and content updated (no change to conclusions), published in Issue 2, 2014.
Review content assessed as up-to-date: 27 January 2014.

Citation: Nanavaty MA, Wang X, Shortt AJ. Endothelial keratoplasty versus penetrating keratoplasty for Fuchs endothelial dystrophy. *Cochrane Database of Systematic Reviews* 2014, Issue 2. Art. No.: CD008420. DOI: 10.1002/14651858.CD008420.pub3.

Copyright © 2014 The Cochrane Collaboration. Published by John Wiley & Sons, Ltd.

ABSTRACT

Background

Fuchs endothelial dystrophy (FED) is a condition in which there is premature degeneration of corneal endothelial cells. When the number of endothelial cells is reduced to a significant degree, fluid begins to accumulate within the cornea. As a result, the cornea loses its transparency and the individual suffers a reduction in vision. The only successful surgical treatment for this condition is replacement of part or all of the cornea with healthy tissue from a donor. The established procedure, penetrating keratoplasty (PKP), has been used for many years and its safety and efficacy are well known. Endothelial keratoplasty (EK) techniques are relatively new surgical procedures and their safety and efficacy relative to PKP are uncertain.

Objectives

The objective of this review was to compare the benefits and complications related to two surgical methods (EK and PKP) of replacing the diseased endothelial layer of the cornea with a healthy layer in people with FED.

Search methods

We searched CENTRAL (which contains the Cochrane Eyes and Vision Group Trials Register) (*The Cochrane Library* 2014, Issue 1), MEDLINE (January 1950 to January 2014), EMBASE (January 1980 to January 2014), Latin American and Caribbean Health Sciences Literature Database (LILACS) (January 1982 to January 2014), the *meta*Register of Controlled Trials (*m*RCT) (www.controlled-trials.com) and ClinicalTrials.gov (www.clinicaltrials.gov). There were no date or language restrictions in the electronic searches for trials. The electronic databases were last searched on 27 January 2014.

Selection criteria

We included all randomised controlled trials (RCTs) comparing EK versus PKP for people (of any age and gender) who had been clinically diagnosed with FED.

Data collection and analysis

Two authors independently screened the search results, assessed trial quality and extracted data using the standard methodological procedures expected by The Cochrane Collaboration.

[Intervention Review]

Environmental sanitary interventions for preventing active trachoma

Mansur Rabiu[1], Mahmoud B Alhassan[2], Henry OD Ejere[3], Jennifer R Evans[4]

[1]Prevention of Blindness Union, Riyadh, Saudi Arabia. [2]Clinical Ophthalmology, The National Eye Centre, Kaduna, Nigeria. [3]Phoebe Inpatient Medicine Specialists, Phoebe Putney Memorial Hospital, Albany, Georgia, USA. [4]Cochrane Eyes and Vision Group, ICEH, London School of Hygiene & Tropical Medicine, London, UK

Contact address: Mansur Rabiu, Prevention of Blindness Union, Riyadh, Saudi Arabia. mrabiu@hotmail.com.

Editorial group: Cochrane Eyes and Vision Group.
Publication status and date: New search for studies and content updated (no change to conclusions), published in Issue 2, 2012.

Citation: Rabiu M, Alhassan MB, Ejere HOD, Evans JR. Environmental sanitary interventions for preventing active trachoma. *Cochrane Database of Systematic Reviews* 2012, Issue 2. Art. No.: CD004003. DOI: 10.1002/14651858.CD004003.pub4.

Copyright © 2012 The Cochrane Collaboration. Published by John Wiley & Sons, Ltd.

ABSTRACT

Background

Trachoma is a major cause of avoidable blindness. It is responsible for about six million blind people worldwide, mostly in the poor communities of developing countries. One of the major strategies advocated for the control of the disease is the application of various environmental sanitary measures to such communities.

Objectives

To assess the evidence for the effectiveness of environmental sanitary measures on the prevalence of active trachoma in endemic areas.

Search methods

We searched CENTRAL (which contains the Cochrane Eyes and Vision Group Trials Register) (*The Cochrane Library* 2011, Issue 9), MEDLINE (January 1950 to September 2011), EMBASE (January 1980 to September 2011), Latin American and Caribbean Literature on Health Sciences (LILACS) (January 1982 to September 2011), the *meta*Register of Controlled Trials (*m*RCT) (www.controlled-trials.com) and ClinicalTrials.gov (www.clinicaltrials.gov). There were no date or language restrictions in the electronic searches for trials. The electronic databases were last searched on 23 September 2011. We checked the reference list of included trials and the Science Citation Index. We also contacted agencies, experts and researchers in trachoma control.

Selection criteria

We included randomised and quasi-randomised controlled trials comparing any form of environmental hygiene measures with no measure. These hygiene measures included fly control, provision of water and health education. Participants in the trials were people normally resident in the trachoma endemic areas.

Data collection and analysis

Two authors independently extracted data and assessed the quality of the included trials. Study authors were contacted for additional information. Six trials met the inclusion criteria but we did not conduct meta-analysis due to heterogeneity of the studies.

Copyright © 2012 The Cochrane Collaboration. Published by John Wiley & Sons, Ltd.

[Intervention Review]

Excimer laser refractive surgery versus phakic intraocular lenses for the correction of moderate to high myopia

Allon Barsam[1], Bruce DS Allan[2]

[1]Moorfields Eye Hospital NHS Foundation Trust, London, UK. [2]External Disease Service, Moorfields Eye Hospital NHS Foundation Trust, London, UK

Contact address: Allon Barsam, Moorfields Eye Hospital NHS Foundation Trust, City Road, London, EC1V 2PD, UK. abarsam@hotmail.com.

Editorial group: Cochrane Eyes and Vision Group.
Publication status and date: New search for studies and content updated (no change to conclusions), published in Issue 6, 2014.
Review content assessed as up-to-date: 11 February 2014.

Citation: Barsam A, Allan BDS. Excimer laser refractive surgery versus phakic intraocular lenses for the correction of moderate to high myopia. *Cochrane Database of Systematic Reviews* 2014, Issue 6. Art. No.: CD007679. DOI: 10.1002/14651858.CD007679.pub4.

Copyright © 2014 The Cochrane Collaboration. Published by John Wiley & Sons, Ltd.

ABSTRACT

Background

Myopia is a condition in which the focusing power (refraction) of the eye is greater than that required for clear distance vision. There are two main types of surgical correction for moderate to high myopia; excimer laser and phakic intraocular lenses (IOLs). Excimer laser refractive surgery for myopia works by removing corneal stroma to lessen the refractive power of the cornea and to bring the image of a viewed object into focus onto the retina rather than in front of it. Phakic IOLs for the treatment of myopia work by diverging light rays so that the image of a viewed object is brought into focus onto the retina rather than in front of the retina. They can be placed either in the anterior chamber of the eye in front of the iris or in the posterior chamber of the eye between the iris and the natural lens.

Objectives

To compare excimer laser refractive surgery and phakic IOLs for the correction of moderate to high myopia by evaluating postoperative uncorrected visual acuity, refractive outcome, potential loss of best spectacle corrected visual acuity (BSCVA) and the incidence of adverse outcomes.

Search methods

We searched CENTRAL (which contains the Cochrane Eyes and Vision Group Trials Register) (2014, Issue 1), Ovid MEDLINE, Ovid MEDLINE In-Process and Other Non-Indexed Citations, Ovid MEDLINE Daily, Ovid OLDMEDLINE (January 1946 to February 2014), EMBASE (January 1980 to February 2014), the *meta*Register of Controlled Trials (*m*RCT) (www.controlled-trials.com), ClinicalTrials.gov (www.clinicaltrials.gov) and the World Health Organization (WHO) International Clinical Trials Registry Platform (ICTRP) (www.who.int/ictrp/search/en). We did not use any date or language restrictions in the electronic searches for trials. We last searched the electronic databases on 11 February 2014.

Selection criteria

We included randomised controlled trials (RCTs) comparing excimer laser refractive surgery and phakic IOLs for the correction of myopia greater than 6.0 diopters (D) spherical equivalent.

Data collection and analysis

Two authors independently assessed trial quality and extracted data. We performed data analysis. We summarised data for outcomes using odds ratios. We used a fixed-effect model as only three trials were included in the review.

Copyright © 2014 The Cochrane Collaboration. Published by John Wiley & Sons, Ltd.

[Intervention Review]

Autologous serum eye drops for dry eye

Qing Pan[1,2], Adla Angelina[3], Michael Marrone[4], Walter J Stark[2], Esen K Akpek[2]

[1]Department of Ophthalmology, Zhejiang Provincial People's Hospital, Hangzhou Medical College, Hangzhou, China. [2]Wilmer Eye Institute, Johns Hopkins University School of Medicine, Baltimore, Maryland, USA. [3]Department of Pathology, University of Mississippi School of Medicine, Jackson, Mississippi, USA. [4]Department of Epidemiology, Johns Hopkins Bloomberg School of Public Health, Baltimore, Maryland, USA

Contact address: Qing Pan, Department of Ophthalmology, Zhejiang Provincial People's Hospital, Hangzhou Medical College, 158 Shangtang Road, Hangzhou, Zhejiang, China. panqing@hotmail.com.

Editorial group: Cochrane Eyes and Vision Group.
Publication status and date: New search for studies and content updated (no change to conclusions), published in Issue 2, 2017.

Citation: Pan Q, Angelina A, Marrone M, Stark WJ, Akpek EK. Autologous serum eye drops for dry eye. *Cochrane Database of Systematic Reviews* 2017, Issue 2. Art. No.: CD009327. DOI: 10.1002/14651858.CD009327.pub3.

Copyright © 2017 The Cochrane Collaboration. Published by John Wiley & Sons, Ltd.

ABSTRACT

Background

Theoretically, autologous serum eye drops (AS) offer a potential advantage over traditional therapies on the assumption that AS not only serve as a lacrimal substitute to provide lubrication but contain other biochemical components that allow them to mimic natural tears more closely. Application of AS has gained popularity as second-line therapy for patients with dry eye. Published studies on this subject indicate that autologous serum could be an effective treatment for dry eye.

Objectives

We conducted this review to evaluate the efficacy and safety of AS given alone or in combination with artificial tears as compared with artificial tears alone, saline, placebo, or no treatment for adults with dry eye.

Search methods

We searched CENTRAL (which contains the Cochrane Eyes and Vision Trials Register) (2016, Issue 5), Ovid MEDLINE, Ovid MEDLINE In-Process and Other Non-Indexed Citations, Ovid MEDLINE Daily, Ovid OLDMEDLINE (January 1946 to July 2016), Embase (January 1980 to July 2016), Latin American and Caribbean Literature on Health Sciences (LILACS) (January 1982 to July 2016), the ISRCTN registry (www.isrctn.com/editAdvancedSearch), ClinicalTrials.gov (www.clinicaltrials.gov) and the World Health Organization (WHO) International Clinical Trials Registry Platform (ICTRP) (www.who.int/ictrp/search/en). We also searched the Science Citation Index Expanded database (December 2016) and reference lists of included studies. We did not use any date or language restrictions in the electronic searches for trials. We last searched the electronic databases on 5 July 2016.

Selection criteria

We included randomized controlled trials (RCTs) that compared AS versus artificial tears for treatment of adults with dry eye.

Data collection and analysis

Two review authors independently screened all titles and abstracts and assessed full-text reports of potentially eligible trials. Two review authors extracted data and assessed risk of bias and characteristics of included trials. We contacted investigators to ask for missing data. For both primary and secondary outcomes, we reported mean differences with corresponding 95% confidence intervals (CIs) for continuous outcomes. We did not perform meta-analysis owing to differences in outcome assessments across trials.

Copyright © 2017 The Cochrane Collaboration. Published by John Wiley & Sons, Ltd.

[Intervention Review]

Optical correction of refractive error for preventing and treating eye symptoms in computer users

Pauline Heus[1], Jos H Verbeek[2], Christina Tikka[2]

[1]Cochrane Netherlands, Julius Center for Health Sciences and Primary Care, University Medical Center Utrecht, Utrecht University, Utrecht, Netherlands. [2]Cochrane Work Review Group, Finnish Institute of Occupational Health, TYÖTERVEYSLAITOS, Finland

Contact address: Pauline Heus, Cochrane Netherlands, Julius Center for Health Sciences and Primary Care, University Medical Center Utrecht, Utrecht University, Room Str. 6.131, PO Box 85500, Utrecht, 3508 GA, Netherlands. p.heus@umcutrecht.nl.

Editorial group: Cochrane Work Group.
Publication status and date: New, published in Issue 4, 2018.

Citation: Heus P, Verbeek JH, Tikka C. Optical correction of refractive error for preventing and treating eye symptoms in computer users. *Cochrane Database of Systematic Reviews* 2018, Issue 4. Art. No.: CD009877. DOI: 10.1002/14651858.CD009877.pub2.

Copyright © 2018 The Cochrane Collaboration. Published by John Wiley & Sons, Ltd.

ABSTRACT

Background

Computer users frequently complain about problems with seeing and functioning of the eyes. Asthenopia is a term generally used to describe symptoms related to (prolonged) use of the eyes like ocular fatigue, headache, pain or aching around the eyes, and burning and itchiness of the eyelids. The prevalence of asthenopia during or after work on a computer ranges from 46.3% to 68.5%. Uncorrected or under-corrected refractive error can contribute to the development of asthenopia. A refractive error is an error in the focusing of light by the eye and can lead to reduced visual acuity. There are various possibilities for optical correction of refractive errors including eyeglasses, contact lenses and refractive surgery.

Objectives

To examine the evidence on the effectiveness, safety and applicability of optical correction of refractive error for reducing and preventing eye symptoms in computer users.

Search methods

We searched the Cochrane Central Register of Controlled Trials (CENTRAL); PubMed; Embase; Web of Science; and OSH update, all to 20 December 2017. Additionally, we searched trial registries and checked references of included studies.

Selection criteria

We included randomised controlled trials (RCTs) and quasi-randomised trials of interventions evaluating optical correction for computer workers with refractive error for preventing or treating asthenopia and their effect on health related quality of life.

Data collection and analysis

Two authors independently assessed study eligibility and risk of bias, and extracted data. Where appropriate, we combined studies in a meta-analysis.

Main results

We included eight studies with 381 participants. Three were parallel group RCTs, three were cross-over RCTs and two were quasi-randomised cross-over trials. All studies evaluated eyeglasses, there were no studies that evaluated contact lenses or surgery. Seven studies evaluated computer glasses with at least one focal area for the distance of the computer screen with or without additional focal areas in

[Intervention Review]

Face washing promotion for preventing active trachoma

Henry OD Ejere[1], Mahmoud B Alhassan[2], Mansur Rabiu[3]

[1]Hode Internal Medicine, Texas, USA. [2]Clinical Ophthalmology, The National Eye Centre, Kaduna, Nigeria. [3]Prevention of Blindness Union, Riyadh, Saudi Arabia

Contact address: Henry OD Ejere, Hode Internal Medicine, 120 South Park Drive, Suite F, Brownwood, Texas, 76801, USA. hodejere2000@yahoo.com.

Editorial group: Cochrane Eyes and Vision Group.
Publication status and date: New search for studies and content updated (no change to conclusions), published in Issue 2, 2015.
Review content assessed as up-to-date: 26 January 2015.

Citation: Ejere HOD, Alhassan MB, Rabiu M. Face washing promotion for preventing active trachoma. *Cochrane Database of Systematic Reviews* 2015, Issue 2. Art. No.: CD003659. DOI: 10.1002/14651858.CD003659.pub4.

Copyright © 2015 The Cochrane Collaboration. Published by John Wiley & Sons, Ltd.

ABSTRACT

Background

Trachoma remains a major cause of avoidable blindness among underprivileged populations in many developing countries. It is estimated that about 146 million people have active trachoma and nearly six million people are blind due to complications associated with repeat infections.

Objectives

The objective of this review was to assess the effects of face washing promotion for the prevention of active trachoma in endemic communities.

Search methods

We searched CENTRAL (which contains the Cochrane Eyes and Vision Group Trials Register) (2015, Issue 1), Ovid MEDLINE, Ovid MEDLINE In-Process and Other Non-Indexed Citations, Ovid MEDLINE Daily, Ovid OLDMEDLINE (January 1946 to January 2015), EMBASE (January 1980 to January 2015), PubMed (January 1948 to January 2015), Latin American and Caribbean Health Sciences Literature Database (LILACS) (January 1982 to January 2015), the *meta*Register of Controlled Trials (*m*RCT) (www.controlled-trials.com) (accessed 10 January 2014), ClinicalTrials.gov (www.clinicaltrials.gov) and the World Health Organization (WHO) International Clinical Trials Registry Platform (ICTRP) (www.who.int/ictrp/search/en). We did not use any date or language restrictions in the electronic searches for trials. We last searched the electronic databases on 26 January 2015.

To identify further relevant trials we checked the reference lists of the included trials. Also, we used the Science Citation Index to search for references to publications that cited the trials included in the review. We contacted investigators and experts in the field to identify additional trials.

Selection criteria

We included randomized controlled trials (RCTs) or quasi-RCTs that compared face washing with no treatment or face washing combined with antibiotics against antibiotics alone. Trial participants were residents of endemic trachoma communities.

Data collection and analysis

Two review authors independently extracted data and assessed trial quality. We contacted trial authors for additional information when needed. Two trials met our inclusion criteria; but we did not conduct meta-analysis due to methodological heterogeneity.

Copyright © 2015 The Cochrane Collaboration. Published by John Wiley & Sons, Ltd.

[Intervention Review]

Face-down positioning or posturing after macular hole surgery

Ameenat Lola Solebo[1], Clemens AK Lange[2,3], Catey Bunce[4], James W Bainbridge[5]

[1]Ophthalmology/Epidemiology, Institute of Child Health, London, UK. [2]Institute of Ophthalmology, London, UK. [3]University Eye Hospital Freiburg, Freiburg, Germany. [4]Research and Development Department, Moorfields Eye Hospital NHS Foundation Trust, London, UK. [5]Division of Molecular Therapy, Institute of Ophthalmology, London, UK

Contact address: Ameenat Lola Solebo, Ophthalmology/Epidemiology, Institute of Child Health, 30 Guilford Street, London, WC1N 1EH, UK. l.solebo@ich.ucl.ac.uk. lolawhoshe@yahoo.co.uk.

Editorial group: Cochrane Eyes and Vision Group.
Publication status and date: New, published in Issue 12, 2011.
Review content assessed as up-to-date: 29 August 2011.

Citation: Solebo AL, Lange CAK, Bunce C, Bainbridge JW. Face-down positioning or posturing after macular hole surgery. *Cochrane Database of Systematic Reviews* 2011, Issue 12. Art. No.: CD008228. DOI: 10.1002/14651858.CD008228.pub2.

Copyright © 2011 The Cochrane Collaboration. Published by John Wiley & Sons, Ltd.

ABSTRACT

Background

Macular holes cause significant loss of central vision. With the aim of improving the outcome of surgery, a variable period of face-down positioning may be advised.

Objectives

To evaluate the evidence of the impact of postoperative face-down positioning on the outcome of surgery for macular hole.

Search methods

We searched CENTRAL (which contains the Cochrane Eyes and Vision Group Trials Register) (*The Cochrane Library* 2011, Issue 8), MEDLINE (January 1950 to August 2011), EMBASE (January 1980 to August 2011), the International Standard Randomised Controlled Trial Number Register (ISRCTN Register) (http://www.controlled-trials.com), the WHO International Clinical Trials Registry Platform (ICTRP) (http://www.who.int/ictrp/search/en) and ClinicalTrials.gov (http://clinicaltrials.gov). There were no date or language restrictions in the electronic searches for trials. The electronic databases were last searched on 29 August 2011.

Selection criteria

We included randomised controlled trials (RCTs) in which postoperative face-down positioning was compared to no face-down positioning following surgery for macular holes.

Data collection and analysis

Data were collected and analysed independently by two authors.

Main results

Three RCTs were identified, A, B and C; one of which was unpublished data. We were unable to conduct a meta-analysis due to study heterogeneity regarding duration of face-down positioning and surgical methods (use of inner limiting peel).

All three studies suggested an overall beneficial effect of posturing in terms of closure of holes: (A: risk ratio (RR) 1.10; 95% confidence interval (CI) 1.00 to 1.20, P = 0.05); B: RR 1.58, CI 1.0 to 2.5, P = 0.01; C: RR 1.03, CI 0.9 to 1.17, P = 0.67).

Copyright © 2011 The Cochrane Collaboration. Published by John Wiley & Sons, Ltd.

[Intervention Review]

Fibrin glue versus sutures for conjunctival autografting in primary pterygium surgery

Vito Romano[1], Mario Cruciani[2], Luigi Conti[3], Luigi Fontana[4]

[1]Ophthalmology, Royal Liverpool University Hospital, Liverpool, UK. [2]Center of Community Medicine and Infectious Diseases Service, ULSS 20 Verona, Verona, Italy. [3]Clinica Stabia, private practice, Castellammare di Stabia, Italy. [4]Ophthalmology, Hospital of Arcispedale Santa Maria Nuova, Reggio-Emilia, Italy

Contact address: Vito Romano, Ophthalmology, Royal Liverpool University Hospital, Prescot Street, Liverpool, L7 8XP, UK. vito.romano@gmail.com.

Editorial group: Cochrane Eyes and Vision Group.
Publication status and date: New, published in Issue 12, 2016.
Review content assessed as up-to-date: 14 October 2016.

Citation: Romano V, Cruciani M, Conti L, Fontana L. Fibrin glue versus sutures for conjunctival autografting in primary pterygium surgery. *Cochrane Database of Systematic Reviews* 2016, Issue 12. Art. No.: CD011308. DOI: 10.1002/14651858.CD011308.pub2.

Copyright © 2016 The Cochrane Collaboration. Published by John Wiley & Sons, Ltd.

ABSTRACT

Background

Pterygium, a growth of the conjunctiva over the cornea, is a progressive disease leading in advanced stages to visual impairment, restriction of ocular motility, chronic inflammation and cosmetic concerns. Surgical removal is the treatment of choice, but recurrence can be a problem. Currently the best surgical option in terms of recurrence is conjunctival autograft. To date the most common surgical methods of attaching conjunctival autografts to the sclera are through suturing or fibrin glue. Each method presents its own advantages and disadvantages. Sutures require considerable skill from the surgeon and can be associated with a prolonged operation time, postoperative discomfort and suture-related complications, whereas fibrin glue may give a decreased operation time, improve postoperative comfort and avoid suture-related problems.

Objectives

To assess the effectiveness of fibrin glue compared to sutures in conjunctival autografting for the surgical treatment of pterygium.

Search methods

We searched CENTRAL (which contains the Cochrane Eyes and Vision Trials Register) (2016, Issue 9), Ovid MEDLINE, Ovid MEDLINE In-Process and Other Non-Indexed Citations, Ovid MEDLINE Daily, Ovid OLDMEDLINE (January 1946 to October 2016), Embase (January 1980 to October 2016), the ISRCTN registry (www.isrctn.com/editAdvancedSearch), ClinicalTrials.gov (www.clinicaltrials.gov), and the World Health Organization (WHO) International Clinical Trials Registry Platform (ICTRP) (www.who.int/ictrp/search/en). We did not use any date or language restrictions in the electronic searches for trials. We last searched the electronic databases on 14 October 2016.

Selection criteria

We included randomised controlled trials (RCTs) in any setting where fibrin glue was compared with sutures to treat people with pterygium.

[Intervention Review]

Macular grid laser photocoagulation for branch retinal vein occlusion

Fook Chang Lam[1], Seen N Chia[2], Richard MH Lee[3]

[1]Western Sussex Hospitals NHS Foundation Trust, West Sussex, UK. [2]Tennent Institute of Ophthalmology, Gartnavel General Hospital, Glasgow, UK. [3]Institute of Ophthalmology, University College London, London, UK

Contact address: Fook Chang Lam, Western Sussex Hospitals NHS Foundation Trust, West Sussex, UK. fook_chang@hotmail.com.

Editorial group: Cochrane Eyes and Vision Group.
Publication status and date: New, published in Issue 5, 2015.

Citation: Lam FC, Chia SN, Lee RMH. Macular grid laser photocoagulation for branch retinal vein occlusion. *Cochrane Database of Systematic Reviews* 2015, Issue 5. Art. No.: CD008732. DOI: 10.1002/14651858.CD008732.pub2.

Copyright © 2015 The Cochrane Collaboration. Published by John Wiley & Sons, Ltd.

ABSTRACT

Background

Branch retinal vein occlusion (BRVO) is the second most common cause of retinal vascular abnormality after diabetic retinopathy. Persistent macular oedema develops in 60% of eyes with a BRVO. Untreated, only 14% of eyes with chronic macular oedema will have a visual acuity (VA) of 20/40 or better. Macular grid laser photocoagulation is used for chronic non-ischaemic macular oedema following BRVO and has been the mainstay of treatment for over 20 years. New treatments are available and a systematic review is necessary to ensure that the most up-to-date evidence is considered objectively.

Objectives

To examine the effects of macular grid laser photocoagulation in the treatment of macular oedema following BRVO.

Search methods

We searched CENTRAL, Ovid MEDLINE, EMBASE, Web of Science Conference Proceedings Citation Index, the *meta*Register of Controlled Trials (*m*RCT), ClinicalTrials.gov and the WHO International Clinical Trials Registry Platform. We did not use any date or language restrictions in the electronic searches for trials. We last searched the electronic databases on 21 August 2014.

Selection criteria

We included randomised controlled trials (RCTs) comparing macular grid laser photocoagulation treatment to another treatment, sham treatment or no treatment.

Data collection and analysis

We used standard methodological procedures expected by Cochrane.

Main results

We included five studies conducted in Europe and North America. Four separate trials compared grid laser to no treatment, sham treatment, intravitreal bevacizumab and intravitreal triamcinolone. One further trial compared subthreshold to threshold laser. Two of these trials were judged to be at high risk of bias in one or more domains.

In one trial of grid laser versus observation, people receiving grid laser were more likely to gain visual acuity (VA) (10 or more ETDRS letters) at 36 months (RR 1.75, 95% confidence interval (CI) 1.08 to 2.84, 78 participants, moderate-quality evidence). The effect

[Intervention Review]

Anti-vascular endothelial growth factor for proliferative diabetic retinopathy

Maria José Martinez-Zapata[1], Arturo J Martí-Carvajal[2], Ivan Solà[1], José I Pijoán[3,4], José A Buil-Calvo[5], Josep A Cordero[6], Jennifer R Evans[7]

[1]Iberoamerican Cochrane Centre, Biomedical Research Institute Sant Pau (IIB Sant Pau), CIBER Epidemiología y Salud Pública (CIBERESP), Barcelona, Spain. [2]Iberoamerican Cochrane Network, Valencia, Venezuela. [3]Hospital Universitario Cruces, Barakaldo, Spain. [4]BioCruces Health Research Institute, CIBER Epidemiología y Salud Pública (CIBERESP), Barakaldo, Spain. [5]Oftalmology, Hospital de la Santa Creu i Sant Pau, Barcelona, Spain. [6]Blanquerna School of Health Science, Universitat Ramon Llull, Barcelona, Spain. [7]Cochrane Eyes and Vision Group, ICEH, London School of Hygiene & Tropical Medicine, London, UK

Contact address: Maria José Martinez-Zapata, Iberoamerican Cochrane Centre, Biomedical Research Institute Sant Pau (IIB Sant Pau), CIBER Epidemiología y Salud Pública (CIBERESP), Sant Antoni M. Claret 171, Casa de Convalescència, Barcelona, Catalonia, 08041, Spain. mmartinezz@santpau.cat.

Editorial group: Cochrane Eyes and Vision Group.
Publication status and date: Edited (no change to conclusions), published in Issue 11, 2014.
Review content assessed as up-to-date: 28 April 2014.

Citation: Martinez-Zapata MJ, Martí-Carvajal AJ, Solà I, Pijoán JI, Buil-Calvo JA, Cordero JA, Evans JR. Anti-vascular endothelial growth factor for proliferative diabetic retinopathy. *Cochrane Database of Systematic Reviews* 2014, Issue 11. Art. No.: CD008721. DOI: 10.1002/14651858.CD008721.pub2.

Copyright © 2014 The Cochrane Collaboration. Published by John Wiley & Sons, Ltd.

ABSTRACT

Background

Proliferative diabetic retinopathy (PDR) is a complication of diabetic retinopathy that can cause blindness. Although panretinal photocoagulation (PRP) is the treatment of choice for PDR, it has secondary effects that can affect vision. An alternative treatment such as anti-vascular endothelial growth factor (anti-VEGF), which produces an inhibition of vascular proliferation, could improve the vision of people with PDR.

Objectives

To assess the effectiveness and safety of anti-VEGFs for PDR.

Search methods

We searched CENTRAL (which contains the Cochrane Eyes and Vision Group Trials Register) (2014, Issue 3), Ovid MEDLINE, Ovid MEDLINE In-Process and Other Non-Indexed Citations, Ovid MEDLINE Daily, Ovid OLDMEDLINE (January 1946 to April 2014), EMBASE (January 1980 to April 2014), the *meta*Register of Controlled Trials (*m*RCT) (www.controlled-trials.com), ClinicalTrials.gov (www.clinicaltrials.gov) and the World Health Organization (WHO) International Clinical Trials Registry Platform (ICTRP) (www.who.int/ictrp/search/en). We did not use any date or language restrictions in the electronic searches for trials. We last searched the electronic databases on 28 April 2014.

Selection criteria

We included randomised controlled trials (RCTs) comparing anti-VEGFs to another active treatment, sham treatment or no treatment for people with PDR. We also included studies that assessed the combination of anti-VEGFs with other treatments.

[Intervention Review]

Non-surgical interventions for acute internal hordeolum

Kristina Lindsley[1], Jason J Nichols[2], Kay Dickersin[3]

[1]Department of Epidemiology, Johns Hopkins Bloomberg School of Public Health, Baltimore, Maryland, USA. [2]Office of the Vice President for Research and Economic Development, Office of Industry Engagement, Clinical Trials Office, The University of Alabama at Birmingham, Birmingham, Alabama, USA. [3]Center for Clinical Trials and US Cochrane Center, Johns Hopkins University, Baltimore, MD, USA

Contact address: Kristina Lindsley, Department of Epidemiology, Johns Hopkins Bloomberg School of Public Health, 615 North Wolfe Street, Mail Room E6132, Baltimore, Maryland, 21205, USA. klindsley@jhu.edu.

Editorial group: Cochrane Eyes and Vision Group.
Publication status and date: New search for studies and content updated (no change to conclusions), published in Issue 1, 2017.

Citation: Lindsley K, Nichols JJ, Dickersin K. Non-surgical interventions for acute internal hordeolum. *Cochrane Database of Systematic Reviews* 2017, Issue 1. Art. No.: CD007742. DOI: 10.1002/14651858.CD007742.pub4.

Copyright © 2017 The Cochrane Collaboration. Published by John Wiley & Sons, Ltd.

ABSTRACT

Background

A hordeolum is a common, painful inflammation of the eyelid margin that is usually caused by a bacterial infection. The infection affects oil glands of the eyelid and can be either internal or external. In many cases, the lesion drains spontaneously and resolves without treatment; however, the inflammation can spread to other ocular glands or tissues, and recurrences are common. If unresolved, an acute internal hordeolum can become chronic, or can develop into a chalazion. External hordeola, also known as styes, were not included in the scope of this review.

Objectives

The objective of this review was to investigate the effectiveness, and when possible, the safety, of non-surgical treatments for acute internal hordeola compared with observation or placebo.

Search methods

We searched CENTRAL (which contains the Cochrane Eyes and Vision Trials Register (2016; Issue 12)), MEDLINE Ovid, MEDLINE Ovid Epub Ahead of Print, MEDLINE Ovid In-Process & Other Non-Indexed Citations, MEDLINE(R) Ovid Daily (January 1946 to December 2016), Embase (January 1947 to December 2016), PubMed (1948 to December 2016), Latin American and Caribbean Literature on Health Sciences (LILACS (January 1982 to December 2016)), the *meta*Register of Controlled Trials (*m*RCT; www.controlled-trials.com (last searched 26 July 2012)), ClinicalTrials.gov (www.clinicaltrials.gov), and the World Health Organization (WHO) International Clinical Trials Registry Platform (ICTRP) (www.who.int/ictrp/search/en). We used no date or language restrictions in the electronic searches for trials. We last searched the electronic databases on 2 December 2016.

Selection criteria

The selection criteria for this review included randomized or quasi-randomized clinical trials of participants diagnosed with an acute internal hordeolum. Studies of participants with external hordeola (styes), chronic hordeola, or chalazia were excluded. Non-surgical interventions of interest included the use of hot or warm compresses, lid scrubs, antibiotics, or steroids compared with observation, placebo, or other active interventions.

Data collection and analysis

Two review authors independently assessed the references identified by electronic searches for inclusion in this review. No relevant studies were found. The reasons for exclusion were documented.

[Intervention Review]

Interventions for involutional lower lid entropion

Kostas G Boboridis[1], Catey Bunce[2]

[1]Aristotle University of Thessaloniki, 54622 Thessaloniki, Greece. [2]Research and Development Department, Moorfields Eye Hospital NHS Foundation Trust, London, UK

Contact address: Kostas G Boboridis, Aristotle University of Thessaloniki, Pavlou Mela 16, 54622 Thessaloniki, Greece. kosbob@otenet.gr.

Editorial group: Cochrane Eyes and Vision Group.
Publication status and date: New search for studies and content updated (conclusions changed), published in Issue 12, 2011.
Review content assessed as up-to-date: 2 November 2011.

Citation: Boboridis KG, Bunce C. Interventions for involutional lower lid entropion. *Cochrane Database of Systematic Reviews* 2011, Issue 12. Art. No.: CD002221. DOI: 10.1002/14651858.CD002221.pub2.

Copyright © 2011 The Cochrane Collaboration. Published by John Wiley & Sons, Ltd.

ABSTRACT

Background

Entropion is a condition in which the eyelid margin turns in against the eyeball. Involutional or senile entropion is one of the most common lower lid malpositions in the elderly. The interventions described and currently used for the treatment of this condition are surgical in nature, although non-surgical temporary medical treatment for the early stages of entropion has also been reported. The relative effectiveness of these interventions has not yet been resolved.

Objectives

To examine the effect of interventions for involutional entropion and to assess whether any method is superior to any other.

Search methods

We searched CENTRAL (which contains the Cochrane Eyes and Vision Group Trials Register) (*The Cochrane Library* 2011, Issue 10), MEDLINE (January 1950 to November 2011), EMBASE (January 1980 to November 2011), the *meta*Register of Controlled Trials (*m*RCT) (www.controlled-trials.com),ClinicalTrials.gov (http://clinicaltrials.gov) and the WHO International Clinical Trials Registry Platform (ICTRP) (www.who.int/ictrp/search/en). There were no date or language restrictions in the electronic searches for trials. The electronic databases were last searched on 2 November 2011. We also searched oculoplastic textbooks, conference proceedings from the European and American Society of Ophthalmic Plastic and Reconstructive Surgery (ESOPRS, ASOPRS), European Ophthalmological Society (SOE), the Association for Recearch in Vision and Ophthalmology (ARVO) and American Academy of Ophthalmology (AAO) for the years 2000 to 2009 to identify relevant data. We attempted to contact researchers who are active in this field for information about further published or unpublished studies.

Selection criteria

We included randomised controlled trials (RCTs) with no restriction on date or language comparing two or more surgical methods for correction of involutional lower eyelid entropion in people older than 60 years of age with involutional lower lid entropion.

Data collection and analysis

Each review author independently assessed study abstracts identified from the electronic and manual searches. Author analysis was then compared and full papers for appropriate studies were obtained according to the inclusion criteria. Disagreements between the authors were resolved by discussion.

[Intervention Review]

Interventions to increase attendance for diabetic retinopathy screening

John G Lawrenson[1], Ella Graham-Rowe[2], Fabiana Lorencatto[2], Jennifer Burr[3], Catey Bunce[4], Jillian J Francis[2], Patricia Aluko[5], Stephen Rice[6], Luke Vale[6], Tunde Peto[7], Justin Presseau[8], Noah Ivers[9], Jeremy M Grimshaw[8,10]

[1]Centre for Applied Vision Research, School of Health Sciences, City University of London, London, UK. [2]School of Health Sciences, Centre for Health Services Research, City University London, London, UK. [3]School of Medicine, Medical and Biological Sciences Building, University of St Andrews, Fife, UK. [4]Department of Primary Care & Public Health Sciences, Kings College London, London, UK. [5]National Institute for Health Research (NIHR) Innovation Observatory, Newcastle University, Newcastle upon Tyne, UK. [6]Institute of Health & Society, Newcastle University, Newcastle upon Tyne, UK. [7]Centre for Public Health, Queen's University Belfast, Belfast, UK. [8]Clinical Epidemiology Program, Ottawa Hospital Research Institute, Ottawa, Canada. [9]Department of Family and Community Medicine, Women's College Hospital, Toronto, Canada. [10]Department of Medicine, University of Ottawa, Ottawa, Canada

Contact address: John G Lawrenson, Centre for Applied Vision Research, School of Health Sciences, City University of London, Northampton Square, London, EC1V 0HB, UK. j.g.lawrenson@city.ac.uk.

Editorial group: Cochrane Eyes and Vision Group.
Publication status and date: New, published in Issue 1, 2018.

Citation: Lawrenson JG, Graham-Rowe E, Lorencatto F, Burr J, Bunce C, Francis JJ, Aluko P, Rice S, Vale L, Peto T, Presseau J, Ivers N, Grimshaw JM. Interventions to increase attendance for diabetic retinopathy screening. *Cochrane Database of Systematic Reviews* 2018, Issue 1. Art. No.: CD012054. DOI: 10.1002/14651858.CD012054.pub2.

Copyright © 2018 The Cochrane Collaboration. Published by John Wiley & Sons, Ltd.

ABSTRACT

Background

Despite evidence supporting the effectiveness of diabetic retinopathy screening (DRS) in reducing the risk of sight loss, attendance for screening is consistently below recommended levels.

Objectives

The primary objective of the review was to assess the effectiveness of quality improvement (QI) interventions that seek to increase attendance for DRS in people with type 1 and type 2 diabetes.

Secondary objectives were:

To use validated taxonomies of QI intervention strategies and behaviour change techniques (BCTs) to code the description of interventions in the included studies and determine whether interventions that include particular QI strategies or component BCTs are more effective in increasing screening attendance;

To explore heterogeneity in effect size within and between studies to identify potential explanatory factors for variability in effect size;

To explore differential effects in subgroups to provide information on how equity of screening attendance could be improved;

To critically appraise and summarise current evidence on the resource use, costs and cost effectiveness.

[Intervention Review]

Interventions to slow progression of myopia in children

Jeffrey J Walline[1], Kristina Lindsley[2], Satyanarayana S Vedula[2], Susan A Cotter[3], Donald O Mutti[1], J. Daniel Twelker[4]

[1]College of Optometry, The Ohio State University, Columbus, Ohio, USA. [2]Center for Clinical Trials, Department of Epidemiology, Johns Hopkins Bloomberg School of Public Health, Baltimore, Maryland, USA. [3]Southern California College of Optometry, Fullerton, California, USA. [4]Department of Ophthalmology, University of Arizona, Tucson, Arizona, USA

Contact address: Jeffrey J Walline, College of Optometry, The Ohio State University, 338 West Tenth Avenue, Columbus, Ohio, 43210-1240, USA. walline.1@osu.edu.

Editorial group: Cochrane Eyes and Vision Group.
Publication status and date: New, published in Issue 12, 2011.

Citation: Walline JJ, Lindsley K, Vedula SS, Cotter SA, Mutti DO, Twelker JD. Interventions to slow progression of myopia in children. *Cochrane Database of Systematic Reviews* 2011, Issue 12. Art. No.: CD004916. DOI: 10.1002/14651858.CD004916.pub3.

Copyright © 2011 The Cochrane Collaboration. Published by John Wiley & Sons, Ltd.

ABSTRACT

Background

Nearsightedness (myopia) causes blurry vision when looking at distant objects. Highly nearsighted people are at greater risk of several vision-threatening problems such as retinal detachments, choroidal atrophy, cataracts and glaucoma. Interventions that have been explored to slow the progression of myopia include bifocal spectacles, cycloplegic drops, intraocular pressure-lowering drugs, muscarinic receptor antagonists and contact lenses. The purpose of this review was to systematically assess the effectiveness of strategies to control progression of myopia in children.

Objectives

To assess the effects of several types of interventions, including eye drops, undercorrection of nearsightedness, multifocal spectacles and contact lenses, on the progression of nearsightedness in myopic children younger than 18 years. We compared the interventions of interest with each other, to single vision lenses (SVLs) (spectacles), placebo or no treatment.

Search methods

We searched CENTRAL (which contains the Cochrane Eyes and Vision Group Trials Register) (*The Cochrane Library* 2011, Issue 10), MEDLINE (January 1950 to October 2011), EMBASE (January 1980 to October 2011), Latin American and Caribbean Literature on Health Sciences (LILACS) (January 1982 to October 2011), the *meta*Register of Controlled Trials (*m*RCT) (www.controlled-trials.com) and ClinicalTrials.gov (http://clinicaltrials.gov). There were no date or language restrictions in the electronic searches for trials. The electronic databases were last searched on 11 October 2011. We also searched the reference lists and Science Citation Index for additional, potentially relevant studies.

Selection criteria

We included randomized controlled trials (RCTs) in which participants were treated with spectacles, contact lenses or pharmaceutical agents for the purpose of controlling progression of myopia. We excluded trials where participants were older than 18 years at baseline or participants had less than -0.25 diopters (D) spherical equivalent myopia.

Data collection and analysis

Two review authors independently extracted data and assessed the risk of bias for each included study. When possible, we analyzed data with the inverse variance method using a fixed-effect or random-effects model, depending on the number of studies and amount of heterogeneity detected.

[Intervention Review]

Intravitreal steroids for macular edema in diabetes

Donald A Grover[1], Tianjing Li[2], Colin CW Chong[3]

[1]Department of Ophthalmology, Strong Memorial Hospital, Rochester, NY, USA. [2]Cochrane Eyes and Vision Group US Project, Baltimore, USA. [3]Department of Ophthalmology and Eye Health, Save Sight Institute, Sydney, Australia

Contact address: Donald A Grover, Department of Ophthalmology, Strong Memorial Hospital, Box 659, 601 Elmwood Avenue, Rochester, NY, 14642, USA. dagrover@frontiernet.net.

Editorial group: Cochrane Eyes and Vision Group.
Publication status and date: Edited (no change to conclusions), published in Issue 1, 2009.

Citation: Grover DA, Li T, Chong CCW. Intravitreal steroids for macular edema in diabetes. *Cochrane Database of Systematic Reviews* 2008, Issue 1. Art. No.: CD005656. DOI: 10.1002/14651858.CD005656.pub2.

Copyright © 2009 The Cochrane Collaboration. Published by John Wiley & Sons, Ltd.

ABSTRACT

Background

Macular edema is secondary to leakage from diseased retinal capillaries and is an important cause of poor central visual acuity in patients with diabetic retinopathy.

Objectives

This review evaluated the effectiveness and safety of intraocular steroids in treating diabetic macular edema (DME).

Search methods

We searched CENTRAL, MEDLINE, EMBASE in June 2007, reference lists, Science Citation Index and conference proceedings.

Selection criteria

We included randomized clinical trials (RCTs) evaluating any form of intravitreal steroids for treating DME.

Data collection and analysis

Two authors independently assessed eligibility, methodological quality and extracted data. We performed meta-analyses when appropriate.

Main results

Seven studies, involving 632 DME eyes were included. Four examined the effectiveness of intravitreal triamcinolone acetate injection (IVTA), three examined intravitreal steroids implantation (fluocinolone acetonide implant (FAI) or dexamethasone drug delivery system (DDS)). Two trials were at low risk of bias, one was at median risk of bias, two were at high risk of bias and the remaining two were at unclear risk of bias.

The preponderance of data suggest a beneficial effect from IVTA. Comparing IVTA with controls, the mean difference in visual acuity was -0.15 LogMAR (95% CI -0.21 to -0.09) at 3 months (based on three trials), -0.23 LogMAR (95% CI -0.33 to -0.13) at 6 months (two trials), -0.29 LogMAR (95% CI -0.47 to -0.11) at 9 months (one trial), and -0.11 LogMAR (95% CI -0.20 to -0.03) at 24 months (one trial), all in favor of IVTA. The relative risk (RR) for one or more lines improvement in visual acuity was 2.85 (95% CI 1.59 to 5.10) at 3 months (two trials), 1.25 (95% CI 0.66 to 2.38) at 6 months (one trial), and 2.17 (95% CI 1.15 to 4.11) at 24 months (one trial), all in favor of IVTA. We did not find evidence for three or more lines improvement in visual acuity. The mean difference in retinal thickness was -131.97 um (95% CI -169.08 to -94.86) at 3 months (two trials), -135.00 um (95% CI -194.50 to -75.50) at

Copyright © 2009 The Cochrane Collaboration. Published by John Wiley & Sons, Ltd.

[Intervention Review]

Laser photocoagulation for proliferative diabetic retinopathy

Jennifer R Evans[1], Manuele Michelessi[2], Gianni Virgili[3]

[1] Cochrane Eyes and Vision Group, ICEH, London School of Hygiene & Tropical Medicine, London, UK. [2] Ophthalmology, Fondazione G.B. Bietti per lo studio e la ricerca in Oftalmolologia-IRCCS, Rome, Italy. [3] Department of Translational Surgery and Medicine, Eye Clinic, University of Florence, Florence, Italy

Contact address: Jennifer R Evans, Cochrane Eyes and Vision Group, ICEH, London School of Hygiene & Tropical Medicine, Keppel Street, London, WC1E 7HT, UK. jennifer.evans@lshtm.ac.uk.

Editorial group: Cochrane Eyes and Vision Group.
Publication status and date: Edited (no change to conclusions), published in Issue 8, 2015.

Citation: Evans JR, Michelessi M, Virgili G. Laser photocoagulation for proliferative diabetic retinopathy. *Cochrane Database of Systematic Reviews* 2014, Issue 11. Art. No.: CD011234. DOI: 10.1002/14651858.CD011234.pub2.

Copyright © 2015 The Cochrane Collaboration. Published by John Wiley & Sons, Ltd.

ABSTRACT

Background

Diabetic retinopathy is a complication of diabetes in which high blood sugar levels damage the blood vessels in the retina. Sometimes new blood vessels grow in the retina, and these can have harmful effects; this is known as proliferative diabetic retinopathy. Laser photocoagulation is an intervention that is commonly used to treat diabetic retinopathy, in which light energy is applied to the retina with the aim of stopping the growth and development of new blood vessels, and thereby preserving vision.

Objectives

To assess the effects of laser photocoagulation for diabetic retinopathy compared to no treatment or deferred treatment.

Search methods

We searched CENTRAL (which contains the Cochrane Eyes and Vision Group Trials Register) (2014, Issue 5), Ovid MEDLINE, Ovid MEDLINE In-Process and Other Non-Indexed Citations, Ovid MEDLINE Daily, Ovid OLDMEDLINE (January 1946 to June 2014), EMBASE (January 1980 to June 2014), the *meta*Register of Controlled Trials (*m*RCT) (www.controlled-trials.com), ClinicalTrials.gov (www.clinicaltrials.gov) and the World Health Organization (WHO) International Clinical Trials Registry Platform (ICTRP) (www.who.int/ictrp/search/en). We did not use any date or language restrictions in the electronic searches for trials. We last searched the electronic databases on 3 June 2014.

Selection criteria

We included randomised controlled trials (RCTs) where people (or eyes) with diabetic retinopathy were randomly allocated to laser photocoagulation or no treatment or deferred treatment. We excluded trials of lasers that are no longer in routine use. Our primary outcome was the proportion of people who lost 15 or more letters (3 lines) of best-corrected visual acuity (BCVA) as measured on a logMAR chart at 12 months. We also looked at longer-term follow-up of the primary outcome at two to five years. Secondary outcomes included mean best corrected distance visual acuity, severe visual loss, mean near visual acuity, progression of diabetic retinopathy, quality of life, pain, loss of driving licence, vitreous haemorrhage and retinal detachment.

Data collection and analysis

We used standard methods as expected by the Cochrane Collaboration. Two review authors selected studies and extracted data.

[Intervention Review]

Laser therapy for retinopathy in sickle cell disease

Kay Thi Myint[1], Soumendra Sahoo[2], Aung Win Thein[3], Soe Moe[4], Han Ni[5]

[1]Ophthalmology, Faculty of Medicine, SEGi University, Sibu, Malaysia. [2]Ophthalmology, Melaka Manipal Medical College, Melaka, Malaysia. [3]Department of Surgery, Melaka-Manipal Medical College, Melaka, Malaysia. [4]Dept. Community Medicine, Melaka-Manipal Medical College (MMMC), Melaka, Malaysia. [5]Internal Medicine, Faculty of Medicine, SEGi University, Teluk Intan, Malaysia

Contact address: Kay Thi Myint, Ophthalmology, Faculty of Medicine, SEGi University, Sibu, Sarawak, 96000, Malaysia. kaythimyint.eye@gmail.com.

Editorial group: Cochrane Cystic Fibrosis and Genetic Disorders Group.
Publication status and date: New, published in Issue 10, 2015.

Citation: Myint KT, Sahoo S, Thein AW, Moe S, Ni H. Laser therapy for retinopathy in sickle cell disease. *Cochrane Database of Systematic Reviews* 2015, Issue 10. Art. No.: CD010790. DOI: 10.1002/14651858.CD010790.pub2.

Copyright © 2015 The Cochrane Collaboration. Published by John Wiley & Sons, Ltd.

ABSTRACT

Background

Sickle cell disease includes a group of inherited haemoglobinopathies affecting multiple organs including the eyes. Some people with the disease develop ocular manifestations due to vaso-occlusion. Vision-threatening complications of sickle cell disease are mainly due to proliferative sickle retinopathy which is characterized by proliferation of new blood vessels. Laser photocoagulation is widely applicable in proliferative retinopathies such as proliferative sickle retinopathy and proliferative diabetic retinopathy. It is important to evaluate the efficacy and safety of laser photocoagulation in the treatment of proliferative sickle retinopathy to prevent sight-threatening complications.

Objectives

To evaluate the effectiveness of various techniques of laser photocoagulation therapy in sickle cell disease-related retinopathy.

Search methods

We searched the Cochrane Cystic Fibrosis and Genetic Disorders Group's Haemoglobinopathies Trials Register, compiled from electronic database searches and handsearching of journals and conference abstract books. Date of last search: 21 September 2015.

We also searched the following resources (24 March 2015): Latin American and Carribean Health Science Literature Database (LILACS); WHO International Clinical Trials Registry Platforms (ICTRP); and ClinicalTrials.gov.

Selection criteria

Randomised controlled trials comparing laser photocoagulation to no treatment in children and adults.

Data collection and analysis

Two authors independently assessed trial eligibility, the risk of bias of the included trials and extracted and analysed data. We contacted the trial authors for additional information.

Copyright © 2015 The Cochrane Collaboration. Published by John Wiley & Sons, Ltd.

[Intervention Review]

Laser-assisted in-situ keratomileusis (LASIK) versus photorefractive keratectomy (PRK) for myopia

Alex J Shortt[1], Bruce DS Allan[2], Jennifer R Evans[3]

[1]The Moorfields Eye Hospital/UCL Institute of Ophthalmology National Institute for Health Research Biomedical Research Centre, London, UK. [2]External Disease Service, Moorfields Eye Hospital NHS Foundation Trust, London, UK. [3]Cochrane Eyes and Vision Group, ICEH, London School of Hygiene & Tropical Medicine, London, UK

Contact address: Alex J Shortt, The Moorfields Eye Hospital/UCL Institute of Ophthalmology National Institute for Health Research Biomedical Research Centre, 162 City Road, London, EC1V 2PD, UK. a.shortt@ucl.ac.uk.

Editorial group: Cochrane Eyes and Vision Group.
Publication status and date: New search for studies and content updated (no change to conclusions), published in Issue 1, 2013.

Citation: Shortt AJ, Allan BDS, Evans JR. Laser-assisted in-situ keratomileusis (LASIK) versus photorefractive keratectomy (PRK) for myopia. *Cochrane Database of Systematic Reviews* 2013, Issue 1. Art. No.: CD005135. DOI: 10.1002/14651858.CD005135.pub3.

Copyright © 2013 The Cochrane Collaboration. Published by John Wiley & Sons, Ltd.

ABSTRACT

Background

Myopia (also known as short-sightedness or near-sightedness) is an ocular condition in which the refractive power of the eye is greater than is required, resulting in light from distant objects being focused in front of the retina instead of directly on it. The two most commonly used surgical techniques to permanently correct myopia are photorefractive keratectomy (PRK) and laser-assisted in-situ keratomileusis (LASIK).

Objectives

To compare the effectiveness and safety of LASIK and PRK for correction of myopia by examining post-treatment uncorrected visual acuity, refractive outcome, loss of best spectacle-corrected visual acuity, pain scores, flap complications in LASIK, subepithelial haze, adverse events, quality of life indices and higher order aberrations.

Search methods

We searched CENTRAL (which contains the Cochrane Eyes and Vision Group Trials Register) (*The Cochrane Library* 2012, Issue 11), Ovid MEDLINE, Ovid MEDLINE In-Process and Other Non-Indexed Citations, Ovid MEDLINE Daily, Ovid OLDMEDLINE (January 1946 to November 2012), EMBASE (January 1980 to November 2012), Latin American and Caribbean Literature on Health Sciences (LILACS) (January 1982 to November 2012), the *meta*Register of Controlled Trials (*m*RCT) (www.controlled-trials.com), ClinicalTrials.gov (www.clinicaltrials.gov) and the WHO International Clinical Trials Registry Platform (ICTRP) (www.who.int/ictrp/search/en). We did not use any date or language restrictions in the electronic searches for trials. We last searched the electronic databases on 15 November 2012. We also searched the reference lists of the studies and the Science Citation Index.

Selection criteria

We included randomised controlled trials comparing LASIK and PRK for the correction of any degree of myopia.

Data collection and analysis

Two authors independently assessed trial quality and extracted data. We summarised data using the odds ratio and mean difference. We combined odds ratios using a random-effects model after testing for heterogeneity.

Copyright © 2013 The Cochrane Collaboration. Published by John Wiley & Sons, Ltd.

[Intervention Review]

Medical interventions for primary open angle glaucoma and ocular hypertension

Clemens Vass[1], Cornelia Hirn[1], Thomas Sycha[2], Oliver Findl[1], Stefan Sacu[1], Peter Bauer[3], Leopold Schmetterer[4]

[1]Department of Ophthalmology, Medical University of Vienna, Vienna, Austria. [2]Department of Neurology, Medical University of Vienna, Vienna, Austria. [3]Institute of Medical Statistics, Medical University of Vienna, Vienna, Austria. [4]Institute of Medical Physics, Department of Clinical Pharmacology, Medical University of Vienna, Vienna, Austria

Contact address: Clemens Vass, Department of Ophthalmology, Medical University of Vienna, Währinger Gürtel 18-20, Vienna, A-1090, Austria. clemens.vass@meduniwien.ac.at.

Editorial group: Cochrane Eyes and Vision Group.
Publication status and date: Edited (no change to conclusions), published in Issue 1, 2009.
Review content assessed as up-to-date: 28 May 2007.

Citation: Vass C, Hirn C, Sycha T, Findl O, Sacu S, Bauer P, Schmetterer L. Medical interventions for primary open angle glaucoma and ocular hypertension. *Cochrane Database of Systematic Reviews* 2007, Issue 4. Art. No.: CD003167. DOI: 10.1002/14651858.CD003167.pub3.

Copyright © 2009 The Cochrane Collaboration. Published by John Wiley & Sons, Ltd.

ABSTRACT

Background

Primary open angle glaucoma (POAG) is a progressive optic neuropathy with an elevated intraocular pressure (IOP), where the optic nerve head becomes pathologically excavated and the visual field (VF) is characteristically altered. Ocular hypertension (OHT) is a condition with elevated IOP but without discernible pathology of the optic nerve head or the VF. It is a major risk factor for development of POAG.

Objectives

To assess and compare the effectiveness of topical pharmacological treatment for POAG or OHT to prevent progression or onset of glaucomatous optic neuropathy.

Search methods

We searched CENTRAL, MEDLINE and EMBASE in May 2007. We searched the bibliographies of identified articles and contacted experts, investigators and pharmaceutical companies for additional published and unpublished studies.

Selection criteria

Randomised controlled trials comparing topical pharmacological treatment to placebo, no treatment or other treatment for specified endpoints which included people with POAG or OHT, and with duration of treatment of at least one year.

Data collection and analysis

Two authors independently extracted data and assessed trial quality. Where appropriate, we summarised data using Peto odds ratio and mean difference after testing for heterogeneity between studies.

Main results

We included 26 trials, which randomised 4979 participants, in this review. Meta-analysis of 10 trials clearly demonstrated reduction of onset of VF defects in treated OHT (OR 0.62, 95% CI 0.47 to 0.81). No single drug showed a significant VF protection compared to placebo or untreated controls. We did identify some border line evidence for a positive influence of treatment on VF prognosis (OR 0.67, 95% CI 0.45 to 1.00) for the beta-blockers .

Copyright © 2009 The Cochrane Collaboration. Published by John Wiley & Sons, Ltd.

[Intervention Review]

Medical interventions for fungal keratitis

Nilo Vincent FlorCruz[1], Jennifer R Evans[2]

[1]Department of Ophthalmology and Visual Sciences, University of the Phillipines-Philippine General Hospital, Manila, Philippines. [2]Cochrane Eyes and Vision Group, ICEH, London School of Hygiene & Tropical Medicine, London, UK

Contact address: Nilo Vincent FlorCruz, Department of Ophthalmology and Visual Sciences, University of the Phillipines-Philippine General Hospital, Taft Avenue, Manila, 1000, Philippines. docnilo11@gmail.com.

Editorial group: Cochrane Eyes and Vision Group.
Publication status and date: New search for studies and content updated (conclusions changed), published in Issue 4, 2015.

Citation: FlorCruz NV, Evans JR. Medical interventions for fungal keratitis. *Cochrane Database of Systematic Reviews* 2015, Issue 4. Art. No.: CD004241. DOI: 10.1002/14651858.CD004241.pub4.

Copyright © 2015 The Cochrane Collaboration. Published by John Wiley & Sons, Ltd.

ABSTRACT

Background

Fungal keratitis is a fungal infection of the cornea. It is common in lower income countries, particularly in agricultural areas but relatively uncommon in higher income countries. Although there are medications available, their effectiveness is unclear.

Objectives

To assess the effects of different antifungal drugs in the management of fungal keratitis.

Search methods

We searched CENTRAL (which contains the Cochrane Eyes and Vision Group Trials Register) (2015, Issue 2), Ovid MEDLINE, Ovid MEDLINE In-Process and Other Non-Indexed Citations, Ovid MEDLINE Daily, Ovid OLDMEDLINE (January 1946 to March 2015), EMBASE (January 1980 to March 2015), Latin American and Caribbean Health Sciences Literature Database (LILACS) (January 1982 to March 2015), the ISRCTN registry (www.isrctn.com/editAdvancedSearch), ClinicalTrials.gov (www.clinicaltrials.gov) and the World Health Organization (WHO) International Clinical Trials Registry Platform (ICTRP) (www.who.int/ictrp/search/en). We did not use any date or language restrictions in the electronic searches for trials. We last searched the electronic databases on 16 March 2015.

Selection criteria

We included randomised controlled trials of medical therapy for fungal keratitis.

Data collection and analysis

Two review authors selected studies for inclusion in the review, assessed trials for risk of bias and extracted data. The primary outcome was clinical cure at two to three months. Secondary outcomes included best-corrected visual acuity, time to clinical cure, compliance with treatment, adverse outcomes and quality of life.

Main results

We included 12 trials in this review; 10 trials were conducted in India, one in Bangladesh and one in Egypt. Seven of these trials were at high risk of bias in one or more domains, two of these studies were at low risk of bias in all domains. Participants were randomised to the following comparisons: topical 5% natamycin compared to topical 1% voriconazole; topical 5% natamycin compared to topical 2% econazole; topical 5% natamycin compared to topical chlorhexidine gluconate (0.05%, 0.1% and 0.2%); topical 1% voriconazole compared to intrastromal voriconazole 50 g/0.1 mL (both treatments combined with topical 5% natamycin); topical 1% voriconazole

[Intervention Review]

Medical versus surgical interventions for open angle glaucoma

Jennifer Burr[1], Augusto Azuara-Blanco[2], Alison Avenell[3], Anja Tuulonen[4]

[1]School of Medicine, Medical and Biological Sciences Building, University of St Andrews, Fife, UK. [2]Health Services Research Unit, University of Aberdeen, Aberdeen, UK. [3]Health Services Research Unit, Health Sciences Building, University of Aberdeen, Aberdeen, UK. [4]Eye Centre, Tampere University Hospital, Tampere, Finland

Contact address: Jennifer Burr, School of Medicine, Medical and Biological Sciences Building, University of St Andrews, Fife, KY16 9TF, UK. jmb28@st-andrews.ac.uk.

Editorial group: Cochrane Eyes and Vision Group.
Publication status and date: New search for studies and content updated (no change to conclusions), published in Issue 9, 2012.
Review content assessed as up-to-date: 1 August 2012.

Citation: Burr J, Azuara-Blanco A, Avenell A, Tuulonen A. Medical versus surgical interventions for open angle glaucoma. *Cochrane Database of Systematic Reviews* 2012, Issue 9. Art. No.: CD004399. DOI: 10.1002/14651858.CD004399.pub3.

Copyright © 2012 The Cochrane Collaboration. Published by John Wiley & Sons, Ltd.

ABSTRACT

Background

Open angle glaucoma (OAG) is a common cause of blindness.

Objectives

To assess the effects of medication compared with initial surgery in adults with OAG.

Search methods

We searched CENTRAL (which contains the Cochrane Eyes and Vision Group Trials Register) (*The Cochrane Library* 2012, Issue 7), Ovid MEDLINE, Ovid MEDLINE In-Process and Other Non-Indexed Citations, Ovid MEDLINE Daily, Ovid OLDMEDLINE (January 1946 to August 2012), EMBASE (January 1980 to August 2012), Latin American and Caribbean Literature on Health Sciences (LILACS) (January 1982 to August 2012), Biosciences Information Service (BIOSIS) (January 1969 to August 2012), Cumulative Index to Nursing and Allied Health Literature (CINAHL) (January 1937 to August 2012), OpenGrey (System for Information on Grey Literature in Europe) (www.opengrey.eu/), Zetoc, the *meta*Register of Controlled Trials (*m*RCT) (www.controlled-trials.com) and the WHO International Clinical Trials Registry Platform (ICTRP) (www.who.int/ictrp/search/en). We did not use any date or language restrictions in the electronic searches for trials. We last searched the electronic databases on 1 August 2012. The National Research Register (NRR) was last searched in 2007 after which the database was archived. We also checked the reference lists of articles and contacted researchers in the field.

Selection criteria

We included randomised controlled trials (RCTs) comparing medications with surgery in adults with OAG.

Data collection and analysis

Two authors independently assessed trial quality and extracted data. We contacted study authors for missing information.

Copyright © 2012 The Cochrane Collaboration. Published by John Wiley & Sons, Ltd.

[Intervention Review]

Intraoperative Mitomycin C for glaucoma surgery

Mark Wilkins[1], Andrea Indar[1], Richard Wormald[2]

[1]Moorfields Eye Hospital NHS Foundation Trust, London, UK. [2]Cochrane Eyes and Vision Group, ICEH, London School of Hygiene & Tropical Medicine, London, UK

Contact address: Mark Wilkins, Moorfields Eye Hospital NHS Foundation Trust, London, EC1V 2PD, UK. mail@markwilkins.co.uk.

Editorial group: Cochrane Eyes and Vision Group.
Publication status and date: New search for studies and content updated (no change to conclusions), published in Issue 2, 2010.

Citation: Wilkins M, Indar A, Wormald R. Intraoperative Mitomycin C for glaucoma surgery. *Cochrane Database of Systematic Reviews* 2005, Issue 4. Art. No.: CD002897. DOI: 10.1002/14651858.CD002897.pub2.

Copyright © 2010 The Cochrane Collaboration. Published by John Wiley & Sons, Ltd.

ABSTRACT

Background

Trabeculectomy is performed as a treatment for glaucoma to lower the intraocular pressure (IOP). Mitomycin C (MMC) is an antimetabolite used during the initial stages of a trabeculectomy to prevent excessive postoperative scarring and thus reduce the risk of failure.

Objectives

To assess the effects of intraoperative MMC compared to placebo in trabeculectomy.

Search methods

We searched the Cochrane Central Register of Controlled Trials (CENTRAL) (which contains the Cochrane Eyes and Vision Group Trials Register) (*The Cochrane Library* Issue 4, 2009), MEDLINE (January 1966 to January 2010), EMBASE (January 1980 to January 2010), LILACS (Latin American and Caribbean Health Sciences Literature Database) (January 1982 to January 2010), OpenSIGLE (January 2010) and the UK Clinical Trials Gateway (UKCTG) (January 2010). We also wrote to investigators of trials included in the review to ask if they were aware of any other studies. There were no language or date restrictions in the search for trials. The electronic databases were last searched on 19 January 2010.

Selection criteria

We included randomised controlled trials (RCTs) of intraoperative MMC compared to placebo or no adjunct in trabeculectomy surgery.

Data collection and analysis

Two authors independently assessed trial quality and extracted data. We contacted trial investigators for missing information.

Main results

Eleven trials, involving a total of 698 participants, were included. The trials enrolled three types of participants (high risk of failure, trabeculectomy combined with cataract surgery, no previous surgical intervention). Mitomycin C appears to reduce the relative risk of failure of trabeculectomy both in eyes at high risk of failure (relative risk 0.32, 95% confidence interval: 0.20 to 0.53) and those undergoing surgery for the first time (relative risk 0.29, 95% confidence interval 0.16 to 0.53). No significant effect on failure was noted in the group undergoing trabeculectomy combined with cataract extraction. Mean IOP was significantly reduced at 12 months in all three participant groups receiving MMC compared to placebo. No significant increase in permanent sight-threatening complications was detected. However, none of the trials were large enough or of sufficient duration to address the long-term risk of bleb infection and endophthalmitis which has been reported in observational studies. Some evidence exists that MMC increases the risk of cataract.

Copyright © 2010 The Cochrane Collaboration. Published by John Wiley & Sons, Ltd.

[Intervention Review]

Mitomycin C versus 5-Fluorouracil for wound healing in glaucoma surgery

Emily Cabourne[1], Jonathan CK Clarke[1], Patricio G Schlottmann[2], Jennifer R Evans[3]

[1]Moorfields Eye Hospital NHS Foundation Trust, London, UK. [2]Organizacion Medica de Investigacion, Ciudad de Buenos Aires, Argentina. [3]Cochrane Eyes and Vision Group, ICEH, London School of Hygiene & Tropical Medicine, London, UK

Contact address: Jonathan CK Clarke, Moorfields Eye Hospital NHS Foundation Trust, 162 City Road, London, EC1V 2PD, UK. jonathan.clarke@moorfields.nhs.uk.

Editorial group: Cochrane Eyes and Vision Group.
Publication status and date: New, published in Issue 11, 2015.

Citation: Cabourne E, Clarke JCK, Schlottmann PG, Evans JR. Mitomycin C versus 5-Fluorouracil for wound healing in glaucoma surgery. *Cochrane Database of Systematic Reviews* 2015, Issue 11. Art. No.: CD006259. DOI: 10.1002/14651858.CD006259.pub2.

Copyright © 2015 The Cochrane Collaboration. Published by John Wiley & Sons, Ltd.

ABSTRACT

Background

Raised intraocular pressure is a risk factor for glaucoma. One treatment option is glaucoma drainage surgery (trabeculectomy). Antimetabolites are used during surgery to reduce postoperative scarring during wound healing. Two agents in common use are mitomycin C (MMC) and 5-Fluorouracil (5-FU).

Objectives

To assess the effects of MMC compared to 5-FU as an antimetabolite adjunct in trabeculectomy surgery.

Search methods

We searched CENTRAL (which contains the Cochrane Eyes and Vision Group Trials Register) (2015 Issue 9), Ovid MEDLINE, Ovid MEDLINE In-Process and Other Non-Indexed Citations, Ovid MEDLINE Daily, Ovid OLDMEDLINE (January 1946 to October 2015), EMBASE (January 1980 to October 2015), Latin American and Caribbean Health Sciences Literature Database (LILACS) (January 1982 to October 2015), the ISRCTN registry (www.isrctn.com/editAdvancedSearch), ClinicalTrials.gov (www.clinicaltrials.gov) and the World Health Organization (WHO) International Clinical Trials Registry Platform (ICTRP) (www.who.int/ictrp/search/en). We did not use any date or language restrictions in the electronic searches for trials. We last searched the electronic databases on 2 October 2015.

Selection criteria

We included randomised controlled trials where wound healing had been modified with MMC compared to 5-FU.

Data collection and analysis

Two review authors independently selected trials and collected data. The primary outcome was failure of a functioning trabeculectomy one year after surgery. Secondary outcomes included mean intraocular pressure at one year. We considered three subgroups: high risk of trabeculectomy failure (people with previous glaucoma surgery, extracapsular cataract surgery, African origin and people with secondary glaucoma or congenital glaucoma); medium risk of trabeculectomy failure (people undergoing trabeculectomy with extracapsular cataract surgery) and low risk of trabeculectomy failure (people who have received no previous surgical eye intervention).

[Intervention Review]

Multifocal versus monofocal intraocular lenses after cataract extraction

Samantha R de Silva[1], Jennifer R Evans[2], Varo Kirthi[3], Mohammed Ziaei[4a], Martin Leyland[5]

[1]Oxford Eye Hospital, Oxford, UK. [2]Cochrane Eyes and Vision, ICEH, London School of Hygiene & Tropical Medicine, London, UK. [3]Pain Research and Nuffield Department of Clinical Neurosciences, University of Oxford, Oxford, UK. [4]Moorfields Eye Hospital NHS Foundation Trust, London, UK. [5]Royal Berkshire Hospital NHS Trust, Reading, UK

[a]Joint third author

Contact address: Samantha R de Silva, Oxford Eye Hospital, Oxford, UK. samantha.r.desilva@googlemail.com.

Editorial group: Cochrane Eyes and Vision Group.
Publication status and date: New search for studies and content updated (no change to conclusions), published in Issue 12, 2016.

Citation: de Silva SR, Evans JR, Kirthi V, Ziaei M, Leyland M. Multifocal versus monofocal intraocular lenses after cataract extraction. *Cochrane Database of Systematic Reviews* 2016, Issue 12. Art. No.: CD003169. DOI: 10.1002/14651858.CD003169.pub4.

Copyright © 2016 The Cochrane Collaboration. Published by John Wiley & Sons, Ltd.

ABSTRACT

Background

Good unaided distance visual acuity (VA) is now a realistic expectation following cataract surgery and intraocular lens (IOL) implantation. Near vision, however, still requires additional refractive power, usually in the form of reading glasses. Multiple optic (multifocal) IOLs are available which claim to allow good vision at a range of distances. It is unclear whether this benefit outweighs the optical compromises inherent in multifocal IOLs.

Objectives

To assess the visual effects of multifocal IOLs in comparison with the current standard treatment of monofocal lens implantation.

Search methods

We searched CENTRAL (which contains the Cochrane Eyes and Vision Trials Register) (2016, Issue 5), Ovid MEDLINE, Ovid MEDLINE In-Process and Other Non-Indexed Citations, Ovid MEDLINE Daily, Ovid OLDMEDLINE (January 1946 to June 2016), Embase (January 1980 to June 2016), the ISRCTN registry (www.isrctn.com/editAdvancedSearch), ClinicalTrials.gov (www.clinicaltrials.gov), and the World Health Organization (WHO) International Clinical Trials Registry Platform (ICTRP) (www.who.int/ictrp/search/en). We did not use any date or language restrictions in the electronic searches for trials. We last searched the electronic databases on 13 June 2016.

Selection criteria

All randomised controlled trials comparing a multifocal IOL of any type with a monofocal IOL as control were included. Both unilateral and bilateral implantation trials were included. We also considered trials comparing multifocal IOLs with "monovision" whereby one eye is corrected for distance vision and one eye corrected for near vision.

Data collection and analysis

We used standard methodological procedures expected by Cochrane. We assessed the 'certainty' of the evidence using GRADE.

[Intervention Review]

Non-steroidal anti-inflammatory drugs versus corticosteroids for controlling inflammation after uncomplicated cataract surgery

Viral V Juthani[1], Elizabeth Clearfield[2], Roy S Chuck[1]

[1]Department of Ophthalmology and Visual Sciences, Albert Einstein College of Medicine, Montefiore Medical Center, New York, New York, USA. [2]Department of Epidemiology, Johns Hopkins Bloomberg School of Public Health, Baltimore, Maryland, USA

Contact address: Roy S Chuck, Department of Ophthalmology and Visual Sciences, Albert Einstein College of Medicine, Montefiore Medical Center, New York, New York, USA. rchuck@montefiore.org.

Editorial group: Cochrane Eyes and Vision Group.
Publication status and date: New, published in Issue 7, 2017.

Citation: Juthani VV, Clearfield E, Chuck RS. Non-steroidal anti-inflammatory drugs versus corticosteroids for controlling inflammation after uncomplicated cataract surgery. *Cochrane Database of Systematic Reviews* 2017, Issue 7. Art. No.: CD010516. DOI: 10.1002/14651858.CD010516.pub2.

Copyright © 2017 The Cochrane Collaboration. Published by John Wiley & Sons, Ltd.

ABSTRACT

Background

Cataract is a leading cause of blindness worldwide. Cataract surgery is commonly performed but can result in postoperative inflammation of the eye. Inadequately controlled inflammation increases the risk of complications. Non-steroidal anti-inflammatory drugs (NSAIDs) and corticosteroids are used to prevent and reduce inflammation following cataract surgery, but these two drug classes work by different mechanisms. Corticosteroids are effective, but NSAIDs may provide an additional benefit to reduce inflammation when given in combination with corticosteroids. A comparison of NSAIDs to corticosteroids alone or combination therapy with these two anti-inflammatory agents will help to determine the role of NSAIDs in controlling inflammation after routine cataract surgery.

Objectives

To evaluate the comparative effectiveness of topical NSAIDs (alone or in combination with topical corticosteroids) versus topical corticosteroids alone in controlling intraocular inflammation after uncomplicated phacoemulsification. To assess postoperative best-corrected visual acuity (BCVA), patient-reported discomfort, symptoms, or complications (such as elevation of IOP), and cost-effectiveness with the use of postoperative NSAIDs or corticosteroids.

Search methods

To identify studies relevant to this review, we searched the Cochrane Central Register of Controlled Trials (CENTRAL), which contains the Cochrane Eyes and Vision Trials Register (2016, Issue 12), MEDLINE Ovid (1946 to December 2016), Embase Ovid (1947 to 16 December 2016), PubMed (1948 to December 2016), LILACS (Latin American and Caribbean Health Sciences Literature Database) (1982 to 16 December 2016), the *meta*Register of Controlled Trials (*m*RCT) (www.controlled-trials.com; last searched 17 June 2013), ClinicalTrials.gov (www.clinicaltrials.gov; searched December 2016), and the WHO International Clinical Trials Registry Platform (ICTRP) (www.who.int/ictrp/search/en; searched December 2016).

Selection criteria

We included randomized controlled trials (RCTs) in which participants were undergoing phacoemulsification for uncomplicated cataract extraction. We included both trials in which topical NSAIDs were compared with topical corticosteroids and trials in which combination therapy (topical NSAIDs and corticosteroids) was compared with topical corticosteroids alone. The primary outcomes for this review were inflammation and best-corrected visual acuity (BCVA).

[Intervention Review]

Non-surgical interventions for convergence insufficiency

Mitchell Scheiman[1], Jane Gwiazda[2], Tianjing Li[3]

[1]Pennsylvania College of Optometry, Philadelphia, Pennsylvania, USA. [2]New England College of Optometry, Boston, Massachusetts, USA. [3]Cochrane Eyes and Vision Group US Project, Johns Hopkins Bloomberg School of Public Health, Baltimore, Maryland, USA

Contact address: Mitchell Scheiman, Pennsylvania College of Optometry, 1200 West Godfrey Avenue, Philadelphia, Pennsylvania, 19141, USA. mscheiman@salus.edu.

Editorial group: Cochrane Eyes and Vision Group.
Publication status and date: New, published in Issue 3, 2011.
Review content assessed as up-to-date: 6 October 2010.

Citation: Scheiman M, Gwiazda J, Li T. Non-surgical interventions for convergence insufficiency. *Cochrane Database of Systematic Reviews* 2011, Issue 3. Art. No.: CD006768. DOI: 10.1002/14651858.CD006768.pub2.

Copyright © 2011 The Cochrane Collaboration. Published by John Wiley & Sons, Ltd.

ABSTRACT

Background

Convergence insufficiency is a common eye muscle co-ordination problem in which the eyes have a strong tendency to drift outward (exophoria) when reading or doing close work. Symptoms may include eye strain, headaches, double vision, print moving on the page, frequent loss of place when reading, inability to concentrate, and short attention span.

Objectives

To systematically assess and synthesize evidence from randomized controlled trials (RCTs) on the effectiveness of non-surgical interventions for convergence insufficiency.

Search methods

We searched *The Cochrane Library*, MEDLINE, EMBASE, Science Citation Index, the *meta*Register of Controlled Trials (*m*RCT) (www.controlled-trials.com) and ClinicalTrials.gov (www.clinicaltrials.gov) on 7 October 2010. We manually searched reference lists and optometric journals.

Selection criteria

We included RCTs examining any form of non-surgical intervention against placebo, no treatment, sham treatment, or each other.

Data collection and analysis

Two authors independently assessed eligibility, risk of bias, and extracted data. We performed meta-analyses when appropriate.

Main results

We included six trials (three in children, three in adults) with a total of 475 participants. We graded four trials at low risk of bias.

Evidence from one trial (graded at low risk of bias) suggests that base-in prism reading glasses was no more effective than placebo reading glasses in improving clinical signs or symptoms in children.

Evidence from one trial (graded at high risk of bias) suggests that base-in prism glasses using a progressive addition lens design was more effective than progressive addition lens alone in decreasing symptoms in adults. At three weeks of therapy, the mean difference in Convergence Insufficiency Symptoms Survey (CISS) score was -10.24 points (95% confidence interval (CI) -15.45 to -5.03).

Copyright © 2011 The Cochrane Collaboration. Published by John Wiley & Sons, Ltd.

[Intervention Review]

Ocriplasmin for symptomatic vitreomacular adhesion

James E Neffendorf[1], Varo Kirthi[1], Edward Pringle[1], Timothy L Jackson[1,2]

[1]Department of Ophthalmology, King's College Hospital, London, UK. [2]School of Medicine, King's College London, London, UK

Contact address: James E Neffendorf, School of Medicine, King's College London, London, UK. james.neffendorf@gmail.com.

Editorial group: Cochrane Eyes and Vision Group.
Publication status and date: New, published in Issue 10, 2017.

Citation: Neffendorf JE, Kirthi V, Pringle E, Jackson TL. Ocriplasmin for symptomatic vitreomacular adhesion. *Cochrane Database of Systematic Reviews* 2017, Issue 10. Art. No.: CD011874. DOI: 10.1002/14651858.CD011874.pub2.

Copyright © 2017 The Cochrane Collaboration. Published by John Wiley & Sons, Ltd.

ABSTRACT

Background

Symptomatic vitreomacular adhesion (sVMA) is a recognised cause of visual loss and by tradition has been managed by pars plana vitrectomy (PPV). A less invasive alternative to surgery in some people is enzymatic vitreolysis, using an intravitreal injection of ocriplasmin.

Objectives

To assess the efficacy and safety of ocriplasmin compared to no treatment, sham or placebo for the treatment of sVMA.

Search methods

We searched the Cochrane Central Register of Controlled Trials (CENTRAL) (which contains the Cochrane Eyes and Vision Trials Register) (2017, Issue 1), MEDLINE Ovid (1946 to 24 February 2017), Embase Ovid (1947 to 24 February 2017), PubMed (1946 to 24 February 2017), the ISRCTN registry (www.isrctn.com/editAdvancedSearch); searched 24 February 2017, ClinicalTrials.gov (www.clinicaltrials.gov); searched 24 February 2017 and the World Health Organization (WHO) International Clinical Trials Registry Platform (ICTRP) (www.who.int/ictrp/search/en); searched 24 February 2017. We did not use any date or language restrictions in the electronic searches for trials.

Selection criteria

We included randomised controlled trials (RCTs) of people with sVMA. The intervention was intravitreal ocriplasmin 125 μg injection, and this was compared to placebo or sham injection (control). Placebo was defined as a single intravitreal injection of 0.10 mL placebo with identical drug vehicle diluted with saline. A sham injection was defined as the syringe hub or blunt needle touching the conjunctiva to simulate an injection.

Data collection and analysis

Two authors independently selected relevant trials, assessed methodological quality and extracted data. We graded the certainty of the evidence using the GRADE approach.

Main results

This review included four RCTs conducted in Europe and the USA with a total of 932 eyes of 932 participants. Participants were 18 to 97 years of age, with evidence of focal vitreomacular adhesion (VMA) on optical coherence tomography (OCT) imaging, with a best corrected visual acuity (BCVA) of 20/25 or worse in the study eye and 20/400 or better in the fellow eye. The interventions compared were intravitreal ocriplasmin versus sham (two RCTs) or placebo (two RCTs) injection. Both sham and placebo injection were classified

[Intervention Review]

Oral antivirals for preventing recurrent herpes simplex keratitis in people with corneal grafts

Uday K Bhatt[1], MN Abdul Karim[2], Jeremy I Prydal[3], Senthil V Maharajan[4], Usama Fares[5]

[1]Vision Eye Institute, Melbourne, Australia. [2]Kettering General Hospital, Kettering, UK. [3]Department of Ophthalmology, Leicester Royal Infirmary, Leicester, UK. [4]Queens Medical Centre, University Hospitals NHS Trust, Nottingham, UK. [5]Division of Ophthalmology and Visual Sciences, B Floor, Eye and ENT Building, University of Nottingham, Nottingham, UK

Contact address: Uday K Bhatt, Vision Eye Institute, 600 St Kilda Road, Melbourne, VIC 3004, Australia. uday.bhatt@gmail.com.

Editorial group: Cochrane Eyes and Vision Group.
Publication status and date: New, published in Issue 11, 2016.

Citation: Bhatt UK, Abdul Karim MN, Prydal JI, Maharajan SV, Fares U. Oral antivirals for preventing recurrent herpes simplex keratitis in people with corneal grafts. *Cochrane Database of Systematic Reviews* 2016, Issue 11. Art. No.: CD007824. DOI: 10.1002/14651858.CD007824.pub2.

Copyright © 2016 The Cochrane Collaboration. Published by John Wiley & Sons, Ltd.

ABSTRACT

Background

Ocular herpes is a viral infection of the eye caused by the herpes simplex virus (HSV), a double-stranded DNA virus. Corneal scarring caused by herpes simplex keratitis (HSK) is the leading infectious cause of penetrating corneal graft in high-income countries. Acyclovir is an antiviral drug known to have a protective effect against recurrences in herpetic eye disease. While there are some studies which have evaluated the effects of intervention with oral antiviral in preventing such recurrences in people with corneal grafts, a systematic review of all comparative clinical trials has not been previously undertaken.

Objectives

To assess the efficacy of oral antivirals such as acyclovir in any dosage when taken for six months or more, in preventing recurrence of herpetic keratitis in people having corneal graft surgery for herpetic keratitis.

Search methods

We searched CENTRAL (which contains the Cochrane Eyes and Vision Trials Register) (2016, Issue 5), Ovid MEDLINE, Ovid MEDLINE In-Process and Other Non-Indexed Citations, Ovid MEDLINE Daily, Ovid OLDMEDLINE (January 1946 to June 2016), Embase (January 1980 to June 2016), the ISRCTN registry (www.isrctn.com/editAdvancedSearch), ClinicalTrials.gov (www.clinicaltrials.gov), and the World Health Organization (WHO) International Clinical Trials Registry Platform (ICTRP) (www.who.int/ictrp/search/en). We did not use any date or language restrictions in the electronic searches for trials. We last searched the electronic databases on 1 June 2016. We handsearched conference proceedings and contacted authors of the included studies and researchers active in the field.

Selection criteria

We included randomised controlled trials (RCTs). People enrolled in these trials had corneal grafts for HSK. The intervention was oral antivirals for six months or more following the corneal graft surgery, and this was compared to no treatment or placebo.

Data collection and analysis

Two review authors independently assessed trial quality and extracted data. We contacted trial investigators for any clarification or missing information. We graded the certainty of the evidence using GRADE.

Copyright © 2016 The Cochrane Collaboration. Published by John Wiley & Sons, Ltd.

[Intervention Review]

Orbital radiotherapy for adult thyroid eye disease

Rathie Rajendram[1], Catey Bunce[2], Richard WJ Lee[3,4], Ana MS Morley[5]

[1]Adnexal Department, Moorfields Eye Hospital NHS Foundation Trust, London, UK. [2]Research and Development Department, Moorfields Eye Hospital NHS Foundation Trust, London, UK. [3]School of Clinical Sciences, University of Bristol, Bristol, UK. [4]NIHR Biomedical Research Centre for Ophthalmology, Moorfields Eye Hospital Foundation Trust and University College London Institute of Ophthalmology, London, UK. [5]St. Thomas's Hospital, London, UK

Contact address: Rathie Rajendram, Adnexal Department, Moorfields Eye Hospital NHS Foundation Trust, 162 City Road, London, EC1V 2PD, UK. rathie.rajendram@moorfields.nhs.uk, rathierajendram@hotmail.com.

Editorial group: Cochrane Eyes and Vision Group.
Publication status and date: New, published in Issue 7, 2012.

Citation: Rajendram R, Bunce C, Lee RWJ, Morley AMS. Orbital radiotherapy for adult thyroid eye disease. *Cochrane Database of Systematic Reviews* 2012, Issue 7. Art. No.: CD007114. DOI: 10.1002/14651858.CD007114.pub2.

Copyright © 2012 The Cochrane Collaboration. Published by John Wiley & Sons, Ltd.

ABSTRACT

Background

Thyroid eye disease is an autoimmune inflammatory condition of the orbital and periorbital tissues. Orbital radiotherapy is an anti-inflammatory treatment used in the treatment of active thyroid eye disease. It is administered as an outpatient procedure in 10 to 12 fractionated doses.

Objectives

To assess the effectiveness and adverse events of orbital radiotherapy in thyroid eye disease. The effectiveness was dependent on the level of 'success' of the intervention predefined in each randomised controlled trial (RCT).

Search methods

We searched CENTRAL (which contains the Cochrane Eyes and Vision Group Trials Register) (*The Cochrane Library* 2012, Issue 2), MEDLINE (January 1950 to March 2012), EMBASE (January 1980 to March 2012), Latin American and Caribbean Literature on Health Sciences (LILACS) (January 1982 to March 2012), the *meta*Register of Controlled Trials (*m*RCT) (www.controlled-trials.com), ClinicalTrials.gov (www.clinicaltrials.gov) and the WHO International Clinical Trials Registry Platform (ICTRP) (www.who.int/ictrp/search/en). We did not restrict the electronic searches for trials by date or language. We last searched the electronic databases on 12 March 2012. We screened reference lists of reports of included studies, other reviews and book chapters to find additional trials. We contacted trial investigators and experts in the field to identify additionally published studies.

Selection criteria

We included RCTs of orbital radiotherapy versus sham radiotherapy or other interventions enrolling adults, with a minimum of three months' follow-up and an endpoint of two years or less post treatment.

Data collection and analysis

Two review authors independently assessed trial quality and extracted data. Trial authors were contacted for missing data. The risk ratio was used for our primary outcome. For our secondary outcomes, the odds ratio and mean difference were reported where possible.

[Intervention Review]

Photodynamic therapy for neovascular age-related macular degeneration

Richard Wormald[1], Jennifer R Evans[1], Liam L Smeeth[2], Katherine S Henshaw[3]

[1]Cochrane Eyes and Vision Group, ICEH, London School of Hygiene & Tropical Medicine, London, UK. [2]Department of Epidemiology, London School of Hygiene & Tropical Medicine, London, UK. [3]c/o Cochrane Eyes and Vision Group, ICEH, London School of Hygiene & Tropical Medicine, London, UK

Contact address: Richard Wormald, Cochrane Eyes and Vision Group, ICEH, London School of Hygiene & Tropical Medicine, Keppel Street, London, WC1E 7HT, UK. r.wormald@ucl.ac.uk.

Editorial group: Cochrane Eyes and Vision Group.
Publication status and date: New search for studies and content updated (no change to conclusions), published in Issue 4, 2009.

Citation: Wormald R, Evans JR, Smeeth LL, Henshaw KS. Photodynamic therapy for neovascular age-related macular degeneration. *Cochrane Database of Systematic Reviews* 2007, Issue 3. Art. No.: CD002030. DOI: 10.1002/14651858.CD002030.pub3.

Copyright © 2009 The Cochrane Collaboration. Published by John Wiley & Sons, Ltd.

ABSTRACT

Background

In neovascular age-related macular degeneration (AMD) new vessels grow under the retina distorting vision and leading to scarring. This is exacerbated if the blood vessels leak. Photodynamic therapy (PDT) has been investigated as a way to treat the neovascular membranes without affecting the retina.

Objectives

The aim of this review was to examine the effects of PDT in the treatment of neovascular AMD.

Search methods

We searched CENTRAL (Issue 2, 2009), MEDLINE (1966 to April 2009) and EMBASE (1980 to April 2009). We contacted experts in the field and searched the reference lists of relevant studies.

Selection criteria

We included randomised trials of PDT in people with choroidal neovascularisation due to AMD.

Data collection and analysis

Two authors independently extracted the data. Risk ratios were combined using a random-effects model after testing for heterogeneity.

Main results

Four trials (1429 participants) comparing PDT with verteporfin to PDT with 5% dextrose in water were included in this review. Participants received on average five treatments over two years. The risk ratio of losing 3 or more lines of visual acuity at 24 months comparing the intervention with the control group was 0.80 (95% confidence interval (CI) 0.73 to 0.88). The risk ratio of losing 6 or more lines of visual acuity at 24 months comparing the intervention with the control group was 0.66 (95% CI 0.56 to 0.83). The results at 12 months were similar to those at 24 months. The most serious adverse outcome, severe visual acuity decrease within one week of treatment, occurred in 11 per 1000 patients (95% CI 3 to 48). Infusion related back pain was experienced by 20 per 1000 (95% CI 6 to 70). Two further trials compared different treatment regimens: standard versus delayed light application; retreatment every two months versus every three months. Neither trial demonstrated differences in effectiveness. The overall quality of the evidence included in this review was considered to be high. Five out of the six trials were funded by the manufacturers of verteporfin.

Copyright © 2009 The Cochrane Collaboration. Published by John Wiley & Sons, Ltd.

[Intervention Review]

Interventions for recurrent corneal erosions

Stephanie L Watson[1], Vannessa Leung[2,3,4]

[1]Save Sight Institute, Sydney, Australia. [2]Sydney Eye Hospital, Sydney, Australia. [3]The University of Sydney, Sydney, Australia. [4]The University of New South Wales, Sydney, Australia

Contact address: Stephanie L Watson, Save Sight Institute, University of Sydney, Sydney, NSW, Australia. stephanie.watson@sydney.edu.au.

Editorial group: Cochrane Eyes and Vision Group.
Publication status and date: New search for studies and content updated (no change to conclusions), published in Issue 7, 2018.

Citation: Watson SL, Leung V. Interventions for recurrent corneal erosions. *Cochrane Database of Systematic Reviews* 2018, Issue 7. Art. No.: CD001861. DOI: 10.1002/14651858.CD001861.pub4.

Copyright © 2018 The Cochrane Collaboration. Published by John Wiley & Sons, Ltd.

ABSTRACT

Background

Recurrent corneal erosion is a common cause of disabling ocular symptoms and predisposes the cornea to infection. It may follow corneal trauma. Measures to prevent the development of recurrent corneal erosion following corneal trauma have not been firmly established. Once recurrent corneal erosion develops, simple medical therapy (standard treatment) may lead to resolution of the episode. However, some people continue to suffer when such therapy fails and repeated episodes of erosion develop. A number of treatment and prophylactic options are then available but there is no agreement as to the best option. This review version is an update to the original version published in 2007 and a previous update published in 2012.

Objectives

To assess the effectiveness and adverse effects of regimens for the prophylaxis of further recurrent corneal erosion episodes, the treatment of recurrent corneal erosion and prophylaxis of the development of recurrent corneal erosion following trauma.

Search methods

We searched CENTRAL, which contains the Cochrane Eyes and Vision Trials Register; MEDLINE; Embase; LILACS; the ISRCTN registry; ClinicalTrials.gov and the ICTRP. The date of the search was 14 December 2017.

Selection criteria

We included randomised and quasi-randomised trials that compared a prophylactic or treatment regimen with another prophylaxis/treatment or no prophylaxis/treatment for people with recurrent corneal erosion.

Data collection and analysis

We used standard methods expected by Cochrane. Two authors independently screened search results, extracted data and assessed risk of bias in the included studies using the Cochrane tool for assessing risk of bias. We considered the following outcome measures: resolution of symptoms after treatment; recurrence after complete or partial resolution; symptoms (pain); adverse effects (corneal haze, astigmatism). We graded the certainty of the evidence using GRADE for the three most clinically relevant comparisons.

Copyright © 2018 The Cochrane Collaboration. Published by John Wiley & Sons, Ltd.

[Intervention Review]

Prophylactic non-steroidal anti-inflammatory drugs for the prevention of macular oedema after cataract surgery

Blanche X Lim[1a], Chris HL Lim[2b], Dawn K Lim[1c], Jennifer R Evans[3], Catey Bunce[4], Richard Wormald[3,5]

[1]Department of Ophthalmology, National University Health System, Singapore, Singapore. [2]Department of Ophthalmology, Royal Melbourne Hospital, Melbourne, Australia. [3]Cochrane Eyes and Vision, ICEH, London School of Hygiene & Tropical Medicine, London, UK. [4]Department of Primary Care & Public Health Sciences, Kings College London, London, UK. [5]Research and Development Department, NIHR Biomedical Research Centre at Moorfields Eye Hospital NHS Foundation Trust and UCL Institute of Ophthalmology, London, UK

[a]Joint first author. [b]Joint first author. [c]Joint first author

Contact address: Richard Wormald, Cochrane Eyes and Vision, ICEH, London School of Hygiene & Tropical Medicine, Keppel Street, London, WC1E 7HT, UK. r.wormald@ucl.ac.uk.

Editorial group: Cochrane Eyes and Vision Group.
Publication status and date: New, published in Issue 11, 2016.

Citation: Lim BX, Lim CHL, Lim DK, Evans JR, Bunce C, Wormald R. Prophylactic non-steroidal anti-inflammatory drugs for the prevention of macular oedema after cataract surgery. *Cochrane Database of Systematic Reviews* 2016, Issue 11. Art. No.: CD006683. DOI: 10.1002/14651858.CD006683.pub3.

Copyright © 2016 The Cochrane Collaboration. Published by John Wiley & Sons, Ltd.

ABSTRACT

Background

Macular oedema (MO) is the accumulation of extracellular fluid in the central retina (the macula). It may occur after cataract surgery and may give rise to poor visual outcome, with reduced visual acuity and distortion of the central vision. MO is often self-limiting with spontaneous resolution, but a small proportion of people with chronic persistent MO may be difficult to treat. Chronic oedema may lead to the formation of cystic spaces in the retina termed 'cystoid macular oedema' (CMO). Non-steroidal anti-inflammatory drugs (NSAIDs) are commonly used in cataract surgery and may reduce the chances of developing MO.

Objectives

The aim of this review is to answer the question: is there evidence to support the prophylactic use of topical NSAIDs either in addition to, or instead of, topical steroids postoperatively to reduce the incidence of macular oedema (MO) and associated visual morbidity.

Search methods

We searched a number of electronic databases including CENTRAL, MEDLINE and Embase. Date last searched 2 September 2016.

Selection criteria

We included randomised controlled trials (RCTs) in which adult participants had undergone surgery for age-related cataract. We included participants irrespective of their baseline risk of MO, in particular we included people with diabetes and uveitis. We included trials of preoperative and/or postoperative topical NSAIDs in conjunction with postoperative topical steroids. The comparator was postoperative topical steroids alone. A secondary comparison was preoperative and/or postoperative topical NSAIDs alone versus postoperative topical steroids alone.

Copyright © 2016 The Cochrane Collaboration. Published by John Wiley & Sons, Ltd.

[Intervention Review]

Sublingual immunotherapy for treating allergic conjunctivitis

Moises A Calderon[1], Martin Penagos[1], Aziz Sheikh[2], Giorgio W Canonica[3], Stephen Durham[1]

[1]Department of Allergy and Respiratory Medicine, Royal Brompton Hospital, London, UK. [2]Centre for Population Health Sciences, University of Edinburgh, Edinburgh, UK. [3]Allergy and Respiratory Diseases Clinic, Department of Internal Medicine (DIMI), University of Genoa, Genoa, Italy

Contact address: Moises A Calderon, Department of Allergy and Respiratory Medicine, Royal Brompton Hospital, Imperial College School of Medicine at the National Heart and Lung Institute, London, SW3 6LY, UK. m.calderon@imperial.ac.uk.

Editorial group: Cochrane Eyes and Vision Group.
Publication status and date: New, published in Issue 7, 2011.
Review content assessed as up-to-date: 18 January 2011.

Citation: Calderon MA, Penagos M, Sheikh A, Canonica GW, Durham S. Sublingual immunotherapy for treating allergic conjunctivitis. *Cochrane Database of Systematic Reviews* 2011, Issue 7. Art. No.: CD007685. DOI: 10.1002/14651858.CD007685.pub2.

Copyright © 2011 The Cochrane Collaboration. Published by John Wiley & Sons, Ltd.

ABSTRACT

Background

Allergic ocular symptoms, although frequently trivialised, are common and represent an important comorbidity of allergic rhinitis. Sublingual Immunotherapy (SLIT) is an effective and well-tolerated treatment for allergic rhinitis, but its effects on symptoms of ocular allergy have not been well established.

Objectives

To evaluate the efficacy of SLIT compared with placebo for reductions in ocular symptoms, topical ocular medication requirements and conjunctival immediate allergen sensitivity.

Search methods

We searched CENTRAL (which contains the Cochrane Eyes and Vision Group Trials Register) (*The Cochrane Library* 2011, Issue 1), MEDLINE (January 1950 to January 2011), EMBASE (January 1980 to January 2011), Latin American and Caribbean Literature on Health Sciences (LILACS) (January 1982 to January 2011), Web of Science (January 1970 to January 2011), Biosis Previews, (January 1979 to January 2011), the *meta*Register of Controlled Trials (*m*RCT) (www.controlled-trials.com) (January 2011), ClinicalTrials.gov (www.clinicaltrials.gov) (January 2011), the Australian New Zealand Clinical Trials Registry (ANZCTR) (www.actr.org.au) (July 2010), SCOPUS (November 2008) and the UK Clinical Trials Gateway (January 2010). There were no language or date restrictions in the search for trials. All electronic databases except for SCOPUS, the UK Clinical Trials Gateway and ANZCTR were last searched on 19 January 2011.

Selection criteria

Randomised controlled trials (RCTs), double-masked and placebo controlled, which evaluated the efficacy of SLIT in patients with symptoms of allergic rhinoconjunctivitis (ARC) or allergic conjunctivitis (AC).

Data collection and analysis

The primary outcome was the total ocular symptom scores. Secondary endpoints included individual ocular symptom scores (such as itchy eyes, red eyes, watery eyes, swollen eyes), ocular medication scores (eye drops) and conjunctival immediate allergen sensitivity (CIAS). Data were analysed and reported as standardised mean differences (SMDs) using Review Manager software.

Copyright © 2011 The Cochrane Collaboration. Published by John Wiley & Sons, Ltd.

[Intervention Review]

Surgical interventions for age-related cataract

Yasmin Riaz[1], Jod S Mehta[2], Richard Wormald[3], Jennifer R Evans[3], Allen Foster[4], Thulasiraj Ravilla[5], Torkel Snellingen[6]

[1]Moorfields Eye Hospital, London, UK. [2]c/o Prof D Tan, Singapore National Eye Centre, Singapore, Singapore. [3]Cochrane Eyes and Vision Group, ICEH, London School of Hygiene & Tropical Medicine, London, UK. [4]Department of Infectious and Tropical Diseases, London School of Hygiene and Tropical Medicine, London, UK. [5]Aravind Eye Hospital, Madurai, India. [6]Centre for International Health, Forskningsparken Breivilka, Tromsø, Norway

Contact address: Yasmin Riaz, Moorfields Eye Hospital, City Road, London, EC1V 2PD, UK. yasmin.riaz@gmail.com.

Editorial group: Cochrane Eyes and Vision Group.
Publication status and date: Edited (no change to conclusions), published in Issue 1, 2009.

Citation: Riaz Y, Mehta JS, Wormald R, Evans JR, Foster A, Ravilla T, Snellingen T. Surgical interventions for age-related cataract. *Cochrane Database of Systematic Reviews* 2006, Issue 4. Art. No.: CD001323. DOI: 10.1002/14651858.CD001323.pub2.

Copyright © 2009 The Cochrane Collaboration. Published by John Wiley & Sons, Ltd.

ABSTRACT

Background

Cataract accounts for 50% of blindness globally and remains the leading cause of visual impairment in all regions of the world, despite improvements in surgical outcomes (WHO 2005). This number is expected to rise due to an aging population and increase in life expectancy. Although cataracts are not preventable, their surgical treatment is one of the most cost-effective interventions in healthcare.

Objectives

To compare the effects of different surgical interventions for age-related cataract.

Search methods

We searched CENTRAL, MEDLINE, EMBASE up to July 2006, NRR Issue 3 2005, the reference lists of identified trials and we contacted investigators and experts in the field for details of published and unpublished trials.

Selection criteria

We included randomised controlled trials (RCTS).

Data collection and analysis

Two review authors independently extracted data and discrepancies were resolved by discussion. Where appropriate, risk ratios, odds ratios and weighted mean differences were summarised after assessing heterogeneity between the studies.

Main results

We identified 17 trials that randomised a total of 9627 people. Phacoemulsification gave a better visual outcome than extracapsular surgery but similar average cost per procedure in Europe but not in poorer countries. Extracapsular surgery with posterior chamber lens implant and ICCE with or without an anterior chamber intraocular lens (IOL) implant gave acceptable visual outcomes but extracapsular surgery had less complications. Manual small incision surgery provides better visual outcome than ECCE but slightly inferior unaided visual acuity compared to phacoemulsification.

Copyright © 2009 The Cochrane Collaboration. Published by John Wiley & Sons, Ltd.

[Intervention Review]

Systemic safety of bevacizumab versus ranibizumab for neovascular age-related macular degeneration

Lorenzo Moja[1], Ersilia Lucenteforte[2], Koren H Kwag[3], Vittorio Bertele[4], Annalisa Campomori[5], Usha Chakravarthy[6], Roberto D'Amico[7], Kay Dickersin[8], Laurent Kodjikian[9], Kristina Lindsley[10], Yoon Loke[11], Maureen Maguire[12], Daniel F Martin[13], Alessandro Mugelli[14], Bernd Mühlbauer[15], Isabel Püntmann[15], Barnaby Reeves[16], Chris Rogers[16], Christine Schmucker[17], Manju L Subramanian [18], Gianni Virgili[19]

[1]Department of Biomedical Sciences for Health, University of Milan - IRCCS Galeazzi Orthopaedic Institute, Milan, Italy. [2]Department of Neurosciences, Psychology, Drug Research and Children's Health, University of Florence, Florence, Italy. [3]Clinical Epidemiology Unit, IRCCS Galeazzi Orthopaedic Institute, Milan, Italy. [4]Laboratory of Regulatory Policies, IRCCS Mario Negri Institute for Pharmacological Research, Milan, Italy. [5]Hospital Pharmacy, Trento General Hospital, Health Trust of the Autonomous Province of Trento, Trento, Italy. [6]Centre for Vision and Vascular Science, Queen's University Belfast, Belfast, UK. [7]Italian Cochrane Centre, Department of Diagnostic, Clinical and Public Health Medicine, University of Modena and Reggio Emilia, Modena, Italy. [8]Center for Clinical Trials and US Cochrane Center, Johns Hopkins University, Baltimore, MD, USA. [9]Department of Ophthalmology, Hôpital de la Croix-Rousse, Lyon, France. [10]Department of Epidemiology, Johns Hopkins Bloomberg School of Public Health, Baltimore, Maryland, USA. [11]School of Medicine, University of East Anglia, Norwich, UK. [12]Department of Ophthalmology, University of Pennsylvania, Philadelphia, Pennsylvania, USA. [13]Cole Eye Institute, Cleveland Clinic, Cleveland, Ohio, USA. [14]Department of Neurosciences, Psychology, Drug Research and Child Health, University of Florence, Florence, Italy. [15]Dept of Pharmacology, Klinikum Bremen Mitte gGmbH, Bremen, Germany. [16]School of Clinical Sciences, University of Bristol, Bristol, UK. [17]German Cochrane Centre, Institute of Medical Biometry and Medical Informatics, University Medical Center Freiburg, Freiburg, Germany. [18]Department of Ophthalmology, Boston University, School of Medicine, Boston, Massachusetts, USA. [19]Department of Translational Surgery and Medicine, Eye Clinic, University of Florence, Florence, Italy

Contact address: Lorenzo Moja, Department of Biomedical Sciences for Health, University of Milan - IRCCS Galeazzi Orthopaedic Institute, Via Pascal 36, Milan, 20133, Italy. lorenzo.moja@unimi.it.

Editorial group: Cochrane Eyes and Vision Group.
Publication status and date: New, published in Issue 9, 2014.
Review content assessed as up-to-date: 27 March 2014.

Citation: Moja L, Lucenteforte E, Kwag KH, Bertele V, Campomori A, Chakravarthy U, D'Amico R, Dickersin K, Kodjikian L, Lindsley K, Loke Y, Maguire M, Martin DF, Mugelli A, Mühlbauer B, Püntmann I, Reeves B, Rogers C, Schmucker C, Subramanian ML, Virgili G. Systemic safety of bevacizumab versus ranibizumab for neovascular age-related macular degeneration. *Cochrane Database of Systematic Reviews* 2014, Issue 9. Art. No.: CD011230. DOI: 10.1002/14651858.CD011230.pub2.

Copyright © 2014 The Cochrane Collaboration. Published by John Wiley & Sons, Ltd.

ABSTRACT

Background

Neovascular age-related macular degeneration (AMD) is the leading cause of legal blindness in elderly populations of industrialised countries. Bevacizumab (Avastin®) and ranibizumab (Lucentis®) are targeted biological drugs (a monoclonal antibody) that inhibit vascular endothelial growth factor, an angiogenic cytokine that promotes vascular leakage and growth, thereby preventing its pathological angiogenesis. Ranibizumab is approved for intravitreal use to treat neovascular AMD, while bevacizumab is approved for intravenous use as a cancer therapy. However, due to the biological similarity of the two drugs, bevacizumab is widely used off-label to treat neovascular AMD.

Copyright © 2014 The Cochrane Collaboration. Published by John Wiley & Sons, Ltd.

[Intervention Review]

Tamponade in surgery for retinal detachment associated with proliferative vitreoretinopathy

Stephen G Schwartz[1], Harry W Flynn Jr[1], Wen-Hsiang Lee[1], Xue Wang[2]

[1]Bascom Palmer Eye Institute, University of Miami Miller School of Medicine, Miami, Florida, USA. [2]Department of Epidemiology, Johns Hopkins Bloomberg School of Public Health, Baltimore, Maryland, USA

Contact address: Stephen G Schwartz, Bascom Palmer Eye Institute, University of Miami Miller School of Medicine, Miami, Florida, USA. sschwartz2@med.miami.edu.

Editorial group: Cochrane Eyes and Vision Group.
Publication status and date: New search for studies and content updated (no change to conclusions), published in Issue 2, 2014.

Citation: Schwartz SG, Flynn Jr HW, Lee WH, Wang X. Tamponade in surgery for retinal detachment associated with proliferative vitreoretinopathy. *Cochrane Database of Systematic Reviews* 2014, Issue 2. Art. No.: CD006126. DOI: 10.1002/14651858.CD006126.pub3.

Copyright © 2014 The Cochrane Collaboration. Published by John Wiley & Sons, Ltd.

ABSTRACT

Background

Retinal detachment (RD) with proliferative vitreoretinopathy (PVR) often requires surgery to restore normal anatomy and to stabilize or improve vision. PVR usually occurs in association with recurrent RD (that is, after initial retinal re-attachment surgery) but occasionally may be associated with primary RD. Either way, a tamponade agent (gas or silicone oil) is needed during surgery to reduce the rate of postoperative recurrent RD.

Objectives

The objective of this review was to assess the relative safety and effectiveness of various tamponade agents used with surgery for retinal detachment (RD) complicated by proliferative vitreoretinopathy (PVR).

Search methods

We searched CENTRAL (which contains the Cochrane Eyes and Vision Group Trials Register) (*The Cochrane Library* 2013, Issue 5), Ovid MEDLINE, Ovid MEDLINE In-Process and Other Non-Indexed Citations, Ovid MEDLINE Daily, Ovid OLDMEDLINE (January 1946 to June 2013), EMBASE (January 1980 to June 2013), Latin American and Caribbean Literature on Health Sciences (LILACS) (January 1982 to June 2013), the *meta*Register of Controlled Trials (*m*RCT) (www.controlled-trials.com), ClinicalTrials.gov (www.clinicaltrials.gov) and the WHO International Clinical Trials Registry Platform (ICTRP) (www.who.int/ictrp/search/en). We did not use any date or language restrictions in the electronic searches for trials. We last searched the electronic databases on 26 June 2013.

Selection criteria

We included randomized controlled trials (RCTs) of participants undergoing surgery for RD associated with PVR that compared various tamponade agents.

Data collection and analysis

Two review authors screened the search results independently. We used the standard methodological procedures expected by The Cochrane Collaboration.

Copyright © 2014 The Cochrane Collaboration. Published by John Wiley & Sons, Ltd.

[Intervention Review]

Thyroid surgery for Graves' disease and Graves' ophthalmopathy

Zi Wei Liu[1], Liam Masterson[2], Brian Fish[2], Piyush Jani[2], Krishna Chatterjee[3]

[1]ENT Department, Whipps Cross University Hospital, London, UK. [2]ENT Department, Cambridge University Hospitals NHS Foundation Trust, Cambridge, UK. [3]Department of Endocrinology, Cambridge University Hospitals NHS Foundation Trust, Cambridge, UK

Contact address: Zi Wei Liu, ENT Department, Whipps Cross University Hospital, Leytonstone, London, E11 1NR, UK. zwl20cam@gmail.com, ziweiliu@doctors.org.uk.

Editorial group: Cochrane Metabolic and Endocrine Disorders Group.
Publication status and date: New, published in Issue 11, 2015.

Citation: Liu ZW, Masterson L, Fish B, Jani P, Chatterjee K. Thyroid surgery for Graves' disease and Graves' ophthalmopathy. *Cochrane Database of Systematic Reviews* 2015, Issue 11. Art. No.: CD010576. DOI: 10.1002/14651858.CD010576.pub2.

Copyright © 2015 The Cochrane Collaboration. Published by John Wiley & Sons, Ltd.

ABSTRACT

Background

Graves' disease is an autoimmune disease caused by the production of auto-antibodies against the thyroid-stimulating hormone receptor, which stimulates follicular cell production of thyroid hormone. It is the commonest cause of hyperthyroidism and may cause considerable morbidity with increased risk of cardiovascular and respiratory adverse events. Five per cent of people with Graves' disease develop moderate to severe Graves' ophthalmopathy. Thyroid surgery for Graves' disease commonly falls into one of three categories: 1) total thyroidectomy, which aims to achieve complete macroscopic removal of thyroid tissue; 2) bilateral subtotal thyroidectomy, in which bilateral thyroid remnants are left; and 3) unilateral total and contralateral subtotal thyroidectomy, or the Dunhill procedure. Recent American Thyroid Association guidelines on treatment of Graves' hyperthyroidism emphasised the role of surgery as one of the first-line treatments. Total thyroidectomy removes target tissue for the thyroid-stimulating hormone receptor antibody. It controls hyperthyroidism at the cost of lifelong thyroxine replacement. Subtotal thyroidectomy leaves a thyroid remnant and may be less likely to lead to complications, however a higher rate of recurrent hyperthyroidism is expected and revision surgery would be challenging. The choice of the thyroidectomy technique is currently largely a matter of surgeon preference, and a systematic review of the evidence base is required to determine which option offers the best outcomes for patients.

Objectives

To assess the optimal surgical technique for Graves' disease and Graves' ophthalmopathy.

Search methods

We searched the Cochrane Library, MEDLINE and PubMed, EMBASE, ClinicalTrials.gov, and the World Health Organization (WHO) International Clinical Trials Registry Platform (ICTRP). The date of the last search was June 2015 for all databases. We did not apply any language restrictions.

Selection criteria

Only randomised controlled trials (RCTs) involving participants with a diagnosis of Graves' disease based on clinical features and biochemical findings of hyperthyroidism were eligible for inclusion. Trials had to directly compare at least two surgical techniques of thyroidectomy. There was no age limit to study inclusion.

Copyright © 2015 The Cochrane Collaboration. Published by John Wiley & Sons, Ltd.

[Intervention Review]

Conjunctival autograft for pterygium

Elizabeth Clearfield[1], Valliammai Muthappan[2], Xue Wang[1], Irene C Kuo[2]

[1]Department of Epidemiology, Johns Hopkins Bloomberg School of Public Health, Baltimore, Maryland, USA. [2]Department of Ophthalmology, Wilmer Eye Institute, Johns Hopkins University School of Medicine, Baltimore, Maryland, USA

Contact address: Irene C Kuo, Department of Ophthalmology, Wilmer Eye Institute, Johns Hopkins University School of Medicine, 600 North Wolfe Street, Baltimore, Maryland, 21287, USA. ickuo@jhmi.edu.

Editorial group: Cochrane Eyes and Vision Group.
Publication status and date: New, published in Issue 2, 2016.

Citation: Clearfield E, Muthappan V, Wang X, Kuo IC. Conjunctival autograft for pterygium. *Cochrane Database of Systematic Reviews* 2016, Issue 2. Art. No.: CD011349. DOI: 10.1002/14651858.CD011349.pub2.

Copyright © 2016 The Cochrane Collaboration. Published by John Wiley & Sons, Ltd.

ABSTRACT

Background

A pterygium is a fleshy, wing-shaped growth from the conjunctiva, crossing over the limbus onto the cornea. Prevalence ranges widely around the world. Evidence suggests that ultraviolet light is a major contributor in the formation of pterygia. Pterygia impair vision, limit eye movements, and can cause eye irritation, foreign body sensation, and dryness. In some susceptible patients, the pterygium can grow over the entire corneal surface, blocking the visual axis.

Surgery is the only effective treatment for pterygium, though recurrences are common. With simple excision techniques (that is, excising the pterygium and leaving bare sclera), the risk of recurrence has been reported to be upwards of 80%. Pterygium excision combined with a tissue graft has a lower risk of recurrence. In conjunctival autograft surgery, conjunctival tissue from another part of the person's eye along with limbal tissue is resected in one piece and used to cover the area from which the pterygium was excised. Another type of tissue graft surgery for pterygium is amniotic membrane graft, whereby a piece of donor amniotic membrane is fixed to the remaining limbus and bare sclera area after the pterygium has been excised.

Objectives

The objective of this review was to assess the safety and effectiveness of conjunctival autograft (with or without adjunctive therapy) compared with amniotic membrane graft (with or without adjunctive therapy) for pterygium. We also planned to determine whether use of MMC yielded better surgical results and to assess the direct and indirect comparative costs of these procedures.

Search methods

We searched CENTRAL (which contains the Cochrane Eyes and Vision Trials Register) (Issue 10, 2015), Ovid MEDLINE, Ovid MEDLINE In-Process and Other Non-Indexed Citations, Ovid MEDLINE Daily, Ovid OLDMEDLINE (January 1946 to November 2015), EMBASE (January 1980 to November 2015), PubMed (1948 to November 2015), Latin American and Caribbean Health Sciences Literature Database (LILACS) (1982 to November 2015), the *meta*Register of Controlled Trials (*m*RCT) (www.controlled-trials.com) (last searched 21 November 2014), ClinicalTrials.gov (www.clinicaltrials.gov) and the World Health Organization (WHO) International Clinical Trials Registry Platform (ICTRP) (www.who.int/ ictrp/search/en). We did not use any date or language restrictions in the electronic search for trials. We last searched the electronic databases on 23 November 2015.

Selection criteria

We included in this review randomized controlled trials that had compared conjunctival autograft surgery (with or without adjunctive therapy) with amniotic membrane graft surgery (with or without adjunctive therapy) in people with primary or recurrent pterygium.

Copyright © 2016 The Cochrane Collaboration. Published by John Wiley & Sons, Ltd.

[Intervention Review]

Topical antihistamines and mast cell stabilisers for treating seasonal and perennial allergic conjunctivitis

Mayret Castillo[1], Neil W Scott[2], Mohammad Z Mustafa[3], Mohammed S Mustafa[4], Augusto Azuara-Blanco[5]

[1]Queen's University Belfast, Belfast, UK. [2]Medical Statistics Team, University of Aberdeen, Aberdeen, UK. [3]Princess Alexandra Eye Pavilion, Edinburgh, UK. [4]Moorfields Eye Hospital Dubai, Dubai, United Arab Emirates. [5]Centre for Experimental Medicine, Queen's University Belfast, Belfast, UK

Contact address: Augusto Azuara-Blanco, Centre for Experimental Medicine, Queen's University Belfast, Grosvenor Road, Belfast, BT12 6BA, UK. aazblanco@aol.com. a.azuara-blanco@qub.ac.uk.

Editorial group: Cochrane Eyes and Vision Group.
Publication status and date: New, published in Issue 6, 2015.
Review content assessed as up-to-date: 17 July 2014.

Citation: Castillo M, Scott NW, Mustafa MZ, Mustafa MS, Azuara-Blanco A. Topical antihistamines and mast cell stabilisers for treating seasonal and perennial allergic conjunctivitis. *Cochrane Database of Systematic Reviews* 2015, Issue 6. Art. No.: CD009566. DOI: 10.1002/14651858.CD009566.pub2.

Copyright © 2015 The Cochrane Collaboration. Published by John Wiley & Sons, Ltd.

ABSTRACT

Background

Seasonal/perennial allergic conjunctivitis is the most common allergic conjunctivitis, usually with acute manifestations when a person is exposed to allergens and with typical signs and symptoms including itching, redness, and tearing. The clinical signs and symptoms of allergic conjunctivitis are mediated by the release of histamine by mast cells. Histamine antagonists (also called antihistamines) inhibit the action of histamine by blocking histamine H1 receptors, antagonising the vasoconstrictor, and to a lesser extent, the vasodilator effects of histamine. Mast cell stabilisers inhibit degranulation and consequently the release of histamine by interrupting the normal chain of intracellular signals.

Topical treatments include eye drops with antihistamines, mast cell stabilisers, non-steroidal anti-inflammatory drugs, combinations of the previous treatments, and corticosteroids. Standard treatment is based on topical antihistamines alone or topical mast cell stabilisers alone or a combination of treatments. There is clinical uncertainty about the relative efficacy and safety of topical treatment.

Objectives

The objective of this review was to assess the effects of topical antihistamines and mast cell stabilisers, alone or in combination, for use in treating seasonal and perennial allergic conjunctivitis.

Search methods

We searched CENTRAL (which contains the Cochrane Eyes and Vision Trials Register) (2014, Issue 7), Ovid MEDLINE, Ovid MEDLINE In-Process and Other Non-Indexed Citations, Ovid MEDLINE Daily, Ovid OLDMEDLINE (January 1946 to July 2014), EMBASE (January 1980 to July 2014), the *meta*Register of Controlled Trials (*m*RCT) (www.controlled-trials.com), ClinicalTrials.gov (www.clinicaltrials.gov) and the World Health Organization (WHO) International Clinical Trials Registry Platform (ICTRP) (www.who.int/ictrp/search/en). We did not use any date or language restrictions in the electronic searches for trials. We last searched the electronic databases on 17 July 2014. We also searched the reference lists of review articles and relevant trial reports for details of further relevant publications.

[Intervention Review]

Topical non-steroidal anti-inflammatory drugs for analgesia in traumatic corneal abrasions

Abel Wakai[1], John G Lawrenson[2], Annali L Lawrenson[3], Yongjun Wang[4], Michael D Brown[5], Michael Quirke[1], Omar Ghandour[6], Ryan McCormick[6], Cathal D Walsh[7], Ahmed Amayem[8], Eddy Lang[9], Nick Harrison[10]

[1]Emergency Care Research Unit (ECRU), Division of Population Health Sciences (PHS), Royal College of Surgeons in Ireland (RCSI), Dublin 2, Ireland. [2]Applied Vision Research Centre, School of Health Sciences, City University of London, London, UK. [3]Emergency Department, Epsom General Hospital, Surrey, UK. [4]Schulich School of Medicine & Dentistry, Western University, London, Canada. [5]Department of Emergency Medicine, Michigan State University College of Human Medicine, Grand Rapids, MI, USA. [6]School of Medicine, Royal College of Surgeons in Ireland (RCSI), Dublin 2, Ireland. [7]Health Research Institute (HRI) and MACSI, Department of Mathematics and Statistics, University of Limerick, Ireland. [8]Cumming School of Medicine, University of Calgary, Calgary, Canada. [9]Department of Emergency Medicine, University of Calgary, Calgary, Canada. [10]Beaumont Health Emergency Medicine Residency, Beaumont Hospital, Royal Oak, Michigan, USA

Contact address: Abel Wakai, Emergency Care Research Unit (ECRU), Division of Population Health Sciences (PHS), Royal College of Surgeons in Ireland (RCSI), 123 St. Stephen's Green, Dublin 2, Ireland. awakai@rcsi.ie, abelwakai@beaumont.ie.

Editorial group: Cochrane Eyes and Vision Group.
Publication status and date: New, published in Issue 5, 2017.

Citation: Wakai A, Lawrenson JG, Lawrenson AL, Wang Y, Brown MD, Quirke M, Ghandour O, McCormick R, Walsh CD, Amayem A, Lang E, Harrison N. Topical non-steroidal anti-inflammatory drugs for analgesia in traumatic corneal abrasions. *Cochrane Database of Systematic Reviews* 2017, Issue 5. Art. No.: CD009781. DOI: 10.1002/14651858.CD009781.pub2.

Copyright © 2017 The Cochrane Collaboration. Published by John Wiley & Sons, Ltd.

ABSTRACT

Background

Traumatic corneal abrasions are relatively common and there is a lack of consensus about analgesia in their management. It is therefore important to document the clinical efficacy and safety profile of topical ophthalmic non-steroidal anti-inflammatory drugs (NSAIDs) in the management of traumatic corneal abrasions.

Objectives

To identify and evaluate all randomised controlled trials (RCTs) comparing the use of topical NSAIDs with placebo or any alternative analgesic interventions in adults with traumatic corneal abrasions (including corneal abrasions arising from foreign body removal), to reduce pain, and its effects on healing time.

Search methods

We searched the Cochrane Central Register of Controlled Trials (CENTRAL) (which contains the Cochrane Eyes and Vision Trials Register) (2017, Issue 2), MEDLINE Ovid (1946 to 30 March 2017), Embase Ovid (1947 to 30 March 2017), LILACS (Latin American and Caribbean Health Sciences Literature Database) (1982 to 30 March 2017), OpenGrey (System for Information on Grey Literature in Europe) (www.opengrey.eu/); searched 30 March 2017, ZETOC (1993 to 30 March 2017), the ISRCTN registry (www.isrctn.com/editAdvancedSearch); searched 30 March 2017, ClinicalTrials.gov (www.clinicaltrials.gov); searched 30 March 2017 and the WHO International Clinical Trials Registry Platform (ICTRP) (www.who.int/ictrp/search/en); searched 30 March 2017. We did not use any date or language restrictions in the electronic searches for trials.We checked the reference lists of identified trials to search for further potentially relevant studies.

Copyright © 2017 The Cochrane Collaboration. Published by John Wiley & Sons, Ltd.

[Intervention Review]

Topical cyclosporine for atopic keratoconjunctivitis

Julio J González-López[1,2], Jesús López-Alcalde[3], Rafael Morcillo Laiz[1], Roberto Fernández Buenaga[1], Gema Rebolleda Fernández[1,2]

[1]Department of Ophthalmology, Hospital Ramón y Cajal, Madrid, Spain. [2]Department of Surgery, School of Medicine, Universidad de Alcalá, Madrid, Spain. [3]Health Technology Assessment Unit, Laín Entralgo Agency (Cochrane Collaborating Centre), Madrid, Spain

Contact address: Julio J González-López, Department of Ophthalmology, Hospital Ramón y Cajal, Carretera de Colmenar Viejo, Km 9,100, Madrid, 28034, Spain. juliojose.gonzalez@live.com. juliojose.gonzalez@madrimasd.net.

Editorial group: Cochrane Eyes and Vision Group.
Publication status and date: New, published in Issue 9, 2012.
Review content assessed as up-to-date: 9 July 2012.

Citation: González-López JJ, López-Alcalde J, Morcillo Laiz R, Fernández Buenaga R, Rebolleda Fernández G. Topical cyclosporine for atopic keratoconjunctivitis. *Cochrane Database of Systematic Reviews* 2012, Issue 9. Art. No.: CD009078. DOI: 10.1002/14651858.CD009078.pub2.

Copyright © 2012 The Cochrane Collaboration. Published by John Wiley & Sons, Ltd.

ABSTRACT

Background

Atopic keratoconjunctivitis (AKC) is a chronic ocular surface non-infectious inflammatory condition that atopic dermatitis patients may suffer at any time point in the course of their dermatologic disease and is independent of its degree of severity. AKC is usually not self resolving and it poses a higher risk of corneal injuries and severe sequelae. Management of AKC should prevent or treat corneal damage. Although topical corticosteroids remain the standard treatment for patients with AKC, prolonged use may lead to complications. Topical cyclosporine A (CsA) may improve AKC signs and symptoms, and be used as a corticosteroid sparing agent.

Objectives

To determine the efficacy and gather evidence on safety from randomised controlled trials (RCTs) of topical CsA in patients with AKC.

Search methods

We searched CENTRAL (which contains the Cochrane Eyes and Vision Group Trials Register) (*The Cochrane Library* 2012, Issue 6), MEDLINE (January 1946 to July 2012), EMBASE (January 1980 to July 2012), Latin American and Caribbean Literature on Health Sciences (LILACS) (January 1982 to July 2012), Cumulative Index to Nursing and Allied Health Literature (CINAHL) (January 1937 to July 2012), OpenGrey (System for Information on Grey Literature in Europe) (www.opengrey.eu/), the *meta*Register of Controlled Trials (*m*RCT) (www.controlled-trials.com), ClinicalTrials.gov (www.clinicaltrials.gov), the WHO International Clinical Trials Registry Platform (ICTRP) (www.who.int/ictrp/search/en), the IFPMA Clinical Trials Portal (http://clinicaltrials.ifpma.org/no_cache/en/myportal/index.htm) and Web of Science Conference Proceedings Citation Index- Science (CPCI-S). We did not use any date or language restrictions in the electronic searches for trials. The electronic databases were last searched on 9 July 2012. We also handsearched the following conference proceedings: American Academy of Ophthalmology, Association for Research in Vision and Ophthalmology, International Council of Opthalmology and Societas Ophthalmologica Europaea from 2005 to July 2011.

Selection criteria

We included randomised controlled trials only.

Data collection and analysis

Two review authors independently extracted data. Due to the small number of studies and the diversity of outcome measures, interventions and participants, we presented results narratively.

Copyright © 2012 The Cochrane Collaboration. Published by John Wiley & Sons, Ltd.

[Intervention Review]

Interventions for unilateral and bilateral refractive amblyopia

Kate Taylor[1], Christine Powell[1], Sarah R Hatt[2], Catherine Stewart[3]

[1]Department of Ophthalmology, Royal Victoria Infirmary, Newcastle upon Tyne, UK. [2]Ophthalmology Research, Mayo Clinic, Rochester, Minnesota, USA. [3]Department of Optometry & Visual Science, City University, London, UK

Contact address: Kate Taylor, Department of Ophthalmology, Royal Victoria Infirmary, Claremont Wing, Queen Victoria Road, Newcastle upon Tyne, NE1 4LP, UK. kate.taylor@nuth.nhs.uk.

Editorial group: Cochrane Eyes and Vision Group.
Publication status and date: Edited (no change to conclusions), published in Issue 6, 2012.
Review content assessed as up-to-date: 24 January 2012.

Citation: Taylor K, Powell C, Hatt SR, Stewart C. Interventions for unilateral and bilateral refractive amblyopia. *Cochrane Database of Systematic Reviews* 2012, Issue 4. Art. No.: CD005137. DOI: 10.1002/14651858.CD005137.pub3.

Copyright © 2012 The Cochrane Collaboration. Published by John Wiley & Sons, Ltd.

ABSTRACT

Background

Refractive amblyopia is a common cause of reduced visual acuity in childhood, but optimal treatment is not well defined. This review examined the treatment effect from spectacles and conventional occlusion.

Objectives

Evaluation of the evidence of the effectiveness of spectacles, occlusion or both in the treatment of unilateral and bilateral refractive amblyopia.

Search methods

We searched CENTRAL (which contains the Cochrane Eyes and Vision Group Trials Register) (*The Cochrane Library* 2012, Issue 1), MEDLINE (January 1950 to January 2012), EMBASE (January 1980 to January 2012), Latin American and Caribbean Health Sciences Literature Database (LILACS) (January 1982 to January 2012), the *meta*Register of Controlled Trials (*m*RCT) (www.controlled-trials.com), ClinicalTrials.gov (www.clinicaltrials.gov) and the WHO International Clinical Trials Registry Platform (ICTRP) (www.who.int/ictrp/search/en). There were no date or language restrictions in the electronic searches for trials. We last searched the electronic databases on 24 January 2012. We manually searched relevant conference proceedings.

Selection criteria

Randomised controlled trials of treatment for unilateral and bilateral refractive amblyopia by spectacles, with or without occlusion, were eligible. We included studies with participants of any age.

Data collection and analysis

Two authors independently assessed abstracts identified by the searches. We obtained full-text copies and contacted study authors where necessary. Eleven trials were eligible for inclusion. We extracted data from eight. Insufficient data were present for the remaining three trials so data extraction was not possible. We identified no trials as containing participants with bilateral amblyopia. We performed no meta-analysis as there were insufficient trials for each outcome.

Copyright © 2012 The Cochrane Collaboration. Published by John Wiley & Sons, Ltd.

[Intervention Review]

Interventions for strabismic amblyopia

Kate Taylor[1], Sue Elliott[2]

[1]Department of Ophthalmology, Royal Victoria Infirmary, Newcastle upon Tyne, UK. [2]Ophthalmology Department, Salisbury Health Care NHS Trust, Salisbury, UK

Contact address: Kate Taylor, Department of Ophthalmology, Royal Victoria Infirmary, Claremont Wing, Queen Victoria Road, Newcastle upon Tyne, NE1 4LP, UK. kate.taylor@nuth.nhs.uk.

Editorial group: Cochrane Eyes and Vision Group.
Publication status and date: New search for studies and content updated (no change to conclusions), published in Issue 7, 2014.
Review content assessed as up-to-date: 30 January 2014.

Citation: Taylor K, Elliott S. Interventions for strabismic amblyopia. *Cochrane Database of Systematic Reviews* 2014, Issue 7. Art. No.: CD006461. DOI: 10.1002/14651858.CD006461.pub4.

Copyright © 2014 The Cochrane Collaboration. Published by John Wiley & Sons, Ltd.

ABSTRACT

Background

Amblyopia is reduced visual acuity in one or both eyes in the absence of any demonstrable abnormality of the visual pathway. It is not immediately resolved by the correction of refractive error. Strabismus develops in approximately 5% to 8% of the general population. The aim of treatment for amblyopia is to obtain the best possible level of vision in the amblyopic eye. Different treatment options were examined within the review.

Objectives

By reviewing the available evidence we wanted to establish the most effective treatment for strabismic amblyopia. In particular this review aimed to examine the impact of conventional occlusion therapy for strabismic amblyopia and to analyse the role of partial occlusion and optical penalisation for strabismic amblyopia.

Search methods

We searched CENTRAL (which contains the Cochrane Eyes and Vision Group Trials Register) (2013, Issue 12), Ovid MEDLINE, Ovid MEDLINE In-Process and Other Non-Indexed Citations, Ovid MEDLINE Daily, Ovid OLDMEDLINE (January 1946 to January 2014), EMBASE (January 1980 to January 2014), Latin American and Caribbean Health Sciences Literature Database (LILACS) (January 1982 to January 2014), the *meta*Register of Controlled Trials (*m*RCT) (www.controlled-trials.com), ClinicalTrials.gov (www.clinicaltrials.gov) and the World Health Organization (WHO) International Clinical Trials Registry Platform (ICTRP) (www.who.int/ictrp/search/en). We did not use any date or language restrictions in the electronic searches for trials. We last searched the electronic databases on 30 January 2014.

Selection criteria

We included randomised controlled trials (RCTs) for the treatment of strabismic amblyopia including participants of any age.

Data collection and analysis

Two authors working independently extracted and entered data into Review Manager 5 and then independently checked the data for errors.

Copyright © 2014 The Cochrane Collaboration. Published by John Wiley & Sons, Ltd.

[Intervention Review]

Conventional occlusion versus pharmacologic penalization for amblyopia

Tianjing Li[1], Kate Shotton[2]

[1]Cochrane Eyes and Vision Group US Project, Johns Hopkins Bloomberg School of Public Health, Baltimore, USA. [2]Department of Ophthalmology, Royal Victoria Infirmary, Newcastle upon Tyne, UK

Contact address: Tianjing Li, Cochrane Eyes and Vision Group US Project, Johns Hopkins Bloomberg School of Public Health, 615 North Wolfe Street. E6006, Baltimore, MD 21205, USA. tli@jhsph.edu.

Editorial group: Cochrane Eyes and Vision Group.
Publication status and date: Edited (no change to conclusions), published in Issue 7, 2010.

Citation: Li T, Shotton K. Conventional occlusion versus pharmacologic penalization for amblyopia. *Cochrane Database of Systematic Reviews* 2009, Issue 4. Art. No.: CD006460. DOI: 10.1002/14651858.CD006460.pub2.

Copyright © 2010 The Cochrane Collaboration. Published by John Wiley & Sons, Ltd.

ABSTRACT

Background

Amblyopia is defined as defective visual acuity in one or both eyes without demonstrable abnormality of the visual pathway, and is not immediately resolved by wearing glasses.

Objectives

To assess the effectiveness and safety of conventional occlusion versus atropine penalization for amblyopia.

Search methods

We searched CENTRAL, MEDLINE, EMBASE, LILACS, the WHO International Clinical Trials Registry Platform, preference lists, science citation index and ongoing trials up to June 2009.

Selection criteria

We included randomized/quasi-randomized controlled trials comparing conventional occlusion to atropine penalization for amblyopia.

Data collection and analysis

Two authors independently screened abstracts and full text articles, abstracted data, and assessed the risk of bias.

Main results

Three trials with a total of 525 amblyopic eyes were included. One trial was assessed as having a low risk of bias among these three trials, and one was assessed as having a high risk of bias.

Evidence from three trials suggests atropine penalization is as effective as conventional occlusion. One trial found similar improvement in vision at six and 24 months. At six months, visual acuity in the amblyopic eye improved from baseline 3.16 lines in the occlusion and 2.84 lines in the atropine group (mean difference 0.034 logMAR; 95% confidence interval (CI) 0.005 to 0.064 logMAR). At 24 months, additional improvement was seen in both groups; but there continued to be no meaningful difference (mean difference 0.01 logMAR; 95% CI −0.02 to 0.04 logMAR). The second trial reported atropine to be more effective than occlusion. At six months, visual acuity improved 1.8 lines in the patching group and 3.4 lines in the atropine penalization group, and was in favor of atropine (mean difference -0.16 logMAR; 95% CI -0.23 to -0.09 logMAR). Different occlusion modalities were used in these two trials. The third trial had inherent methodological flaws and limited inference could be drawn.

Copyright © 2010 The Cochrane Collaboration. Published by John Wiley & Sons, Ltd.

[Intervention Review]

Laser-assisted subepithelial keratectomy (LASEK) versus photorefractive keratectomy (PRK) for correction of myopia

Shi-Ming Li[1], Siyan Zhan[2], Si-Yuan Li[1], Xiao-Xia Peng[3], Jing Hu[2], Hua Andrew Law[4], Ning-Li Wang[1]

[1]Beijing Tongren Eye Center, Beijing Tongren Hospital, Capital Medical University, Beijing Ophthalmology & Visual Science Key Laboratory, Beijing, China. [2]Centre for Evidence Based Medicine and Clinical Research, Department of Epidemiology and Biostatistics, School of Public Health, Peking University, Beijing, China. [3]School of Public Health, Capital Medical University, Beijing, China. [4]Department of Epidemiology, Johns Hopkins Bloomberg School of Public Health, Baltimore, Maryland, USA

Contact address: Ning-Li Wang, Beijing Tongren Eye Center, Beijing Tongren Hospital, Capital Medical University, Beijing Ophthalmology & Visual Science Key Laboratory, No.1 Dongjiaominxiang, Dongcheng District, Beijing, 100730, China. wningli@vip.163.com.

Editorial group: Cochrane Eyes and Vision Group.
Publication status and date: New, published in Issue 2, 2016.

Citation: Li SM, Zhan S, Li SY, Peng XX, Hu J, Law HA, Wang NL. Laser-assisted subepithelial keratectomy (LASEK) versus photorefractive keratectomy (PRK) for correction of myopia. *Cochrane Database of Systematic Reviews* 2016, Issue 2. Art. No.: CD009799. DOI: 10.1002/14651858.CD009799.pub2.

Copyright © 2016 The Cochrane Collaboration. Published by John Wiley & Sons, Ltd.

ABSTRACT

Background

Myopia (near-sightedness or short-sightedness) is a condition in which the refractive power of the eye is greater than required. The most frequent complaint of people with myopia is blurred distance vision, which can be eliminated by conventional optical aids such as spectacles or contact lenses, or by refractive surgery procedures such as photorefractive keratectomy (PRK) and laser epithelial keratomileusis (LASEK). PRK uses laser to remove the corneal stroma. Similar to PRK, LASEK first creates an epithelial flap and then replaces it after ablating the corneal stroma. The relative benefits and harms of LASEK and PRK, as shown in different trials, warrant a systematic review.

Objectives

The objective of this review is to compare LASEK versus PRK for correction of myopia by evaluating their efficacy and safety in terms of postoperative uncorrected visual acuity, residual refractive error, and associated complications.

Search methods

We searched CENTRAL (which contains the Cochrane Eyes and Vision group Trials Register) (2015 Issue 12), Ovid MEDLINE, Ovid MEDLINE In-Process and Other Non-Indexed Citations, Ovid MEDLINE Daily, Ovid OLDMEDLINE (January 1946 to December 2015), EMBASE (January 1980 to December 2015), Latin American and Caribbean Health Sciences (LILACS) (January 1982 to December 2015), the ISRCTN registry (www.isrctn.com/editAdvancedSearch), ClinicalTrials.gov (www.clinicaltrials.gov) and the World Health Organization (WHO) International Clinical Trials Registry Platform (ICTRP) (www.who.int/ictrp/search/en). We did not use any date or language restrictions in the electronic searches for trials. We last searched the electronic databases on 15 December 2015. We used the Science Citation Index and searched the reference lists of the included trials to identify relevant trials for this review.

[Intervention Review]

Vitrectomy for idiopathic macular hole

Mariacristina Parravano[1], Fabrizio Giansanti[2], Chiara M Eandi[3], Yew C Yap[4], Stanislao Rizzo[5], Gianni Virgili[6]

[1]Ophthalmology, Fondazione G.B. Bietti per lo studio e la ricerca in Oftalmolologia-IRCCS, Rome, Italy. [2]Department of Specialised Surgical Sciences, University of Florence, Florence, Italy. [3]Department of Surgical Science, Eye Clinic, University of Torino, Torino, Italy. [4]Moorfields Eye Hospital NHS Foundation Trust, London, UK. [5]Eye Clinic SOD Oculistica, Azienda Ospedaliero Universitaria Careggi, Florence, Italy. [6]Department of Translational Surgery and Medicine, Eye Clinic, University of Florence, Florence, Italy

Contact address: Mariacristina Parravano, Ophthalmology, Fondazione G.B. Bietti per lo studio e la ricerca in Oftalmolologia-IRCCS, Via Livenza n 3, Rome, 00198, Italy. criparra@tin.it.

Editorial group: Cochrane Eyes and Vision Group.
Publication status and date: New, published in Issue 5, 2015.
Review content assessed as up-to-date: 4 March 2015.

Citation: Parravano M, Giansanti F, Eandi CM, Yap YC, Rizzo S, Virgili G. Vitrectomy for idiopathic macular hole. *Cochrane Database of Systematic Reviews* 2015, Issue 5. Art. No.: CD009080. DOI: 10.1002/14651858.CD009080.pub2.

Copyright © 2015 The Cochrane Collaboration. Published by John Wiley & Sons, Ltd.

ABSTRACT

Background

A macular hole is an anatomic opening in the retina that develops at the fovea. Macular holes can be seen in highly myopic eyes or following ocular trauma, but the great majority are idiopathic. Pars plana vitrectomy was introduced to treat full-thickness macular holes, which if left untreated have a poor prognosis since spontaneous closure and visual recovery are rare.

Vitrectomy is a surgical technique involving the removal of the vitreous body that fills the eye. The surgeon inserts thin cannulas into the eyes through scleral incisions to relieve traction exerted by the vitreous or epiretinal membranes to the central retina and to induce glial tissue to bridge and close the hole.

Objectives

The primary objective of this review was to examine the effects of vitrectomy for idiopathic macular hole on visual acuity. A secondary objective was to investigate anatomic effects on hole closure and other dimensions of visual function, as well as to report on adverse effects recorded in included studies.

Search methods

We searched the Cochrane Eyes and Vision Group Trials Register (4 March 2015), the Cochrane Central Register of Controlled Trials (CENTRAL; 2015, Issue 2), Ovid MEDLINE, Ovid MEDLINE In-Process and Other Non-Indexed Citations, Ovid MEDLINE Daily, Ovid OLDMEDLINE (January 1946 to March 2015), EMBASE (January 1980 to March 2015), Latin American and Caribbean Health Sciences Literature Database (LILACS) (January 1982 to March 2015), the Web of Science Conference Proceedings Citation Index-Science (CPCI-S) (January 1980 to March 2015), the ISRCTN registry (www.isrctn.com/editAdvancedSearch), ClinicalTrials.gov (www.clinicaltrials.gov) and the World Health Organization (WHO) International Clinical Trials Registry Platform (ICTRP) (www.who.int/ictrp/search/en). We did not use any date or language restrictions in the electronic searches for trials. We last searched the electronic databases on 4 March 2015.

Selection criteria

We included randomised controlled trials comparing vitrectomy (with or without internal limiting membrane peeling) to no treatment (that is observation) for macular holes.

Copyright © 2015 The Cochrane Collaboration. Published by John Wiley & Sons, Ltd.

[Intervention Review]

Vitrectomy with internal limiting membrane (ILM) peeling versus vitrectomy with no peeling for idiopathic full-thickness macular hole (FTMH)

Kurt Spiteri Cornish[1], Noemi Lois[2], Neil Scott[3], Jennifer Burr[4], Jonathan Cook[5], Charles Boachie[5], Ramin Tadayoni[6], Morten la Cour[7], Ulrik Christensen[7], Alvin Kwok[8]

[1]Ophthalmology Department, Grampian University Hospitals NHS Trust, Aberdeen, UK. [2]Centre for Vascular and Visual Sciences (CVVS), Queen's University, Belfast, UK. [3]Medical Statistics Team, University of Aberdeen, Aberdeen, UK. [4]School of Medicine, Medical and Biological Sciences Building, University of St Andrews, Fife, UK. [5]Health Services Research Unit, University of Aberdeen, Aberdeen, UK. [6]Ophthalmology, Assistance Hopitaux Publique de Paris, Paris, France. [7]Ophthalmology, Glostrup Hospital, University of Copenhagen, Copenhagen, Denmark. [8]Department of Ophthalmology, Hong Kong Sanatorium and Hospital, Hong Kong, China

Contact address: Noemi Lois, Centre for Vascular and Visual Sciences (CVVS), Queen's University, Belfast, UK. noemilois@aol.com.

Editorial group: Cochrane Eyes and Vision Group.
Publication status and date: New, published in Issue 6, 2013.
Review content assessed as up-to-date: 28 February 2013.

Citation: Spiteri Cornish K, Lois N, Scott N, Burr J, Cook J, Boachie C, Tadayoni R, la Cour M, Christensen U, Kwok A. Vitrectomy with internal limiting membrane (ILM) peeling versus vitrectomy with no peeling for idiopathic full-thickness macular hole (FTMH). *Cochrane Database of Systematic Reviews* 2013, Issue 6. Art. No.: CD009306. DOI: 10.1002/14651858.CD009306.pub2.

Copyright © 2013 The Cochrane Collaboration. Published by John Wiley & Sons, Ltd.

ABSTRACT

Background

Several observational studies have suggested the potential benefit of internal limiting membrane (ILM) peeling to treat idiopathic full-thickness macular hole (FTMH). However, no strong evidence is available on the potential benefit(s) of this surgical manoeuvre and uncertainty remains among vitreoretinal surgeons about the indication for peeling the ILM, whether to use it in all cases or in long-standing and/or larger holes.

Objectives

To determine whether ILM peeling improves anatomical and functional outcomes of macular hole surgery compared with the no-peeling technique and to investigate the impact of different parameters such as presenting vision, stage/size of the hole and duration of symptoms in the success of the surgery.

Search methods

We searched the Cochrane Central Register of Controlled Trials (CENTRAL) which contains the Cochrane Eyes and Vision Group Trials Register (*The Cochrane Library* 2013, Issue 2), Ovid MEDLINE, Ovid MEDLINE In-Process and Other Non-Indexed Citations, Ovid MEDLINE Daily, Ovid OLDMEDLINE, (January 1950 to February 2013), EMBASE (January 1980 to February 2013), Latin American and Caribbean Literature on Health Sciences (LILACS) (January 1982 to February 2013), the *meta*Register of Controlled Trials (*m*RCT) (www.controlled-trials.com), ClinicalTrials.gov (www.clinicaltrials.gov) and the WHO International Clinical Trials Registry Platform (ICTRP) (www.who.int/ictrp/search/en). We searched the reference lists of included studies for any additional studies not identified by the electronic searches. We did not use any date or language restrictions in the electronic searches for trials. We last searched the electronic databases on 28 February 2013.

Copyright © 2013 The Cochrane Collaboration. Published by John Wiley & Sons, Ltd.

8.2 Apêndice 2 - *Abstracts* das revisões sistemáticas da Colaboração Cochrane com desfechos que apoiam a intervenção sem recomendação de novos estudos **(A2)**.

[Intervention Review]

5-Fluorouracil for glaucoma surgery

Elspeth Green[1], Mark Wilkins[2], Catey Bunce[3], Richard Wormald[3,4]

[1]Norfolk and Norwich University Hospital, Norwich, UK. [2]Moorfields Eye Hospital NHS Foundation Trust, London, UK. [3]Research and Development Department, Moorfields Eye Hospital NHS Foundation Trust, London, UK. [4]Cochrane Eyes and Vision Group, ICEH, London School of Hygiene & Tropical Medicine, London, UK

Contact address: Richard Wormald, Cochrane Eyes and Vision Group, ICEH, London School of Hygiene & Tropical Medicine, Keppel Street, London, WC1E 7HT, UK. r.wormald@ucl.ac.uk.

Editorial group: Cochrane Eyes and Vision Group.
Publication status and date: New search for studies and content updated (conclusions changed), published in Issue 2, 2014.

Citation: Green E, Wilkins M, Bunce C, Wormald R. 5-Fluorouracil for glaucoma surgery. *Cochrane Database of Systematic Reviews* 2014, Issue 2. Art. No.: CD001132. DOI: 10.1002/14651858.CD001132.pub2.

Copyright © 2014 The Cochrane Collaboration. Published by John Wiley & Sons, Ltd.

ABSTRACT

Background

Trabeculectomy is performed as a treatment for many types of glaucoma in an attempt to lower the intraocular pressure. The surgery involves creating a channel through the sclera, through which intraocular fluid can leave the eye. If scar tissue blocks the exit of the surgically created channel, intraocular pressure rises and the operation fails. Antimetabolites such as 5-Fluorouracil (5-FU) are used to inhibit wound healing to prevent the conjunctiva scarring down on to the sclera. This is an update of a Cochrane review first published in 2000, and previously updated in 2009.

Objectives

To assess the effects of both intraoperative application and postoperative injections of 5-FU in eyes of people undergoing surgery for glaucoma at one year.

Search methods

We searched CENTRAL (which contains the Cochrane Eyes and Vision Group Trials Register) (*The Cochrane Library* 2013, Issue 6), Ovid MEDLINE, Ovid MEDLINE In-Process and Other Non-Indexed Citations, Ovid MEDLINE Daily, Ovid OLDMEDLINE (January 1946 to July 2013), EMBASE (January 1980 to July 2013), the *meta*Register of Controlled Trials (*m*RCT) (www.controlled-trials.com), ClinicalTrials.gov (www.clinicaltrials.gov) and the WHO International Clinical Trials Registry Platform (ICTRP) (www.who.int/ictrp/search/en). We did not use any date or language restrictions in the electronic searches for trials. We last searched the electronic databases on 25 July 2013. We also searched the reference lists of relevant articles and the Science Citation Index and contacted investigators and experts for details of additional relevant trials.

Selection criteria

We included randomised trials of intraoperative application and postoperative 5-FU injections compared with placebo or no treatment in trabeculectomy for glaucoma.

Data collection and analysis

Two authors independently assessed trial quality and extracted data. We used standard methodological procedures expected by The Cochrane Collaboration. We contacted trial investigators for missing information. Data were summarised using risk ratio (RR), Peto odds ratio and mean difference, as appropriate.

Copyright © 2014 The Cochrane Collaboration. Published by John Wiley & Sons, Ltd.

[Intervention Review]

Manual small incision cataract surgery (MSICS) with posterior chamber intraocular lens versus extracapsular cataract extraction (ECCE) with posterior chamber intraocular lens for age-related cataract

Marcus Ang[1], Jennifer R Evans[2], Jod S Mehta[1]

[1]Singapore National Eye Centre, Singapore, Singapore. [2]Cochrane Eyes and Vision Group, ICEH, London School of Hygiene & Tropical Medicine, London, UK

Contact address: Jennifer R Evans, Cochrane Eyes and Vision Group, ICEH, London School of Hygiene & Tropical Medicine, Keppel Street, London, WC1E 7HT, UK. jennifer.evans@lshtm.ac.uk.

Editorial group: Cochrane Eyes and Vision Group.
Publication status and date: New search for studies and content updated (no change to conclusions), published in Issue 11, 2014.
Review content assessed as up-to-date: 23 September 2014.

Citation: Ang M, Evans JR, Mehta JS. Manual small incision cataract surgery (MSICS) with posterior chamber intraocular lens versus extracapsular cataract extraction (ECCE) with posterior chamber intraocular lens for age-related cataract. *Cochrane Database of Systematic Reviews* 2014, Issue 11. Art. No.: CD008811. DOI: 10.1002/14651858.CD008811.pub3.

Copyright © 2014 The Cochrane Collaboration. Published by John Wiley & Sons, Ltd.

ABSTRACT

Background

Age-related cataract is the opacification of the lens, which occurs as a result of denaturation of lens proteins. Age-related cataract remains the leading cause of blindness globally, except in the most developed countries. A key question is what is the best way of removing the lens, especially in lower income settings.

Objectives

To compare two different techniques of lens removal in cataract surgery: manual small incision surgery (MSICS) and extracapsular cataract extraction (ECCE).

Search methods

We searched CENTRAL (which contains the Cochrane Eyes and Vision Group Trials Register) (2014, Issue 8), Ovid MEDLINE, Ovid MEDLINE In-Process and Other Non-Indexed Citations, Ovid MEDLINE Daily, Ovid OLDMEDLINE (January 1946 to September 2014), EMBASE (January 1980 to September 2014), Latin American and Caribbean Health Sciences Literature Database (LILACS) (January 1982 to September 2014), Web of Science Conference Proceedings Citation Index- Science (CPCI-S), (January 1990 to September 2014), the *meta*Register of Controlled Trials (*m*RCT) (www.controlled-trials.com), ClinicalTrials.gov (www.clinicaltrials.gov) and the World Health Organization (WHO) International Clinical Trials Registry Platform (ICTRP) (www.who.int/ictrp/search/en). We did not use any date or language restrictions in the electronic searches for trials. We last searched the electronic databases on 23 September 2014.

Selection criteria

We included randomised controlled trials (RCTs) only. Participants in the trials were people with age-related cataract. We included trials where MSICS with a posterior chamber intraocular lens (IOL) implant was compared to ECCE with a posterior chamber IOL implant.

[Intervention Review]

Perioperative medications for preventing temporarily increased intraocular pressure after laser trabeculoplasty

Linda Zhang[1], Jennifer S Weizer[2], David C Musch[2]

[1]The Eye Center, Warren, New Jersey, USA. [2]Ophthalmology and Visual Sciences, Kellogg Eye Center, University of Michigan, Ann Arbor, Michigan, USA

Contact address: Linda Zhang, The Eye Center, 65 Mountain Blvd Extension, Warren, New Jersey, 07059, USA. lz1126@gmail.com.

Editorial group: Cochrane Eyes and Vision Group.
Publication status and date: New, published in Issue 2, 2017.

Citation: Zhang L, Weizer JS, Musch DC. Perioperative medications for preventing temporarily increased intraocular pressure after laser trabeculoplasty. *Cochrane Database of Systematic Reviews* 2017, Issue 2. Art. No.: CD010746. DOI: 10.1002/14651858.CD010746.pub2.

Copyright © 2017 The Cochrane Collaboration. Published by John Wiley & Sons, Ltd.

ABSTRACT

Background

Glaucoma is the international leading cause of irreversible blindness. Intraocular pressure (IOP) is the only currently known modifiable risk factor; it can be reduced by medications, incisional surgery, or laser trabeculoplasty (LTP). LTP reduces IOP by 25% to 30% from baseline, but early acute IOP elevation after LTP is a common adverse effect. Most of these IOP elevations are transient, but temporarily elevated IOP may cause further optic nerve damage, worsening of glaucoma requiring additional therapy, and permanent vision loss. Antihypertensive prophylaxis with medications such as acetazolamide, apraclonidine, brimonidine, dipivefrin, pilocarpine, and timolol have been recommended to blunt and treat the postoperative IOP spike and associated pain and discomfort. Conversely, other researchers have observed that early postoperative IOP rise happens regardless of whether people receive perioperative glaucoma medications. It is unclear whether perioperative administration of antiglaucoma medications may be helpful in preventing or reducing the occurrence of postoperative IOP elevation.

Objectives

To assess the effectiveness of medications administered perioperatively to prevent temporarily increased intraocular pressure (IOP) after laser trabeculoplasty (LTP) in people with open-angle glaucoma (OAG).

Search methods

We searched CENTRAL (which contains the Cochrane Eyes and Vision Trials Register) (2016, Issue 11), MEDLINE Ovid (1946 to 18 November 2016), Embase.com (1947 to 18 November 2016), PubMed (1948 to 18 November 2016), LILACS (Latin American and Caribbean Health Sciences Literature Database) (1982 to 18 November 2016), the *meta*Register of Controlled Trials (*m*RCT) (www.controlled-trials.com); last searched 17 September 2013, ClinicalTrials.gov (www.clinicaltrials.gov); searched 18 November 2016 and the WHO International Clinical Trials Registry Platform (ICTRP) (www.who.int/ictrp/search/en); searched 18 November 2016. We did not use any date or language restrictions.

Selection criteria

We included randomized controlled trials (RCTs) in which participants with OAG received LTP. We included trials which compared any antiglaucoma medication with no medication, one type of antiglaucoma medication compared with another type of antiglaucoma medication, or different timings of medication.

Copyright © 2017 The Cochrane Collaboration. Published by John Wiley & Sons, Ltd.

[Diagnostic Test Accuracy Review]

Optical coherence tomography (OCT) for detection of macular oedema in patients with diabetic retinopathy

Gianni Virgili[1], Francesca Menchini[2], Giovanni Casazza[3], Ruth Hogg[4], Radha R Das[5], Xue Wang[6], Manuele Michelessi[7]

[1]Department of Translational Surgery and Medicine, Eye Clinic, University of Florence, Florence, Italy. [2]Department of Ophthalmology, University of Udine, Azienda Ospedaliero-universitaria di Udine, Udine, Italy. [3]Dipartimento di Scienze Biomediche e Cliniche "L. Sacco", Università degli Studi di Milano, Milan, Italy. [4]Centre for Experimental Medicine, Queen's University Belfast, Belfast, UK. [5]Royal Victoria Hospital, Belfast, UK. [6]Department of Epidemiology, Johns Hopkins Bloomberg School of Public Health, Baltimore, Maryland, USA. [7]Ophthalmology, Fondazione G.B. Bietti per lo studio e la ricerca in Oftalmolologia-IRCCS, Rome, Italy

Contact address: Gianni Virgili, Department of Translational Surgery and Medicine, Eye Clinic, University of Florence, Largo Brambilla, 3, Florence, 50134, Italy. gianni.virgili@unifi.it.

Editorial group: Cochrane Eyes and Vision Group.
Publication status and date: Edited (no change to conclusions), published in Issue 4, 2015.

Citation: Virgili G, Menchini F, Casazza G, Hogg R, Das RR, Wang X, Michelessi M. Optical coherence tomography (OCT) for detection of macular oedema in patients with diabetic retinopathy. *Cochrane Database of Systematic Reviews* 2015, Issue 1. Art. No.: CD008081. DOI: 10.1002/14651858.CD008081.pub3.

Copyright © 2015 The Cochrane Collaboration. Published by John Wiley & Sons, Ltd.

ABSTRACT

Background

Diabetic macular oedema (DMO) is a thickening of the central retina, or the macula, and is associated with long-term visual loss in people with diabetic retinopathy (DR). Clinically significant macular oedema (CSMO) is the most severe form of DMO. Almost 30 years ago, the Early Treatment Diabetic Retinopathy Study (ETDRS) found that CSMO, diagnosed by means of stereoscopic fundus photography, leads to moderate visual loss in one of four people within three years. It also showed that grid or focal laser photocoagulation to the macula halves this risk. Recently, intravitreal injection of antiangiogenic drugs has also been used to try to improve vision in people with macular oedema due to DR.

Optical coherence tomography (OCT) is based on optical reflectivity and is able to image retinal thickness and structure producing cross-sectional and three-dimensional images of the central retina. It is widely used because it provides objective and quantitative assessment of macular oedema, unlike the subjectivity of fundus biomicroscopic assessment which is routinely used by ophthalmologists instead of photography. Optical coherence tomography is also used for quantitative follow-up of the effects of treatment of CSMO.

Objectives

To determine the diagnostic accuracy of OCT for detecting DMO and CSMO, defined according to ETDRS in 1985, in patients referred to ophthalmologists after DR is detected. In the update of this review we also aimed to assess whether OCT might be considered the new reference standard for detecting DMO.

Search methods

We searched the Cochrane Database of Systematic Reviews (CDSR), the Database of Abstracts of Reviews of Effects (DARE), the Health Technology Assessment Database (HTA) and the NHS Economic Evaluation Database (NHSEED) (*The Cochrane Library* 2013, Issue 5), Ovid MEDLINE, Ovid MEDLINE In-Process and Other Non-Indexed Citations, Ovid MEDLINE Daily, Ovid OLDMEDLINE (January 1946 to June 2013), EMBASE (January 1950 to June 2013), Web of Science Conference Proceedings Citation Index - Science (CPCI-S) (January 1990 to June 2013), BIOSIS Previews (January 1969 to June 2013), MEDION and the Aggressive Research Intelligence Facility database (ARIF). We did not use any date or language restrictions in the electronic searches for trials. We last searched the electronic databases on 25 June 2013. We checked bibliographies of relevant studies for additional references.

[Intervention Review]

Sub-Tenon's anaesthesia versus topical anaesthesia for cataract surgery

Joanne Guay[1], Karl Sales[2]

[1]Department of Anesthesiology, Faculty of Medicine, University of Sherbrooke, Sherbrooke, Canada. [2]Department of Surgery/Ophthalmology, CSSS Rouyn-Noranda, Rouyn-Noranda, Canada

Contact address: Joanne Guay, Department of Anesthesiology, Faculty of Medicine, University of Sherbrooke, Sherbrooke, QC, Canada. joanneguay@bell.net, joanneguay@att.net.

Editorial group: Cochrane Anaesthesia, Critical and Emergency Care Group.
Publication status and date: New search for studies and content updated (conclusions changed), published in Issue 8, 2015.

Citation: Guay J, Sales K. Sub-Tenon's anaesthesia versus topical anaesthesia for cataract surgery. *Cochrane Database of Systematic Reviews* 2015, Issue 8. Art. No.: CD006291. DOI: 10.1002/14651858.CD006291.pub3.

Copyright © 2015 The Cochrane Collaboration. Published by John Wiley & Sons, Ltd.

ABSTRACT

Background

Local anaesthesia for cataract surgery can be provided by sub-Tenon's or topical anaesthesia. Both techniques offer possible advantages. This review, which originally was published in 2007 and was updated in 2014, was undertaken to compare these two anaesthetic techniques.

Objectives

Our objectives were to compare the effectiveness of topical anaesthesia (with or without intracameral local anaesthetic) versus sub-Tenon's anaesthesia in providing pain relief during cataract surgery. We reviewed pain during administration of anaesthesia, postoperative pain, surgical satisfaction with operating conditions and patient satisfaction with pain relief provided, and we looked at associated complications.

Search methods

We searched the Cochrane Central Register of Controlled Trials, MEDLINE and EMBASE (last search in November 2014) and the reference lists of published articles. We looked for conferences abstracts and trials in progress and placed no constraints on language or publication status.

Selection criteria

We included all randomized studies that compared sub-Tenon's anaesthesia versus topical anaesthesia for cataract surgery.

Data collection and analysis

We assessed trial quality and extracted data in the format allowing maximal data inclusion.

Main results

We included eight studies in this updated review but could retain in the analysis only seven studies on 742 operated eyes of 617 participants. Two cross-over trials included 125 participants, and five parallel trials included 492 participants. These studies were published between 1997 and 2005. The mean age of participants varied from 71.5 years to 83.5 years. The female proportion of participants varied from 54% to 76%. Compared with sub-Tenon's anaesthesia, topical anaesthesia (with or without intracameral injection) for cataract surgery increases intraoperative pain but decreases postoperative pain at 24 hours. The amplitude of the effect

8.3. Apêndice 3. *Abstracts* das revisões sistemáticas da Colaboração Cochrane com desfechos que contraindicam a intervenção, com recomendação de novos estudos **(B1)**.

[Intervention Review]

Amniotic membrane transplantation for acute ocular burns

Gerry Clare[1], Hanif Suleman[2], Catey Bunce[3], Harminder Dua[2]

[1]London Vision Clinic, London, UK. [2]Ophthalmology and Visual Sciences, University of Nottingham, Nottingham, UK. [3]Research and Development Department, Moorfields Eye Hospital NHS Foundation Trust, London, UK

Contact address: Gerry Clare, London Vision Clinic, 138 Harley Street, London, W1G 7LA, UK. gerry.clare@lshtm.ac.uk. gerry@londonvisionclinic.com.

Editorial group: Cochrane Eyes and Vision Group.
Publication status and date: Edited (no change to conclusions), published in Issue 4, 2015.
Review content assessed as up-to-date: 11 June 2012.

Citation: Clare G, Suleman H, Bunce C, Dua H. Amniotic membrane transplantation for acute ocular burns. *Cochrane Database of Systematic Reviews* 2012, Issue 9. Art. No.: CD009379. DOI: 10.1002/14651858.CD009379.pub2.

Copyright © 2015 The Cochrane Collaboration. Published by John Wiley & Sons, Ltd.

ABSTRACT

Background

Ocular surface burns can be caused by chemicals (alkalis and acids) or by direct heat. Amniotic membrane transplantation (AMT) performed in the acute phase (day 0 to day 7) of an ocular surface burn is reported to relieve pain, accelerate healing and reduce scarring and blood vessel formation. The surgery involves applying a patch of amniotic membrane (AM) over the entire ocular surface up to the eyelid margins.

Objectives

To assess the effects of AMT on the eyes of people having suffered acute ocular surface burns.

Search methods

We searched CENTRAL (which contains the Cochrane Eyes and Vision Group Trials Register) (*The Cochrane Library* 2012, Issue 6), MEDLINE (January 1946 to June 2012), EMBASE (January 1980 to June 2012), Latin American and Caribbean Literature on Health Sciences (LILACS) (January 1982 to June 2012), the *meta*Register of Controlled Trials (*m*RCT) (www.controlled-trials.com), ClinicalTrials.gov (www.clinicaltrials.gov) and the WHO International Clinical Trials Registry Platform (ICTRP) (www.who.int/ictrp/search/en). We did not use any date or language restrictions in the electronic searches for trials. We last searched the electronic databases on 11 June 2012.

Selection criteria

We included randomised trials of medical therapy and AMT applied in the first seven days after an ocular surface burn compared to medical therapy alone.

Data collection and analysis

Two authors independently assessed the risk of bias of included studies and extracted relevant data. We contacted trial investigators for missing information. We summarised data using risk ratios (RRs) and mean differences (MDs) as appropriate.

Copyright © 2015 The Cochrane Collaboration. Published by John Wiley & Sons, Ltd.

[Intervention Review]

Patching for corneal abrasion

Chris HL Lim[1], Angus Turner[2], Blanche X Lim[3]

[1]The Royal Melbourne Hospital, Melbourne, Australia. [2]Royal Victorian Eye and Ear Hospital, Victoria, Australia. [3]Department of Ophthalmology, National University Health System/Jurong General Health Services, Singapore, Singapore

Contact address: Angus Turner, Royal Victorian Eye and Ear Hospital, 32 Gisborne St, East Melbourne, Victoria, 3002, Australia. angus.turner@gmail.com.

Editorial group: Cochrane Eyes and Vision Group.
Publication status and date: New search for studies and content updated (no change to conclusions), published in Issue 7, 2016.

Citation: Lim CHL, Turner A, Lim BX. Patching for corneal abrasion. *Cochrane Database of Systematic Reviews* 2016, Issue 7. Art. No.: CD004764. DOI: 10.1002/14651858.CD004764.pub3.

Copyright © 2016 The Cochrane Collaboration. Published by John Wiley & Sons, Ltd.

ABSTRACT

Background

Published audits have demonstrated that corneal abrasions are a common presenting eye complaint. Eye patches are often recommended for treating corneal abrasions despite the lack of evidence for their use. This systematic review was conducted to determine the effects of the eye patch when used to treat corneal abrasions.

Objectives

The objective of this review was to assess the effects of patching for corneal abrasion on healing and pain relief.

Search methods

We searched CENTRAL (which contains the Cochrane Eyes and Vision Trials Register) (2016, Issue 4), Ovid MEDLINE, Ovid MEDLINE In-Process and Other Non-Indexed Citations, Ovid MEDLINE Daily, Ovid OLDMEDLINE (January 1946 to May 2016), EMBASE (January 1980 to May 2016), Latin American and Caribbean Health Sciences Literature Database (LILACS) (January 1982 to May 2016), System for Information on Grey Literature in Europe (OpenGrey) (January 1995 to May 2016), the ISRCTN registry (www.isrctn.com/editAdvancedSearch), ClinicalTrials.gov (www.clinicaltrials.gov) and the World Health Organization (WHO) International Clinical Trials Registry Platform (ICTRP) (www.who.int/ictrp/search/en). We did not use any date or language restrictions in the electronic searches for trials. We last searched the electronic databases on 9 May 2016. We also searched the reference lists of included studies, unpublished 'grey' literature and conference proceedings and contacted pharmaceutical companies for details of unpublished trials.

Selection criteria

We included randomised and quasi-randomised controlled trials that compared patching the eye with no patching to treat simple corneal abrasions.

Data collection and analysis

Two authors independently assessed the risk of bias and extracted data. Investigators were contacted for further information regarding the quality of trials. The primary outcome was healing at 24, 48 and 72 hours while secondary outcomes included measures of pain, quality of life and adverse effects. We graded the certainty of the evidence using GRADE.

Copyright © 2016 The Cochrane Collaboration. Published by John Wiley & Sons, Ltd.

[Intervention Review]

Corticosteroid implants for chronic non-infectious uveitis

Christopher J Brady[1], Andrea C Villanti[2], Hua Andrew Law[3], Ehsan Rahimy[4], Rahul Reddy[5], Pamela C Sieving[6], Sunir J Garg[4], Johnny Tang[7]

[1]Wilmer Eye Institute, Johns Hopkins University School of Medicine, Baltimore, Maryland, USA. [2]Department of Health, Behavior and Society, Johns Hopkins Bloomberg School of Public Health, Baltimore, Maryland, USA. [3]Department of Epidemiology, Johns Hopkins Bloomberg School of Public Health, Baltimore, Maryland, USA. [4]MidAtlantic Retina, The Retina Service of Wills Eye Hospital, Thomas Jefferson University, Philadelphia, Pennsylvania, USA. [5]Associated Retinal Consultants, Phoenix, Arizona, USA. [6]National Institutes of Health Library, Bethesda, Maryland, USA. [7]University Hospitals Eye Institute, University Hospitals Eye Institute/Case Western Reserve University, Cleveland, Ohio, USA

Contact address: Christopher J Brady, Wilmer Eye Institute, Johns Hopkins University School of Medicine, Baltimore, Maryland, USA. brady@jhmi.edu.

Editorial group: Cochrane Eyes and Vision Group.
Publication status and date: New, published in Issue 2, 2016.

Citation: Brady CJ, Villanti AC, Law HA, Rahimy E, Reddy R, Sieving PC, Garg SJ, Tang J. Corticosteroid implants for chronic non-infectious uveitis. *Cochrane Database of Systematic Reviews* 2016, Issue 2. Art. No.: CD010469. DOI: 10.1002/14651858.CD010469.pub2.

Copyright © 2016 The Cochrane Collaboration. Published by John Wiley & Sons, Ltd.

ABSTRACT

Background

Uveitis is a term used to describe a heterogeneous group of intraocular inflammatory diseases of the anterior, intermediate, and posterior uveal tract (iris, ciliary body, choroid). Uveitis is the fifth most common cause of vision loss in high-income countries, accounting for 5% to 20% of legal blindness, with the highest incidence of disease in the working-age population.

Corticosteroids are the mainstay of acute treatment for all anatomical subtypes of non-infectious uveitis and can be administered orally, topically with drops or ointments, by periocular (around the eye) or intravitreal (inside the eye) injection, or by surgical implantation.

Objectives

To determine the efficacy and safety of steroid implants in people with chronic non-infectious posterior uveitis, intermediate uveitis, and panuveitis.

Search methods

We searched CENTRAL (which contains the Cochrane Eyes and Vision Trials Register) (Issue 10, 2015), Ovid MEDLINE, Ovid MEDLINE In-Process and Other Non-Indexed Citations, Ovid MEDLINE Daily, Ovid OLDMEDLINE (January 1946 to November 2015), EMBASE (January 1980 to November 2015), PubMed (1948 to November 2015), Latin American and Caribbean Health Sciences Literature Database (LILACS) (1982 to November 2015), the *meta*Register of Controlled Trials (*m*RCT) (www.controlled-trials.com) (last searched 15 April 2013), ClinicalTrials.gov (www.clinicaltrials.gov), and the World Health Organization (WHO) International Clinical Trials Registry Platform (ICTRP) (www.who.int/ictrp/search/en). We did not use any date or language restrictions in the electronic search for studies. We last searched the electronic databases on 6 November 2015.

We also searched reference lists of included study reports, citation databases, and abstracts and clinical study presentations from professional meetings.

Copyright © 2016 The Cochrane Collaboration. Published by John Wiley & Sons, Ltd.

[Intervention Review]

Steroids for traumatic optic neuropathy

Patrick Yu-Wai-Man[1], Philip G Griffiths[1]

[1]Department of Ophthalmology, Royal Victoria Infirmary, Newcastle upon Tyne, UK

Contact address: Patrick Yu-Wai-Man, Department of Ophthalmology, Royal Victoria Infirmary, Newcastle upon Tyne, NE1 4LP, UK. patrick.yu-wai-man@ncl.ac.uk.

Editorial group: Cochrane Eyes and Vision Group.
Publication status and date: New search for studies and content updated (no change to conclusions), published in Issue 6, 2013.

Citation: Yu-Wai-Man P, Griffiths PG. Steroids for traumatic optic neuropathy. *Cochrane Database of Systematic Reviews* 2013, Issue 6. Art. No.: CD006032. DOI: 10.1002/14651858.CD006032.pub4.

Copyright © 2013 The Cochrane Collaboration. Published by John Wiley & Sons, Ltd.

ABSTRACT

Background

Traumatic optic neuropathy (TON) is an important cause of severe visual loss following blunt or penetrating head trauma. Following the initial injury, optic nerve swelling within the optic nerve canal can result in secondary retinal ganglion cell loss. Optic nerve decompression with steroids or surgical interventions or both has therefore been advocated as a means of improving visual prognosis in TON.

Objectives

The aim of this review was to examine the effectiveness and safety of using steroids in TON.

Search methods

We searched CENTRAL (which contains the Cochrane Eyes and Vision Group Trials Register) (*The Cochrane Library* 2013, Issue 4), Ovid MEDLINE, Ovid MEDLINE In-Process and Other Non-Indexed Citations, Ovid MEDLINE Daily, Ovid OLDMEDLINE, (January 1950 to May 2013), EMBASE (January 1980 to May 2013), Latin American and Caribbean Literature on Health Sciences (LILACS) (January 1982 to May 2013), Web of Science Conference Proceedings Citation Index- Science (CPCI-S) (January 1990 to May 2013), the *meta*Register of Controlled Trials (*m*RCT) (www.controlled-trials.com), ClinicalTrials.gov (http://clinicaltrials.gov) and the WHO International Clinical Trials Registry Platform (ICTRP) (www.who.int/ictrp/search/en). We did not use any date or language restrictions in the electronic searches for trials. We last searched the electronic databases on 21 May 2013. We also searched the reference lists of included studies, other reviews and book chapters on TON to find references to additional trials. The Science Citation Index was used to look for papers that cited the studies included in this review. We did not manually search any journals or conference proceedings. We contacted trial investigators and experts in the field to identify additional published and unpublished studies.

Selection criteria

We planned to include only randomised controlled trials (RCTs) of TON in which any steroid regime, either on its own or in combination with surgical optic nerve decompression, was compared to surgery alone or no treatment.

Data collection and analysis

Two review authors independently assessed the titles and abstracts identified from the electronic searches.

Copyright © 2013 The Cochrane Collaboration. Published by John Wiley & Sons, Ltd.

[Intervention Review]

Surgery for nonarteritic anterior ischemic optic neuropathy

Kay Dickersin[1], Tianjing Li[2]

[1]Center for Clinical Trials and US Cochrane Center, Johns Hopkins University, Baltimore, MD, USA. [2]Department of Epidemiology, Johns Hopkins Bloomberg School of Public Health, Baltimore, Maryland, USA

Contact address: Kay Dickersin, Center for Clinical Trials and US Cochrane Center, Johns Hopkins University, Bloomberg School of Public Health, 615 North Wolfe Street, Mail Rm E6152, Baltimore, MD, 21205, USA. kdicker3@jhu.edu.

Editorial group: Cochrane Eyes and Vision Group.
Publication status and date: New search for studies and content updated (no change to conclusions), published in Issue 3, 2015.

Citation: Dickersin K, Li T. Surgery for nonarteritic anterior ischemic optic neuropathy. *Cochrane Database of Systematic Reviews* 2015, Issue 3. Art. No.: CD001538. DOI: 10.1002/14651858.CD001538.pub4.

Copyright © 2015 The Cochrane Collaboration. Published by John Wiley & Sons, Ltd.

ABSTRACT

Background

Nonarteritic anterior ischemic optic neuropathy (NAION) is characterized by sudden and painless loss of vision in the eye, accompanied by pallid swelling of the optic disc. Its etiology is unknown and no medical therapy has been proven effective in treating this condition. Optic nerve decompression surgery, a proposed treatment for NAION, involves making two or more slits or a window in the tissue surrounding the optic nerve, thereby allowing cerebrospinal fluid to escape, and theoretically reducing the pressure surrounding the optic nerve.

Objectives

The objective of this review was to assess the safety and efficacy of surgery compared with other treatment or no treatment in people with NAION.

Search methods

We searched CENTRAL (which contains the Cochrane Eyes and Vision Group Trials Register) (2014, Issue 10), Ovid MEDLINE, Ovid MEDLINE In-Process and Other Non-Indexed Citations, Ovid MEDLINE Daily, Ovid OLDMEDLINE (January 1946 to October 2014), EMBASE (January 1980 to October 2014), PubMed (1948 to October 2014), the *meta*Register of Controlled Trials (*m*RCT) (www.controlled-trials.com), ClinicalTrials.gov (www.clinicaltrials.gov) and the World Health Organization (WHO) International Clinical Trials Registry Platform (ICTRP) (www.who.int/ictrp/search/en). There were no date or language restrictions in the electronic searches for trials. We last searched the electronic databases on 23 October 2014.

Selection criteria

All randomized trials of surgical treatment of NAION were eligible for inclusion in this review.

Data collection and analysis

From full-text copies of all reports from relevant trials, one author extracted data which were verified by another author. No data synthesis was required.

Copyright © 2015 The Cochrane Collaboration. Published by John Wiley & Sons, Ltd.

8.4. Apêndice *4. Abstract* das revisões sistemáticas da Colaboração Cochrane com desfechos que apoiam a intervenção sem recomendação de novos estudos **(B2)**.

[Intervention Review]

Anti-vascular endothelial growth factor combined with intravitreal steroids for diabetic macular oedema

Hemal Mehta[1,2], Charles Hennings[1], Mark C Gillies[2], Vuong Nguyen[2], Anna Campain[2], Samantha Fraser-Bell[2]

[1]Royal Free London NHS Foundation Trust, London, UK. [2]Macular Research Group, Save Sight Institute, University of Sydney, Sydney, Australia

Contact address: Hemal Mehta, Royal Free London NHS Foundation Trust, London, UK. hm@cantab.net.

Editorial group: Cochrane Eyes and Vision Group.
Publication status and date: New, published in Issue 4, 2018.

Citation: Mehta H, Hennings C, Gillies MC, Nguyen V, Campain A, Fraser-Bell S. Anti-vascular endothelial growth factor combined with intravitreal steroids for diabetic macular oedema. *Cochrane Database of Systematic Reviews* 2018, Issue 4. Art. No.: CD011599. DOI: 10.1002/14651858.CD011599.pub2.

Copyright © 2018 The Cochrane Collaboration. Published by John Wiley & Sons, Ltd.

ABSTRACT

Background

The combination of steroid and anti-vascular endothelial growth factor (VEGF) intravitreal therapeutic agents could potentially have synergistic effects for treating diabetic macular oedema (DMO). On the one hand, if combined treatment is more effective than monotherapy, there would be significant implications for improving patient outcomes. Conversely, if there is no added benefit of combination therapy, then people could be potentially exposed to unnecessary local or systemic side effects.

Objectives

To assess the effects of intravitreal agents that block vascular endothelial growth factor activity (anti-VEGF agents) plus intravitreal steroids versus monotherapy with macular laser, intravitreal steroids or intravitreal anti-VEGF agents for managing DMO.

Search methods

We searched the Cochrane Central Register of Controlled Trials (CENTRAL) (which contains the Cochrane Eyes and Vision Trials Register) (2018, Issue 1); Ovid MEDLINE; Ovid Embase; LILACS; the ISRCTN registry; ClinicalTrials.gov and the ICTRP. The date of the search was 21 February 2018.

Selection criteria

We included randomised controlled trials (RCTs) of intravitreal anti-VEGF combined with intravitreal steroids versus intravitreal anti-VEGF alone, intravitreal steroids alone or macular laser alone for managing DMO. We included people with DMO of all ages and both sexes. We also included trials where both eyes from one participant received different treatments.

Data collection and analysis

We used standard methodological procedures recommended by Cochrane.Two authors independently reviewed all the titles and abstracts identified from the electronic and manual searches against the inclusion criteria. Our primary outcome was change in best corrected visual acuity (BCVA) between baseline and one year. Secondary outcomes included change in central macular thickness (CMT), economic data and quality of life. We considered adverse effects including intraocular inflammation, raised intraocular pressure (IOP) and development of cataract.

Copyright © 2018 The Cochrane Collaboration. Published by John Wiley & Sons, Ltd.

[Intervention Review]

Antioxidant vitamin supplementation for preventing and slowing the progression of age-related cataract

Milan C Mathew[1], Ann-Margret Ervin[2], Jeremiah Tao[3], Richard M Davis[4]

[1]MetroWest Medical Center, Framingham, Massachusetts, USA. [2]Department of Epidemiology, Johns Hopkins Bloomberg School of Public Health, Baltimore, Maryland, USA. [3]Ophthalmology, University of California, Irvine, Irvine, California, USA. [4]Department of Ophthalmology, University of North Carolina, Chapel Hill, North Carolina, USA

Contact address: Milan C Mathew, MetroWest Medical Center, 115 Lincoln Street, Framingham, Massachusetts, 01702, USA. milan@milanmathew.com.

Editorial group: Cochrane Eyes and Vision Group.
Publication status and date: New, published in Issue 6, 2012.

Citation: Mathew MC, Ervin AM, Tao J, Davis RM. Antioxidant vitamin supplementation for preventing and slowing the progression of age-related cataract. *Cochrane Database of Systematic Reviews* 2012, Issue 6. Art. No.: CD004567. DOI: 10.1002/14651858.CD004567.pub2.

Copyright © 2012 The Cochrane Collaboration. Published by John Wiley & Sons, Ltd.

ABSTRACT

Background

Age-related cataract is a major cause of visual impairment in the elderly. Oxidative stress has been implicated in its formation and progression. Antioxidant vitamin supplementation has been investigated in this context.

Objectives

To assess the effectiveness of antioxidant vitamin supplementation in preventing and slowing the progression of age-related cataract.

Search methods

We searched CENTRAL (which contains the Cochrane Eyes and Vision Group Trials Register) (*The Cochrane Library* 2012, Issue 2), MEDLINE (January 1950 to March 2012), EMBASE (January 1980 to March 2012), Latin American and Caribbean Literature on Health Sciences (LILACS) (January 1982 to March 2012), Open Grey (System for Information on Grey Literature in Europe) (www.opengrey.eu/), the *meta*Register of Controlled Trials (*m*RCT) (www.controlled-trials.com), ClinicalTrials.gov (www.clinicaltrials.gov) and the WHO International Clinical Trials Registry Platform (ICTRP) (www.who.int/ictrp/search/en). There were no date or language restrictions in the electronic searches for trials. The electronic databases were last searched on 2 March 2012. We also checked the reference lists of included studies and ongoing trials and contacted investigators to identify eligible randomized trials.

Selection criteria

We included only randomized controlled trials in which supplementation with one or more antioxidant vitamins (beta-carotene, vitamin C and vitamin E) in any form, dosage or combination for at least one year was compared to another antioxidant vitamin or to placebo.

Data collection and analysis

Two authors extracted data and assessed trial quality independently. We pooled results for the primary outcomes, i.e., incidence of cataract and incidence of cataract extraction. We did not pool results of the secondary outcomes - progression of cataract and loss of visual acuity, because of differences in definitions of outcomes and data presentation. We pooled results by type of cataract when data were available. We did not perform a sensitivity analysis.

Copyright © 2012 The Cochrane Collaboration. Published by John Wiley & Sons, Ltd.

[Intervention Review]

Beta-blockers for prevention and treatment of retinopathy of prematurity in preterm infants

Siree Kaempfen[1], Roland P Neumann[1], Kerstin Jost[1], Sven M Schulzke[1]

[1]Department of Neonatology, University of Basel Children's Hospital (UKBB), Basel, Switzerland

Contact address: Siree Kaempfen, Department of Neonatology, University of Basel Children's Hospital (UKBB), Basel, Basel, CH-4031, Switzerland. siree.kaempfen@ukbb.ch.

Editorial group: Cochrane Neonatal Group.
Publication status and date: New, published in Issue 3, 2018.

Citation: Kaempfen S, Neumann RP, Jost K, Schulzke SM. Beta-blockers for prevention and treatment of retinopathy of prematurity in preterm infants. *Cochrane Database of Systematic Reviews* 2018, Issue 3. Art. No.: CD011893. DOI: 10.1002/14651858.CD011893.pub2.

Copyright © 2018 The Cochrane Collaboration. Published by John Wiley & Sons, Ltd.

ABSTRACT

Background

Retinopathy of prematurity (ROP) is a vision-threatening disease of preterm neonates. The use of beta-adrenergic blocking agents (beta-blockers), which modulate the vasoproliferative retinal process, may reduce the progression of ROP or even reverse established ROP.

Objectives

To determine the effect of beta-blockers on short-term structural outcomes, long-term functional outcomes, and the need for additional treatment, when used either as prophylaxis in preterm infants without ROP, stage 1 ROP (zone I), or stage 2 ROP (zone II) without plus disease or as treatment in preterm infants with at least prethreshold ROP.

Search methods

We searched the Cochrane Neonatal Review Group Specialized Register; CENTRAL (in the Cochrane Library Issue 7, 2017); Embase (January 1974 to 7 August 2017); PubMed (January 1966 to 7 August 2017); and CINAHL (January 1982 to 7 August 2017). We checked references and cross-references and handsearched abstracts from the proceedings of the Pediatric Academic Societies Meetings.

Selection criteria

We considered for inclusion randomised or quasi-randomised clinical trials that used beta-blockers for prevention or treatment of ROP in preterm neonates of less than 37 weeks' gestational age.

Data collection and analysis

We used the standard methods of Cochrane and the Cochrane Neonatal Review Group. We used the GRADE approach to assess the quality of evidence.

Main results

We included three randomised trials (N = 366) in this review. Two of these studies were at high risk of bias. All studies reported on prevention of ROP and compared oral propranolol with placebo or no treatment. We found no trials assessing beta-blockers in infants with established stage 2 or higher ROP with plus disease.

[Intervention Review]

Laser photocoagulation for choroidal neovascularisation in pathologic myopia

Gianni Virgili[1], Francesca Menchini[2]

[1]Department of Ophthalmology, University of Florence, Florence, Italy. [2]Department of Ophthalmology, University of Udine, Azienda Ospedaliero-universitaria di Udine, Udine, Italy

Contact address: Gianni Virgili, Department of Ophthalmology, University of Florence, Via le Morgagni 85, Florence, 50134, Italy. gianni.virgili@unifi.it.

Editorial group: Cochrane Eyes and Vision Group.
Publication status and date: Edited (no change to conclusions), published in Issue 1, 2009.
Review content assessed as up-to-date: 14 March 2007.

Citation: Virgili G, Menchini F. Laser photocoagulation for choroidal neovascularisation in pathologic myopia. *Cochrane Database of Systematic Reviews* 2005, Issue 4. Art. No.: CD004765. DOI: 10.1002/14651858.CD004765.pub2.

Copyright © 2009 The Cochrane Collaboration. Published by John Wiley & Sons, Ltd.

ABSTRACT

Background

Pathologic myopia is usually defined as the need for a spectacle correction of -6 diopters or higher. Choroidal neovascularisation (CNV) is the most commonly occurring cause of visual loss in people with pathologic myopia. In myopic macular degeneration the occurrence of newly formed vessels in the macula often leads to a fibrotic pigmented scar causing a blind spot in the centre of the visual field.

Objectives

The primary objective of this review was to examine the effects of laser photocoagulation for CNV associated with pathologic myopia. A secondary objective was to compare the effects of different photocoagulation techniques.

Search methods

We searched the Cochrane Controlled Trials Register (CENTRAL) (which contains the Cochrane Eyes and Vision Group Trials Register) in *The Cochrane Library* (Issue 1, 2007), MEDLINE (1966 to March 2007), EMBASE (1980 to March 2007), LILACS (March 2007) and reference lists of identified trial reports.

Selection criteria

We included randomised controlled trials comparing photocoagulation with observation or comparing different photocoagulation techniques in people with CNV associated with myopia of -6 diopters or higher.

Data collection and analysis

Two authors independently assessed the search results for eligibility.

Main results

Two studies were included that enrolled people with CNV located at 100 microns or more from the foveal centre. One study compared photocoagulation with observation. At the final examination, 16/35 participants randomised to photocoagulation versus 31/35 randomised to observation had visual acuity of 20/100 or worse after six to 48 months. The second study randomised 27 eyes (26 participants) to photocoagulation with three laser wavelengths (nine eyes per group). The number of eyes losing two or more lines was two (577 nm), three (590 nm) and three (620 nm) after three to 17 months. In both studies comparisons were made using outcomes assessed at the final examination. As the final examination took place at different follow-up times it was difficult to interpret the findings and it was impossible to extract data for further analyses.

Copyright © 2009 The Cochrane Collaboration. Published by John Wiley & Sons, Ltd.

[Intervention Review]

Laser photocoagulation for neovascular age-related macular degeneration

Gianni Virgili[1], Alessandro Bini[2]

[1]Department of Ophthalmology, University of Florence, Florence, Italy. [2]Eye Clinic II, Dept. Oto-Neuro-Ophthalmological Surgical Sciences, University of Florence, Florence, Italy

Contact address: Gianni Virgili, Department of Ophthalmology, University of Florence, Via le Morgagni 85, Florence, 50134, Italy. gianni.virgili@unifi.it.

Editorial group: Cochrane Eyes and Vision Group.
Publication status and date: Edited (no change to conclusions), published in Issue 1, 2010.

Citation: Virgili G, Bini A. Laser photocoagulation for neovascular age-related macular degeneration. *Cochrane Database of Systematic Reviews* 2007, Issue 3. Art. No.: CD004763. DOI: 10.1002/14651858.CD004763.pub2.

Copyright © 2010 The Cochrane Collaboration. Published by John Wiley & Sons, Ltd.

ABSTRACT

Background

Laser photocoagulation was the first treatment introduced to try to halt the progression of neovascular age-related macular degeneration (AMD), in which newly formed vessels or choroidal neovascularisation (CNV) grow under the macula leading to the occurrence of a scotoma or blind spot in the central visual field.

Objectives

The aim of this review was to examine the effects of laser photocoagulation for neovascular AMD.

Search methods

We searched the CENTRAL, MEDLINE, EMBASE, LILACS, NRR and ZETOC in March 2007.

Selection criteria

We included randomised trials of laser photocoagulation in people with CNV due to AMD.

Data collection and analysis

Two authors independently extracted the data. The risk ratio (RR) of severe visual loss (loss of six or more lines of visual acuity) was estimated at three months and two years after treatment.

Main results

Fifteen trials were included in the review (2064 participants). Three types of photocoagulation were used in the trials: direct photocoagulation of the entire CNV (11 trials), perifoveal photocoagulation (one trial) and grid photocoagulation (three trials). In 12 trials the control group was observation only. One trial compared photocoagulation to submacular surgery and two trials compared different lasers. Data on the progression of visual loss could be extracted from five of the eight trials of direct photocoagulation of the CNV versus observation. The treatment effect was in the direction of harm in all studies at three months follow up (RR 1.41, 95% confidence intervals (CI) 1.08 to 1.82). After two years the treatment effect was in the direction of benefit (RR 0.67, 95% CI 0.53 to 0.83). These studies were clinically heterogenous with participants having CNV lesions in different locations and different baseline visual acuities. There was little evidence of statistical heterogeneity at three months but substantial statistical heterogeneity at two years. However, all treatment effects in the individual trials were in the direction of benefit. One study comparing perifoveal photocoagulation or observation of subfoveal CNV found benefits that were statistically significant only at two years (RR 0.36, 95% CI 0.18 to 0.72). Other comparisons did not demonstrate differences.

Copyright © 2010 The Cochrane Collaboration. Published by John Wiley & Sons, Ltd.

[Intervention Review]

Laser treatment of drusen to prevent progression to advanced age-related macular degeneration

Gianni Virgili[1], Manuele Michelessi[2,3], Maurizio B Parodi[4], Daniela Bacherini[1], Jennifer R Evans[5]

[1]Department of Translational Surgery and Medicine, Eye Clinic, University of Florence, Florence, Italy. [2]Ophthalmology, Fondazione G.B. Bietti per lo studio e la ricerca in Oftalmolologia-IRCCS, Rome, Italy. [3]Department of Epidemiology, Johns Hopkins Bloomberg School of Public Health, Baltimore, Maryland, USA. [4]Department of Ophthalmology, University Vita-Salute, Ospedale San Raffaeale, Milan, Italy. [5]Cochrane Eyes and Vision Group, ICEH, London School of Hygiene & Tropical Medicine, London, UK

Contact address: Maurizio B Parodi, Department of Ophthalmology, University Vita-Salute, Ospedale San Raffaeale, Milan, Italy. maubp@yahoo.it.

Editorial group: Cochrane Eyes and Vision Group.
Publication status and date: New search for studies and content updated (conclusions changed), published in Issue 10, 2015.
Review content assessed as up-to-date: 3 August 2015.

Citation: Virgili G, Michelessi M, Parodi MB, Bacherini D, Evans JR. Laser treatment of drusen to prevent progression to advanced age-related macular degeneration. *Cochrane Database of Systematic Reviews* 2015, Issue 10. Art. No.: CD006537. DOI: 10.1002/14651858.CD006537.pub3.

Copyright © 2015 The Cochrane Collaboration. Published by John Wiley & Sons, Ltd.

ABSTRACT

Background

Drusen are amorphous yellowish deposits beneath the sensory retina. People with drusen, particularly large drusen, are at higher risk of developing age-related macular degeneration (AMD). The most common complication in AMD is choroidal neovascularisation (CNV), the growth of new blood vessels in the centre of the macula. The risk of CNV is higher among people who are already affected by CNV in one eye.

It has been observed clinically that laser photocoagulation of drusen leads to their disappearance and may prevent the occurrence of advanced disease (CNV or geographic atrophy) associated with visual loss.

Objectives

To examine the effectiveness and adverse effects of laser photocoagulation of drusen in AMD.

Search methods

We searched CENTRAL (which contains the Cochrane Eyes and Vision Group Trials Register) (2015, Issue 7), Ovid MEDLINE, Ovid MEDLINE In-Process and Other Non-Indexed Citations, Ovid MEDLINE Daily, Ovid OLDMEDLINE (January 1946 to August 2015), EMBASE (January 1980 to August 2015), Latin American and Caribbean Health Sciences Literature Database (LILACS) (January 1982 to August 2015), the ISRCTN registry (www.isrctn.com/editAdvancedSearch), ClinicalTrials.gov (www.clinicaltrials.gov) and the World Health Organization (WHO) International Clinical Trials Registry Platform (ICTRP) (www.who.int/ictrp/search/en). We did not use any date or language restrictions in the electronic searches for trials. We last searched the electronic databases on 3 August 2015.

Selection criteria

Randomised controlled trials (RCTs) of laser treatment of drusen in AMD in which laser treatment had been compared with no intervention or sham treatment. Two types of trials were included. Some trials studied one eye of each participant (unilateral studies); other studies recruited participants with bilateral drusen and randomised one eye to photocoagulation or control and the fellow eye to the other group.

[Intervention Review]

Routine preoperative medical testing for cataract surgery

Lisa Keay[1], Kristina Lindsley[2], James Tielsch[3], Joanne Katz[3], Oliver Schein[4]

[1]Injury Division, The George Institute for Global Health, The University of Sydney, Sydney, Australia. [2]Center for Clinical Trials, Department of Epidemiology, Johns Hopkins Bloomberg School of Public Health, Baltimore, Maryland, USA. [3]Department of International Health, Johns Hopkins Bloomberg School of Public Health, Baltimore, Maryland, USA. [4]Wilmer Eye Institute, Johns Hopkins University School of Medicine, Baltimore, Maryland, USA

Contact address: Lisa Keay, Injury Division, The George Institute for Global Health, The University of Sydney, P.O. Box M201 Missenden Road, Sydney, NSW, 2050, Australia. lkeay@georgeinstitute.org.au.

Editorial group: Cochrane Eyes and Vision Group.
Publication status and date: New search for studies and content updated (no change to conclusions), published in Issue 3, 2012.
Review content assessed as up-to-date: 9 December 2011.

Citation: Keay L, Lindsley K, Tielsch J, Katz J, Schein O. Routine preoperative medical testing for cataract surgery. *Cochrane Database of Systematic Reviews* 2012, Issue 3. Art. No.: CD007293. DOI: 10.1002/14651858.CD007293.pub3.

Copyright © 2012 The Cochrane Collaboration. Published by John Wiley & Sons, Ltd.

ABSTRACT

Background

Cataract surgery is practiced widely and substantial resources are committed to an increasing cataract surgical rate in developing countries. With the current volume of cataract surgery and the increases in the future, it is critical to optimize the safety and cost-effectiveness of this procedure. Most cataracts are performed on older individuals with correspondingly high systemic and ocular comorbidities. It is likely that routine preoperative medical testing will detect medical conditions, but it is questionable whether these conditions should preclude individuals from cataract surgery or change their perioperative management.

Objectives

(1) To investigate the evidence for reductions in adverse events through preoperative medical testing, and (2) to estimate the average cost of performing routine medical testing.

Search methods

We searched CENTRAL (which contains the Cochrane Eyes and Vision Group Trials Register) (*The Cochrane Library* 2011, Issue 12), MEDLINE (January 1950 to December 2011), EMBASE (January 1980 to December 2011), Latin American and Caribbean Literature on Health Sciences (LILACS) (January 1982 to December 2011), the *meta*Register of Controlled Trials (*m*RCT) (www.controlled-trials.com), ClinicalTrials.gov (www.clinicaltrials.gov) and the WHO International Clinical Trials Registry Platform (ICTRP) (www.who.int/ictrp/search/en). There were no date or language restrictions in the electronic searches for trials. The electronic databases were last searched on 9 December 2011. We used reference lists and the Science Citation Index to search for additional studies.

Selection criteria

We included randomized clinical trials in which routine preoperative medical testing was compared to no preoperative or selective preoperative testing prior to age-related cataract surgery.

Data collection and analysis

Two review authors independently assessed abstracts to identify possible trials for inclusion. For each included study, two review authors independently documented study characteristics, extracted data, and assessed methodological quality.

Copyright © 2012 The Cochrane Collaboration. Published by John Wiley & Sons, Ltd.

[Intervention Review]

Day care versus in-patient surgery for age-related cataract

David Lawrence[1], Zbys Fedorowicz[2], Esther J van Zuuren[3]

[1]London School of Hygiene & Tropical Medicine, London, UK. [2]Bahrain Branch, Cochrane, Awali, Bahrain. [3]Department of Dermatology, Leiden University Medical Center, Leiden, Netherlands

Contact address: Zbys Fedorowicz, Bahrain Branch, Cochrane, Box 25438, Awali, Bahrain. zbysfedorowicz@gmail.com.

Editorial group: Cochrane Eyes and Vision Group.
Publication status and date: New search for studies and content updated (no change to conclusions), published in Issue 11, 2015.

Citation: Lawrence D, Fedorowicz Z, van Zuuren EJ. Day care versus in-patient surgery for age-related cataract. *Cochrane Database of Systematic Reviews* 2015, Issue 11. Art. No.: CD004242. DOI: 10.1002/14651858.CD004242.pub5.

Copyright © 2015 The Cochrane Collaboration. Published by John Wiley & Sons, Ltd.

ABSTRACT

Background

Age-related cataract accounts for more than 40% of cases of blindness in the world with the majority of people who are blind from cataract living in lower income countries. With the increased number of people with cataract, it is important to review the evidence on the effectiveness of day care cataract surgery.

Objectives

To provide authoritative, reliable evidence regarding the safety, feasibility, effectiveness and cost-effectiveness of day case cataract extraction by comparing clinical outcomes, cost-effectiveness, patient satisfaction or a combination of these in cataract operations performed in day care versus in-patient units.

Search methods

We searched CENTRAL (which contains the Cochrane Eyes and Vision Group Trials Register) (2015, Issue 7), Ovid MEDLINE, Ovid MEDLINE In-Process and Other Non-Indexed Citations, Ovid MEDLINE Daily, Ovid OLDMEDLINE (January 1946 to August 2015), EMBASE (January 1980 to August 2015), Latin American and Caribbean Health Sciences Literature Database (LILACS) (January 1982 to August 2015), the ISRCTN registry (www.isrctn.com/editAdvancedSearch), ClinicalTrials.gov (www.clinicaltrials.gov) and the World Health Organization (WHO) International Clinical Trials Registry Platform (ICTRP) (www.who.int/ictrp/search/en). We did not use any date or language restrictions in the electronic searches for trials. We last searched the electronic databases on 17 August 2015.

Selection criteria

We included randomised controlled trials comparing day care and in-patient surgery for age-related cataract. The primary outcome was the achievement of a satisfactory visual acuity six weeks after the operation.

Data collection and analysis

Two review authors independently assessed trial quality and extracted data. We contacted study authors for additional information. We collected adverse effects information from the trials.

Copyright © 2015 The Cochrane Collaboration. Published by John Wiley & Sons, Ltd.

[Intervention Review]

Submacular surgery for choroidal neovascularisation secondary to age-related macular degeneration

Fabrizio Giansanti[1], Chiara M Eandi[2], Gianni Virgili[1]

[1]Department of Neuro-Oto-Ophthalmological Surgical Sciences, Eye Clinic, University of Florence, Florence, Italy. [2]Department of Clinical Physiopathology, Eye Clinic, University of Torino, Torino, Italy

Contact address: Fabrizio Giansanti, Department of Neuro-Oto-Ophthalmological Surgical Sciences, Eye Clinic, University of Florence, Via le Morgagni 85, Florence, 50134, Italy. fabrizio.giansanti@unifi.it.

Editorial group: Cochrane Eyes and Vision Group.
Publication status and date: New, published in Issue 2, 2009.
Review content assessed as up-to-date: 10 February 2009.

Citation: Giansanti F, Eandi CM, Virgili G. Submacular surgery for choroidal neovascularisation secondary to age-related macular degeneration. *Cochrane Database of Systematic Reviews* 2009, Issue 2. Art. No.: CD006931. DOI: 10.1002/14651858.CD006931.pub2.

Copyright © 2009 The Cochrane Collaboration. Published by John Wiley & Sons, Ltd.

ABSTRACT

Background

Vitreoretinal surgeons proposed submacular surgery to remove the fibrovascular tissue causing damage to the centre of the retina, in the attempt to limit central visual loss in people affected by neovascular age-related macular degeneration (AMD).

Objectives

This review aims at assessing the effectiveness of submacular surgery for preserving or improving vision in patients with AMD.

Search methods

We searched CENTRAL, MEDLINE, EMBASE and LILACS. There were no language or date restrictions in the search for trials. The electronic databases were last searched on 11 February 2009.

Selection criteria

We included randomised or quasi-randomised controlled trials comparing submacular surgery with any other treatment or observation.

Data collection and analysis

Two authors independently extracted the data. The risk ratio (RR) of visual loss and visual gain was estimated at one year.

Main results

Two multicentre studies with a similar design were conducted between 1997 and 2003 and compared submacular surgery with observation in people affected by subfoveal neovascular AMD with (n=336) or without (n=454) extensive blood in the macula. At one year there was high quality evidence of no benefit for preventing visual loss (RR: 0.96; 95% confidence interval (CI): 0.84 to 1.09). No difference could be demonstrated regarding the chance of visual gain (RR: 1.06; 95% CI: 0.75 to 1.51), although this evidence was of low quality because of imprecision. The risk difference was -2% (95% CI: -10% to 5%) and 1% (95% CI: -4% to 6%) for visual loss and visual gain, respectively, thus excluding a large benefit with surgery in terms of absolute risk in this sample. There was high quality evidence that cataract needing surgery (RR: 8.69; 95% CI: 4.06 to 18.61) and retinal detachment (RR: 6.13; 95% CI: 2.81 to 13.38) were more common among operated patients, and detachment occurred in 5% of patients with no extensive blood and in 18% of those with extensive blood beneath the macula.

Copyright © 2009 The Cochrane Collaboration. Published by John Wiley & Sons, Ltd.

8.5. Apêndice *5*. *Abstracts* das revisões sistemáticas da Colaboração Cochrane com desfechos que não demosntraram evidências para a intervenção, com recomendação de novos estudos **(C1)**.

[Intervention Review]

Acupuncture for acute hordeolum

Ke Cheng[1], Andrew Law[2], Menghu Guo[1], L. Susan Wieland[3], Xueyong Shen[4], Lixing Lao[5]

[1]School of Acupuncture-Moxibustion and Tuina, Shanghai University of Traditional Chinese Medicine, Shanghai, China. [2]Department of Epidemiology, Johns Hopkins Bloomberg School of Public Health, Baltimore, Maryland, USA. [3]Center for Integrative Medicine, University of Maryland School of Medicine, Baltimore, Maryland, USA. [4]School of Acupuncture-Moxibustion and Tuina, Shanghai University of Traditional Chinese Medicine, Shanghai Research Center of Acupuncture & Meridians, Shanghai Key Laboratory of acupuncture mechanism and acupoint function, Shanghai, China. [5]School of Chinese Medicine, The University of Hong Kong, Hong Kong, China

Contact address: Xueyong Shen, School of Acupuncture-Moxibustion and Tuina, Shanghai University of Traditional Chinese Medicine, Shanghai Research Center of Acupuncture & Meridians, Shanghai Key Laboratory of acupuncture mechanism and acupoint function, 1200, Cailun RD, Shanghai, 201203, China. snowysh@hotmail.com.

Editorial group: Cochrane Eyes and Vision Group.
Publication status and date: New, published in Issue 2, 2017.

Citation: Cheng K, Law A, Guo M, Wieland LS, Shen X, Lao L. Acupuncture for acute hordeolum. *Cochrane Database of Systematic Reviews* 2017, Issue 2. Art. No.: CD011075. DOI: 10.1002/14651858.CD011075.pub2.

Copyright © 2017 The Cochrane Collaboration. Published by John Wiley & Sons, Ltd.

ABSTRACT

Background

Hordeolum is an acute, purulent inflammation of the eyelid margin usually caused by obstructed orifices of the sebaceous glands of the eyelid. The condition, which affects sebaceous glands internally or externally, is common. When the meibomian gland in the tarsal plate is affected, internal hordeolum occurs, while when the glands of Zeis or Moll associated with eyelash follicles are affected, external hordeolum, or stye occurs. The onset of hordeolum is usually self limited, and may resolve in about a week with spontaneous drainage of the abscess. When the condition is severe, it can spread to adjacent glands and tissues. Recurrences are very common. As long as an internal hordeolum remains unresolved, it can develop into a chalazion or generalized eyelid cellulitis. Acupuncture is a traditional Chinese medical therapy aimed to treat disease by using fine needles to stimulate specific points on the body. However, it is unclear if acupuncture is an effective and safe treatment for acute hordeolum.

Objectives

The objective of this review was to investigate the effectiveness and safety of acupuncture to treat acute hordeolum compared with no treatment, sham acupuncture, or other active treatment. We also compared the effectiveness and safety of acupuncture plus another treatment with that treatment alone.

Search methods

We searched CENTRAL, Ovid MEDLINE, Ovid MEDLINE In-Process and Other Non-Indexed Citations, Ovid MEDLINE Daily, Ovid OLDMEDLINE, Embase, PubMed, Latin American and Caribbean Health Sciences Literature Database (LILACS), three major Chinese databases, as well as clinical trial registers all through 7 June 2016. We reviewed the reference lists from potentially eligible studies to identify additional randomised clinical trials (RCTs).

Selection criteria

We included RCTs of people diagnosed with acute internal or external hordeola. We included RCTs comparing acupuncture with sham acupuncture or no treatment, other active treatments, or comparing acupuncture plus another treatment versus another treatment alone.

Copyright © 2017 The Cochrane Collaboration. Published by John Wiley & Sons, Ltd.

[Intervention Review]

Acupuncture for slowing the progression of myopia in children and adolescents

Mao Ling Wei[1], Jian Ping Liu[2], Ni Li[3], Ming Liu[4]

[1]Chinese Cochrane Centre, Chinese Evidence-Based Medicine Centre, West China Hospital, Sichuan University, Chengdu, China. [2]Centre for Evidence-Based Chinese Medicine, Beijing University of Chinese Medicine, Beijing, China. [3]Department of Ophthalmology, West China Hospital, Sichuan University, Chengdu, China. [4]Department of Neurology, West China Hospital, Sichuan University, Chengdu, China

Contact address: Mao Ling Wei, Chinese Cochrane Centre, Chinese Evidence-Based Medicine Centre, West China Hospital, Sichuan University, No. 37, Guo Xue Xiang, Chengdu, Sichuan, 610041, China. maolingwei@hotmail.com.

Editorial group: Cochrane Eyes and Vision Group.
Publication status and date: New, published in Issue 9, 2011.

Citation: Wei ML, Liu JP, Li N, Liu M. Acupuncture for slowing the progression of myopia in children and adolescents. *Cochrane Database of Systematic Reviews* 2011, Issue 9. Art. No.: CD007842. DOI: 10.1002/14651858.CD007842.pub2.

Copyright © 2011 The Cochrane Collaboration. Published by John Wiley & Sons, Ltd.

ABSTRACT

Background

Myopia (near-sightedness or short-sightedness) is one of the three commonly detected refractive (focusing) errors. Acupuncture is the stimulation of acupuncture points by various methods including needle insertion and acupressure. It is often used by traditional Chinese medicine practitioners to treat myopia in children.

Objectives

To assess the effectiveness and safety of acupuncture in slowing the progression of myopia in children and adolescents.

Search methods

We searched CENTRAL (which contains the Cochrane Eyes and Vision Group Trials Register) (*The Cochrane Library* 2011, Issue 7), MEDLINE (January 1950 to July 2011), EMBASE (January 1980 to July 2011), the Allied and Complementary Medicine Database (AMED) (January 1985 to July 2011), Latin American and Caribbean Health Sciences Literature Database (LILACS) (January 1982 to July 2011), the *meta*Register of Controlled Trials (*m*RCT) (www.controlled-trials.com), ClinicalTrials.gov (www.clinicaltrial.gov), the National Center for Complementary and Alternative Medicine (NCCAM) (The first issue to August 2010), the Chinese Biological Medicine Database (CBM) (1978 to April 2011), China National Knowledge Infrastructure (CNKI) (1994 to April 2011) and VIP (1989 to April 2011). There were no date or language restrictions in the electronic searches for trials. CENTRAL, MEDLINE, EMBASE, AMED, LILACS, *m*RCT and ClinicalTrials.gov were last searched on 9 July 2011. NCCAM was searched up to August 2010 and CBM, CNKI, and VIP were last searched on 6 April 2011.

Selection criteria

We included randomized controlled trials (RCTs) that included any type of acupuncture treatment for myopia in children and adolescents.

Data collection and analysis

Two authors independently evaluated the search results according to the inclusion and exclusion criteria. Two authors extracted and assessed data independently. We contacted the study investigator for missing data.

Copyright © 2011 The Cochrane Collaboration. Published by John Wiley & Sons, Ltd.

[Intervention Review]

Adjustable versus non-adjustable sutures for strabismus

Shoaib Hassan[1], Anjana Haridas[2], Venki Sundaram[3]

[1]University Hospital of Wales, Cardiff, UK. [2]Cardiff, UK. [3]St Albans, UK

Contact address: Anjana Haridas, Cardiff, UK. anjana@doctors.org.uk.

Editorial group: Cochrane Eyes and Vision Group.
Publication status and date: New search for studies and content updated (no change to conclusions), published in Issue 3, 2018.

Citation: Hassan S, Haridas A, Sundaram V. Adjustable versus non-adjustable sutures for strabismus. *Cochrane Database of Systematic Reviews* 2018, Issue 3. Art. No.: CD004240. DOI: 10.1002/14651858.CD004240.pub4.

Copyright © 2018 The Cochrane Collaboration. Published by John Wiley & Sons, Ltd.

ABSTRACT

Background

Strabismus, or squint, can be defined as a deviation from perfect ocular alignment and can be classified in many ways according to its aetiology and presentation. Treatment can be broadly divided into medical and surgical options, with a variety of surgical techniques being available, including the use of adjustable or non-adjustable sutures for the extraocular muscles. There exists an uncertainty as to which of these techniques produces a better surgical outcome, and an opinion that the adjustable suture technique may be of greater benefit in certain situations.

Objectives

To determine if either an adjustable suture or non-adjustable suture technique is associated with a more accurate long-term ocular alignment and to identify specific situations in which it would be of benefit to use a particular method.

Search methods

We searched the Cochrane Central Register of Controlled Trials (CENTRAL) (which contains the Cochrane Eyes and Vision Trials Register) (2017, Issue 5); Ovid MEDLINE; Ovid Embase; LILACS; the ISRCTN registry; ClinicalTrials.gov and the ICTRP. The date of the search was 13 June 2017. We contacted experts in the field for further information.

Selection criteria

We included only randomised controlled trials (RCTs) comparing adjustable to non-adjustable sutures for strabismus surgery.

Data collection and analysis

We used standard procedures recommended by Cochrane. Two review authors independently screened search results and extracted data. We graded the certainty of the evidence using the GRADE approach.

Main results

We identified one RCT comparing adjustable and non-adjustable sutures in primary horizontal strabismus surgeries in 60 children aged less than 12 years in Egypt. The study was not masked and we judged it at high risk of detection bias. Ocular alignment was defined as orthophoria or a horizontal tropia of 8 prism dioptres (PD) or less at near and far distances. At six months, there may be a small increased chance of ocular alignment with adjustable sutures compared with non-adjustable sutures clinically, however, the confidence intervals (CIs) were wide and were compatible with an increased chance of ocular alignment in the non-adjustable sutures group, so there was no statistical difference (risk ratio (RR) 1.18, 95% CI 0.91 to 1.53). We judged this to be low-certainty evidence, downgrading for imprecision and risk of bias. At six months, 730 per 1000 children in the non-adjustable sutures group had ocular alignment. The study authors reported that there were no complications during surgery. The trials did not assess patient satisfaction and resource use and costs.

Copyright © 2018 The Cochrane Collaboration. Published by John Wiley & Sons, Ltd.

[Intervention Review]

Anti-vascular endothelial growth factor (VEGF) drugs for treatment of retinopathy of prematurity

Mari Jeeva Sankar[1], Jhuma Sankar[2], Parijat Chandra[3]

[1]Newborn Health Knowledge Centre, WHO Collaborating Centre for Training and Research in Newborn Care, Department of Pediatrics, All India Institute of Medical Sciences, Delhi, India. [2]Department of Pediatrics, All India Institute of Medical Sciences, New Delhi, India. [3]Dr. R. P. Centre for Ophthalmic Sciences, All India Institute of Medical Sciences (AIIMS), New Delhi, India

Contact address: Mari Jeeva Sankar, Newborn Health Knowledge Centre, WHO Collaborating Centre for Training and Research in Newborn Care, Department of Pediatrics, All India Institute of Medical Sciences, Delhi, India. jeevasankar@gmail.com.

Editorial group: Cochrane Neonatal Group.
Publication status and date: New search for studies and content updated (conclusions changed), published in Issue 1, 2018.

Citation: Sankar MJ, Sankar J, Chandra P. Anti-vascular endothelial growth factor (VEGF) drugs for treatment of retinopathy of prematurity. *Cochrane Database of Systematic Reviews* 2018, Issue 1. Art. No.: CD009734. DOI: 10.1002/14651858.CD009734.pub3.

Copyright © 2018 The Cochrane Collaboration. Published by John Wiley & Sons, Ltd.

ABSTRACT

Background

Vascular endothelial growth factor (VEGF) plays a key role in angiogenesis in foetal life. Researchers have recently attempted to use anti-VEGF agents for the treatment of retinopathy of prematurity (ROP), a vasoproliferative disorder. The safety and efficacy of these agents in preterm infants with ROP is currently uncertain.

Objectives

To evaluate the efficacy and safety of anti-VEGF drugs when used either as monotherapy, that is without concomitant cryotherapy or laser therapy, or in combination with planned cryo/laser therapy in preterm infants with type 1 ROP (defined as zone I any stage with plus disease, zone I stage 3 with or without plus disease, or zone II stage 2 or 3 with plus disease).

Search methods

We searched the Cochrane Central Register of Controlled Trials (CENTRAL 2016, Issue 11), MEDLINE (1966 to 11 December 2016), Embase (1980 to 11 December 2016), CINAHL (1982 to 11 December 2016), and conference proceedings.

Selection criteria

Randomised or quasi-randomised controlled trials that evaluated the efficacy or safety of administration, or both, of anti-VEGF agents compared with conventional therapy in preterm infants with ROP.

Data collection and analysis

We used standard Cochrane and Cochrane Neonatal methods for data collection and analysis. We used the GRADE approach to assess the quality of the evidence.

Main results

Six trials involving a total of 383 infants fulfilled the inclusion criteria. Five trials compared intravitreal bevacizumab (n = 4) or ranibizumab (n = 1) with conventional laser therapy (monotherapy), while the sixth study compared intravitreal pegaptanib plus conventional laser therapy with laser/cryotherapy (combination therapy).

Copyright © 2018 The Cochrane Collaboration. Published by John Wiley & Sons, Ltd.

[Intervention Review]

Anti-vascular endothelial growth factor for control of wound healing in glaucoma surgery

Jin-Wei Cheng[1], Shi-Wei Cheng[2], Rui-Li Wei[1], Guo-Cai Lu[3]

[1]Department of Ophthalmology, Shanghai Changzheng Hospital, Second Military Medical University, Shanghai, China. [2]School of Life Sciences, Ludong University, Yantai, China. [3]Center for New Drug Evaluation, Second Military Medical University, Shanghai, China

Contact address: Jin-Wei Cheng, Department of Ophthalmology, Shanghai Changzheng Hospital, Second Military Medical University, 415 Fengyang Road, Shanghai, 200003, China. jinnwave@163.com.

Editorial group: Cochrane Eyes and Vision Group.
Publication status and date: New, published in Issue 1, 2016.

Citation: Cheng JW, Cheng SW, Wei RL, Lu GC. Anti-vascular endothelial growth factor for control of wound healing in glaucoma surgery. *Cochrane Database of Systematic Reviews* 2016, Issue 1. Art. No.: CD009782. DOI: 10.1002/14651858.CD009782.pub2.

Copyright © 2016 The Cochrane Collaboration. Published by John Wiley & Sons, Ltd.

ABSTRACT

Background

Trabeculectomy is performed as a treatment for glaucoma to lower intraocular pressure (IOP). The surgical procedure involves creating a channel through the wall of the eye. However scarring during wound healing can block this channel which will lead to the operation failing. Anti-vascular endothelial growth factor (VEGF) agents have been proposed to slow down healing response and scar formation.

Objectives

To assess the effectiveness of anti-VEGF therapies administered by subconjunctival injection for the outcome of trabeculectomy at 12 months follow-up and to examine the balance of benefit and harms when compared to any other anti-scarring agents or no additional anti-scarring agents.

Search methods

We searched CENTRAL (which contains the Cochrane Eyes and Vision Trials Register) (2015, Issue 10), Ovid MEDLINE, Ovid MEDLINE In-Process and Other Non-Indexed Citations, Ovid MEDLINE Daily, Ovid OLDMEDLINE (January 1946 to November 2015), EMBASE (January 1980 to November 2015), the ISRCTN registry (www.isrctn.com/editAdvancedSearch), ClinicalTrials.gov (www.clinicaltrials.gov) and the World Health Organization (WHO) International Clinical Trials Registry Platform (ICTRP) (www.who.int/ictrp/search/en). We did not use any date or language restrictions in the electronic searches for trials. We last searched the electronic databases on 12 November 2015.

Selection criteria

We included randomised controlled trials (RCTs) of anti-VEGF therapies administered by subconjunctival injection compared to any other anti-scarring agents or no additional anti-scarring agents (no treatment or placebo) in trabeculectomy surgery.

Data collection and analysis

We used standard methodological procedures expected by Cochrane. Our primary outcome was successful trabeculectomy at 12 months after surgery which was defined as achieving a target IOP (usually no more than 21 mm Hg) without any additional intervention. Other outcomes included: qualified success (achieving target IOP with or without additional intervention), mean IOP and adverse events.

[Intervention Review]

Anti-vascular endothelial growth factor for neovascular glaucoma

Arathi Simha[1], Andrew Braganza[1], Lekha Abraham[1], Prasanna Samuel[2], Kristina Lindsley[3]

[1]Department of Ophthalmology, Christian Medical College, Vellore, India. [2]Department of Biostatistics, Christian Medical College, Vellore, India. [3]Department of Epidemiology, Johns Hopkins Bloomberg School of Public Health, Baltimore, Maryland, USA

Contact address: Arathi Simha, Department of Ophthalmology, Christian Medical College, Vellore, 632001, India. arathisimha@rediffmail.com.

Editorial group: Cochrane Eyes and Vision Group.
Publication status and date: New, published in Issue 10, 2013.
Review content assessed as up-to-date: 11 January 2013.

Citation: Simha A, Braganza A, Abraham L, Samuel P, Lindsley K. Anti-vascular endothelial growth factor for neovascular glaucoma. *Cochrane Database of Systematic Reviews* 2013, Issue 10. Art. No.: CD007920. DOI: 10.1002/14651858.CD007920.pub2.

Copyright © 2013 The Cochrane Collaboration. Published by John Wiley & Sons, Ltd.

ABSTRACT

Background

Neovascular glaucoma (NVG) is a potentially blinding secondary glaucoma. It is caused by the formation of abnormal new blood vessels which prevent normal drainage of aqueous from the anterior segment of the eye. Anti-vascular endothelial growth factor (anti-VEGF) agents are specific inhibitors of the primary mediators of neovascularization. Studies have reported the effectiveness of anti-VEGFs for the control of intraocular pressure (IOP) in NVG.

Objectives

To compare the IOP lowering effects of intraocular anti-VEGF agents to no anti-VEGF treatment, as an adjunct to existing modalities for the treatment of NVG.

Search methods

We searched CENTRAL (which contains the Cochrane Eyes and Vision Group Trials Register) (*The Cochrane Library* 2012, Issue 12), Ovid MEDLINE, Ovid MEDLINE In-Process and Other Non-Indexed Citations, Ovid MEDLINE Daily, Ovid OLDMEDLINE, (January 1950 to January 2013), EMBASE (January 1980 to January 2013), Latin American and Caribbean Literature on Health Sciences (LILACS) (January 1982 to January 2013), the *meta*Register of Controlled Trials (*m*RCT) (www.controlled-trials.com), ClinicalTrials.gov (www.clinicaltrials.gov/) and the WHO International Clinical Trials Registry Platform (ICTRP) (www.who.int/ictrp/search/en). We did not use any date or language restrictions in the electronic searches for trials. We last searched the electronic databases on 11 January 2013.

Selection criteria

We included randomized controlled trials (RCTs) and quasi-RCTs of people treated with anti-VEGF agents for NVG.

Data collection and analysis

Two authors independently assessed the search results for trials to be included in the review. Discrepancies were resolved by discussion with a third author. Since no trial met our inclusion criteria, no assessment of risk of bias or meta-analysis was undertaken.

Copyright © 2013 The Cochrane Collaboration. Published by John Wiley & Sons, Ltd.

[Intervention Review]

Anti-vascular endothelial growth factor for choroidal neovascularisation in people with pathological myopia

Ying Zhu[1], Ting Zhang[2], Gezhi Xu[2], Lijun Peng[3]

[1]Department of Ophthalmology, Xiangya Hospital, Central South University, Changsha, China. [2]Department of Ophthalmology, Eye and Ear Nose Throat Hospital, Shanghai Medical School, Fudan University, Shanghai, China. [3]Department of Gastroenterology, Linyi People's Hospital affiliated to Shandong University, Linyi, China

Contact address: Ting Zhang, Department of Ophthalmology, Eye and Ear Nose Throat Hospital, Shanghai Medical School, Fudan University, No. 83, Fenyang Road, Shanghai, 200032, China. tina-chang07@163.com.

Editorial group: Cochrane Eyes and Vision Group.
Publication status and date: New, published in Issue 12, 2016.

Citation: Zhu Y, Zhang T, Xu G, Peng L. Anti-vascular endothelial growth factor for choroidal neovascularisation in people with pathological myopia. *Cochrane Database of Systematic Reviews* 2016, Issue 12. Art. No.: CD011160. DOI: 10.1002/14651858.CD011160.pub2.

Copyright © 2016 The Cochrane Collaboration. Published by John Wiley & Sons, Ltd.

ABSTRACT

Background

Choroidal neovascularisation (CNV) is a common complication of pathological myopia. Once developed, most eyes with myopic CNV (mCNV) experience a progression to macular atrophy, which leads to irreversible vision loss. Anti-vascular endothelial growth factor (anti-VEGF) therapy is used to treat diseases characterised by neovascularisation and is increasingly used to treat mCNV.

Objectives

To assess the effects of anti-vascular endothelial growth factor (anti-VEGF) therapy for choroidal neovascularisation (CNV), compared with other treatments, sham treatment or no treatment, in people with pathological myopia.

Search methods

We searched a number of electronic databases including CENTRAL and Ovid MEDLINE, ClinicalTrials.gov and the World Health Organization (WHO) International Clinical Trials Registry Platform ICTRP). We did not use any date or language restrictions in the electronic searches for trials. Electronic databases were last searched on 16 June 2016.

Selection criteria

We included randomised controlled trials (RCTs) and quasi-RCTs comparing anti-VEGF therapy with another treatment (e.g. photodynamic therapy (PDT) with verteporfin, laser photocoagulation, macular surgery, another anti-VEGF), sham treatment or no treatment in participants with mCNV.

Data collection and analysis

We used standard methodological procedures expected by Cochrane. Two authors independently screened records, extracted data, and assessed risk of bias. We contacted trial authors for additional data. We analysed outcomes as risk ratios (RRs) or mean differences (MDs). We graded the certainty of the evidence using GRADE.

Copyright © 2016 The Cochrane Collaboration. Published by John Wiley & Sons, Ltd.

[Intervention Review]

Antioxidant vitamin and mineral supplements for preventing age-related macular degeneration

Jennifer R Evans[1], John G Lawrenson[2]

[1]Cochrane Eyes and Vision, ICEH, London School of Hygiene & Tropical Medicine, London, UK. [2]Centre for Applied Vision Research, School of Health Sciences, City University of London, London, UK

Contact address: Jennifer R Evans, Cochrane Eyes and Vision, ICEH, London School of Hygiene & Tropical Medicine, Keppel Street, London, WC1E 7HT, UK. jennifer.evans@lshtm.ac.uk.

Editorial group: Cochrane Eyes and Vision Group.
Publication status and date: Edited (no change to conclusions), published in Issue 7, 2017.

Citation: Evans JR, Lawrenson JG. Antioxidant vitamin and mineral supplements for preventing age-related macular degeneration. *Cochrane Database of Systematic Reviews* 2017, Issue 7. Art. No.: CD000253. DOI: 10.1002/14651858.CD000253.pub4.

Copyright © 2017 The Cochrane Collaboration. Published by John Wiley & Sons, Ltd.

ABSTRACT

Background

There is inconclusive evidence from observational studies to suggest that people who eat a diet rich in antioxidant vitamins (carotenoids, vitamins C, and E) or minerals (selenium and zinc) may be less likely to develop age-related macular degeneration (AMD).

Objectives

To determine whether or not taking antioxidant vitamin or mineral supplements, or both, prevent the development of AMD.

Search methods

We searched the Cochrane Central Register of Controlled Trials (CENTRAL) (which contains the Cochrane Eyes and Vision Trials Register) (2017, Issue 2), MEDLINE Ovid (1946 to 29 March 2017), Embase Ovid (1947 to 29 March 2017), AMED (Allied and Complementary Medicine Database) (1985 to 29 March 2017), OpenGrey (System for Information on Grey Literature in Europe) (www.opengrey.eu/); searched 29 March 2017, the ISRCTN registry (www.isrctn.com/editAdvancedSearch); searched 29 March 2017, ClinicalTrials.gov (www.clinicaltrials.gov); searched 29 March 2017 and the WHO International Clinical Trials Registry Platform (ICTRP) (www.who.int/ictrp/search/en); searched 29 March 2017. We did not use any date or language restrictions in the electronic searches for trials.

Selection criteria

We included all randomised controlled trials (RCTs) comparing an antioxidant vitamin or mineral supplement (alone or in combination) to control.

Data collection and analysis

Both review authors independently assessed risk of bias in the included studies and extracted data. One author entered data into RevMan 5; the other author checked the data entry. We pooled data using a fixed-effect model. We graded the certainty of the evidence using GRADE.

[Intervention Review]

Aqueous shunts for glaucoma

Victoria L Tseng[1], Anne L Coleman[1], Melinda Y Chang[1], Joseph Caprioli[1]

[1]Stein Eye Institute, UCLA, Los Angeles, California, USA

Contact address: Victoria L Tseng, Stein Eye Institute, UCLA, 100 Stein Plaza, Los Angeles, California, 90025, USA. tseng@jsei.ucla.edu.

Editorial group: Cochrane Eyes and Vision Group.
Publication status and date: New search for studies and content updated (conclusions changed), published in Issue 7, 2017.

Citation: Tseng VL, Coleman AL, Chang MY, Caprioli J. Aqueous shunts for glaucoma. *Cochrane Database of Systematic Reviews* 2017, Issue 7. Art. No.: CD004918. DOI: 10.1002/14651858.CD004918.pub3.

Copyright © 2017 The Cochrane Collaboration. Published by John Wiley & Sons, Ltd.

ABSTRACT

Background

Aqueous shunts are employed to control intraocular pressure (IOP) for people with primary or secondary glaucomas who fail or are not candidates for standard surgery.

Objectives

To assess the effectiveness and safety of aqueous shunts for reducing IOP in glaucoma compared with standard surgery, another type of aqueous shunt, or modification to the aqueous shunt procedure.

Search methods

We searched CENTRAL (which contains the Cochrane Eyes and Vision Trials Register) (2016, Issue 8), MEDLINE Ovid (1946 to August 2016), Embase.com (1947 to August 2016), PubMed (1948 to August 2016), LILACS (Latin American and Caribbean Health Sciences Literature Database) (1982 to August 2016), ClinicalTrials.gov (www.clinicaltrials.gov); searched 15 August 2016, and the World Health Organization (WHO) International Clinical Trials Registry Platform (ICTRP) (www.who.int/ictrp/search/en); searched 15 August 2016. We did not use any date or language restrictions in the electronic search for trials. We last searched the electronic databases on 15 August 2016. We also searched the reference lists of identified trial reports and the Science Citation Index to find additional trials.

Selection criteria

We included randomized controlled trials that compared various types of aqueous shunts with standard surgery or to each other in eyes with glaucoma.

Data collection and analysis

Two review authors independently screened search results for eligibility, assessed the risk of bias, and extracted data from included trials. We contacted trial investigators when data were unclear or not reported. We graded the certainty of the evidence using the GRADE approach. We followed standard methods as recommended by Cochrane.

Main results

We included 27 trials with a total of 2099 participants with mixed diagnoses and comparisons of interventions. Seventeen studies reported adequate methods of randomization, and seven reported adequate allocation concealment. Data collection and follow-up times varied.

Copyright © 2017 The Cochrane Collaboration. Published by John Wiley & Sons, Ltd.

[Intervention Review]

Artificial corneas versus donor corneas for repeat corneal transplants

Esen K Akpek[1], Majed Alkharashi[2], Frank S Hwang[3], Sueko M Ng[4], Kristina Lindsley[4]

[1]Wilmer Eye Institute, Johns Hopkins University School of Medicine, Baltimore, MD, USA. [2]Department of Ophthalmology, King Saud University, Riyadh, Saudi Arabia. [3]Cornea, External Disease and Refractive Surgery, Kresge Eye Institute, Detroit, Michigan, USA. [4]Department of Epidemiology, Johns Hopkins Bloomberg School of Public Health, Baltimore, Maryland, USA

Contact address: Esen K Akpek, Wilmer Eye Institute, Johns Hopkins University School of Medicine, 600 N. Wolfe Street, Maumenee #317, Baltimore, MD, 21287, USA. esakpek@jhmi.edu.

Editorial group: Cochrane Eyes and Vision Group.
Publication status and date: New, published in Issue 11, 2014.
Review content assessed as up-to-date: 27 November 2013.

Citation: Akpek EK, Alkharashi M, Hwang FS, Ng SM, Lindsley K. Artificial corneas versus donor corneas for repeat corneal transplants. *Cochrane Database of Systematic Reviews* 2014, Issue 11. Art. No.: CD009561. DOI: 10.1002/14651858.CD009561.pub2.

Copyright © 2014 The Cochrane Collaboration. Published by John Wiley & Sons, Ltd.

ABSTRACT

Background

Individuals who have failed one or more full thickness penetrating keratoplasties (PKs) may be offered repeat corneal surgery using an artificial or donor cornea. An artificial or prosthetic cornea is known as a keratoprosthesis. Both donor and artificial corneal transplantations involve removal of the diseased and opaque recipient cornea (or the previously failed cornea) and replacement with another donor or prosthetic cornea.

Objectives

To assess the effectiveness of artificial versus donor corneas in individuals who have had one or more failed donor corneal transplantations.

Search methods

We searched CENTRAL (which contains the Cochrane Eyes and Vision Group Trials Register) (2013, Issue 10), Ovid MEDLINE, Ovid MEDLINE In-Process and Other Non-Indexed Citations, Ovid MEDLINE Daily, Ovid OLDMEDLINE (January 1946 to November 2013), EMBASE (January 1980 to November 2013), Latin American and Caribbean Health Sciences Literature Database (LILACS) (January 1982 to November 2013), the *meta*Register of Controlled Trials (*m*RCT) (www.controlled-trials.com), ClinicalTrials.gov (www.clinicaltrials.gov) and the World Health Organization (WHO) International Clinical Trials Registry Platform (ICTRP) (www.who.int/ictrp/search/en). We did not use any date or language restrictions in the electronic searches for trials. We last searched the electronic databases on 27 November 2013.

Selection criteria

Two review authors independently assessed reports from the electronic searches to identify randomized controlled trials (RCTs) or controlled clinical trials (CCTs). We resolved discrepancies by discussion or consultation with a third review author.

Data collection and analysis

For discussion purposes, we assessed findings from observational cohort studies and non-comparative case series. No data synthesis was performed.

[Intervention Review]

Blue-light filtering intraocular lenses (IOLs) for protecting macular health

Laura E Downie[1], Ljoudmila Busija[2], Peter R Keller[1]

[1]Department of Optometry and Vision Sciences, The University of Melbourne, Parkville, Australia. [2]Institute for Health and Ageing, Australian Catholic University, Melbourne, Australia

Contact address: Laura E Downie, Department of Optometry and Vision Sciences, The University of Melbourne, Level 4, Alice Hoy Building, Parkville, Victoria, 3010, Australia. ldownie@unimelb.edu.au.

Editorial group: Cochrane Eyes and Vision Group.
Publication status and date: New, published in Issue 5, 2018.

Citation: Downie LE, Busija L, Keller PR. Blue-light filtering intraocular lenses (IOLs) for protecting macular health. *Cochrane Database of Systematic Reviews* 2018, Issue 5. Art. No.: CD011977. DOI: 10.1002/14651858.CD011977.pub2.

Copyright © 2018 The Cochrane Collaboration. Published by John Wiley & Sons, Ltd.

ABSTRACT

Background

An intraocular lens (IOL) is a synthetic lens that is surgically implanted within the eye following removal of the crystalline lens, during cataract surgery. While all modern IOLs attenuate the transmission of ultra-violet (UV) light, some IOLs, called blue-blocking or blue-light filtering IOLs, also reduce short-wavelength visible light transmission. The rationale for blue-light filtering IOLs derives primarily from cell culture and animal studies, which suggest that short-wavelength visible light can induce retinal photoxicity. Blue-light filtering IOLs have been suggested to impart retinal protection and potentially prevent the development and progression of age-related macular degeneration (AMD). We sought to investigate the evidence relating to these suggested benefits of blue-light filtering IOLs, and to consider any potential adverse effects.

Objectives

To assess the effects of blue-light filtering IOLs compared with non-blue-light filtering IOLs, with respect to providing protection to macular health and function.

Search methods

We searched the Cochrane Central Register of Controlled Trials (CENTRAL) (which contains the Cochrane Eyes and Vision Trials Register) (2017, Issue 9); Ovid MEDLINE; Ovid Embase; LILACS; the ISRCTN registry; ClinicalTrials.gov and the ICTRP. The date of the search was 25 October 2017.

Selection criteria

We included randomised controlled trials (RCTs), involving adult participants undergoing cataract extraction, where a blue-light filtering IOL was compared with an equivalent non-blue-light filtering IOL.

Data collection and analysis

The prespecified primary outcome was the change in distance best-corrected visual acuity (BCVA), as a continuous outcome, between baseline and 12 months of follow-up. Prespecified secondary outcomes included postoperative contrast sensitivity, colour discrimination, macular pigment optical density (MPOD), proportion of eyes with a pathological finding at the macula (including, but not limited to the development or progression of AMD, or both), daytime alertness, reaction time and patient satisfaction. We evaluated findings related to ocular and systemic adverse effects.

Copyright © 2018 The Cochrane Collaboration. Published by John Wiley & Sons, Ltd.

[Intervention Review]

Aspirin as adjunctive treatment for giant cell arteritis

Susan P Mollan[1], Noor Sharrack[2], Mike A Burdon[1], Alastair K Denniston[1,3]

[1]Ophthalmology Department, University Hospitals Birmingham NHS Trust, Queen Elizabeth Hospital, Birmingham, UK. [2]Medical School, University of Birmingham, Edgbaston, UK. [3]Academic Unit of Ophthalmology, University of Birmingham, Birmingham and Midland Eye Centre, Birmingham, UK

Contact address: Susan P Mollan, Ophthalmology Department, University Hospitals Birmingham NHS Trust, Queen Elizabeth Hospital, Birmingham, UK. soozmollan@doctors.org.uk.

Editorial group: Cochrane Eyes and Vision Group.
Publication status and date: New, published in Issue 8, 2014.
Review content assessed as up-to-date: 24 January 2014.

Citation: Mollan SP, Sharrack N, Burdon MA, Denniston AK. Aspirin as adjunctive treatment for giant cell arteritis. *Cochrane Database of Systematic Reviews* 2014, Issue 8. Art. No.: CD010453. DOI: 10.1002/14651858.CD010453.pub2.

Copyright © 2014 The Cochrane Collaboration. Published by John Wiley & Sons, Ltd.

ABSTRACT

Background

Giant cell arteritis (GCA) is a common inflammatory condition that affects medium and large-sized arteries and can cause sudden, permanent blindness. At present there is no alternative to early treatment with high-dose corticosteroids as the recommended standard management. Corticosteroid-induced side effects can develop and further disease-related ischaemic complications can still occur. Alternative and adjunctive therapies are sought. Aspirin has been shown to have effects on the immune-mediated inflammation in GCA, hence it may reduce damage caused in the arterial wall.

Objectives

To assess the safety and effectiveness of low-dose aspirin, as an adjunctive, in the treatment of giant cell arteritis (GCA).

Search methods

We searched CENTRAL (which contains the Cochrane Eyes and Vision Group Trials Register) (2013, Issue 12), Ovid MEDLINE, Ovid MEDLINE In-Process and Other Non-Indexed Citations, Ovid MEDLINE Daily, Ovid OLDMEDLINE (January 1946 to January 2014), EMBASE (January 1980 to January 2014), Latin American and Caribbean Health Sciences Literature Database (LILACS) (January 1982 to January 2014), the *meta*Register of Controlled Trials (*m*RCT) (www.controlled-trials.com), ClinicalTrials.gov (www.clinicaltrials.gov), the World Health Organization (WHO) International Clinical Trials Registry Platform (ICTRP) (www.who.int/ictrp/search/en) and the US Food and Drugs Administration (FDA) web site (www.fda.gov). We did not use any date or language restrictions in the electronic searches for trials. We last searched the electronic databases on 24 January 2014.

Selection criteria

We planned to include only randomised controlled trials (RCTs) comparing outcomes of GCA with and without concurrent adjunctive use of low-dose aspirin.

Data collection and analysis

Two authors independently assessed the search results for trials identified by the electronic searches. No trials met our inclusion criteria, therefore we undertook no assessment of risk of bias or meta-analysis.

Copyright © 2014 The Cochrane Collaboration. Published by John Wiley & Sons, Ltd.

[Intervention Review]

Assistive technology for children and young people with low vision

Rachel Thomas[1], Lucy Barker[2], Gary Rubin[3], Annegret Dahlmann-Noor[4]

[1]Optometry, Moorfields at Bedford Hospital, Bedford, UK. [2]Moorfields Eye Hospital NHS Foundation Trust, London, UK. [3]Institute of Ophthalmology, London, UK. [4]NIHR Biomedical Research Centre at Moorfields Eye Hospital NHS Foundation Trust and UCL Institute of Ophthalmology, London, UK

Contact address: Rachel Thomas, Optometry, Moorfields at Bedford Hospital, Kempston Road, Bedford, MK42 9DJ, UK. rachel.thomas@bedfordhospital.nhs.uk.

Editorial group: Cochrane Eyes and Vision Group.
Publication status and date: New, published in Issue 6, 2015.

Citation: Thomas R, Barker L, Rubin G, Dahlmann-Noor A. Assistive technology for children and young people with low vision. *Cochrane Database of Systematic Reviews* 2015, Issue 6. Art. No.: CD011350. DOI: 10.1002/14651858.CD011350.pub2.

Copyright © 2015 The Cochrane Collaboration. Published by John Wiley & Sons, Ltd.

ABSTRACT

Background

Recent technological developments, such as the near universal spread of mobile phones and portable computers and improvements in the accessibility features of these devices, give children and young people with low vision greater independent access to information. Some electronic technologies, such as closed circuit TV, are well established low vision aids and newer versions, such as electronic readers or off-the shelf tablet computers, may offer similar functionalities with easier portability and at lower cost.

Objectives

To assess the effect of electronic assistive technologies on reading, educational outcomes and quality of life in children and young people with low vision.

Search methods

We searched CENTRAL (which contains the Cochrane Eyes and Vision Group Trials Register) (2014, Issue 9), Ovid MEDLINE, Ovid MEDLINE In-Process and Other Non-Indexed Citations, Ovid MEDLINE Daily, Ovid OLDMEDLINE (January 1946 to October 2014), EMBASE (January 1980 to October 2014), the Health Technology Assessment Programme (HTA) (www.hta.ac.uk/), the *meta*Register of Controlled Trials (*m*RCT) (www.controlled-trials.com), ClinicalTrials.gov (www.clinicaltrials.gov) and the World Health Organization (WHO) International Clinical Trials Registry Platform (ICTRP) (www.who.int/ictrp/search/en). We did not use any date or language restrictions in the electronic searches for trials. We last searched the electronic databases on 30 October 2014.

Selection criteria

We intended to include randomised controlled trials (RCTs) and quasi-RCTs in this review. We planned to include trials involving children between the ages of 5 and 16 years with low vision as defined by, or equivalent to, the WHO 1992 definition of low vision. We planned to include studies that explore the use of assistive technologies (ATs). These could include all types of closed circuit television/electronic vision enhancement systems (CCTV/EVES), computer technology including tablet computers and adaptive technologies such as screen readers, screen magnification and optical character recognition (OCR). We intended to compare the use of ATs with standard optical aids, which include distance refractive correction (with appropriate near addition for aphakic (no lens)/pseudophakic (with lens implant) patients) and monocular/binoculars for distance and brightfield magnifiers for near. We also planned to include studies that compare different types of ATs with each other, without or in addition to conventional optical aids, and those that compare ATs given with or without instructions for use.

Copyright © 2015 The Cochrane Collaboration. Published by John Wiley & Sons, Ltd.

[Intervention Review]

Botulinum toxin for the treatment of strabismus

Fiona J Rowe[1], Carmel P Noonan[2]

[1]Department of Health Services Research, University of Liverpool, Liverpool, UK. [2]Department of Ophthalmology, Aintree University Hospitals NHS Foundation Trust, Liverpool, UK

Contact address: Fiona J Rowe, Department of Health Services Research, University of Liverpool, Waterhouse Building (B211), 1-3 Brownlow Street, Liverpool, L69 3GL, UK. rowef@liverpool.ac.uk.

Editorial group: Cochrane Eyes and Vision Group.
Publication status and date: New search for studies and content updated (no change to conclusions), published in Issue 3, 2017.

Citation: Rowe FJ, Noonan CP. Botulinum toxin for the treatment of strabismus. *Cochrane Database of Systematic Reviews* 2017, Issue 3. Art. No.: CD006499. DOI: 10.1002/14651858.CD006499.pub4.

Copyright © 2017 The Cochrane Collaboration. Published by John Wiley & Sons, Ltd.

ABSTRACT

Background

The use of botulinum toxin as an investigative and treatment modality for strabismus is well reported in the medical literature. However, it is unclear how effective it is in comparison to other treatment options for strabismus.

Objectives

The primary objective was to examine the efficacy of botulinum toxin therapy in the treatment of strabismus compared with alternative conservative or surgical treatment options. This review sought to ascertain those types of strabismus that particularly benefit from the use of botulinum toxin as a treatment option (such as small angle strabismus or strabismus with binocular potential, i.e. the potential to use both eyes together as a pair). The secondary objectives were to investigate the dose effect and complication rates associated with botulinum toxin.

Search methods

We searched CENTRAL (which contains the Cochrane Eyes and Vision Trials Register) (2016, Issue 6), Ovid MEDLINE, Ovid MEDLINE In-Process and Other Non-Indexed Citations, Ovid MEDLINE Daily, Ovid OLDMEDLINE (January 1946 to July 2016), Embase (January 1980 to July 2016), Latin American and Caribbean Literature on Health Sciences (LILACS) (January 1982 to July 2016), the ISRCTN registry (www.isrctn.com/editAdvancedSearch), ClinicalTrials.gov (www.clinicaltrials.gov), and the World Health Organization (WHO) International Clinical Trials Registry Platform (ICTRP) (www.who.int/ictrp/search/en). We did not use any date or language restrictions in the electronic searches for trials. We last searched the electronic databases on 11 July 2016. We handsearched the British and Irish Orthoptic Journal, Australian Orthoptic Journal, proceedings of the European Strabismological Association (ESA), International Strabismological Association (ISA) and International Orthoptic Association (IOA) (www.liv.ac.uk/orthoptics/research/search.htm) and American Academy of Paediatric Ophthalmology and Strabismus meetings (AAPOS). We contacted researchers who are active in this field for information about further published or unpublished studies.

Selection criteria

We included randomised controlled trials (RCTS) of any use of botulinum toxin treatment for strabismus.

Data collection and analysis

Two review authors independently selected studies and extracted data. We used standard methods expected by Cochrane and assessed the certainty of the evidence using GRADE. We defined ocular alignment as an angle of deviation of less than or equal to 10 prism dioptres.

Copyright © 2017 The Cochrane Collaboration. Published by John Wiley & Sons, Ltd.

[Intervention Review]

Surgery for cataracts in people with age-related macular degeneration

Heather Casparis[1], Kristina Lindsley[2], Irene C Kuo[3], Shameema Sikder[4], Neil M Bressler[4]

[1]Private practice, Ophthalmology, Via Antonio Ciseri 13, CH-6600 Locarno, Switzerland. [2]Department of Epidemiology, Johns Hopkins Bloomberg School of Public Health, Baltimore, Maryland, USA. [3] Department of Ophthalmology, Wilmer Eye Institute, Johns Hopkins University School of Medicine, Baltimore, Maryland, USA. [4]Wilmer Ophthalmological Institute, Johns Hopkins University School of Medicine, Baltimore, Maryland, USA

Contact address: Heather Casparis, Private practice, Ophthalmology, Via Antonio Ciseri 13, CH-6600 Locarno, Switzerland. studiocasparis@gmail.com.

Editorial group: Cochrane Eyes and Vision Group.
Publication status and date: New search for studies and content updated (no change to conclusions), published in Issue 2, 2017.

Citation: Casparis H, Lindsley K, Kuo IC, Sikder S, Bressler NM. Surgery for cataracts in people with age-related macular degeneration. *Cochrane Database of Systematic Reviews* 2017, Issue 2. Art. No.: CD006757. DOI: 10.1002/14651858.CD006757.pub4.

Copyright © 2017 The Cochrane Collaboration. Published by John Wiley & Sons, Ltd.

ABSTRACT

Background

Cataract and age-related macular degeneration (AMD) are common causes of decreased vision that often occur simultaneously in people over age 50. Although cataract surgery is an effective treatment for cataract-induced visual loss, some clinicians suspect that such an intervention may increase the risk of worsening of underlying AMD and thus have deleterious effects on vision.

Objectives

The objective of this review was to evaluate the effectiveness and safety of cataract surgery compared with no surgery in eyes with AMD.

Search methods

We searched CENTRAL (which contains the Cochrane Eyes and Vision Trials Register) (2016, Issue 11), Ovid MEDLINE, Epub Ahead of Print, In-Process & Other Non-Indexed Citations, Ovid MEDLINE Daily (January 1946 to December 2016), Embase (January 1980 to December 2016), Latin American and Caribbean Literature on Health Sciences (LILACS) (January 1982 to December 2016), the ISRCTN registry (www.isrctn.com/editAdvancedSearch), ClinicalTrials.gov (www.clinicaltrials.gov), and the World Health Organization (WHO) International Clinical Trials Registry Platform (ICTRP) (www.who.int/ictrp/search/en). We did not use any date or language restrictions in the electronic searches for trials. We last searched the electronic databases on 2 December 2016.

Selection criteria

We included randomized controlled trials (RCTs) and quasi-randomized trials that enrolled participants whose eyes were affected by both cataract and AMD in which cataract surgery was compared with no surgery.

Data collection and analysis

Two review authors independently evaluated the search results against the inclusion and exclusion criteria. Two review authors independently extracted data, assessed risk of bias for included studies, and graded the certainty of evidence. We followed methods as recommended by Cochrane.

[Intervention Review]

Community screening for visual impairment in older people

Emily L Clarke[1,2], Jennifer R Evans[3], Liam Smeeth[4]

[1]Leeds Teaching Hospitals NHS Trust, Leeds, UK. [2]University of Leeds, Leeds, UK. [3]Cochrane Eyes and Vision, ICEH, London School of Hygiene & Tropical Medicine, London, UK. [4]Faculty of Epidemiology and Population Health, London School of Hygiene & Tropical Medicine, London, UK

Contact address: Emily L Clarke, Leeds Teaching Hospitals NHS Trust, Leeds, UK. e.l.clarke@leeds.ac.uk.

Editorial group: Cochrane Eyes and Vision Group.
Publication status and date: New search for studies and content updated (no change to conclusions), published in Issue 2, 2018.

Citation: Clarke EL, Evans JR, Smeeth L. Community screening for visual impairment in older people. *Cochrane Database of Systematic Reviews* 2018, Issue 2. Art. No.: CD001054. DOI: 10.1002/14651858.CD001054.pub3.

Copyright © 2018 The Cochrane Collaboration. Published by John Wiley & Sons, Ltd.

ABSTRACT

Background

Visual problems in older people are common and frequently under-reported. The effects of poor vision in older people are wide reaching and include falls, confusion and reduced quality of life. Much of the visual impairment in older ages can be treated (e.g. cataract surgery, correction of refractive error). Vision screening may therefore reduce the number of older people living with sight loss.

Objectives

The objective of this review was to assess the effects on vision of community vision screening of older people for visual impairment.

Search methods

We searched the Cochrane Central Register of Controlled Trials (CENTRAL) (which contains the Cochrane Eyes and Vision Trials Register) (2017, Issue 10); Ovid MEDLINE; Ovid Embase; the ISRCTN registry; ClinicalTrials.gov and the ICTRP. The date of the search was 23 November 2017.

Selection criteria

We included randomised controlled trials (RCTs) that compared vision screening alone or as part of a multi-component screening package as compared to no vision screening or standard care, on the vision of people aged 65 years or over in a community setting. We included trials that used self-reported visual problems or visual acuity testing as the screening tool.

Data collection and analysis

We used standard methods expected by Cochrane. We graded the certainty of the evidence using GRADE.

Main results

Visual outcome data were available for 10,608 people in 10 trials. Four trials took place in the UK, two in Australia, two in the United States and two in the Netherlands. Length of follow-up ranged from one to five years. Three of these studies were cluster-randomised trials whereby general practitioners or family physicians were randomly allocated to undertake vision screening or no vision screening. All studies were funded by government agencies. Overall we judged the studies to be at low risk of bias and only downgraded the certainty of the evidence (GRADE) for imprecision.

Seven trials compared vision screening as part of a multi-component screening versus no screening. Six of these studies used self-reported vision as both screening tool and outcome measure, but did not directly measure vision. One study used a combination of self-

Copyright © 2018 The Cochrane Collaboration. Published by John Wiley & Sons, Ltd.

[Intervention Review]

Types of intraocular lenses for cataract surgery in eyes with uveitis

Theresa G Leung[1], Kristina Lindsley[2], Irene C Kuo[3]

[1]The Wilmer Eye Institute, Johns Hopkins University School of Medicine, Baltimore, MD, USA. [2]Department of Epidemiology, Johns Hopkins Bloomberg School of Public Health, Baltimore, Maryland, USA. [3]Department of Ophthalmology, Wilmer Eye Institute, Johns Hopkins University School of Medicine, Baltimore, Maryland, USA

Contact address: Kristina Lindsley, Department of Epidemiology, Johns Hopkins Bloomberg School of Public Health, 615 North Wolfe Street, W5010, Baltimore, Maryland, 21205, USA. klindsle@jhsph.edu.

Editorial group: Cochrane Eyes and Vision Group.
Publication status and date: New, published in Issue 3, 2014.
Review content assessed as up-to-date: 14 August 2013.

Citation: Leung TG, Lindsley K, Kuo IC. Types of intraocular lenses for cataract surgery in eyes with uveitis. *Cochrane Database of Systematic Reviews* 2014, Issue 3. Art. No.: CD007284. DOI: 10.1002/14651858.CD007284.pub2.

Copyright © 2014 The Cochrane Collaboration. Published by John Wiley & Sons, Ltd.

ABSTRACT

Background

Cataract formation often occurs in people with uveitis. It is unclear which intraocular lens (IOL) type is optimal for use in cataract surgery for eyes with uveitis.

Objectives

To summarize the effects of different IOLs on visual acuity, other visual outcomes, and quality of life in people with uveitis.

Search methods

We searched CENTRAL (which contains the Cochrane Eyes and Vision Group Trials Register) (*The Cochrane Library* 2013, Issue 7), Ovid MEDLINE, Ovid MEDLINE In-Process and Other Non-Indexed Citations, Ovid MEDLINE Daily, Ovid OLDMEDLINE (January 1946 to August 2013), EMBASE (January 1980 to August 2013), Latin American and Caribbean Literature on Health Sciences (LILACS) (January 1982 to August 2013), the *meta*Register of Controlled Trials (*m*RCT) (www.controlled-trials.com), ClinicalTrials.gov (www.clinicaltrials.gov) and the WHO International Clinical Trials Registry Platform (ICTRP) (www.who.int/ictrp/search/en). We did not use any date or language restrictions in the electronic searches for trials. We last searched the electronic databases on 14 August 2013. We also performed forward and backward searching using the Science Citation Index and the reference lists of the included studies, respectively, in August 2013.

Selection criteria

We included randomized controlled trials (RCTs) comparing hydrophobic or hydrophilic acrylic, silicone, or poly(methyl methacrylate) (PMMA) IOLs with or without heparin-surface modification (HSM), with each other, or with no treatment in adults with uveitis, for any indication, undergoing cataract surgery.

Data collection and analysis

We used standard methodological procedures expected by The Cochrane Collaboration. Two review authors screened the search results and for included studies, assessed the risk of bias and extracted data independently. We contacted study investigators for additional information. We did not perform a meta-analysis due to variability in reporting and follow-up intervals for the primary and secondary outcomes of interest.

Copyright © 2014 The Cochrane Collaboration. Published by John Wiley & Sons, Ltd.

[Intervention Review]

Complement inhibitors for age-related macular degeneration

Michael A Williams[1], Gareth J McKay[2], Usha Chakravarthy[3]

[1]Medical Ophthalmology, Eye and Ear Clinic, Royal Victoria Hospital, Belfast, UK. [2]Centre for Public Health, Queen's University Belfast, Belfast, UK. [3]Centre for Vision and Vascular Science, Queen's University Belfast, Belfast, UK

Contact address: Michael A Williams, Medical Ophthalmology, Eye and Ear Clinic, Royal Victoria Hospital, Grosvenor Road, Belfast, Northern Ireland, BT12 6BA, UK. m.williams@qub.ac.uk.

Editorial group: Cochrane Eyes and Vision Group.
Publication status and date: New, published in Issue 1, 2014.
Review content assessed as up-to-date: 21 November 2013.

Citation: Williams MA, McKay GJ, Chakravarthy U. Complement inhibitors for age-related macular degeneration. *Cochrane Database of Systematic Reviews* 2014, Issue 1. Art. No.: CD009300. DOI: 10.1002/14651858.CD009300.pub2.

Copyright © 2014 The Cochrane Collaboration. Published by John Wiley & Sons, Ltd.

ABSTRACT

Background

Given the relatively high prevalence of age-related macular degeneration (AMD) and the increased incidence of AMD as populations age, the results of trials of novel treatments are awaited with much anticipation. The complement cascade describes a series of proteolytic reactions occurring throughout the body that generate proteins with a variety of roles including the initiation and promotion of immune reactions against foreign materials or micro-organisms. The complement cascade is normally tightly regulated, but much evidence implicates complement overactivity in AMD and so it is a logical therapeutic target in the treatment of AMD.

Objectives

To assess the effects and safety of complement inhibitors in the prevention or treatment of advanced AMD.

Search methods

We searched CENTRAL (which contains the Cochrane Eyes and Vision Group Trials Register) (*The Cochrane Library* 2013, Issue 11), Ovid MEDLINE, Ovid MEDLINE In-Process and Other Non-Indexed Citations, Ovid MEDLINE Daily, Ovid OLDMEDLINE (January 1946 to November 2013), EMBASE (January 1980 to November 2013), Allied and Complementary Medicine Database (AMED) (January 1985 to November 2013), Latin American and Caribbean Literature on Health Sciences (LILACS) (January 1982 to November 2013), OpenGrey (System for Information on Grey Literature in Europe) (www.opengrey.eu/), Web of Science Conference Proceedings Citation Index - Science (CPCI-S) (January 1990 to November 2013), the *meta*Register of Controlled Trials (*m*RCT) (www.controlled-trials.com), ClinicalTrials.gov (www.clinicaltrials.gov) and the WHO International Clinical Trials Registry Platform (ICTRP) (www.who.int/ictrp/search/en). We did not use any date or language restrictions in the electronic searches for trials. We last searched the electronic databases on 21 November 2013. We also performed handsearching of proceedings, from 2012 onwards, of meetings and conferences of specific professional organisations.

Selection criteria

We planned to include randomised controlled trials (RCTs) with parallel treatment groups which investigated either the prevention or treatment of advanced AMD by inhibition of the complement cascade.

Data collection and analysis

Two authors (MW and GMcK) independently evaluated all the titles and abstracts resulting from the searches. We contacted companies running clinical trials which had not yet reported results to request information. Since no trials met our inclusion criteria, we undertook no assessment of quality or meta-analysis.

Copyright © 2014 The Cochrane Collaboration. Published by John Wiley & Sons, Ltd.

[Intervention Review]

Corneal collagen cross-linking for treating keratoconus

Evripidis Sykakis[1], Rushmia Karim[2], Jennifer R Evans[3], Catey Bunce[4], Kwesi N Amissah-Arthur[5], Showrob Patwary[5], Peter J McDonnell[5], Samer Hamada[1]

[1]Corneoplastic Unit and Eye Bank, Queen Victoria Hospital, East Grinstead, UK. [2]Moorfields Eye Hospital NHS Foundation Trust, London, UK. [3]Cochrane Eyes and Vision Group, ICEH, London School of Hygiene & Tropical Medicine, London, UK. [4]Research and Development Department, Moorfields Eye Hospital NHS Foundation Trust, London, UK. [5]Birmingham and Midland Eye Centre, Birmingham, UK

Contact address: Samer Hamada, Corneoplastic Unit and Eye Bank, Queen Victoria Hospital, East Grinstead, UK. samer.hamada@qvh.nhs.uk.

Editorial group: Cochrane Eyes and Vision Group.
Publication status and date: New, published in Issue 3, 2015.

Citation: Sykakis E, Karim R, Evans JR, Bunce C, Amissah-Arthur KN, Patwary S, McDonnell PJ, Hamada S. Corneal collagen cross-linking for treating keratoconus. *Cochrane Database of Systematic Reviews* 2015, Issue 3. Art. No.: CD010621. DOI: 10.1002/14651858.CD010621.pub2.

Copyright © 2015 The Cochrane Collaboration. Published by John Wiley & Sons, Ltd.

ABSTRACT

Background

Keratoconus is a condition of the eye that affects approximately 1 in 2000 people. The disease leads to a gradual increase in corneal curvature and decrease in visual acuity with consequent impact on quality of life. Collagen cross-linking (CXL) with ultraviolet A (UVA) light and riboflavin (vitamin B_2) is a relatively new treatment that has been reported to slow or halt the progression of the disease in its early stages.

Objectives

The objective of this review was to assess whether there is evidence that CXL is an effective and safe treatment for halting the progression of keratoconus compared to no treatment.

Search methods

We searched the Cochrane Central Register of Controlled Trials (CENTRAL; 2014, Issue 7), Ovid MEDLINE, Ovid MEDLINE In-Process and Other Non-Indexed Citations, Ovid MEDLINE Daily, Ovid OLDMEDLINE (January 1946 to August 2014), EMBASE (January 1980 to August 2014), Latin American and Caribbean Health Sciences Literature Database (LILACS) (1982 to August 2014), Cumulative Index to Nursing and Allied Health Literature (CINAHL) (1982 to August 2014), OpenGrey (System for Information on Grey Literature in Europe) (www.opengrey.eu/), the *meta*Register of Controlled Trials (*m*RCT) (www.controlled-trials.com), ClinicalTrials.gov (www.clinicaltrials.gov) and the World Health Organisation International Clinical Trials Registry Platform (ICTRP) (www.who.int/ictrp/search/en). We used no date or language restrictions in the electronic searches for trials. We last searched the electronic databases on 28 August 2014.

Selection criteria

We included randomised controlled trials (RCTs) where CXL with UVA light and riboflavin was used to treat people with keratoconus and was compared to no treatment.

[Intervention Review]

Topical corticosteroids as adjunctive therapy for bacterial keratitis

Samantha Herretes[1], Xue Wang[2], Johann MG Reyes[3,4]

[1]Department of Ophthalmology, Bascom Palmer Eye Institute, University of Miami School of Medicine, Miami, Florida, USA. [2]Department of Epidemiology, Johns Hopkins Bloomberg School of Public Health, Baltimore, Maryland, USA. [3]Department of Ophthalmology, The Medical City, Pasig City, Philippines. [4]Department of Ophthalmology and Visual Sciences, University of the Philippines, Philippine General Hospital, Manila, Philippines

Contact address: Samantha Herretes, Department of Ophthalmology, Bascom Palmer Eye Institute, University of Miami School of Medicine, 11010 NW 30th St. Ste 104, Miami, Florida, 33172, USA. sherretes@gmail.com.

Editorial group: Cochrane Eyes and Vision Group.
Publication status and date: New search for studies and content updated (no change to conclusions), published in Issue 10, 2014.
Review content assessed as up-to-date: 14 July 2014.

Citation: Herretes S, Wang X, Reyes JMG. Topical corticosteroids as adjunctive therapy for bacterial keratitis. *Cochrane Database of Systematic Reviews* 2014, Issue 10. Art. No.: CD005430. DOI: 10.1002/14651858.CD005430.pub3.

Copyright © 2014 The Cochrane Collaboration. Published by John Wiley & Sons, Ltd.

ABSTRACT

Background

Bacterial keratitis is a serious ocular infectious disease that can lead to severe visual disability. Risk factors for bacterial corneal infection include contact lens wear, ocular surface disease, corneal trauma, and previous ocular or eyelid surgery. Topical antibiotics constitute the mainstay of treatment in cases of bacterial keratitis, whereas the use of topical corticosteroids as an adjunctive therapy to antibiotics remains controversial. Topical corticosteroids are usually used to control inflammation using the smallest amount of the drug. Their use requires optimal timing, concomitant antibiotics, and careful follow-up.

Objectives

The objective of the review was to assess the effectiveness and safety of corticosteroids as adjunctive therapy for bacterial keratitis. Secondary objectives included evaluation of health economic outcomes and quality of life outcomes.

Search methods

We searched CENTRAL (which contains the Cochrane Eyes and Vision Group Trials Register) (2014, Issue 6), Ovid MEDLINE, Ovid MEDLINE In-Process and Other Non-Indexed Citations, Ovid MEDLINE Daily, Ovid OLDMEDLINE (January 1946 to July 2014), EMBASE (January 1980 to July 2014), Latin American and Caribbean Health Sciences Literature Database (LILACS) (January 1982 to July 2014), the *meta*Register of Controlled Trials (*m*RCT) (www.controlled-trials.com), ClinicalTrials.gov (www.clinicaltrials.gov) and the World Health Organization (WHO) International Clinical Trials Registry Platform (ICTRP) (www.who.int/ictrp/search/en). We did not use any date or language restrictions in the electronic searches for trials. We last searched the electronic databases on 14 July 2014. We also searched the Science Citation Index to identify additional studies that had cited the only trial included in the original version of this review, reference lists of included trials, earlier reviews, and the American Academy of Ophthalmology guidelines. We also contacted experts to identify any unpublished and ongoing randomized trials.

Selection criteria

We included randomized controlled trials (RCTs) that had evaluated adjunctive therapy with topical corticosteroids in people with bacterial keratitis who were being treated with antibiotics.

Copyright © 2014 The Cochrane Collaboration. Published by John Wiley & Sons, Ltd.

[Intervention Review]

Corticosteroids as adjuvant therapy for ocular toxoplasmosis

Smitha Jasper[1], Satyanarayana S Vedula[2], Sheeja S John[1], Saban Horo[1], Yasir J Sepah[3], Quan Dong Nguyen[3]

[1]Department of Ophthalmology, Christian Medical College, Vellore, India. [2]Johns Hopkins University, Baltimore, Maryland, USA. [3]Byers Eye Institute, Stanford University, Palo Alto, California, USA

Contact address: Quan Dong Nguyen, Byers Eye Institute, Stanford University, Palo Alto, California, USA. ndquan@stanford.edu.

Editorial group: Cochrane Eyes and Vision Group.
Publication status and date: New search for studies and content updated (no change to conclusions), published in Issue 1, 2017.

Citation: Jasper S, Vedula SS, John SS, Horo S, Sepah YJ, Nguyen QD. Corticosteroids as adjuvant therapy for ocular toxoplasmosis. *Cochrane Database of Systematic Reviews* 2017, Issue 1. Art. No.: CD007417. DOI: 10.1002/14651858.CD007417.pub3.

Copyright © 2017 The Cochrane Collaboration. Published by John Wiley & Sons, Ltd.

ABSTRACT

Background

Ocular infection caused by *Toxoplasma gondii*, a parasite, may result in inflammation in the retina, choroid, and uvea, and consequently lead to complications such as glaucoma, cataract, and posterior synechiae.

Objectives

The objective of this systematic review was to assess the effects of adjunctive use of corticosteroids to anti-parasitic therapy versus anti-parasitic therapy alone for ocular toxoplasmosis.

Search methods

We searched CENTRAL (which contains the Cochrane Eyes and Vision Trials Register (2016; Issue 11)), MEDLINE Ovid, Epub Ahead of Print, In-Process & Other Non-Indexed Citations, MEDLINE Ovid Daily (January 1946 to December 2016), Embase (January 1980 to December 2016), Latin American and Caribbean Literature on Health Sciences (LILACS (January 1982 to December 2016)), the ISRCTN registry (www.isrctn.com/editAdvancedSearch), ClinicalTrials.gov (www.clinicaltrials.gov), and the World Health Organization (WHO) International Clinical Trials Registry Platform (ICTRP; www.who.int/ictrp/search/en). We used no date or language restrictions in the electronic searches for trials. We last searched the electronic databases on 7 December 2016.

Selection criteria

We had planned to include randomized and quasi-randomized controlled trials. Eligible trials would have enrolled participants of any age who were immunocompetent and were diagnosed with acute ocular toxoplasmosis. Included trials would have compared anti-parasitic therapy plus corticosteroids versus anti-parasitic therapy alone, different doses or times of initiation of corticosteroids.

Data collection and analysis

Two authors independently screened titles and abstracts retrieved through the electronic searches. We retrieved full-text reports of studies categorized as 'unsure' or 'include' after we reviewed the abstracts. Two authors independently reviewed each full-text report for eligibility. Discrepancies were resolved through discussion.

Main results

We identified no completed or ongoing trial that was eligible for this Cochrane review.

Copyright © 2017 The Cochrane Collaboration. Published by John Wiley & Sons, Ltd.

[Intervention Review]

Corticosteroids for treating optic neuritis

Robin L Gal[1], Satyanarayana S Vedula[2], Roy Beck[1]

[1]Jaeb Center for Health Research, Tampa, Florida, USA. [2]Johns Hopkins University, Baltimore, Maryland, USA

Contact address: Robin L Gal, Jaeb Center for Health Research, 15310 Amberley Drive, Suite 350, Tampa, Florida, 33647, USA. rgal@jaeb.org.

Editorial group: Cochrane Eyes and Vision Group.
Publication status and date: New search for studies and content updated (no change to conclusions), published in Issue 8, 2015.

Citation: Gal RL, Vedula SS, Beck R. Corticosteroids for treating optic neuritis. *Cochrane Database of Systematic Reviews* 2015, Issue 8. Art. No.: CD001430. DOI: 10.1002/14651858.CD001430.pub4.

Copyright © 2015 The Cochrane Collaboration. Published by John Wiley & Sons, Ltd.

ABSTRACT

Background

Optic neuritis is an inflammatory disease of the optic nerve. It usually presents with an abrupt loss of vision and recovery of vision is almost never complete. It occurs more commonly in women than in men. Closely linked in pathogenesis, optic neuritis may be the initial manifestation for multiple sclerosis. In some people, no underlying cause can be found.

Objectives

The objective of this review was to assess the effects of corticosteroids on visual recovery in eyes with acute optic neuritis.

Search methods

We searched CENTRAL (which contains the Cochrane Eyes and Vision Group Trials Register) (*The Cochrane Library* 2015, Issue 4), MEDLINE (January 1950 to April 2015), EMBASE (January 1980 to April 2015), Latin American and Caribbean Health Sciences Literature (LILACS) (January 1982 to April 2015), PubMed (January 1946 to April 2015), the *meta*Register of Controlled Trials (*m*RCT) (www.controlled-trials.com), ClinicalTrials.gov (www.clinicaltrials.gov), and the World Health Organization (WHO) International Clinical Trials Registry Platform (ICTRP) (www.who.int/ictrp/search/en). There were no date or language restrictions in the electronic searches for trials. The *meta*Register of Controlled Trials (*m*RCT) was last searched on 6 March 2014. The electronic databases were last searched on 7 April 2015. We also searched reference lists of identified trial reports for additional trials.

Selection criteria

We included randomized controlled trials (RCTs) that evaluated systemic corticosteroids, in any form, dose or route of administration, in people with acute optic neuritis.

Data collection and analysis

We used standard methodological procedures expected by Cochrane.

Main results

We included six RCTs with a total of 750 participants. Each trial was conducted in a different country: Denmark, Germany, India, Japan, UK, and United States. Additionally, we identified two ongoing trials not due to be completed until 2016. Among the six trials included in this review, we judged one to be at high risk of bias. The remaining five trials were judged to be at either low or uncertain risk of biases.

Five trials compared only two intervention groups and one trial had a three-arm comparison of oral corticosteroids or intravenous corticosteroids with placebo. Of the five trials with only two intervention groups, two trials compared oral corticosteroids versus placebo,

Copyright © 2015 The Cochrane Collaboration. Published by John Wiley & Sons, Ltd.

[Intervention Review]

D-Penicillamine for preventing retinopathy of prematurity in preterm infants

Mosarrat J Qureshi[1], Manoj Kumar[2]

[1]Pediatrics, Royal Alexandra Hospital, University of Alberta, Edmonton, Canada. [2]Department of Pediatrics, University of Alberta, Edmonton, Canada

Contact address: Mosarrat J Qureshi, Pediatrics, Royal Alexandra Hospital, University of Alberta, Edmonton, Alberta, T5H 3V9, Canada. Mosarrat.Qureshi@albertahealthservices.ca.

Editorial group: Cochrane Neonatal Group.
Publication status and date: New search for studies and content updated (no change to conclusions), published in Issue 9, 2013.
Review content assessed as up-to-date: 27 May 2013.

Citation: Qureshi MJ, Kumar M. D-Penicillamine for preventing retinopathy of prematurity in preterm infants. *Cochrane Database of Systematic Reviews* 2013, Issue 9. Art. No.: CD001073. DOI: 10.1002/14651858.CD001073.pub2.

Copyright © 2013 The Cochrane Collaboration. Published by John Wiley & Sons, Ltd.

ABSTRACT

Background

The rate of retinopathy of prematurity (ROP) in moderately premature infants has decreased dramatically with improved care in the neonatal intensive care unit. A low rate of this disorder was unexpectedly observed among infants treated with intravenous D-penicillamine to prevent hyperbilirubinaemia. This observation led to the investigation of its use, both enterally as well as intravenously, to prevent ROP.

Objectives

To determine the effect of prophylactic administration of D-penicillamine on the incidence of acute ROP or severe ROP and other morbidities in preterm infants.

Search methods

We used the Cochrane Neonatal Review Group search strategy. Two review authors independently searched multiple electronic databases, previous reviews including cross references, abstracts, conference/symposia proceedings, and expert informants. We updated the search on November 27, 2012.

Selection criteria

We included randomised or quasi-randomised controlled trials if they administered D-penicillamine and compared it with no treatment or placebo to premature infants and reported on the outcome of ROP.

Data collection and analysis

We used the criteria and standard methods of the Cochrane Neonatal Review Group to assess the methodological quality of the included trials. One review author examined trials for validity. A second review author checked validity and they reached consensus on the final data before entry into this review. We used the standards of the Neonatal Cochrane Review Group to analyse data.

Copyright © 2013 The Cochrane Collaboration. Published by John Wiley & Sons, Ltd.

[Intervention Review]

Deep anterior lamellar keratoplasty versus penetrating keratoplasty for treating keratoconus

Miriam Keane[1], Douglas Coster[1], Mohammed Ziaei[2], Keryn Williams[1]

[1]Department of Ophthalmology, Flinders University, Adelaide, Australia. [2]Moorfields Eye Hospital NHS Foundation Trust, London, UK

Contact address: Miriam Keane, Department of Ophthalmology, Flinders University, Level 3 Flinders Medical Centre, Bedford Park, Adelaide, SA 5042, Australia. miriam.keane@flinders.edu.au.

Editorial group: Cochrane Eyes and Vision Group.
Publication status and date: New, published in Issue 7, 2014.

Citation: Keane M, Coster D, Ziaei M, Williams K. Deep anterior lamellar keratoplasty versus penetrating keratoplasty for treating keratoconus. *Cochrane Database of Systematic Reviews* 2014, Issue 7. Art. No.: CD009700. DOI: 10.1002/14651858.CD009700.pub2.

Copyright © 2014 The Cochrane Collaboration. Published by John Wiley & Sons, Ltd.

ABSTRACT

Background

Keratoconus is an ectatic (weakening) disease of the cornea, which is the clear surface at the front of the eye. Approximately 10% to 15% of patients diagnosed with keratoconus require corneal transplantation. This may be full-thickness (penetrating) or partial-thickness (lamellar).

Objectives

To compare visual outcomes after deep anterior lamellar keratoplasty (DALK) and penetrating keratoplasty for keratoconus, and to compare additional outcomes relating to factors which may contribute to poor visual outcomes (e.g. astigmatism, graft rejection and failure).

Search methods

We searched a number of electronic databases including CENTRAL, PubMed and EMBASE without using any date or language restrictions. We last searched the electronic databases on 31 October 2013. We also handsearched the proceedings of several international ophthalmic conferences.

Selection criteria

We included all randomised controlled trials (RCTs) comparing the outcomes of DALK and penetrating keratoplasty in the treatment of keratoconus.

Data collection and analysis

Two authors assessed trial quality and extracted data independently. For dichotomous data (graft failure, rejection, achievement of functional vision) results were expressed as odds ratios (ORs) and 95% confidence intervals (CIs). For continuous data (postoperative best corrected visual acuity (BCVA), uncorrected visual acuity (UCVA), keratometric astigmatism and spherical equivalent) results were expressed as mean differences (MDs) and 95% CIs.

Copyright © 2014 The Cochrane Collaboration. Published by John Wiley & Sons, Ltd.

[Intervention Review]

Endonasal versus external dacryocystorhinostomy for nasolacrimal duct obstruction

Lona Jawaheer[1], Caroline J MacEwen[2], Deepa Anijeet[1]

[1]Ophthalmology Department, Gartnavel General Hospital, Glasgow, UK. [2]Department of Ophthalmology, Ninewells University Hospital, Dundee, UK

Contact address: Lona Jawaheer, Ophthalmology Department, Gartnavel General Hospital, 1053 Great Western Road, Glasgow, G12 0YN, UK. lona_j@hotmail.com, lonajawaheer@doctors.org.uk.

Editorial group: Cochrane Eyes and Vision Group.
Publication status and date: New search for studies and content updated (no change to conclusions), published in Issue 2, 2017.

Citation: Jawaheer L, MacEwen CJ, Anijeet D. Endonasal versus external dacryocystorhinostomy for nasolacrimal duct obstruction. *Cochrane Database of Systematic Reviews* 2017, Issue 2. Art. No.: CD007097. DOI: 10.1002/14651858.CD007097.pub3.

Copyright © 2017 The Cochrane Collaboration. Published by John Wiley & Sons, Ltd.

ABSTRACT

Background

A dacryocystorhinostomy (DCR) procedure aims to restore drainage of tears by bypassing a blockage in the nasolacrimal duct, through the creation of a bony ostium that allows communication between the lacrimal sac and the nasal cavity. It can be performed using endonasal or external approaches. The comparative success rates of these two approaches have not yet been established and this review aims to evaluate the relevant up-to-date research.

Objectives

The primary aim of this review is to compare the success rates of endonasal DCR with that of external DCR. The secondary aim is to compare the complication rates between the two procedures.

Search methods

We searched CENTRAL (which contains the Cochrane Eyes and Vision Group Trials Register) (2016, Issue 8), Ovid MEDLINE, Ovid MEDLINE In-Process and Other Non-Indexed Citations, Ovid MEDLINE Daily, Ovid OLDMEDLINE (January 1946 to 22 August 2016), Embase (January 1980 to 22 August 2016), Latin American and Caribbean Health Sciences Literature Database (LILACS) (January 1982 to 22 August 2016), Web of Science Conference Proceedings Citation Index- Science (CPCI-S) (January 1990 to 22 August 2016), the ISRCTN registry (www.isrctn.com/editAdvancedSearch), ClinicalTrials.gov (www.clinicaltrials.gov) and the World Health Organization (WHO) International Clinical Trials Registry Platform (ICTRP) (www.who.int/ictrp/search/en). We did not use any date or language restrictions in the electronic searches for trials. We last searched the electronic databases on 22 August 2016. We requested or examined relevant conference proceedings for appropriate trials.

Selection criteria

We included all randomised controlled trials (RCTs) comparing endonasal and external DCRs.

Data collection and analysis

Two review authors independently assessed studies for eligibility and extracted data on reported outcomes. We attempted to contact investigators to clarify the methodological quality of the studies. We graded the certainty of the evidence using GRADE.

Copyright © 2017 The Cochrane Collaboration. Published by John Wiley & Sons, Ltd.

[Intervention Review]

Interventions for infantile esotropia

Sue Elliott[1], Ayad Shafiq[2]

[1]Ophthalmology Department, Salisbury Health Care NHS Trust, Salisbury, UK. [2]Royal Victoria Infirmary, Newcastle upon Tyne, UK

Contact address: Sue Elliott, Ophthalmology Department, Salisbury Health Care NHS Trust, Salisbury District Hospital, Salisbury, Wiltshire, SP2 8BJ, UK. sue.elliott@salisbury.nhs.uk.

Editorial group: Cochrane Eyes and Vision Group.
Publication status and date: New search for studies and content updated (no change to conclusions), published in Issue 7, 2013.
Review content assessed as up-to-date: 10 June 2013.

Citation: Elliott S, Shafiq A. Interventions for infantile esotropia. *Cochrane Database of Systematic Reviews* 2013, Issue 7. Art. No.: CD004917. DOI: 10.1002/14651858.CD004917.pub3.

Copyright © 2013 The Cochrane Collaboration. Published by John Wiley & Sons, Ltd.

ABSTRACT

Background

Infantile esotropia (IE) is the inward deviation of the eye. Various aspects of the clinical management of IE are unclear; mainly, the most effective type of intervention and the age at intervention.

Objectives

The objective of this review was to assess the effectiveness of various surgical and non-surgical interventions for IE and to determine the significance of age at treatment with respect to outcome.

Search methods

We searched CENTRAL (which contains the Cochrane Eyes and Vision Group Trials Register) (*The Cochrane Library* 2013, Issue 5), Ovid MEDLINE, Ovid MEDLINE In-Process and Other Non-Indexed Citations, Ovid MEDLINE Daily, Ovid OLDMEDLINE, (January 1950 to June 2013), EMBASE (January 1980 to June 2013), Latin American and Caribbean Literature on Health Sciences (LILACS) (January 1982 to June 2013), the *meta*Register of Controlled Trials (*m*RCT) (www.controlled-trials.com), ClinicalTrials.gov (www.clinicaltrials.gov) and the WHO International Clinical Trials Registry Platform (ICTRP) (www.who.int/ictrp/search/en). We did not use any date or language restrictions in the electronic searches for trials. We last searched the electronic databases on 10 June 2013. We manually searched the conference proceedings of the European Strabismological Association (ESA) (1975 to 1997, 1999 to 2002), International Strabismological Association (ISA) (1994) and American Academy of Paediatric Ophthalmology and Strabismus meeting (AAPOS) (1995 to 2003). Efforts were made to contact researchers who are active in the field for information about further published or unpublished studies.

Selection criteria

We included randomised trials comparing any surgical or non-surgical intervention for infantile esotropia.

Data collection and analysis

Each review author independently assessed study abstracts identified from the electronic and manual searches.

Main results

No studies were found that met our selection criteria and therefore none were included for analysis.

Copyright © 2013 The Cochrane Collaboration. Published by John Wiley & Sons, Ltd.

[Intervention Review]

Different-sized incisions for phacoemulsification in age-related cataract

Chongfei Jin[1,2,3], Xinyi Chen[1a], Andrew Law[4], Yunhee Kang[5], Xue Wang[4], Wen Xu[1], Ke Yao[1]

[1]Eye Center of the Second Affiliated Hospital, Medical College of Zhejiang University, Hangzhou, China. [2]Ophthalmic Genetics and Visual Function Branch, National Eye Institute, National Institutes of Health, Rockville, Maryland, USA. [3]Department of Internal Medicine, Brookdale University Hospital and Medical Center, Brooklyn, New York, USA. [4]Department of Epidemiology, Johns Hopkins Bloomberg School of Public Health, Baltimore, Maryland, USA. [5]International Health Department, Johns Hopkins Bloomberg School of Public Health, Baltimore, Maryland, USA

[a]The first two authors contribute equally to this paper.

Contact address: Chongfei Jin, Eye Center of the Second Affiliated Hospital, Medical College of Zhejiang University, 88 Jiefang Road, Hangzhou, 310009, China. kingbird918@hotmail.com.

Editorial group: Cochrane Eyes and Vision Group.
Publication status and date: New, published in Issue 9, 2017.

Citation: Jin C, Chen X, Law A, Kang Y, Wang X, Xu W, Yao K. Different-sized incisions for phacoemulsification in age-related cataract. *Cochrane Database of Systematic Reviews* 2017, Issue 9. Art. No.: CD010510. DOI: 10.1002/14651858.CD010510.pub2.

Copyright © 2017 The Cochrane Collaboration. Published by John Wiley & Sons, Ltd.

ABSTRACT

Background

Age-related cataract is the principal cause of blindness and visual impairment in the world. Phacoemulsification is the main surgical procedure used to treat cataract. The comparative effectiveness and safety of different-sized incisions for phacoemulsification has not been determined.

Objectives

The aim of this systematic review was to assess the effectiveness and safety of smaller versus larger incisions for phacoemulsification in age-related cataract. The primary outcome of this review was surgically induced astigmatism at three months after surgery.

Search methods

We searched the Cochrane Central Register of Controlled Trials (CENTRAL) (which contains the Cochrane Eyes and Vision Trials Register) (2016, Issue 10), MEDLINE Ovid (1946 to 28 October 2016), Embase Ovid (1947 to 28 October 2016), PubMed (1948 to 28 October 2016), LILACS (Latin American and Caribbean Health Sciences Literature Database) (1982 to 28 October 2016), the *meta*Register of Controlled Trials (*m*RCT) (www.controlled-trials.com; last searched 13 May 2013), ClinicalTrials.gov (www.clinicaltrials.gov; searched 28 October 2016), and the WHO International Clinical Trials Registry Platform (ICTRP) (www.who.int/ictrp; searched 28 October 2016). We did not use any date or language restrictions in the electronic searches for trials.

Selection criteria

We included randomized controlled trials (RCTs) comparing different-sized incisions in people with age-related cataract undergoing phacoemulsification.

Data collection and analysis

We used standard methodological procedures expected by Cochrane.

Copyright © 2017 The Cochrane Collaboration. Published by John Wiley & Sons, Ltd.

[Intervention Review]

Different lasers and techniques for proliferative diabetic retinopathy

Tanya Moutray[1], Jennifer R Evans[2], Noemi Lois[3], David J Armstrong[1], Tunde Peto[4], Augusto Azuara-Blanco[4]

[1]Ophthalmology Department, Royal Victoria Hospital, Belfast, UK. [2]Cochrane Eyes and Vision, ICEH, London School of Hygiene & Tropical Medicine, London, UK. [3]Wellcome-Wolfson Institute for Experimental Medicine, Queen's University, Belfast, UK. [4]Centre for Public Health, Queen's University Belfast, Belfast, UK

Contact address: Tanya Moutray, Ophthalmology Department, Royal Victoria Hospital, Grosvenor Road, Belfast, BT12 6BA, UK. tanya.moutray@gmail.com.

Editorial group: Cochrane Eyes and Vision Group.
Publication status and date: Edited (no change to conclusions), published in Issue 3, 2018.

Citation: Moutray T, Evans JR, Lois N, Armstrong DJ, Peto T, Azuara-Blanco A. Different lasers and techniques for proliferative diabetic retinopathy. *Cochrane Database of Systematic Reviews* 2018, Issue 3. Art. No.: CD012314. DOI: 10.1002/14651858.CD012314.pub2.

Copyright © 2018 The Cochrane Collaboration. Published by John Wiley & Sons, Ltd.

ABSTRACT

Background

Diabetic retinopathy (DR) is a chronic progressive disease of the retinal microvasculature associated with prolonged hyperglycaemia. Proliferative DR (PDR) is a sight-threatening complication of DR and is characterised by the development of abnormal new vessels in the retina, optic nerve head or anterior segment of the eye. Argon laser photocoagulation has been the gold standard for the treatment of PDR for many years, using regimens evaluated by the Early Treatment of Diabetic Retinopathy Study (ETDRS). Over the years, there have been modifications of the technique and introduction of new laser technologies.

Objectives

To assess the effects of different types of laser, other than argon laser, and different laser protocols, other than those established by the ETDRS, for the treatment of PDR. We compared different wavelengths; power and pulse duration; pattern, number and location of burns versus standard argon laser undertaken as specified by the ETDRS.

Search methods

We searched the Cochrane Central Register of Controlled Trials (CENTRAL) (which contains the Cochrane Eyes and Vision Trials Register) (2017, Issue 5); Ovid MEDLINE; Ovid Embase; LILACS; the ISRCTN registry; ClinicalTrials.gov and the ICTRP. The date of the search was 8 June 2017.

Selection criteria

We included randomised controlled trials (RCTs) of pan-retinal photocoagulation (PRP) using standard argon laser for treatment of PDR compared with any other laser modality. We excluded studies of lasers that are not in common use, such as the xenon arc, ruby or Krypton laser.

Data collection and analysis

We followed Cochrane guidelines and graded the certainty of evidence using the GRADE approach.

[Intervention Review]

Educational interventions for the prevention of eye injuries

Anupa Shah[1], Karen Blackhall[2], Katharine Ker[2], Daksha Patel[3]

[1]Cochrane Eyes and Vision Group, ICEH, London School of Health & Tropical Medicine, London, UK. [2]Cochrane Injuries Group, London School of Hygiene & Tropical Medicine, London, UK. [3]International Centre for Eye Health, London School of Hygiene & Tropical Medicine, London, UK

Contact address: Anupa Shah, Cochrane Eyes and Vision Group, ICEH, London School of Health & Tropical Medicine, Keppel Street, London, WC1E 7HT, UK. cevg@lshtm.ac.uk.

Editorial group: Cochrane Injuries Group.
Publication status and date: New, published in Issue 1, 2010.
Review content assessed as up-to-date: 6 August 2008.

Citation: Shah A, Blackhall K, Ker K, Patel D. Educational interventions for the prevention of eye injuries. *Cochrane Database of Systematic Reviews* 2009, Issue 4. Art. No.: CD006527. DOI: 10.1002/14651858.CD006527.pub3.

Copyright © 2010 The Cochrane Collaboration. Published by John Wiley & Sons, Ltd.

ABSTRACT

Background

Ocular injury is a preventable cause of blindness, yet it remains a significant disabling health problem that affects all age groups. Injuries may occur in the home, in the workplace, during recreational activities or as a result of road crashes. Types of injuries vary from closed globe (contusion or lamellar laceration) to an open globe injury, which includes penetration and even perforation of the globe. To date, the main strategy to prevent these injuries has been to educate people to identify high-risk situations and to take correct action to avoid danger.

Objectives

To assess the evidence for the effectiveness of educational interventions for the prevention of eye injuries.

Search methods

We searched the Cochrane Injuries and the Cochrane Eyes & Vision Group Specialised Registers, CENTRAL (*The Cochrane Library* 2008, Issue 3), MEDLINE, EMBASE, Current Controlled Trials *meta*Register (now includes National Research Register), AgeInfo, HMIC Health Management Information Consortium, WHOLIS (World Health Organization Library Information System), LILACS (Latin American and Caribbean Health Sciences), MEDCARIB (Caribbean Health Sciences Literature), ISI Web of Science: (*Science Citation Index Expanded (SCI-EXPANDED), Social Sciences Citation Index (SSCI) Conference Proceedings Citation Index-Science (CPCI-S)*), ERIC, ZETOC and SPORTdiscus. We also checked reference lists of relevant papers and contacted study authors in an effort to identify published, unpublished and ongoing trials. Searches were last updated in August 2008.

Selection criteria

We included any randomised controlled trials (RCTs) and controlled before-and-after studies which evaluated any educational intervention aimed at preventing eye injuries.

Data collection and analysis

Four authors independently screened the electronic search results and data extracted. Three authors entered data into RevMan 5. As we judged there to be substantial heterogeneity between participants and interventions, we did not pool the studies' results, but have reviewed the results narratively.

Copyright © 2010 The Cochrane Collaboration. Published by John Wiley & Sons, Ltd.

[Intervention Review]

Environmental and behavioural interventions for reducing physical activity limitation in community-dwelling visually impaired older people

Dawn A Skelton[1], Tracey E Howe[2], Claire Ballinger[3], Fiona Neil[4], Shelagh Palmer[5], Lyle Gray[6]

[1]School of Health & Life Sciences, Institute of Allied Health Research, Glasgow Caledonian University, Glasgow, UK. [2]Glasgow City of Science, Glasgow, UK. [3]Research Design Service South Central, Faculty of Medicine, University of Southampton, Southampton, UK. [4]Community Falls Prevention Programme, Greater Glasgow and Clyde NHS, Glasgow, UK. [5]Visibility, Glasgow, UK. [6]Life Sceince, Glasgow Caledonian University, Glasgow, UK

Contact address: Dawn A Skelton, School of Health & Life Sciences, Institute of Allied Health Research, Glasgow Caledonian University, Cowcaddens Rd, Glasgow, G4 0BA, UK. dawn.skelton@gcu.ac.uk.

Editorial group: Cochrane Eyes and Vision Group.
Publication status and date: New, published in Issue 6, 2013.

Citation: Skelton DA, Howe TE, Ballinger C, Neil F, Palmer S, Gray L. Environmental and behavioural interventions for reducing physical activity limitation in community-dwelling visually impaired older people. *Cochrane Database of Systematic Reviews* 2013, Issue 6. Art. No.: CD009233. DOI: 10.1002/14651858.CD009233.pub2.

Copyright © 2013 The Cochrane Collaboration. Published by John Wiley & Sons, Ltd.

ABSTRACT

Background

Impairment of vision is associated with a loss of function in activities of daily living. Avoidance of physical activity and consequent reduced functional capacity is common in older people with visual impairment and an important risk factor for falls. Indeed, the rate of falls and fractures is higher in older people with visual impairment than age-matched visually normal older people. Depression and anxiety is common in older people with vision impairment and leads to further restriction of activity, reduced social contact and reduced quality of life. Possible mechanisms to reduce activity restriction and therefore improve mobility and activity include environmental and behavioural interventions delivered by a number of health professionals, including occupational therapists.

Objectives

The objective of this review was to assess the effectiveness of environmental and behavioural interventions in reducing activity limitation and improving quality of life amongst visually impaired older people.

Search methods

We searched CENTRAL (which contains the Cochrane Eyes and Vision Group Trials Register) (*The Cochrane Library* 2012, Issue 10), Ovid MEDLINE, Ovid MEDLINE In-Process and Other Non-Indexed Citations, Ovid MEDLINE Daily, Ovid OLDMEDLINE, (January 1950 to November 2012), EMBASE (January 1980 to November 2012), Cumulative Index to Nursing and Allied Health Literature (CINAHL) (January 1937 to November 2012), Allied and Complementary Medicine Database (AMED) (January 1985 to November 2012), OT Seeker (inception to November 2012), the *meta*Register of Controlled Trials (*m*RCT) (www.controlled-trials.com), ClinicalTrials.gov (www.clinicaltrials.gov) and the WHO International Clinical Trials Registry Platform (ICTRP) (www.who.int/ictrp/search/en). We did not use any date or language restrictions in the electronic searches for trials. We last searched the electronic databases on 9 November 2012.

Copyright © 2013 The Cochrane Collaboration. Published by John Wiley & Sons, Ltd.

[Intervention Review]

Focal laser treatment in addition to chemotherapy for retinoblastoma

Ido D Fabian[1], Kenneth P Johnson[2], Andrew W Stacey[1], Mandeep S Sagoo[1], M A Reddy[2]

[1]Moorfields Eye Hospital NHS Foundation Trust, London, UK. [2]Royal London Hospital, Barts Health NHS Trust, London, UK

Contact address: Ido D Fabian, Moorfields Eye Hospital NHS Foundation Trust, 162 City Road, London, EC1V 2PD, UK. didifabian@gmail.com.

Editorial group: Cochrane Eyes and Vision Group.
Publication status and date: New, published in Issue 6, 2017.

Citation: Fabian ID, Johnson KP, Stacey AW, Sagoo MS, Reddy MA. Focal laser treatment in addition to chemotherapy for retinoblastoma. *Cochrane Database of Systematic Reviews* 2017, Issue 6. Art. No.: CD012366. DOI: 10.1002/14651858.CD012366.pub2.

Copyright © 2017 The Cochrane Collaboration. Published by John Wiley & Sons, Ltd.

ABSTRACT

Background

Retinoblastoma is the most common primary intraocular malignancy of childhood. Systemic chemotherapy is a common treatment for intraocular retinoblastoma, and laser treatment is used as adjuvant therapy during or immediately after chemotherapy courses in selected cases.

Objectives

To compare the effectiveness and safety of adding focal laser therapy to systemically-delivered chemotherapy in treating intraocular retinoblastoma.

Search methods

We searched the Cochrane Central Register of Controlled Trials (CENTRAL) (which contains the Cochrane Eyes and Vision Trials Register) (2016, Issue 9), MEDLINE Ovid (1946 to 20 October 2016), Embase Ovid (1980 to 20 October 2016), LILACS (Latin American and Caribbean Health Sciences Literature Database) (1982 to 20 October 2016), the ISRCTN registry (www.isrctn.com/editAdvancedSearch); searched 20 October 2016, ClinicalTrials.gov (www.clinicaltrials.gov); searched 20 October 2016, and the World Health Organization (WHO) International Clinical Trials Registry Platform (ICTRP) (www.who.int/ictrp/search/en); searched 20 October 2016. We did not use any date or language restrictions in the electronic searches for trials.

Selection criteria

We searched for randomised controlled trials (RCTs) of systemic chemotherapy with versus without adjuvant laser therapy for postequatorial retinoblastoma.

Data collection and analysis

We planned to use standard methodological procedures expected by Cochrane. We planned to meta-analyse the primary outcome, that is the proportion of eyes with recurrence of tumours within three years from treatment

Main results

No studies met the inclusion criteria for this review.

[Intervention Review]

Fornix-based versus limbal-based conjunctival trabeculectomy flaps for glaucoma

Christiane Al-Haddad[1], Marwan Abdulaal[1], Ahmad Al-Moujahed[2], Ann-Margret Ervin[3]

[1]Ophthalmology Department, American University of Beirut Medical Center, Beirut, Lebanon. [2]Department of Ophthalmology, Massachusetts Eye and Ear Infirmary, Boston, Massachusetts, USA. [3]Department of Epidemiology, Johns Hopkins Bloomberg School of Public Health, Baltimore, Maryland, USA

Contact address: Christiane Al-Haddad, Ophthalmology Department, American University of Beirut Medical Center, Hamrah Street, PO Box 110236, Beirut, Lebanon. ca12@aub.edu.lb.

Editorial group: Cochrane Eyes and Vision Group.
Publication status and date: New, published in Issue 11, 2015.

Citation: Al-Haddad C, Abdulaal M, Al-Moujahed A, Ervin AM. Fornix-based versus limbal-based conjunctival trabeculectomy flaps for glaucoma. *Cochrane Database of Systematic Reviews* 2015, Issue 11. Art. No.: CD009380. DOI: 10.1002/14651858.CD009380.pub2.

Copyright © 2015 The Cochrane Collaboration. Published by John Wiley & Sons, Ltd.

ABSTRACT

Background

Glaucoma is one of the leading largely preventable causes of blindness in the world. It usually is addressed first medically with topical intraocular pressure-lowering drops or by laser trabeculoplasty. In cases where such treatment fails, glaucoma-filtering surgery is considered, most commonly trabeculectomy surgery with variations in technique, for example, the type of conjunctival flap (fornix- or limbal-based). In a fornix-based flap, the surgical wound is performed at the corneal limbus; while in a limbal-based flap, the incision is further away. Many studies in the literature compare fornix- and limbal-based trabeculectomy with respect to outcomes and complications.

Objectives

To assess the comparative effectiveness of fornix- versus limbal-based conjunctival flaps in trabeculectomy for adult glaucoma, with a specific focus on intraocular pressure (IOP) control and complications (adverse effects).

Search methods

We searched CENTRAL (which contains the Cochrane Eyes and Vision Trials Register) (2015, Issue 9), Ovid MEDLINE, Ovid MEDLINE In-Process and Other Non-Indexed Citations, Ovid MEDLINE Daily, Ovid OLDMEDLINE (January 1946 to October 2015), EMBASE (January 1980 to October 2015), Latin American and Caribbean Health Sciences Literature Database (LILACS) (January 1982 to October 2015), the ISRCTN registry (www.isrctn.com/editAdvancedSearch), ClinicalTrials.gov (www.clinicaltrials.gov) and the World Health Organization (WHO) International Clinical Trials Registry Platform (ICTRP) (www.who.int/ictrp/search/en). We did not use any date or language restrictions in the electronic searches for trials. We last searched the electronic databases on 23 October 2015.

We reviewed the bibliographic references of identified randomised controlled trials (RCTs) in order to find trials not identified by the electronic searches. We contacted researchers and practitioners active in the field of glaucoma to identify other published and unpublished trials.

Copyright © 2015 The Cochrane Collaboration. Published by John Wiley & Sons, Ltd.

[Intervention Review]

Spectacle correction versus no spectacles for prevention of strabismus in hyperopic children

Lisa Jones-Jordan[1], Xue Wang[2], Roberta W Scherer[2], Donald O Mutti[1]

[1]College of Optometry, The Ohio State University, Columbus, Ohio, USA. [2]Department of Epidemiology, Johns Hopkins Bloomberg School of Public Health, Baltimore, Maryland, USA

Contact address: Lisa Jones-Jordan, College of Optometry, The Ohio State University, 338 West 10th Avenue, 649 Fry Hall, Columbus, Ohio, 43210, USA. ljones@optometry.osu.edu.

Editorial group: Cochrane Eyes and Vision Group.
Publication status and date: Edited (no change to conclusions), published in Issue 8, 2014.
Review content assessed as up-to-date: 3 April 2014.

Citation: Jones-Jordan L, Wang X, Scherer RW, Mutti DO. Spectacle correction versus no spectacles for prevention of strabismus in hyperopic children. *Cochrane Database of Systematic Reviews* 2014, Issue 8. Art. No.: CD007738. DOI: 10.1002/14651858.CD007738.pub2.

Copyright © 2014 The Cochrane Collaboration. Published by John Wiley & Sons, Ltd.

ABSTRACT

Background

Hyperopia (far-sightedness) in infancy requires accommodative effort to bring images into focus. Prolonged accommodative effort has been associated with an increased risk of strabismus (eye misalignment). Strabismus makes it difficult for the eyes to work together and may result in symptoms of asthenopia (eye strain) and intermittent diplopia (double vision), and makes near work tasks difficult to complete. Untreated strabismus may result in the development of amblyopia (lazy eye). The prescription of spectacles to correct hyperopic refractive error is believed to prevent the development of strabismus.

Objectives

To assess the effectiveness of prescription spectacles compared with no intervention for the prevention of strabismus in infants and children with hyperopia.

Search methods

We searched CENTRAL (which contains the Cochrane Eyes and Vision Group Trials Register) (2014, Issue 4), Ovid MEDLINE, Ovid MEDLINE In-Process and Other Non-Indexed Citations, Ovid MEDLINE Daily, Ovid OLDMEDLINE (January 1946 to April 2014), EMBASE (January 1980 to April 2014), PubMed (1966 to April 2014), the *meta*Register of Controlled Trials (*m*RCT) (www.controlled-trials.com), ClinicalTrials.gov (www.clinicaltrials.gov) and the World Health Organization (WHO) International Clinical Trials Registry Platform (ICTRP) (www.who.int/ictrp/search/en). We did not use any date or language restrictions in the electronic searches for trials. We last searched the electronic databases on 3 April 2014. We also searched the Science Citation Index database in September 2013.

Selection criteria

We included randomized controlled trials and quasi-randomized trials investigating the assignment to spectacle intervention or no treatment for children with hyperopia. The definition of hyperopia remains subjective, but we required it to be at least greater than +2.00 diopters (D) of hyperopia.

Copyright © 2014 The Cochrane Collaboration. Published by John Wiley & Sons, Ltd.

[Intervention Review]

Immunosuppressants for the prophylaxis of corneal graft rejection after penetrating keratoplasty

Minawaer Abudou[1], Taixiang Wu[2], Jennifer R Evans[3], Xueyi Chen[4]

[1]The Eye Department of the First Affiliated Hospital, Xinjiang Medical University, Xinjiang, China. [2]Chinese Clinical Trial Registry, Chinese Ethics Committee of Registering Clinical Trials, West China Hospital, Sichuan University, Chengdu, China. [3]Cochrane Eyes and Vision Group, ICEH, London School of Hygiene & Tropical Medicine, London, UK. [4]Eye Department, First Affiliated Hospital of Xinjiang Medical University, Xinjiang, China

Contact address: Xueyi Chen, Eye Department, First Affiliated Hospital of Xinjiang Medical University, Xinjiang, China. ykcangel@163.com.

Editorial group: Cochrane Eyes and Vision Group.
Publication status and date: New, published in Issue 8, 2015.

Citation: Abudou M, Wu T, Evans JR, Chen X. Immunosuppressants for the prophylaxis of corneal graft rejection after penetrating keratoplasty. *Cochrane Database of Systematic Reviews* 2015, Issue 8. Art. No.: CD007603. DOI: 10.1002/14651858.CD007603.pub2.

Copyright © 2015 The Cochrane Collaboration. Published by John Wiley & Sons, Ltd.

ABSTRACT

Background

Penetrating keratoplasty is a corneal transplantation procedure in which a full-thickness cornea from the host is replaced by a graft from a donor. The use of various immunosuppressants to prevent graft rejection, the most common cause of graft failure in the late postoperative period, is increasing.

Objectives

To assess the effectiveness of immunosuppressants in the prophylaxis of corneal allograft rejection after high- and normal-risk keratoplasty.

Search methods

We searched CENTRAL (which contains the Cochrane Eyes and Vision Group Trials Register) (2015, Issue 4), Ovid MEDLINE, Ovid MEDLINE In-Process and Other Non-Indexed Citations, Ovid MEDLINE Daily, Ovid OLDMEDLINE (January 1946 to May 2015), EMBASE (January 1980 to May 2015), China National Knowledge Infrastructure (CNKI) (January 1913 to February 2015), VIP database (January 1989 to February 2015), Wanfang Data (www.wanfangdata.com) (January 1990 to February 2015), the ISRCTN registry (www.isrctn.com/editAdvancedSearch), ClinicalTrials.gov (www.clinicaltrials.gov), and the World Health Organization (WHO) International Clinical Trials Registry Platform (ICTRP) (www.who.int/ictrp/search/en). We did not use any date or language restrictions in the electronic searches for trials. We last searched the English language databases on 18 May 2015 and the Chinese language databases on 20 February 2015.

Selection criteria

We included all randomised controlled trials (RCTs) assessing the use of immunosuppressants in the prevention of graft rejection, irrespective of publication language.

Data collection and analysis

We used standard procedures expected by Cochrane. The primary outcome was clear graft survival at 12 months after penetrating keratoplasty. Secondary outcomes included graft rejection, best-corrected visual acuity, and quality of life. We defined 'high-risk keratoplasty' as repeat keratoplasty and other indications of reduced graft survival.

Copyright © 2015 The Cochrane Collaboration. Published by John Wiley & Sons, Ltd.

[Intervention Review]

Implantable miniature telescope (IMT) for vision loss due to end-stage age-related macular degeneration

Amisha Gupta[1], Jessica Lam[1], Peter Custis[2], Stephen Munz[3], Donald Fong[4], Marguerite Koster[5]

[1]Department of Clinical Analysis, Evidence-Based Medicine (EBM) Services, Kaiser Permanente, Pasadena, CA, USA. [2]Ophthalmology, Kaiser Permanente, San Diego, CA, USA. [3]Ophthalmology, Kaiser Permanente, Yorba Linda, CA, USA. [4]Ophthalmology, Kaiser Permanente, Baldwin Park, CA, USA. [5]Department of Clinical Analysis, Evidence-Based Medicine (EBM) Services, Kaiser Permanente Southern California, Pasadena, CA, USA

Contact address: Amisha Gupta, Department of Clinical Analysis, Evidence-Based Medicine (EBM) Services, Kaiser Permanente, 393 E. Walnut Ave, 6th Floor, Pasadena, CA, 91188, USA. amisha.gupta@kp.org.

Editorial group: Cochrane Eyes and Vision Group.
Publication status and date: New, published in Issue 5, 2018.

Citation: Gupta A, Lam J, Custis P, Munz S, Fong D, Koster M. Implantable miniature telescope (IMT) for vision loss due to end-stage age-related macular degeneration. *Cochrane Database of Systematic Reviews* 2018, Issue 5. Art. No.: CD011140. DOI: 10.1002/14651858.CD011140.pub2.

Copyright © 2018 The Cochrane Collaboration. Published by John Wiley & Sons, Ltd.

ABSTRACT

Background

Age-related macular degeneration (AMD) causes progressive and irreversible damage to the retina, resulting in loss of central vision. AMD is the third leading cause of irreversible visual impairment worldwide and the leading cause of blindness in industrialized countries. Since AMD is more common in older individuals, the number of affected individuals will increase significantly as the population ages. The implantable miniature telescope (IMT) is an ophthalmic device developed to improve vision in individuals who have lost vision due to AMD. Once implanted, the IMT is used to enlarge objects in the central visual field and focus them onto healthy areas of the retina not affected by AMD, allowing individuals to recognize objects that they otherwise could not see. It is unclear whether and how much the IMT can improve vision in individuals with end-stage AMD.

Objectives

To assess the effectiveness and safety of the IMT in improving visual acuity and quality of life in people with late or advanced AMD.

Search methods

We searched the Cochrane Central Register of Controlled Trials (CENTRAL) (which contains the Cochrane Eyes and Vision Trials Register) (2017, Issue 11); Ovid MEDLINE; Embase.com; PubMed; LILACS; AMED; Web of Science Conference Proceedings Citation Index-Science; OpenSIGLE; the *meta*Register of Controlled Trials (*m*RCT) (last searched 27 June 2014); ClinicalTrials.gov; the ICTRP and the US Food and Drug Administration (FDA) Medical Devices database. The date of the search was 2 November 2017, with the exception of *m*RCT which is no longer in service.

Selection criteria

We planned to include randomized controlled trials (RCTs) and quasi-randomized trials that compared the IMT versus no IMT.

Data collection and analysis

Two review authors independently assessed all studies for inclusion, using standard methodological procedures expected by Cochrane.

[Intervention Review]

Integrated versus non-integrated orbital implants for treating anophthalmic sockets

Silvana Schellini[1], Regina El Dib[2], Leandro RE Silva[3], Joyce G Farat[3], Yuqing Zhang[4], Eliane C Jorge[5]

[1]Botucatu Medical School, UNESP - Univ Estadual Paulista, Botucatu, Brazil. [2]Department of Anaesthesiology, Botucatu Medical School, UNESP - Univ Estadual Paulista, Botucatu, Brazil. [3]Botucatu Medical School, UNESP - Univ Estadual Paulista, São Paulo, Brazil. [4]Department of Clinical Epidemiology and Biostatistics, McMaster University, Hamilton, Canada. [5]Department of Ophthalmology, Otorhinolaryngology and Head and Neck Surgery, Botucatu Medical School, UNESP - Univ Estadual Paulista, Botucatu, Brazil

Contact address: Eliane C Jorge, Department of Ophthalmology, Otorhinolaryngology and Head and Neck Surgery, Botucatu Medical School, UNESP - Univ Estadual Paulista, Distrito de Rubião Júnior, s/n, Botucatu, São Paulo, 18618-970, Brazil. elianej@fmb.unesp.br.

Editorial group: Cochrane Eyes and Vision Group.
Publication status and date: New, published in Issue 11, 2016.

Citation: Schellini S, El Dib R, Silva LRE, Farat JG, Zhang Y, Jorge EC. Integrated versus non-integrated orbital implants for treating anophthalmic sockets. *Cochrane Database of Systematic Reviews* 2016, Issue 11. Art. No.: CD010293. DOI: 10.1002/14651858.CD010293.pub2.

Copyright © 2016 The Cochrane Collaboration. Published by John Wiley & Sons, Ltd.

ABSTRACT

Background

Anophthalmia is the absence of one or both eyes, and it can be congenital (i.e. a birth defect) or acquired later in life. There are two main types of orbital implant: integrated, whereby the implant receives a blood supply from the body that allows for the integration of the prosthesis within the tissue; and non-integrated, where the implant remains separate. Despite the remarkable progress in anophthalmic socket reconstruction and in the development of various types of implants, there are still uncertainties about the real roles of integrated (hydroxyapatite (HA), porous polyethylene (PP), composites) and non-integrated (polymethylmethacrylate (PMMA)/acrylic and silicone) orbital implants in anophthalmic socket treatment.

Objectives

To assess the effects of integrated versus non-integrated orbital implants for treating anophthalmic sockets.

Search methods

We searched CENTRAL (which contains the Cochrane Eyes and Vision Trials Register) (2016, Issue 7), Ovid MEDLINE, Ovid MEDLINE In-Process and Other Non-Indexed Citations, Ovid MEDLINE Daily, Ovid OLDMEDLINE (January 1946 to August 2016), Embase (January 1980 to August 2016), Latin American and Caribbean Health Sciences Literature Database (LILACS) (1982 to August 2016), the ISRCTN registry (www.isrctn.com/editAdvancedSearch), ClinicalTrials.gov (www.clinicaltrials.gov), and the World Health Organization (WHO) International Clinical Trials Registry Platform (ICTRP) (www.who.int/ictrp/search/en). We did not use any date or language restrictions in the electronic searches for trials. We last searched the electronic databases on 8 August 2016.

Selection criteria

Randomised controlled trials (RCTs) and quasi-RCTs of integrated and non-integrated orbital implants for treating anophthalmic sockets.

Data collection and analysis

Two authors independently selected relevant trials, assessed methodological quality and extracted data.

Copyright © 2016 The Cochrane Collaboration. Published by John Wiley & Sons, Ltd.

[Intervention Review]

Antiangiogenic therapy with interferon alfa for neovascular age-related macular degeneration

Usha Reddy[1], Magdalena Krzystolik[2]

[1]c/o Cochrane Eyes and Vision Group US Project, Baltimore, USA. [2]Southern New England Retina Associates, Providence, USA

Contact address: Usha Reddy, c/o Cochrane Eyes and Vision Group US Project, 615 North Wolfe Street, Mailbox Room W 5010, Baltimore, MD 21218, USA. ushareddy@aol.com.

Editorial group: Cochrane Eyes and Vision Group.
Publication status and date: Stable (no update expected for reasons given in 'What's new'), published in Issue 9, 2010.
Review content assessed as up-to-date: 26 July 2007.

Citation: Reddy U, Krzystolik M. Antiangiogenic therapy with interferon alfa for neovascular age-related macular degeneration. *Cochrane Database of Systematic Reviews* 2006, Issue 1. Art. No.: CD005138. DOI: 10.1002/14651858.CD005138.pub2.

Copyright © 2010 The Cochrane Collaboration. Published by John Wiley & Sons, Ltd.

ABSTRACT

Background

Antiangiogenic therapy is a new approach to the treatment of neovascular age-related macular degeneration. Interferon alfa is one antiangiogenic agent thought to function by inhibiting the migration and proliferation of vascular endothelial cells. It has been used in the treatment of hepatitis, solid tumors and hematologic malignancies.

Objectives

The aim of this review was to investigate interferon alfa as a treatment modality for neovascular age-related macular degeneration.

Search methods

We searched and identified trials from the Cochrane Central Register of Controlled Trials (CENTRAL), which contains the Cochrane Eyes and Vision Group Trials Register, in *The Cochrane Library* (Issue 3, 2007), the National Research Register (Issue 3, 2007), MEDLINE (1966 to July 2007), EMBASE (1980 to July 2007), LILACS (Latin American and Caribbean Health Science Literature Database) (July 2007) and the reference lists of included studies.

Selection criteria

We included randomized controlled trials evaluating interferon alfa therapy in people with neovascular age-related macular degeneration who were followed for at least one year.

Data collection and analysis

Both review authors independently extracted data and assessed trial quality. No data synthesis was conducted as only one trial met the inclusion criteria.

Main results

The one included trial enrolled and randomized 481 participants from 45 centers worldwide into four groups. The study allowed for analysis of the number of participants who had lost three or more lines of vision at 52 weeks in three interferon alfa-2a groups versus placebo. The results show an odds ratio of 1.60 (95% Confidence Interval 1.01 to 2.53) indicating that interferon is associated with a 60% increased odds of losing three or more lines at 52 weeks. This finding is marginally statistical with a P value of 0.04 and indicates that the treatment has the potential for harm rather than benefit.

Copyright © 2010 The Cochrane Collaboration. Published by John Wiley & Sons, Ltd.

[Intervention Review]

Interventions for age-related visual problems in patients with stroke

Alex Pollock[1], Christine Hazelton[1], Clair A Henderson[2], Jayne Angilley[3], Baljean Dhillon[4], Peter Langhorne[5], Katrina Livingstone[6], Frank A Munro[7], Heather Orr[8], Fiona J Rowe[9], Uma Shahani[10]

[1]Nursing, Midwifery and Allied Health Professions Research Unit, Glasgow Caledonian University, Glasgow, UK. [2]Parliamentary, Policy, Press and Research, RNIB Scotland, Edinburgh, UK. [3]Cornwall & Isles of Scilly Primary Care Trust, Newquay, UK. [4]Department of Ophthalmology, Clinical and Surgical Sciences, NHS Lothian, Edinburgh, UK. [5]Academic Section of Geriatric Medicine, University of Glasgow, Glasgow, UK. [6]Community Stroke Team - South Glasgow, NHS Greater Glasgow and Clyde, Glasgow, UK. [7]S/E Community Optometrist, Frank Munro Optometrists, Glasgow, UK. [8]Stroke Rehabilitation Unit, NHS Tayside, Brechin, UK. [9]Directorate of Orthoptics and Vision Science, University of Liverpool, Liverpool, UK. [10]Department of Visual Sciences, Glasgow Caledonian University, Glasgow, UK

Contact address: Alex Pollock, Nursing, Midwifery and Allied Health Professions Research Unit, Glasgow Caledonian University, Buchanan House, Cowcaddens Road, Glasgow, G4 0BA, UK. alex.pollock@gcu.ac.uk.

Editorial group: Cochrane Stroke Group.
Publication status and date: New, published in Issue 3, 2012.

Citation: Pollock A, Hazelton C, Henderson CA, Angilley J, Dhillon B, Langhorne P, Livingstone K, Munro FA, Orr H, Rowe FJ, Shahani U. Interventions for age-related visual problems in patients with stroke. *Cochrane Database of Systematic Reviews* 2012, Issue 3. Art. No.: CD008390. DOI: 10.1002/14651858.CD008390.pub2.

Copyright © 2012 The Cochrane Collaboration. Published by John Wiley & Sons, Ltd.

ABSTRACT

Background

The prevalence of eye problems increases with age and, consequently, so does the level of visual impairment. As the incidence of stroke also increases with age, a significant proportion of stroke patients will have age-related visual problems. It is possible that the effect of interventions for age-related visual problems may differ in the population of stroke patients compared to the wider population of older people. The interaction between the problems arising directly from stroke and those arising directly from age-related visual problems will be complex. Interventions for age-related visual problems may also be affected by the presence of other stroke-related co-morbidities. Consequently, the nature and outcome of interventions for age-related visual problems may be different in patients with stroke.

Objectives

The aim of this review is to determine if interventions for age-related visual problems improve functional ability following stroke.

Search methods

We searched the Cochrane Stroke Group Trials Register (March 2011), the Cochrane Eyes and Vision Group Trials Register (December 2009) and nine electronic bibliographic databases including: the Central Register of Controlled Trials (CENTRAL) (*The Cochrane Library* 2011, Issue 1), MEDLINE (1950 to February 2011), EMBASE (1980 to February 2011), CINAHL (1982 to February 2011), AMED (1985 to February 2011) and PsycINFO (1967 to February 2011). We also searched reference lists and trials registers, handsearched journals and conference proceedings, and contacted experts.

[Intervention Review]

Interventions for asymptomatic retinal breaks and lattice degeneration for preventing retinal detachment

Charles P Wilkinson[1,2]

[1]Department of Ophthalmology, Greater Baltimore Medical Center, Baltimore, Maryland, USA. [2]Department of Ophthalmology, Johns Hopkins University, Baltimore, Maryland, USA

Contact address: Charles P Wilkinson, Department of Ophthalmology, Greater Baltimore Medical Center, 6569 North Charles Street, #505, Baltimore, Maryland, 21204, USA. cwilkins@gbmc.org.

Editorial group: Cochrane Eyes and Vision Group.
Publication status and date: New search for studies and content updated (no change to conclusions), published in Issue 9, 2014.

Citation: Wilkinson CP. Interventions for asymptomatic retinal breaks and lattice degeneration for preventing retinal detachment. *Cochrane Database of Systematic Reviews* 2014, Issue 9. Art. No.: CD003170. DOI: 10.1002/14651858.CD003170.pub4.

Copyright © 2014 The Cochrane Collaboration. Published by John Wiley & Sons, Ltd.

ABSTRACT

Background

Asymptomatic retinal breaks and lattice degeneration are visible lesions that are risk factors for later retinal detachment. Retinal detachments occur when fluid in the vitreous cavity passes through tears or holes in the retina and separates the retina from the underlying retinal pigment epithelium. Creation of an adhesion surrounding retinal breaks and lattice degeneration, with laser photocoagulation or cryotherapy, has been recommended as an effective means of preventing retinal detachment. This therapy is of value in the management of retinal tears associated with the symptoms of flashes and floaters and persistent vitreous traction upon the retina in the region of the retinal break, because such symptomatic retinal tears are associated with a high rate of progression to retinal detachment. Retinal tears and holes unassociated with acute symptoms and lattice degeneration are significantly less likely to be the sites of retinal breaks that are responsible for later retinal detachment. Nevertheless, treatment of these lesions frequently is recommended, in spite of the fact that the effectiveness of this therapy is unproven.

Objectives

The objective of this review was to assess the effectiveness and safety of techniques used to treat asymptomatic retinal breaks and lattice degeneration for the prevention of retinal detachment.

Search methods

We searched CENTRAL (which contains the Cochrane Eyes and Vision Group Trials Register) (2014, Issue 2), Ovid MEDLINE, Ovid MEDLINE In-Process and Other Non-Indexed Citations, Ovid MEDLINE Daily, Ovid OLDMEDLINE (January 1946 to February 2014), EMBASE (January 1980 to February 2014), PubMed (January 1948 to February 2014), the *meta*Register of Controlled Trials (*m*RCT) (www.controlled-trials.com), ClinicalTrials.gov (www.clinicaltrials.gov) and the World Health Organization (WHO) International Clinical Trials Registry Platform (ICTRP) (www.who.int/ ictrp/search/en). We did not use any date or language restrictions in the electronic searches for trials. We last searched the electronic databases on 19 February 2014. Textbooks regarding retinal detachment and the reference lists of relevant reports were reviewed for additional study reports. We contacted experts in the field for details of other published and unpublished studies.

Selection criteria

This review was designed to include randomized controlled trials in which one treatment for asymptomatic retinal breaks and lattice degeneration was compared with another treatment or no treatment.

[Intervention Review]

Interventions for chronic blepharitis

Kristina Lindsley[1], Sueko Matsumura[1], Elham Hatef[2], Esen K Akpek[3]

[1]Center for Clinical Trials, Department of Epidemiology, Johns Hopkins Bloomberg School of Public Health, Baltimore, Maryland, USA. [2]Wilmer Eye Institute, Johns Hopkins University School of Medicine, Baltimore, Maryland, USA. [3]Department of Ophthalmology, Johns Hopkins University School of Medicine, Baltimore, MD, USA

Contact address: Kristina Lindsley, Center for Clinical Trials, Department of Epidemiology, Johns Hopkins Bloomberg School of Public Health, 615 North Wolfe Street, W5010, Baltimore, Maryland, 21205, USA. klindsle@jhsph.edu.

Editorial group: Cochrane Eyes and Vision Group.
Publication status and date: New, published in Issue 5, 2012.

Citation: Lindsley K, Matsumura S, Hatef E, Akpek EK. Interventions for chronic blepharitis. *Cochrane Database of Systematic Reviews* 2012, Issue 5. Art. No.: CD005556. DOI: 10.1002/14651858.CD005556.pub2.

Copyright © 2012 The Cochrane Collaboration. Published by John Wiley & Sons, Ltd.

ABSTRACT

Background

Blepharitis, an inflammatory condition associated with itchiness, redness, flaking, and crusting of the eyelids, is a common eye condition that affects both children and adults. It is common in all ethnic groups and across all ages. Although infrequent, blepharitis can lead to permanent alterations to the eyelid margin or vision loss from superficial keratopathy (abnormality of the cornea), corneal neovascularization, and ulceration. Most importantly, blepharitis frequently causes significant ocular symptoms such as burning sensation, irritation, tearing, and red eyes as well as visual problems such as photophobia and blurred vision. The exact etiopathogenesis is unknown, but suspected to be multifactorial, including chronic low-grade infections of the ocular surface with bacteria, infestations with certain parasites such as demodex, and inflammatory skin conditions such as atopy and seborrhea. Blepharitis can be categorized in several different ways. First, categorization is based on the length of disease process: acute or chronic blepharitis. Second, categorization is based on the anatomical location of disease: anterior, or front of the eye (e.g. staphylococcal and seborrheic blepharitis), and posterior, or back of the eye (e.g. meibomian gland dysfunction (MGD)). This review focuses on chronic blepharitis and stratifies anterior and posterior blepharitis.

Objectives

To examine the effectiveness of interventions in the treatment of chronic blepharitis.

Search methods

We searched CENTRAL (which contains the Cochrane Eyes and Vision Group Trials Register) (*The Cochrane Library* 2012, Issue 1), MEDLINE (January 1950 to February 2012), EMBASE (January 1980 to February 2012), the *meta*Register of Controlled Trials (*m*RCT) (www.controlled-trials.com), ClinicalTrials.gov (www.clinicaltrials.gov) and the WHO International Clinical Trials Registry Platform (ICTRP) (www.who.int/ictrp/search/en). We searched the reference lists of included studies for any additional studies not identified by the electronic searches. There were no date or language restrictions in the electronic searches for trials. The electronic databases were last searched on 9 February 2012.

Selection criteria

We included randomized controlled trials (RCTs) and quasi-randomized controlled trials (CCTs) in which participants were adults aged 16 years or older and clinically diagnosed with chronic blepharitis. We also included trials where participants with chronic blepharitis were a subset of the participants included in the study and data were reported separately for these participants. Interventions within the scope of this review included medical treatment and lid hygiene measures.

Copyright © 2012 The Cochrane Collaboration. Published by John Wiley & Sons, Ltd.

[Intervention Review]

Interventions for central serous chorioretinopathy: a network meta-analysis

Mahsa Salehi[1], Adam S Wenick[1], Hua Andrew Law[2], Jennifer R Evans[3], Peter Gehlbach[4]

[1]Department of Ophthalmology, Wilmer Eye Institute, Johns Hopkins University School of Medicine, Baltimore, Maryland, USA. [2]Department of Epidemiology, Johns Hopkins Bloomberg School of Public Health, Baltimore, Maryland, USA. [3]Cochrane Eyes and Vision, ICEH, London School of Hygiene & Tropical Medicine, London, UK. [4]Retina Division, Wilmer Eye Institute, Johns Hopkins University School of Medicine, Baltimore, Maryland, USA

Contact address: Mahsa Salehi, Department of Ophthalmology, Wilmer Eye Institute, Johns Hopkins University School of Medicine, Baltimore, Maryland, USA. msalehi1@jhmi.edu.

Editorial group: Cochrane Eyes and Vision Group.
Publication status and date: New, published in Issue 12, 2015.

Citation: Salehi M, Wenick AS, Law HA, Evans JR, Gehlbach P. Interventions for central serous chorioretinopathy: a network meta-analysis. *Cochrane Database of Systematic Reviews* 2015, Issue 12. Art. No.: CD011841. DOI: 10.1002/14651858.CD011841.pub2.

Copyright © 2015 The Cochrane Collaboration. Published by John Wiley & Sons, Ltd.

ABSTRACT

Background

Central serous chorioretinopathy (CSC) is characterized by serous detachment of the neural retina with dysfunction of the choroid and retinal pigment epithelium (RPE). The effects on the retina are usually self limited, although some people are left with irreversible vision loss due to progressive and permanent photoreceptor damage or RPE atrophy. There have been a variety of interventions used in CSC, including, but not limited to, laser treatment, photodynamic therapy (PDT), and intravitreal injection of anti-vascular endothelial growth factor (anti-VEGF) agents. However, it is not known whether these or other treatments offer significant advantages over observation or other interventions. At present there is no evidence-based consensus on the management of CSC. Due in large part to the propensity for CSC to resolve spontaneously or to follow a waxing and waning course, the most common initial approach to treatment is observation. It remains unclear whether this is the best approach with regard to safety and efficacy.

Objectives

To compare the relative effectiveness of interventions for central serous chorioretinopathy.

Search methods

We searched CENTRAL (which contains the Cochrane Eyes and Vision Trials Register) (2015, Issue 9), Ovid MEDLINE, Ovid MEDLINE In-Process and Other Non-Indexed Citations, Ovid MEDLINE Daily, Ovid OLDMEDLINE (January 1946 to February 2014), EMBASE (January 1980 to October 2015), the ISRCTN registry (www.isrctn.com/editAdvancedSearch), ClinicalTrials.gov (www.clinicaltrials.gov) and the World Health Organization (WHO) International Clinical Trials Registry Platform (ICTRP) (www.who.int/ictrp/search/en). We did not use any date or language restrictions in the electronic searches for trials. We last searched the electronic databases on 5 October 2015.

Selection criteria

Randomized controlled trials (RCTs) that compared any intervention for CSC with any other intervention for CSC or control.

Copyright © 2015 The Cochrane Collaboration. Published by John Wiley & Sons, Ltd.

[Intervention Review]

Interventions for eye movement disorders due to acquired brain injury

Fiona J Rowe[1], Kerry Hanna[1], Jennifer R Evans[2], Carmel P Noonan[3], Marta Garcia-Finana[4], Caroline S Dodridge[5], Claire Howard [6], Kathryn A Jarvis[7], Sonia L MacDiarmid[8], Tallat Maan[9], Lorraine North[10], Helen Rodgers[11]

[1]Department of Health Services Research, University of Liverpool, Liverpool, UK. [2]Cochrane Eyes and Vision, ICEH, London School of Hygiene & Tropical Medicine, London, UK. [3]Department of Ophthalmology, Aintree University Hospitals NHS Foundation Trust, Liverpool, UK. [4]Biostatistics, University of Liverpool, Liverpool, UK. [5]Orthoptics, Oxford University Hospitals NHS Trust, Oxford, UK. [6]Orthoptics, Salford Royal NHS Foundation Trust, Manchester, UK. [7]Occupational Therapy, University of Liverpool, Liverpool, UK. [8]Department of Orthoptics, Warrington and Halton Hospitals NHS Foundation Trust, Warrington, UK. [9]Community Eye Service, Pennine Care NHS Foundation Trust, Ashton-under-Lyne, UK. [10]Orthoptics, Frimley Park NHS Foundation Trust, Frimley, UK. [11]Institute of Neuroscience, Newcastle University, Newcastle, UK

Contact address: Fiona J Rowe, Department of Health Services Research, University of Liverpool, Waterhouse Building (B211), 1-3 Brownlow Street, Liverpool, L69 3GL, UK. rowef@liverpool.ac.uk.

Editorial group: Cochrane Eyes and Vision Group.
Publication status and date: New, published in Issue 3, 2018.

Citation: Rowe FJ, Hanna K, Evans JR, Noonan CP, Garcia-Finana M, Dodridge CS, Howard C, Jarvis KA, MacDiarmid SL, Maan T, North L, Rodgers H. Interventions for eye movement disorders due to acquired brain injury. *Cochrane Database of Systematic Reviews* 2018, Issue 3. Art. No.: CD011290. DOI: 10.1002/14651858.CD011290.pub2.

Copyright © 2018 The Cochrane Collaboration. Published by John Wiley & Sons, Ltd.

ABSTRACT

Background

Acquired brain injury can cause eye movement disorders which may include: strabismus, gaze deficits and nystagmus, causing visual symptoms of double, blurred or 'juddery' vision and reading difficulties. A wide range of interventions exist that have potential to alleviate or ameliorate these symptoms. There is a need to evaluate the effectiveness of these interventions and the timing of their implementation.

Objectives

We aimed to assess the effectiveness of any intervention and determine the effect of timing of intervention in the treatment of strabismus, gaze deficits and nystagmus due to acquired brain injury. We considered restitutive, substitutive, compensatory or pharmacological interventions separately and compared them to control, placebo, alternative treatment or no treatment for improving ocular alignment or motility (or both).

Search methods

We searched the Cochrane Central Register of Controlled Trials (CENTRAL) (containing the Cochrane Eyes and Vision Trials Register) (2017, Issue 5), MEDLINE Ovid, Embase Ovid, CINAHL EBSCO, AMED Ovid, PsycINFO Ovid, Dissertations & Theses (PQDT) database, PsycBITE (Psychological Database for Brain Impairment Treatment Efficacy), ISRCTN registry, ClinicalTrials.gov, Health Services Research Projects in Progress (HSRProj), National Eye Institute Clinical Studies Database and the World Health Organization (WHO) International Clinical Trials Registry Platform (ICTRP). The databases were last searched on 26 June 2017. No date or language restrictions were used in the electronic searches for trials. We manually searched the Australian Orthoptic Journal, British and Irish Orthoptic Journal, and ESA, ISA and IOA conference proceedings. We contacted researchers active in this field for information about further published or unpublished studies.

Copyright © 2018 The Cochrane Collaboration. Published by John Wiley & Sons, Ltd.

[Intervention Review]

Interventions for disorders of eye movement in patients with stroke

Alex Pollock[1], Christine Hazelton[1], Clair A Henderson[2], Jayne Angilley[3], Baljean Dhillon[4], Peter Langhorne[5], Katrina Livingstone[6], Frank A Munro[7], Heather Orr[8], Fiona J Rowe[9], Uma Shahani[10]

[1]Nursing, Midwifery and Allied Health Professions Research Unit, Glasgow Caledonian University, Glasgow, UK. [2]Parliamentary, Policy, Press and Research, RNIB Scotland, Edinburgh, UK. [3]Cornwall & Isles of Scilly Primary Care Trust, Newquay, UK. [4]Department of Ophthalmology, Clinical and Surgical Sciences, NHS Lothian, Edinburgh, UK. [5]Academic Section of Geriatric Medicine, University of Glasgow, Glasgow, UK. [6]Community Stroke Team - South Glasgow, NHS Greater Glasgow and Clyde, Glasgow, UK. [7]S/E Community Optometrist, Frank Munro Optometrists, Glasgow, UK. [8]Stroke Rehabilitation Unit, NHS Tayside, Brechin, UK. [9]Directorate of Orthoptics and Vision Science, University of Liverpool, Liverpool, UK. [10]Department of Visual Sciences, Glasgow Caledonian University, Glasgow, UK

Contact address: Alex Pollock, Nursing, Midwifery and Allied Health Professions Research Unit, Glasgow Caledonian University, Buchanan House, Cowcaddens Road, Glasgow, G4 0BA, UK. alex.pollock@gcu.ac.uk.

Editorial group: Cochrane Stroke Group.
Publication status and date: New, published in Issue 10, 2011.

Citation: Pollock A, Hazelton C, Henderson CA, Angilley J, Dhillon B, Langhorne P, Livingstone K, Munro FA, Orr H, Rowe FJ, Shahani U. Interventions for disorders of eye movement in patients with stroke. *Cochrane Database of Systematic Reviews* 2011, Issue 10. Art. No.: CD008389. DOI: 10.1002/14651858.CD008389.pub2.

Copyright © 2011 The Cochrane Collaboration. Published by John Wiley & Sons, Ltd.

ABSTRACT

Background

Eye movement disorders may affect over 70% of stroke patients. These eye movement disorders can result in difficulty maintaining the normal ocular position and difficulty moving the eyes appropriately. The resulting functional disabilities include a loss of depth perception, reduced hand-to-eye co-ordination, marked difficulties with near tasks and reading and reduced ability to scan the visual environment. They can also impact on the effectiveness of rehabilitation therapy. There are a wide variety of different treatment interventions proposed for eye movement disorders after stroke. However, in the past, there has been a lack of evidence specific to the impact of interventions on the functional outcome of patients with stroke.

Objectives

To determine the effects of interventions for eye movement disorders on functional ability following stroke.

Search methods

We searched the Cochrane Stroke Group Trials Register (February 2011), the Cochrane Eyes and Vision Group Trials Register (December 2009) and nine electronic bibliographic databases including CENTRAL (*The Cochrane Library* 2009, Issue 4), MEDLINE (1950 to December 2009), EMBASE (1980 to December 2009), CINAHL (1982 to December 2009), AMED (1985 to December 2009), and PsycINFO (1967 to December 2009). We also searched reference lists and trials registers, handsearched journals and conference proceedings, and contacted experts.

Selection criteria

Randomised trials in adults after stroke where the intervention was specifically targeted at improving the eye movement disorder or improving the ability of the participant to cope with the eye movement disorder. The primary outcome was functional ability in

Copyright © 2011 The Cochrane Collaboration. Published by John Wiley & Sons, Ltd.

[Intervention Review]

Interventions for improving adherence to ocular hypotensive therapy

Heather Waterman[1], Jennifer R Evans[2], Trish A Gray[3], David Henson[3], Robert Harper[4]

[1]School of Nursing, Midwifery and Social Work, University of Manchester, Manchester, UK. [2]Cochrane Eyes and Vision Group, ICEH, London School of Hygiene & Tropical Medicine, London, UK. [3]Academic Department of Ophthalmology, Manchester Royal Eye Hospital, Manchester, UK. [4]Optometry Department, Central Manchester & Manchester Children's NHS Trust, Manchester, UK

Contact address: Heather Waterman, School of Nursing, Midwifery and Social Work, University of Manchester, Room 6.31a, University Place, Oxford Road, Manchester, M13 9PL, UK. heather.waterman@manchester.ac.uk.

Editorial group: Cochrane Eyes and Vision Group.
Publication status and date: New search for studies and content updated (conclusions changed), published in Issue 4, 2013.
Review content assessed as up-to-date: 26 June 2012.

Citation: Waterman H, Evans JR, Gray TA, Henson D, Harper R. Interventions for improving adherence to ocular hypotensive therapy. *Cochrane Database of Systematic Reviews* 2013, Issue 4. Art. No.: CD006132. DOI: 10.1002/14651858.CD006132.pub3.

Copyright © 2013 The Cochrane Collaboration. Published by John Wiley & Sons, Ltd.

ABSTRACT

Background

Poor adherence to therapy is a significant healthcare issue, particularly in patients with chronic disease such as open-angle glaucoma. Treatment failure may necessitate unwarranted changes of medications, increased healthcare expenditure and risk to the patient if surgical intervention is required. Simplifying eye drop regimes, providing adequate information, teaching drop instillation technique and ongoing support according to the patient need may have a positive effect on improving adherence.

Objectives

To summarise the effects of interventions for improving adherence to ocular hypotensive therapy in people with ocular hypertension (OHT) or glaucoma.

Search methods

We searched CENTRAL (which contains the Cochrane Eyes and Vision Group Trials Register) (*The Cochrane Library* 2012, Issue 6), MEDLINE (June 1946 to June 2012), EMBASE (June 1980 to June 2012), Cumulative Index to Nursing and Allied Health Literature (CINAHL) (June 1937 to June 2012), PsycINFO (1806 to June 2012), PsycEXTRA (1908 to June 2012), Web of Science (1970 to June 2012), ZETOC (1993 to June 2012), OpenGrey (System for Information on Grey Literature in Europe) (www.opengrey.eu/), the *meta*Register of Controlled Trials (*m*RCT) (www.controlled-trials.com), ClinicalTrials.gov (www.clinicaltrials.gov) and the WHO International Clinical Trials Registry Platform (ICTRP) (www.who.int/ictrp/search/en). We did not use any date or language restrictions in the electronic searches for trials. The electronic databases were last searched on 26 June 2012. We did not search the National Research Register (NNR) as this resource has now been now archived. We contacted pharmaceutical manufacturers to request unpublished data and searched conference proceedings for the Association for Research in Vision and Ophthalmology (ARVO), and the Annual Congress for the Royal College of Ophthalmologists (RCO).

Selection criteria

We included randomised controlled trials (RCTs) and quasi-RCTs that compared interventions to improve adherence to ocular hypotensive therapy for patients with OHT or glaucoma.

[Intervention Review]

Interventions for idiopathic intracranial hypertension

Rory J Piper[1], Aristotelis V Kalyvas[1], Adam MH Young[2,3], Mark A Hughes[1,4], Aimun AB Jamjoom[4], Ioannis P Fouyas[4]

[1]University of Edinburgh, Edinburgh, UK. [2]University of Glasgow, Glasgow, UK. [3]Institute of Neurological Science, Southern General Hospital, Glasgow, UK. [4]Department of Clinical Neurosciences, Western General Hospital, Edinburgh, UK

Contact address: Rory J Piper, University of Edinburgh, Edinburgh, UK. r.j.piper@sms.ed.ac.uk.

Editorial group: Cochrane Eyes and Vision Group.
Publication status and date: New search for studies and content updated (no change to conclusions), published in Issue 8, 2015.

Citation: Piper RJ, Kalyvas AV, Young AMH, Hughes MA, Jamjoom AAB, Fouyas IP. Interventions for idiopathic intracranial hypertension. *Cochrane Database of Systematic Reviews* 2015, Issue 8. Art. No.: CD003434. DOI: 10.1002/14651858.CD003434.pub3.

Copyright © 2015 The Cochrane Collaboration. Published by John Wiley & Sons, Ltd.

ABSTRACT

Background

Idiopathic intracranial hypertension (IIH) has an estimated incidence of one to three people per 100,000 people per year, and occurs most commonly in obese, young women. IIH is associated with severe morbidity, notably due to a significant threat to sight and severe headache. Several different management options have been proposed. Conservative measures centre on weight loss. Pharmacological therapy includes use of diuretics. Refractory and sight-threatening cases demand surgical intervention, most often in the form of cerebrospinal fluid (CSF) diversion or optic nerve sheath fenestration. Other treatments include venous sinus stenting and bariatric surgery.

Objectives

To assess the effects of any intervention for IIH in any patient group.

Search methods

We searched CENTRAL (which contains the Cochrane Eyes and Vision Group Trials Register) (2015 Issue 6), Ovid MEDLINE, Ovid MEDLINE In-Process and Other Non-Indexed Citations, Ovid MEDLINE Daily, Ovid OLDMEDLINE (January 1946 to July 2015), EMBASE (January 1980 to July 2015), the ISRCTN registry (www.isrctn.com/editAdvancedSearch), ClinicalTrials.gov (www.clinicaltrials.gov) and the World Health Organization (WHO) International Clinical Trials Registry Platform (ICTRP) (www.who.int/ictrp/search/en). We did not use any date or language restrictions in the electronic searches for trials. We last searched the electronic databases on 22 July 2015.

Selection criteria

We included only randomised controlled trials (RCTs) in which any intervention was compared to placebo, or to another form of treatment, for people with a clinical diagnosis of IIH.

Data collection and analysis

Two review authors independently assessed the search results for trials to be included in the review. We resolved any discrepancies by third party decision.

[Intervention Review]

Interventions for late trabeculectomy bleb leak

Frank Bochmann[1], Augusto Azuara-Blanco[2]

[1]Department of Ophthalmology, Cantonal Hospital of Lucerne, Lucerne, Switzerland. [2]Health Services Research Unit, University of Aberdeen, Aberdeen, UK

Contact address: Frank Bochmann, Department of Ophthalmology, Cantonal Hospital of Lucerne, Lucerne, CH-6000, Switzerland. frank.bochmann@luks.ch.

Editorial group: Cochrane Eyes and Vision Group.
Publication status and date: New, published in Issue 9, 2012.
Review content assessed as up-to-date: 18 July 2012.

Citation: Bochmann F, Azuara-Blanco A. Interventions for late trabeculectomy bleb leak. *Cochrane Database of Systematic Reviews* 2012, Issue 9. Art. No.: CD006769. DOI: 10.1002/14651858.CD006769.pub2.

Copyright © 2012 The Cochrane Collaboration. Published by John Wiley & Sons, Ltd.

ABSTRACT

Background

Late trabeculectomy bleb leaks are a common complication after filtering glaucoma surgery. Although asymptomatic, late bleb leaks may lead to hypotony and are associated with bleb related infections.

Objectives

To assess the effects of interventions for late trabeculectomy bleb leak.

Search methods

We searched CENTRAL (which contains the Cochrane Eyes and Vision Group Trials Register) (*The Cochrane Library* 2012, Issue 7), MEDLINE (January 1946 to July 2012), EMBASE (January 1980 to July 2012), the *meta*Register of Controlled Trials (*m*RCT) (www.controlled-trials.com), ClinicalTrials.gov (www.clinicaltrials.gov) and the WHO International Clinical Trials Registry Platform (ICTRP) (www.who.int/ictrp/search/en). We did not use any date or language restrictions in the electronic searches for trials. We last searched the electronic databases on 18 July 2012.

Selection criteria

We included randomised and quasi-randomised trials in which any treatments for eyes with late bleb leak (interventional and non-interventional) were compared with each other.

Data collection and analysis

Two authors independently assessed trial quality and extracted data. We contacted study authors when additional information was needed.

Main results

The review included one multicentre trial based in the USA with 30 eyes of 30 participants. The trial compared two surgical procedures (conjunctival advancement and amniotic membrane transplant) to cover a filtering bleb leak. Conjunctival advancement has been shown to be more effective in sealing filtering bleb leaks.

Copyright © 2012 The Cochrane Collaboration. Published by John Wiley & Sons, Ltd.

[Intervention Review]

Interventions for Mooren's ulcer

Mahmoud B Alhassan[1], Mansur Rabiu[2], Idris O Agbabiaka[3]

[1]Clinical Ophthalmology, The National Eye Centre, Kaduna, Nigeria. [2]Prevention of Blindness Union, Riyadh, Saudi Arabia. [3]National Eye Centre, Kaduna, Nigeria

Contact address: Mahmoud B Alhassan, Clinical Ophthalmology, The National Eye Centre, Western Bye Pass, Nnamdi Azikiwe Way, Kaduna, Kaduna State, PMP 2267, Nigeria. mbalhassan@yahoo.com.

Editorial group: Cochrane Eyes and Vision Group.
Publication status and date: New search for studies and content updated (no change to conclusions), published in Issue 1, 2014.

Citation: Alhassan MB, Rabiu M, Agbabiaka IO. Interventions for Mooren's ulcer. *Cochrane Database of Systematic Reviews* 2014, Issue 1. Art. No.: CD006131. DOI: 10.1002/14651858.CD006131.pub3.

Copyright © 2014 The Cochrane Collaboration. Published by John Wiley & Sons, Ltd.

ABSTRACT

Background

Mooren's ulcer is a chronic, painful peripheral ulcer of the cornea. Its cause is unknown but it can or will lead to loss of vision if untreated. Severe pain is common in patients with Mooren's ulcer and the eye(s) may be intensely reddened, inflamed and photophobic, with tearing. The disease is rare in the northern hemisphere but more common in southern and central Africa, China and the Indian subcontinent. There are a number of treatments used such as anti-inflammatory drugs (steroidal and non-steroidal), cytotoxic drugs (topical and systemic), conjunctivectomy and cornea debridement (superficial keratectomy). There is no evidence to show which is the most effective amongst these treatment modalities.

Objectives

The aim of this systematic review is to assess the effectiveness of the various interventions (medical and surgical) for Mooren's ulcer.

Search methods

We searched CENTRAL (which contains the Cochrane Eyes and Vision Group Trials Register) (*The Cochrane Library* 2013, Issue 5), Ovid MEDLINE, Ovid MEDLINE In-Process and Other Non-Indexed Citations, Ovid MEDLINE Daily, Ovid OLDMEDLINE (January 1946 to June 2013), EMBASE (January 1980 to June 2013), Latin American and Caribbean Literature on Health Sciences (LILACS) (January 1982 to June 2013), the *meta*Register of Controlled Trials (*m*RCT) (www.controlled-trials.com), ClinicalTrials.gov (www.clinicaltrials.gov) and the WHO International Clinical Trials Registry Platform (ICTRP) (www.who.int/ictrp/search/en). We did not use any date or language restrictions in the electronic searches for trials. We last searched the electronic databases on 4 June 2013.

Selection criteria

We planned to include randomised controlled trials (RCTs) or discuss any prospective non-RCTs in the absence of any RCTs. The trials included would be of people of any age or gender diagnosed with Mooren's ulcer and all interventions (medical and surgical) would be considered.

Data collection and analysis

Two authors screened the search results independently; we found no studies that met our inclusion criteria.

Main results

As we found no studies that met our inclusion criteria, we highlighted important considerations for conducting RCTs in the future in this area.

Copyright © 2014 The Cochrane Collaboration. Published by John Wiley & Sons, Ltd.

[Intervention Review]

Interventions for prevention of giant retinal tear in the fellow eye

Ghee Soon Ang[1], John Townend[2], Noemi Lois[3]

[1]Department of Ophthalmology, Aberdeen Royal Infirmary, Aberdeen, UK. [2]Department of Public Health, University of Aberdeen, Aberdeen, UK. [3]Ophthalmology Department, Grampian University Hospitals NHS Trust, Aberdeen, UK

Contact address: Noemi Lois, Ophthalmology Department, Grampian University Hospitals NHS Trust, Foresterhill, Aberdeen, AB25 2ZN, UK. noemilois@aol.com.

Editorial group: Cochrane Eyes and Vision Group.
Publication status and date: New search for studies and content updated (no change to conclusions), published in Issue 2, 2012.
Review content assessed as up-to-date: 6 December 2011.

Citation: Ang GS, Townend J, Lois N. Interventions for prevention of giant retinal tear in the fellow eye. *Cochrane Database of Systematic Reviews* 2012, Issue 2. Art. No.: CD006909. DOI: 10.1002/14651858.CD006909.pub3.

Copyright © 2012 The Cochrane Collaboration. Published by John Wiley & Sons, Ltd.

ABSTRACT

Background

A giant retinal tear is a full-thickness retinal break that extends circumferentially around the retina for 90 degrees or more in the presence of a posteriorly detached vitreous. It causes significant visual morbidity from retinal detachment and proliferative vitreoretinopathy. The fellow eye of patients who have had a spontaneous giant retinal tear has an increased risk of developing a giant retinal tear, a retinal detachment or both. Interventions such as 360-degree encircling scleral buckling, 360-degree cryotherapy and 360-degree laser photocoagulation have been advocated by some ophthalmologists as prophylaxis for the fellow eye against the development of a giant retinal tear and/or a retinal detachment, or to prevent its extension.

Objectives

To evaluate the effectiveness of prophylactic 360-degree interventions in the fellow eye of patients with unilateral giant retinal tear to prevent the occurrence of a giant retinal tear, a retinal detachment or both.

Search methods

We searched CENTRAL (which contains the Cochrane Eyes and Vision Group Trials Register) (*The Cochrane Library* 2011, Issue 11), MEDLINE (January 1950 to December 2011), EMBASE (January 1980 to December 2011), Latin American and Caribbean Literature on Health Sciences (LILACS) (January 1982 to December 2011), the *meta*Register of Controlled Trials (*m*RCT) (www.controlled-trials.com), ClinicalTrials.gov (www.clinicaltrials.gov) and the WHO International Clinical Trials Registry Platform (ICTRP) (www.who.int/ictrp/search/en). There were no date or language restrictions in the electronic searches for trials. The electronic databases were last searched on 6 December 2011. In addition, we searched the proceedings of the Annual Meeting of the Association for Research in Vision and Ophthalmology (ARVO) up to 2008 for information about other relevant studies.

Selection criteria

Prospective randomised controlled trials (RCTs) comparing one prophylactic treatment for fellow eyes of patients with giant retinal tear against observation (no treatment) or another form of prophylactic treatment. In the absence of RCTs, we planned to discuss case-control studies that met the inclusion criteria but we would not conduct a meta-analysis using these studies.

Copyright © 2012 The Cochrane Collaboration. Published by John Wiley & Sons, Ltd.

[Intervention Review]

Interventions for trachoma trichiasis

Matthew Burton[1], Esmael Habtamu[2], Derek Ho[3], Emily W Gower[4]

[1]International Centre for Eye Health, London School of Hygiene & Tropical Medicine, London, UK. [2]London School of Hygiene and Tropical Medicine, London, UK. [3]Imperial College, London, UK. [4]Wake Forest Public Health Sciences and Ophthalmology, Winston-Salem, NC, USA

Contact address: Matthew Burton, International Centre for Eye Health, London School of Hygiene & Tropical Medicine, Keppel Street, London, WC1E 7HT, UK. matthew.burton@lshtm.ac.uk.

Editorial group: Cochrane Eyes and Vision Group.
Publication status and date: Edited (no change to conclusions), published in Issue 12, 2016.

Citation: Burton M, Habtamu E, Ho D, Gower EW. Interventions for trachoma trichiasis. *Cochrane Database of Systematic Reviews* 2015, Issue 11. Art. No.: CD004008. DOI: 10.1002/14651858.CD004008.pub3.

Copyright © 2016 The Authors. Cochrane Database of Systematic Reviews published by John Wiley & Sons, Ltd. on behalf of The Cochrane Collaboration. This is an open access article under the terms of the Creative Commons Attribution Licence, which permits use, distribution and reproduction in any medium, provided the original work is properly cited.

ABSTRACT

Background

Trachoma is the leading infectious cause of blindness. The World Health Organization (WHO) recommends eliminating trachomatous blindness through the SAFE strategy: Surgery for trichiasis, Antibiotic treatment, Facial cleanliness and Environmental hygiene. This is an update of a Cochrane review first published in 2003, and previously updated in 2006.

Objectives

To assess the effects of interventions for trachomatous trichiasis for people living in endemic settings.

Search methods

We searched CENTRAL (which contains the Cochrane Eyes and Vision Group Trials Register) (2015, Issue 4), Ovid MEDLINE, Ovid MEDLINE In-Process and Other Non-Indexed Citations, Ovid MEDLINE Daily, Ovid OLDMEDLINE (January 1946 to May 2015), EMBASE (January 1980 to May 2015), the ISRCTN registry (www.isrctn.com/editAdvancedSearch), ClinicalTrials.gov (www.clinicaltrials.gov) and the WHO International Clinical Trials Registry Platform (ICTRP) (www.who.int/ictrp/search/en). We did not use any date or language restrictions in the electronic searches for trials. We last searched the electronic databases on 7 May 2015. We searched the reference lists of included studies to identify further potentially relevant studies. We also contacted authors for details of other relevant studies.

Selection criteria

We included randomised trials of any intervention intended to treat trachomatous trichiasis.

Data collection and analysis

Three review authors independently selected and assessed the trials, including the risk of bias. We contacted trial authors for missing data when necessary. Our primary outcome was post-operative trichiasis which was defined as any lash touching the globe at three months, one year or two years after surgery.

Copyright © 2016 The Authors. Cochrane Database of Systematic Reviews published by John Wiley & Sons, Ltd. on behalf of The Cochrane Collaboration.

[Intervention Review]

Interventions to improve access to cataract surgical services and their impact on equity in low- and middle-income countries

Jacqueline Ramke[1], Jennifer Petkovic[2], Vivian Welch[3], Ilse Blignault[4], Clare Gilbert[5], Karl Blanchet[6], Robin Christensen[7], Anthony B Zwi[8], Peter Tugwell[9]

[1]School of Population Health, Faculty of Medicine and Health Sciences, University of Auckland, Auckland, New Zealand. [2]Bruyère Research Institute, University of Ottawa, Ottawa, Canada. [3]Methods Centre, Bruyère Research Institute, Ottawa, Canada. [4]School of Public Health and Community Medicine, University of New South Wales, Sydney, Australia. [5]Department of Clinical Research, Faculty of Infectious and Tropical Diseases, London School of Hygiene & Tropical Medicine, London, UK. [6]Department of Global Health and Development, London School of Hygiene & Tropical Medicine, London, UK. [7]Musculoskeletal Statistics Unit, The Parker Institute, Copenhagen University Hospital, Bispebjerg og Frederiksberg, Copenhagen, Denmark. [8]School of Social Sciences, Faculty of Arts and Social Sciences, University of New South Wales, Sydney, Australia. [9]Department of Medicine, Faculty of Medicine, University of Ottawa, Ottawa, Canada

Contact address: Jacqueline Ramke, School of Population Health, Faculty of Medicine and Health Sciences, University of Auckland, Auckland, New Zealand. jramke@gmail.com.

Editorial group: Cochrane Eyes and Vision Group.
Publication status and date: New, published in Issue 11, 2017.

Citation: Ramke J, Petkovic J, Welch V, Blignault I, Gilbert C, Blanchet K, Christensen R, Zwi AB, Tugwell P. Interventions to improve access to cataract surgical services and their impact on equity in low- and middle-income countries. *Cochrane Database of Systematic Reviews* 2017, Issue 11. Art. No.: CD011307. DOI: 10.1002/14651858.CD011307.pub2.

Copyright © 2017 The Cochrane Collaboration. Published by John Wiley & Sons, Ltd.

ABSTRACT

Background

Cataract is the leading cause of blindness in low- and middle-income countries (LMICs), and the prevalence is inequitably distributed between and within countries. Interventions have been undertaken to improve cataract surgical services, however, the effectiveness of these interventions on promoting equity is not known.

Objectives

To assess the effects on equity of interventions to improve access to cataract services for populations with cataract blindness (and visual impairment) in LMICs.

Search methods

We searched the Cochrane Central Register of Controlled Trials (CENTRAL) (which contains the Cochrane Eyes and Vision Trials Register) (2017, Issue 3), MEDLINE Ovid (1946 to 12 April 2017), Embase Ovid (1980 to 12 April 2017), LILACS (Latin American and Caribbean Health Sciences Literature Database) (1982 to 12 April 2017), the ISRCTN registry (www.isrctn.com/editAdvancedSearch); searched 12 April 2017, ClinicalTrials.gov (www.clinicaltrials.gov); searched 12 April 2017 and the World Health Organization (WHO) International Clinical Trials Registry Platform (ICTRP) (www.who.int/ictrp/search/en); searched 12 April 2017. We did not use any date or language restrictions in the electronic searches for trials.

[Intervention Review]

Intravitreal low molecular weight heparin and 5-Fluorouracil for the prevention of proliferative vitreoretinopathy following retinal reattachment surgery

Venki Sundaram[1], Allon Barsam[2], Gianni Virgili[3]

[1]c/o Cochrane Eyes and Vision Group, ICEH, London School of Hygiene & Tropical Medicine, London, UK. [2]Moorfields Eye Hospital NHS Foundation Trust, London, UK. [3]Department of Specialised Surgical Sciences, University of Florence, Florence, Italy

Contact address: Venki Sundaram, c/o Cochrane Eyes and Vision Group, ICEH, London School of Hygiene & Tropical Medicine, Keppel Street, London, WC1E 7HT, UK. venkisundaram@hotmail.com.

Editorial group: Cochrane Eyes and Vision Group.
Publication status and date: New search for studies and content updated (no change to conclusions), published in Issue 1, 2013.
Review content assessed as up-to-date: 15 October 2012.

Citation: Sundaram V, Barsam A, Virgili G. Intravitreal low molecular weight heparin and 5-Fluorouracil for the prevention of proliferative vitreoretinopathy following retinal reattachment surgery. *Cochrane Database of Systematic Reviews* 2013, Issue 1. Art. No.: CD006421. DOI: 10.1002/14651858.CD006421.pub3.

Copyright © 2013 The Cochrane Collaboration. Published by John Wiley & Sons, Ltd.

ABSTRACT

Background

Proliferative vitreoretinopathy (PVR) is a significant cause of failure in retinal reattachment surgery. Various pharmacological agents have shown potential benefit in reducing postoperative PVR risk.

Objectives

This review aimed to compare the use of intravitreal low molecular weight heparin (LMWH) alone or with 5-Fluorouracil (5-FU) versus placebo, as an adjunct in the prevention of PVR following retinal reattachment surgery.

Search methods

We searched CENTRAL (which contains the Cochrane Eyes and Vision Group Trials Register) (*The Cochrane Library* 2012, Issue 9), MEDLINE (January 1950 to October 2012), EMBASE (January 1980 to October 2012), the *meta*Register of Controlled Trials (*m*RCT) (www.controlled-trials.com), ClinicalTrials.gov (www.clinicaltrials.gov) and the WHO International Clinical Trials Registry Platform (ICTRP) (www.who.int/ictrp/search/en). We did not use any date or language restrictions in the electronic searches for trials. We last searched the electronic databases on 15 October 2012.

Selection criteria

We only included randomised controlled trials (RCTs) that compared intravitreal LMWH alone or with 5-FU, versus placebo for the prevention of postoperative PVR in patients undergoing primary vitrectomy for rhegmatogenous retinal detachment repair.

Data collection and analysis

Two review authors independently assessed trial quality and extracted data. The review authors contacted study authors for additional information.

Copyright © 2013 The Cochrane Collaboration. Published by John Wiley & Sons, Ltd.

[Intervention Review]

Strabismus surgery before versus after completion of amblyopia therapy in children

Sanita Korah[1], Swetha Philip[1], Smitha Jasper[1], Aileen Antonio-Santos[2], Andrew Braganza[1]

[1]Department of Ophthalmology, Christian Medical College, Vellore, India. [2]Michigan State University, East Lansing, Michigan, USA

Contact address: Sanita Korah, Department of Ophthalmology, Christian Medical College, Vellore, Tamil Nadu, 632001, India. sanviji@cmcvellore.ac.in.

Editorial group: Cochrane Eyes and Vision Group.
Publication status and date: New, published in Issue 10, 2014.
Review content assessed as up-to-date: 24 July 2014.

Citation: Korah S, Philip S, Jasper S, Antonio-Santos A, Braganza A. Strabismus surgery before versus after completion of amblyopia therapy in children. *Cochrane Database of Systematic Reviews* 2014, Issue 10. Art. No.: CD009272. DOI: 10.1002/14651858.CD009272.pub2.

Copyright © 2014 The Cochrane Collaboration. Published by John Wiley & Sons, Ltd.

ABSTRACT

Background

Normal visual development occurs when the brain is able to integrate the visual input from each of the two eyes to form a single three-dimensional image. The process of development of complete three-dimensional vision begins at birth and is almost complete by 24 months of age. The development of this binocular vision is hindered by any abnormality that prevents the brain from receiving a clear, similar image from each eye, due to decreased vision (e.g. amblyopia), or due to misalignment of the two eyes (strabismus or squint) in infancy and early childhood. Currently, practice patterns for management of a child with both strabismus and amblyopia are not standardized.

Objectives

To study the functional and anatomic (ocular alignment) outcomes of strabismus surgery before completion of amblyopia therapy as compared with surgery after completion of amblyopia therapy in children under seven years of age.

Search methods

We searched CENTRAL (which contains the Cochrane Eyes and Vision Group Trials Register) (2014, Issue 6), Ovid MEDLINE, Ovid MEDLINE In-Process and Other Non-Indexed Citations, Ovid MEDLINE Daily, Ovid OLDMEDLINE (January 1946 to July 2014), EMBASE (January 1980 to July 2014), Latin American and Caribbean Health Sciences Literature Database (LILACS) (January 1982 to July 2014), the *meta*Register of Controlled Trials (*m*RCT) (www.controlled-trials.com), ClinicalTrials.gov (www.clinicaltrials.gov) and the World Health Organization (WHO) International Clinical Trials Registry Platform (ICTRP) (www.who.int/ictrp/search/en). We did not use any date or language restrictions in the electronic searches for trials. We last searched the electronic databases on 24 July 2014. A manual search for articles from a review of the references of the selected publications and conference abstracts was completed to identify any additional relevant studies.

Selection criteria

We searched for randomized controlled trials (RCTs) that provided data on strabismus surgery in children less than seven years of age, performed after initiation of, but before completion of amblyopia therapy, as compared with strabismus surgery after completion of amblyopia therapy.

Copyright © 2014 The Cochrane Collaboration. Published by John Wiley & Sons, Ltd.

[Intervention Review]

Nd:YAG laser vitreolysis versus pars plana vitrectomy for vitreous floaters

Jan Kokavec[1], Zhichao Wu[2], Justin C Sherwin[3], Alan JS Ang[4], Ghee Soon Ang[3]

[1]South Australian Institute of Ophthalmology, Royal Adelaide Hospital, Adelaide, Australia. [2]Centre for Eye Research Australia, East Melbourne, Australia. [3]The Royal Victorian Eye and Ear Hospital, Melbourne, Australia. [4]International Specialist Eye Centre, Penang, Malaysia

Contact address: Jan Kokavec, South Australian Institute of Ophthalmology, Royal Adelaide Hospital, Level 8, East Wing, North Terrace, Adelaide, SA, 5000, Australia. jkokavec@gmail.com.

Editorial group: Cochrane Eyes and Vision Group.
Publication status and date: New, published in Issue 6, 2017.

Citation: Kokavec J, Wu Z, Sherwin JC, Ang AJS, Ang GS. Nd:YAG laser vitreolysis versus pars plana vitrectomy for vitreous floaters. *Cochrane Database of Systematic Reviews* 2017, Issue 6. Art. No.: CD011676. DOI: 10.1002/14651858.CD011676.pub2.

Copyright © 2017 The Cochrane Collaboration. Published by John Wiley & Sons, Ltd.

ABSTRACT

Background

The vitreous is the clear jelly of the eye and contains fine strands of proteins. Throughout life the composition of this vitreous changes, which causes the protein strands in it to bundle together and scatter light before it reaches the retina. Individuals perceive the shadows cast by these protein bundles as 'floaters'. Some people are so bothered by floaters that treatment is required to control their symptoms. Two major interventions for floaters include Nd:YAG laser vitreolysis and vitrectomy. Nd:YAG laser vitreolysis involves using laser energy to fragment the vitreous opacities via a non-invasive approach. Vitrectomy involves the surgical replacement of the patient's vitreous (including the symptomatic vitreous floaters) with an inert and translucent balanced salt solution, through small openings in the pars plana.

Objectives

To compare the effectiveness and safety of Nd:YAG laser vitreolysis to pars plana vitrectomy for symptomatic vitreous floaters.

Search methods

We searched the Cochrane Central Register of Controlled Trials (CENTRAL) (which contains the Cochrane Eyes and Vision Trials Register) (2016, Issue 12), MEDLINE Ovid (1946 to 17 January 2017), Embase Ovid (1947 to 17 January 2017), LILACS (Latin American and Caribbean Health Sciences Literature Database) (1982 to 17 January 2017), the ISRCTN registry (www.isrctn.com/editAdvancedSearch); searched 17 January 2017, ClinicalTrials.gov (www.clinicaltrials.gov); searched 17 January 2017 and the World Health Organization (WHO) International Clinical Trials Registry Platform (ICTRP) (www.who.int/ictrp/search/en); searched 17 January 2017. We did not use any date or language restrictions in the electronic searches for trials. We also searched conference proceedings to identify additional studies.

Selection criteria

We included only randomised controlled trials (RCTs) that compared Nd:YAG laser vitreolysis to pars plana vitrectomy for treatment of symptomatic floaters.

Copyright © 2017 The Cochrane Collaboration. Published by John Wiley & Sons, Ltd.

[Intervention Review]

Laser peripheral iridoplasty for angle-closure

Wai Siene Ng[1], Ghee Soon Ang[2], Augusto Azuara-Blanco[3]

[1] c/o Cochrane Eyes and Vision, ICEH, London School of Hygiene & Tropical Medicine, London, UK. [2] Department of Ophthalmology, Aberdeen Royal Infirmary, Aberdeen, UK. [3] Health Services Research Unit, University of Aberdeen, Aberdeen, UK

Contact address: Wai Siene Ng, c/o Cochrane Eyes and Vision, ICEH, London School of Hygiene & Tropical Medicine, Keppel Street, London, WC1E 7HT, UK. waisiene@doctors.org.uk.

Editorial group: Cochrane Eyes and Vision Group.
Publication status and date: New search for studies and content updated (no change to conclusions), published in Issue 2, 2012.
Review content assessed as up-to-date: 5 January 2012.

Citation: Ng WS, Ang GS, Azuara-Blanco A. Laser peripheral iridoplasty for angle-closure. *Cochrane Database of Systematic Reviews* 2012, Issue 2. Art. No.: CD006746. DOI: 10.1002/14651858.CD006746.pub3.

Copyright © 2012 The Cochrane Collaboration. Published by John Wiley & Sons, Ltd.

ABSTRACT

Background

Angle-closure glaucoma is a leading cause of irreversible blindness in the world. Treatment is aimed at opening the anterior chamber angle and lowering the IOP with medical and/or surgical treatment (e.g. trabeculectomy, lens extraction). Laser iridotomy works by eliminating pupillary block and widens the anterior chamber angle in the majority of patients. When laser iridotomy fails to open the anterior chamber angle, laser iridoplasty may be recommended as one of the options in current standard treatment for angle-closure. Laser peripheral iridoplasty works by shrinking and pulling the peripheral iris tissue away from the trabecular meshwork. Laser peripheral iridoplasty can be used for crisis of acute angle-closure and also in non-acute situations.

Objectives

To assess the effectiveness of laser peripheral iridoplasty in the treatment of narrow angles (i.e. primary angle-closure suspect), primary angle-closure (PAC) or primary angle-closure glaucoma (PACG) in non-acute situations when compared with any other intervention. In this review, angle-closure will refer to patients with narrow angles (PACs), PAC and PACG.

Search methods

We searched CENTRAL (which contains the Cochrane Eyes and Vision Group Trials Register) (*The Cochrane Library* 2011, Issue 12), MEDLINE (January 1950 to January 2012), EMBASE (January 1980 to January 2012), Latin American and Caribbean Literature on Health Sciences (LILACS) (January 1982 to January 2012), the *meta*Register of Controlled Trials (*m*RCT) (www.controlled-trials.com), ClinicalTrials.gov (www.clinicaltrials.gov) and the WHO International Clinical Trials Registry Platform (ICTRP) (www.who.int/ictrp/search/en). There were no date or language restrictions in the electronic searches for trials. The electronic databases were last searched on 5 January 2012.

Selection criteria

We included only randomised controlled trials (RCTs) in this review. Patients with narrow angles, PAC or PACG were eligible. We excluded studies that included only patients with acute presentations, using laser peripheral iridoplasty to break acute crisis.

Data collection and analysis

No analysis was carried out as only one trial was included in the review.

[Intervention Review]

Cyclodestructive procedures for non-refractory glaucoma

Manuele Michelessi[1], Amanda K Bicket[2], Kristina Lindsley[3]

[1]Ophthalmology, Fondazione G.B. Bietti per lo studio e la ricerca in Oftalmolologia-IRCCS, Rome, Italy. [2]Department of Ophthalmology, Wilmer Eye Institute, Johns Hopkins University School of Medicine, Baltimore, Maryland, USA. [3]Department of Epidemiology, Johns Hopkins Bloomberg School of Public Health, Baltimore, Maryland, USA

Contact address: Kristina Lindsley, Department of Epidemiology, Johns Hopkins Bloomberg School of Public Health, 615 North Wolfe Street, Mail Room E6132, Baltimore, Maryland, 21205, USA. klindsley@jhu.edu.

Editorial group: Cochrane Eyes and Vision Group.
Publication status and date: New, published in Issue 4, 2018.

Citation: Michelessi M, Bicket AK, Lindsley K. Cyclodestructive procedures for non-refractory glaucoma. *Cochrane Database of Systematic Reviews* 2018, Issue 4. Art. No.: CD009313. DOI: 10.1002/14651858.CD009313.pub2.

Copyright © 2018 The Cochrane Collaboration. Published by John Wiley & Sons, Ltd.

ABSTRACT

Background

Glaucoma is a leading cause of blindness worldwide. It results in a progressive loss of peripheral vision and, in late stages, loss of central vision leading to blindness. Early treatment of glaucoma aims to prevent or delay vision loss. Elevated intraocular pressure (IOP) is the main causal modifiable risk factor for glaucoma. Aqueous outflow obstruction is the main cause of IOP elevation, which can be mitigated either by increasing outflow or reducing aqueous humor production. Cyclodestructive procedures use various methods to target and destroy the ciliary body epithelium, the site of aqueous humor production, thereby lowering IOP. The most common approach is laser cyclophotocoagulation.

Objectives

To assess the effectiveness and safety of cyclodestructive procedures for the management of non-refractory glaucoma (i.e. glaucoma in an eye that has not undergone incisional glaucoma surgery). We also aimed to compare the effect of different routes of administration, laser delivery instruments, and parameters of cyclophotocoagulation with respect to IOP control, visual acuity, pain control, and adverse events.

Search methods

We searched the Cochrane Central Register of Controlled Trials (CENTRAL) (which contains the Cochrane Eyes and Vision Trials Register) (2017, Issue 8); Ovid MEDLINE; Embase.com; LILACS; the *meta*Register of Controlled Trials (*m*RCT) and ClinicalTrials.gov. The date of the search was 7 August 2017. We also searched the reference lists of reports from included studies.

Selection criteria

We included randomized controlled trials of participants who had undergone cyclodestruction as a primary treatment for glaucoma. We included only head-to-head trials that had compared cyclophotocoagulation to other procedural interventions, or compared cyclophotocoagulation using different types of lasers, delivery methods, parameters, or a combination of these factors.

Data collection and analysis

Two review authors independently screened search results, assessed risks of bias, extracted data, and graded the certainty of the evidence in accordance with Cochrane standards.

Copyright © 2018 The Cochrane Collaboration. Published by John Wiley & Sons, Ltd.

[Intervention Review]

Laser trabeculoplasty for open angle glaucoma

Christiane R Rolim de Moura[1], Augusto Paranhos Jr[1], Richard Wormald[2]

[1]Ophthalmology, Universidade Federal de São Paulo, Escola Paulista de Medicina, São Paulo, Brazil. [2]Cochrane Eyes and Vision Group, ICEH, London School of Hygiene & Tropical Medicine, London, UK

Contact address: Christiane R Rolim de Moura, Ophthalmology, Universidade Federal de São Paulo, Escola Paulista de Medicina, Rua Helena, 309 cj 15, São Paulo, São Paulo, 04006-002, Brazil. chrm@terra.com.br .

Editorial group: Cochrane Eyes and Vision Group.
Publication status and date: Edited (no change to conclusions), published in Issue 1, 2009.
Review content assessed as up-to-date: 16 August 2007.

Citation: Rolim de Moura CR, Paranhos Jr A, Wormald R. Laser trabeculoplasty for open angle glaucoma. *Cochrane Database of Systematic Reviews* 2007, Issue 4. Art. No.: CD003919. DOI: 10.1002/14651858.CD003919.pub2.

Copyright © 2009 The Cochrane Collaboration. Published by John Wiley & Sons, Ltd.

ABSTRACT

Background

Open angle glaucoma (OAG) is an important cause of blindness worldwide. Laser trabeculoplasty, a treatment modality, still does not have a clear position in the treatment sequence.

Objectives

The objective of this review was to study the effects of laser trabeculoplasty for OAG.

Search methods

We identified trials from CENTRAL in *The Cochrane Library,* MEDLINE, EMBASE, LILACS and manual searching. We also contacted researchers in the field.

Selection criteria

We included randomised controlled trials comparing laser trabeculoplasty with no intervention, with medical treatment, or with surgery. We also included trials comparing different technical modalities of laser trabeculoplasty.

Data collection and analysis

Two authors independently assessed trial quality and extracted the data. We contacted trial investigators for missing information.

Main results

This review included 19 trials involving 2137 participants. Only five trials fulfilled the criteria of good methodological quality. One trial compared laser trabeculoplasty with topical beta-blocker to no intervention in early glaucoma. The risk of glaucoma progression was higher in the control group at six years of follow up (risk ratio (RR) 0.71 95% confidence interval (CI) 0.53 to 0.95). No difference in health-related quality of life was observed between the two groups. Three trials compared laser trabeculoplasty to medication (regimens used before the 1990s) in people with newly diagnosed OAG. The risk of uncontrolled intraocular pressure (IOP) was higher in the medication group compared to the trabeculoplasty group at six months and two years of follow up. Three trials compared laser trabeculoplasty with trabeculectomy. The risk of uncontrolled IOP was significantly higher in the trabeculoplasty group at six months but significant heterogeneity was observed at two years. Diode and selective laser are compared to argon laser trabeculoplasty in three trials and there is some evidence showing a comparable effect in controlling IOP at six months and one year of follow up.

Copyright © 2009 The Cochrane Collaboration. Published by John Wiley & Sons, Ltd.

[Intervention Review]

Laser-assisted cataract surgery versus standard ultrasound phacoemulsification cataract surgery

Alexander C Day[1], Daniel M Gore[2], Catey Bunce[3], Jennifer R Evans[4]

[1]NIHR Biomedical Research Centre at Moorfields Eye Hospital NHS Foundation Trust and UCL Institute of Ophthalmology, London, UK. [2]Anterior Segment, Moorfields Eye Hospital NHS Foundation Trust, London, UK. [3]Research and Development Department, NIHR Biomedical Research Centre at Moorfields Eye Hospital NHS Foundation Trust and UCL Institute of Ophthalmology, London, UK. [4]Cochrane Eyes and Vision, ICEH, London School of Hygiene & Tropical Medicine, London, UK

Contact address: Alexander C Day, NIHR Biomedical Research Centre at Moorfields Eye Hospital NHS Foundation Trust and UCL Institute of Ophthalmology, 11 - 43 Bath Street, London, EC1V 9EL, UK. alex.day@ucl.ac.uk.

Editorial group: Cochrane Eyes and Vision Group.
Publication status and date: New, published in Issue 7, 2016.

Citation: Day AC, Gore DM, Bunce C, Evans JR. Laser-assisted cataract surgery versus standard ultrasound phacoemulsification cataract surgery. *Cochrane Database of Systematic Reviews* 2016, Issue 7. Art. No.: CD010735. DOI: 10.1002/14651858.CD010735.pub2.

Copyright © 2016 The Cochrane Collaboration. Published by John Wiley & Sons, Ltd.

ABSTRACT

Background

Cataract is the leading cause of blindness in the world, and cataract surgery is one of the most commonly performed operations in the Western world. Preferred surgical techniques have changed dramatically over the past half century with associated improvements in outcomes and safety. Femtosecond laser platforms that can accurately and reproducibly perform key steps in cataract surgery, including corneal incisions, capsulotomy and lens fragmentation, are now available. The potential advantages of laser-assisted surgery are broad, and include greater safety and better visual outcomes through greater precision and reproducibility.

Objectives

To compare the effectiveness of laser-assisted cataract surgery with standard ultrasound phacoemulsification cataract surgery by gathering evidence on safety from randomised controlled trials (RCTs).

Search methods

We searched CENTRAL (which contains the Cochrane Eyes and Vision Trials Register) (2016, Issue 4), Ovid MEDLINE, Ovid MEDLINE In-Process and Other Non-Indexed Citations, Ovid MEDLINE Daily, Ovid OLDMEDLINE (January 1946 to May 2016), EMBASE (January 1980 to May 2016), Latin American and Caribbean Health Sciences Literature Database (LILACS) (January 1982 to May 2016), the ISRCTN registry (www.isrctn.com/editAdvancedSearch), ClinicalTrials.gov (www.clinicaltrials.gov), the World Health Organization (WHO) International Clinical Trials Registry Platform (ICTRP) (www.who.int/ictrp/search/en) and the U.S. Food and Drugs Administration (FDA) website (www.fda.gov). We did not use any date or language restrictions in the electronic searches for trials. We last searched the electronic databases on 10 May 2016.

Selection criteria

We included randomised controlled trials where laser-assisted cataract surgery was compared to standard ultrasound phacoemulsification cataract surgery. We graded the certainty of the evidence using GRADE.

Copyright © 2016 The Cochrane Collaboration. Published by John Wiley & Sons, Ltd.

[Intervention Review]

Macular translocation for neovascular age-related macular degeneration

Chiara M Eandi[1], Fabrizio Giansanti[2], Gianni Virgili[2]

[1]Department of Clinical Physiopathology, Eye Clinic, University of Torino, Torino, Italy. [2]Department of Neuro-Oto-Ophthalmological Surgical Sciences, Eye Clinic, University of Florence, Florence, Italy

Contact address: Chiara M Eandi, Department of Clinical Physiopathology, Eye Clinic, University of Torino, Via Juvarra 19, Torino, 10122, Italy. chiara.eandi@unito.it.

Editorial group: Cochrane Eyes and Vision Group.
Publication status and date: Edited (no change to conclusions), published in Issue 3, 2009.
Review content assessed as up-to-date: 20 July 2008.

Citation: Eandi CM, Giansanti F, Virgili G. Macular translocation for neovascular age-related macular degeneration. *Cochrane Database of Systematic Reviews* 2008, Issue 4. Art. No.: CD006928. DOI: 10.1002/14651858.CD006928.pub2.

Copyright © 2009 The Cochrane Collaboration. Published by John Wiley & Sons, Ltd.

ABSTRACT

Background

Macular translocation has been proposed by vitreoretinal surgeons to displace the neuroretinal tissue onto healthy retinal pigment epithelium and choroid when the macula has been invaded by subretinal neovascularisation.

Objectives

This review aims at assessing the effectiveness of macular translocation for preserving or improving vision in patients with neovascular age-related macular degeneration (AMD).

Search methods

We searched the Cochrane Central Register of Controlled Trials (CENTRAL) in *The Cochrane Library*, MEDLINE, EMBASE and Caribbean Literature on Health Sciences (LILACS). There were no language or date restrictions in the search for trials.The electronic databases were last searched on 21 July 2008.

Selection criteria

We included randomised or quasi randomised controlled trials comparing macular translocation with any other treatment or observation.

Data collection and analysis

Two authors independently extracted the data. The risk ratio (RR) of visual loss and visual gain was estimated at one year after treatment.

Main results

Only one small unblinded study on 50 people compared full macular translocation with photodynamic therapy (PDT) in AMD patients with predominantly classic subfoveal choroidal neovascularisation (CNV). At the last examination, performed in most of the cases after one year, there was no difference in the rate of visual loss of 3 or more lines (translocation versus PDT: RR 0.56, 95% confidence interval (CI) 0.22 to 1.43), as well as in the mean change of contrast sensitivity (1 letter favouring translocation; 95% CI -3.51 to 5.51) and the rate of recurrence of CNV (translocation versus PDT: RR 1.56, 95% CI 0.83 to 2.91). Other outcomes significantly favoured translocation, such as the gain of 3 or more ETDRS lines (RR 21, 95% CI 1.30 to 340.02), the mean change of visual acuity (mean difference (MD) 14.60, 95% CI 5.39 to 23.81) and the mean change of near visual acuity score (MD 17.80, 95% CI 3.98 to 31.62) which is obtained with an algorithm. Serious complications reported after macular translocation were retinal detachment in 6/25 patients and diplopia requiring prismatic correction in 5/25 patients.

Copyright © 2009 The Cochrane Collaboration. Published by John Wiley & Sons, Ltd.

[Intervention Review]

Optical reading aids for children and young people with low vision

Lucy Barker[1], Rachel Thomas[2], Gary Rubin[3], Annegret Dahlmann-Noor[4]

[1]Moorfields Eye Hospital NHS Foundation Trust, London, UK. [2]Optometry, Moorfields at Bedford Hospital, Bedford, UK. [3]Institute of Ophthalmology, London, UK. [4]NIHR Biomedical Research Centre at Moorfields Eye Hospital and UCL Institute of Ophthalmology, London, UK

Contact address: Lucy Barker, Moorfields Eye Hospital NHS Foundation Trust, 162 City Road, London, EC1V 2PD, UK. leb@doctors.org.uk.

Editorial group: Cochrane Eyes and Vision Group.
Publication status and date: New, published in Issue 3, 2015.

Citation: Barker L, Thomas R, Rubin G, Dahlmann-Noor A. Optical reading aids for children and young people with low vision. *Cochrane Database of Systematic Reviews* 2015, Issue 3. Art. No.: CD010987. DOI: 10.1002/14651858.CD010987.pub2.

Copyright © 2015 The Cochrane Collaboration. Published by John Wiley & Sons, Ltd.

ABSTRACT

Background

Low vision in childhood is a significant barrier to learning and development, particularly for reading and education. Optical low vision aids may be used to maximise the child's functional vision. The World Health Organization (WHO) has previously highlighted the importance of the use of low vision aids in managing children with visual impairment across the world.

Objectives

To assess the effect of optical low vision aids on reading in children and young people with low vision.

Search methods

We searched CENTRAL (which contains the Cochrane Eyes and Vision Group Trials Register) (2014, Issue 12), Ovid MEDLINE, Ovid MEDLINE In-Process and Other Non-Indexed Citations, Ovid MEDLINE Daily, Ovid OLDMEDLINE (January 1946 to January 2015), EMBASE (January 1980 to January 2015), the Health Technology Assessment Programme (HTA) (www.hta.ac.uk/), the ISRCTN registry (www.isrctn.com/editAdvancedSearch), ClinicalTrials.gov (www.clinicaltrials.gov) and the World Health Organization (WHO) International Clinical Trials Registry Platform (ICTRP) (www.who.int/ictrp/search/en). We did not use any date or language restrictions in the electronic searches for trials. We last searched the electronic databases on 8 January 2015.

We also used manual searching to check the references listed in retrieved articles. Manufacturers of low vision aids were contacted to request any information about studies or research regarding their products.

Selection criteria

We planned to include randomised controlled trials (RCTs) and quasi-RCTs where any optical low vision aid was compared to standard refractive correction in children and young people aged between 5 and 16 years of age with low vision as defined by the WHO. We planned to include within-person design studies where the order of presentation of devices was randomised.

Data collection and analysis

Two authors independently reviewed the search results for eligibility .

[Intervention Review]

Medical interventions for acanthamoeba keratitis

Majed Alkharashi[1], Kristina Lindsley[2], Hua Andrew Law[2], Shameema Sikder[3]

[1]Department of Ophthalmology, King Saud University, Riyadh, Saudi Arabia. [2]Department of Epidemiology, Johns Hopkins Bloomberg School of Public Health, Baltimore, Maryland, USA. [3]Wilmer Ophthalmological Institute, Johns Hopkins University School of Medicine, Baltimore, Maryland, USA

Contact address: Majed Alkharashi, Department of Ophthalmology, King Saud University, Riyadh, Saudi Arabia. majedsk@hotmail.com.

Editorial group: Cochrane Eyes and Vision Group.
Publication status and date: New, published in Issue 2, 2015.
Review content assessed as up-to-date: 9 January 2015.

Citation: Alkharashi M, Lindsley K, Law HA, Sikder S. Medical interventions for acanthamoeba keratitis. *Cochrane Database of Systematic Reviews* 2015, Issue 2. Art. No.: CD010792. DOI: 10.1002/14651858.CD010792.pub2.

Copyright © 2015 The Cochrane Collaboration. Published by John Wiley & Sons, Ltd.

ABSTRACT

Background

Acanthamoeba are microscopic, free-living, single-celled organisms which can infect the eye and lead to *Acanthamoeba* keratitis (AK). AK can result in loss of vision in the infected eye or loss of eye itself; however, there are no formal guidelines or standards of care for the treatment of AK.

Objectives

To evaluate the relative effectiveness and safety of medical therapy for the treatment of AK.

Search methods

We searched CENTRAL (which contains the Cochrane Eyes and Vision Group Trials Register) (2015, Issue 1), Ovid MEDLINE, Ovid MEDLINE In-Process and Other Non-Indexed Citations, Ovid MEDLINE Daily, Ovid OLDMEDLINE (January 1946 to January 2015), EMBASE (January 1980 to January 2015), PubMed (1948 to January 2015), Latin American and Caribbean Health Sciences Literature Database (LILACS) (1982 to January 2015), the *meta*Register of Controlled Trials (*m*RCT) (www.controlled-trials.com), ClinicalTrials.gov (www.clinicaltrials.gov) and the World Health Organization (WHO) International Clinical Trials Registry Platform (ICTRP) (www.who.int/ictrp/search/en). We did not use any date or language restrictions in the electronic search for trials. We last searched the electronic databases on 9 January 2015.

Selection criteria

We included randomized controlled trials (RCTs) of medical therapy for AK, regardless of the participants' age, sex, or etiology of disease. We included studies that compared either anti-amoeba therapy (drugs used alone or in combination with other medical therapies) with no anti-amoeba therapy or one anti-amoeba therapy with another anti-amoeba therapy.

Data collection and analysis

Two authors independently screened search results and full-text reports, assessed risk of bias, and abstracted data. We used standard methodological procedures as set forth by the Cochrane Collaboration.

Copyright © 2015 The Cochrane Collaboration. Published by John Wiley & Sons, Ltd.

[Intervention Review]

Medical interventions for traumatic hyphema

Almutez Gharaibeh[1], Howard I Savage[2], Roberta W Scherer[3], Morton F Goldberg[4], Kristina Lindsley[5]

[1]Department of Special Surgery-Ophthalmology, Faculty of Medicine, The University of Jordan, Amman, Jordan. [2]Kaiser Permanente Largo Medical Center, Largo, Maryland, USA. [3]Center for Clinical Trials, Johns Hopkins University Bloomberg School of Public Health, Baltimore, MD, USA. [4]Wilmer Eye Institute, Johns Hopkins University School of Medicine, Baltimore, Maryland, USA. [5]Department of Epidemiology, Johns Hopkins Bloomberg School of Public Health, Baltimore, Maryland, USA

Contact address: Roberta W Scherer, Center for Clinical Trials, Johns Hopkins University Bloomberg School of Public Health, Room W5010, 615 N. Wolfe St., Baltimore, MD, 21205, USA. rscherer@jhsph.edu.

Editorial group: Cochrane Eyes and Vision Group.
Publication status and date: New search for studies and content updated (no change to conclusions), published in Issue 12, 2013.
Review content assessed as up-to-date: 30 August 2013.

Citation: Gharaibeh A, Savage HI, Scherer RW, Goldberg MF, Lindsley K. Medical interventions for traumatic hyphema. *Cochrane Database of Systematic Reviews* 2013, Issue 12. Art. No.: CD005431. DOI: 10.1002/14651858.CD005431.pub3.

Copyright © 2013 The Cochrane Collaboration. Published by John Wiley & Sons, Ltd.

ABSTRACT

Background

Traumatic hyphema is the entry of blood into the anterior chamber (the space between the cornea and iris) subsequent to a blow or a projectile striking the eye. Hyphema uncommonly causes permanent loss of vision. Associated trauma (e.g. corneal staining, traumatic cataract, angle recession glaucoma, optic atrophy, etc.) may seriously affect vision. Such complications may lead to permanent impairment of vision. Patients with sickle cell trait/disease may be particularly susceptible to increases of elevated intraocular pressure. If rebleeding occurs, the rates and severity of complications increase.

Objectives

To assess the effectiveness of various medical interventions in the management of traumatic hyphema.

Search methods

We searched CENTRAL (which contains the Cochrane Eyes and Vision Group Trials Register) (*The Cochrane Library* 2013, Issue 8), Ovid MEDLINE, Ovid MEDLINE In-Process and Other Non-Indexed Citations, Ovid MEDLINE Daily, Ovid OLDMEDLINE (January 1946 to August 2013), EMBASE (January 1980 to August 2013), the *meta*Register of Controlled Trials (*m*RCT) (www.controlled-trials.com), ClinicalTrials.gov (www.clinicaltrials.gov) and the WHO International Clinical Trials Registry Platform (ICTRP) (www.who.int/ictrp/search/en). We did not use any date or language restrictions in the electronic searches for trials. We last searched the electronic databases on 30 August 2013.

Selection criteria

Two authors independently assessed the titles and abstracts of all reports identified by the electronic and manual searches. In this review, we included randomized and quasi-randomized trials that compared various medical interventions versus other medical interventions or control groups for the treatment of traumatic hyphema following closed globe trauma. We applied no restrictions regarding age, gender, severity of the closed globe trauma, or level of visual acuity at the time of enrolment.

Data collection and analysis

Two authors independently extracted the data for the primary and secondary outcomes. We entered and analyzed data using Review Manager 5. We performed meta-analyses using a fixed-effect model and reported dichotomous outcomes as odds ratios and continuous outcomes as mean differences.

Copyright © 2013 The Cochrane Collaboration. Published by John Wiley & Sons, Ltd.

[Intervention Review]

Ab interno trabecular bypass surgery with Trabectome for open angle glaucoma

Kuang Hu[1], Gus Gazzard[1], Catey Bunce[2], Richard Wormald[2,3]

[1]Moorfields Eye Hospital NHS Foundation Trust, London, UK. [2]Research and Development Department, NIHR Biomedical Research Centre at Moorfields Eye Hospital NHS Foundation Trust and UCL Institute of Ophthalmology, London, UK. [3]Cochrane Eyes and Vision Group, ICEH, London School of Hygiene & Tropical Medicine, London, UK

Contact address: Kuang Hu, Moorfields Eye Hospital NHS Foundation Trust, 162 City Road, London, UK. kuang.hu@moorfields.nhs.uk.

Editorial group: Cochrane Eyes and Vision Group.
Publication status and date: New, published in Issue 8, 2016.
Review content assessed as up-to-date: 12 May 2016.

Citation: Hu K, Gazzard G, Bunce C, Wormald R. Ab interno trabecular bypass surgery with Trabectome for open angle glaucoma. *Cochrane Database of Systematic Reviews* 2016, Issue 8. Art. No.: CD011693. DOI: 10.1002/14651858.CD011693.pub2.

Copyright © 2016 The Cochrane Collaboration. Published by John Wiley & Sons, Ltd.

ABSTRACT

Background

Glaucoma is the leading cause of irreversible blindness. Minimally invasive surgical techniques, such as ab interno trabecular bypass surgery, have been introduced to prevent glaucoma progressing.

Objectives

The main objective was to assess the results at two years of ab interno trabecular bypass surgery with Trabectome for open angle glaucoma in comparison to conventional medical, laser, or surgical treatment in terms of efficacy and safety. A secondary objective was to examine the effects of Trabectome surgery in people who have concomitant phacoemulsification in comparison to those who do not have concomitant phacoemulsification.

Search methods

We searched CENTRAL (which contains the Cochrane Eyes and Vision Trials Register) (2016, Issue 4), Ovid MEDLINE, Ovid MEDLINE In-Process and Other Non-Indexed Citations, Ovid MEDLINE Daily, Ovid OLDMEDLINE (January 1946 to May 2016), EMBASE (January 1980 to May 2016), the ISRCTN registry (www.isrctn.com/editAdvancedSearch), ClinicalTrials.gov (www.clinicaltrials.gov), and the World Health Organization (WHO) International Clinical Trials Registry Platform (ICTRP) (www.who.int/ictrp/search/en). We did not use any date or language restrictions in the electronic searches for trials. We last searched the electronic databases on 12 May 2016.

Selection criteria

We included only randomised controlled trials (RCTs) of ab interno trabecular bypass surgery with Trabectome.

Data collection and analysis

We planned to have two review authors independently extract data from reports of included studies using a data collection form.

Copyright © 2016 The Cochrane Collaboration. Published by John Wiley & Sons, Ltd.

[Intervention Review]

Mohs micrographic surgery versus surgical excision for periocular basal cell carcinoma

Krishnamoorthy Narayanan[1], Omar H Hadid[2], Eric A Barnes[2]

[1]Department of Ophthalmology, County Durham and Darlington NHS Foundation Trust, Durham, UK. [2]Department of Ophthalmology, Royal Victoria Infirmary, Newcastle upon Tyne, UK

Contact address: Krishnamoorthy Narayanan, Department of Ophthalmology, County Durham and Darlington NHS Foundation Trust, Durham, Tyne & Wear, UK. krishnamoorthy.narayanan27@gmail.com.

Editorial group: Cochrane Eyes and Vision Group.
Publication status and date: New search for studies and content updated (no change to conclusions), published in Issue 12, 2014.
Review content assessed as up-to-date: 25 February 2014.

Citation: Narayanan K, Hadid OH, Barnes EA. Mohs micrographic surgery versus surgical excision for periocular basal cell carcinoma. *Cochrane Database of Systematic Reviews* 2014, Issue 12. Art. No.: CD007041. DOI: 10.1002/14651858.CD007041.pub4.

Copyright © 2014 The Cochrane Collaboration. Published by John Wiley & Sons, Ltd.

ABSTRACT

Background

Basal cell carcinoma (BCC) is the commonest skin cancer in the white population. It is traditionally treated by surgical excision (SE) or by Mohs micrographic surgery (MMS).

Objectives

The objective of this review was to compare the effectiveness, cost, complications and acceptability of periocular BCCs when operated by MMS or SE.

Search methods

We searched CENTRAL (which contains the Cochrane Eyes and Vision Group Trials Register) (2014, Issue 1), Ovid MEDLINE, Ovid MEDLINE In-Process and Other Non-Indexed Citations, Ovid MEDLINE Daily, Ovid OLDMEDLINE (January 1946 to February 2014), EMBASE (January 1980 to February 2014), the *meta*Register of Controlled Trials (*m*RCT) (www.controlled-trials.com), ClinicalTrials.gov (www.clinicaltrials.gov) and the World Health Organization (WHO) International Clinical Trials Registry Platform (ICTRP) (www.who.int/ictrp/search/en). We did not use any date or language restrictions in the electronic searches for trials. We last searched the electronic databases on 25 February 2014.

Selection criteria

We planned to include only randomised controlled trials (RCTs) comparing SE with MMS for treatment of periocular BCC.

Data collection and analysis

We did not find any studies that met the inclusion criteria for this review.

Main results

We did not find any studies that met the inclusion criteria for this review and hence none were included for analysis. Results of non-randomised studies describing the individual techniques are reported.

[Intervention Review]

N-acetylcarnosine (NAC) drops for age-related cataract

Vincent DJ-P Dubois[1], Andrew Bastawrous[2,3]

[1]Elective Care Centre, Aintree University Hospital NHS Foundation Trust, Liverpool, UK. [2]Mersey Deanery, Liverpool, UK. [3]International Centre for Eye Health, London School of Hygiene & Tropical Medicine, London, UK

Contact address: Vincent DJ-P Dubois, Elective Care Centre, Aintree University Hospital NHS Foundation Trust, Longmore Lane, Liverpool, L9 7AL, UK. vincent.dubois@aintree.nhs.uk.

Editorial group: Cochrane Eyes and Vision Group.
Publication status and date: New, published in Issue 2, 2017.

Citation: Dubois VDJP, Bastawrous A. N-acetylcarnosine (NAC) drops for age-related cataract. *Cochrane Database of Systematic Reviews* 2017, Issue 2. Art. No.: CD009493. DOI: 10.1002/14651858.CD009493.pub2.

Copyright © 2017 The Cochrane Collaboration. Published by John Wiley & Sons, Ltd.

ABSTRACT

Background

Cataract is the leading cause of world blindness. The only available treatment for cataract is surgery. Surgery requires highly-trained individuals with expensive operating facilities. Where these are not available, patients go untreated. A form of treatment that did not involve surgery would be a useful alternative for people with symptomatic cataract who are unable or unwilling to undergo surgery. If an eye drop existed that could reverse or even prevent progression of cataract, then this would be a useful additional treatment option.

Cataract tends to result from oxidative stress. The protein, L-carnosine, is known to have an antioxidant effect on the cataractous lens, so biochemically there is sound logic for exploring L-carnosine as an agent to reverse or even prevent progression of cataract. When applied as an eye drop, L-carnosine cannot penetrate the eye. However, when applied to the surface of the eye, N-acetylcarnosine (NAC) penetrates the cornea into the front chamber of the eye (near to where the cataract is), where it is metabolised into L-carnosine. Hence, it is possible that use of NAC eye drops may reverse or even prevent progression of cataract, thereby improving vision and quality of life.

Objectives

To assess the effectiveness of NAC drops to prevent or reverse the progression of cataract.

Search methods

We searched CENTRAL (which contains the Cochrane Eyes and Vision Trials Register) (2016, Issue 6), Ovid MEDLINE, Ovid MEDLINE In-Process and Other Non-Indexed Citations, Ovid MEDLINE Daily, Ovid OLDMEDLINE (January 1946 to June 2016), Embase (January 1980 to June 2016), Allied and Complementary Medicine Database (AMED) (January 1985 to June 2016), Cumulative Index to Nursing and Allied Health Literature (CINAHL) (1982 to June 2016), the ISRCTN registry (www.isrctn.com/editAdvancedSearch), ClinicalTrials.gov (www.clinicaltrials.gov) and the World Health Organization (WHO) International Clinical Trials Registry Platform (ICTRP) (www.who.int/ictrp/search/en). We did not use any date or language restrictions in the electronic searches for trials. We last searched the electronic databases on 28 June 2016. We handsearched the American Society of Cataract and Refractive Surgery (ASCRS) and the European Society of Cataract and Refractive Surgeons (ESCRS) meetings from 2005 until September 2015.

Selection criteria

We planned to include randomized or quasi-randomised controlled trials where NAC was compared to control in people with age-related cataract.

Copyright © 2017 The Cochrane Collaboration. Published by John Wiley & Sons, Ltd.

[Intervention Review]

Neuroprotection for treatment of glaucoma in adults

Dayse F Sena[1], Kristina Lindsley[2]

[1]Massachusetts Eye and Ear Infirmary, Boston, Massachusetts, USA. [2]Department of Epidemiology, Johns Hopkins Bloomberg School of Public Health, Baltimore, Maryland, USA

Contact address: Dayse F Sena, Massachusetts Eye and Ear Infirmary, 243 Charles St, Connecting Building 703, Boston, Massachusetts, 02114, USA. sena.dayse@gmail.com.

Editorial group: Cochrane Eyes and Vision Group.
Publication status and date: New search for studies and content updated (no change to conclusions), published in Issue 1, 2017.

Citation: Sena DF, Lindsley K. Neuroprotection for treatment of glaucoma in adults. *Cochrane Database of Systematic Reviews* 2017, Issue 1. Art. No.: CD006539. DOI: 10.1002/14651858.CD006539.pub4.

Copyright © 2017 The Cochrane Collaboration. Published by John Wiley & Sons, Ltd.

ABSTRACT

Background

Glaucoma is a heterogeneous group of conditions involving progressive damage to the optic nerve, deterioration of retinal ganglion cells, and ultimately visual field loss. It is a leading cause of blindness worldwide. Open angle glaucoma (OAG), the most common form of glaucoma, is a chronic condition that may or may not present with increased intraocular pressure (IOP). Neuroprotection for glaucoma refers to any intervention intended to prevent optic nerve damage or cell death.

Objectives

The objective of this review was to systematically examine the evidence regarding the effectiveness of neuroprotective agents for slowing the progression of OAG in adults compared with no neuroprotective agent, placebo, or other glaucoma treatment.

Search methods

We searched CENTRAL (which contains the Cochrane Eyes and Vision Trials Register) (2016, Issue 7), Ovid MEDLINE, Epub Ahead of Print, In-Process & Other Non-Indexed Citations, Ovid MEDLINE Daily (January 1946 to August 2016), Embase (January 1980 to August 2016), Latin American and Caribbean Literature on Health Sciences (LILACS) (January 1982 to August 2016), the ISRCTN registry (www.isrctn.com/editAdvancedSearch), ClinicalTrials.gov (www.clinicaltrials.gov), and the World Health Organization (WHO) International Clinical Trials Registry Platform (ICTRP) (www.who.int/ictrp/search/en). We did not use any date or language restrictions in the electronic searches for trials. We last searched the electronic databases on 16 August 2016.

Selection criteria

We included randomised controlled trials (RCTs) in which topical or oral treatments were used for neuroprotection in adults with OAG. Minimum follow-up time was four years.

Data collection and analysis

Two review authors independently reviewed titles and abstracts from the literature searches. We obtained full-text copies of potentially relevant studies and re-evaluated for inclusion. Two review authors independently extracted data related to study characteristics, risk of bias, and outcomes. We identified one trial for this review, thus we performed no meta-analysis. Two studies comparing memantine to placebo are currently awaiting classification until study investigators provide additional study details. We documented reasons for excluding studies from the review.

Copyright © 2017 The Cochrane Collaboration. Published by John Wiley & Sons, Ltd.

[Intervention Review]

Non-steroidal anti-inflammatory agents for treating cystoid macular oedema following cataract surgery

Sobha Sivaprasad[1], Catey Bunce[2], Roxanne Crosby-Nwaobi[3]

[1]Normanby Building, King's College Hospital, London, UK. [2]Research and Development Department, Moorfields Eye Hospital NHS Foundation Trust, London, UK. [3]The Florence Nightingale School of Nursing and Midwifery, King's College London, London, UK

Contact address: Sobha Sivaprasad, Normanby Building, King's College Hospital, Denmark Hill, London, SE5 9RS, UK. senswathi@aol.com.

Editorial group: Cochrane Eyes and Vision Group.
Publication status and date: New search for studies and content updated (no change to conclusions), published in Issue 2, 2012.

Citation: Sivaprasad S, Bunce C, Crosby-Nwaobi R. Non-steroidal anti-inflammatory agents for treating cystoid macular oedema following cataract surgery. *Cochrane Database of Systematic Reviews* 2012, Issue 2. Art. No.: CD004239. DOI: 10.1002/14651858.CD004239.pub3.

Copyright © 2012 The Cochrane Collaboration. Published by John Wiley & Sons, Ltd.

ABSTRACT

Background

Cystoid macular oedema (CMO) is the accumulation of fluid in the central retina (the macula) due to leakage from dilated capillaries. It is the most common cause of poor visual outcome following cataract surgery. The exact cause is unclear. Acute CMO, defined as oedema of less than four months duration, often resolve spontaneously. CMO that persists for four months or more is termed chronic CMO. Different types of non-steroidal anti-inflammatory agents (NSAIDs) are used in the treatment of CMO which may be delivered topically or systemically.

Objectives

To examine the effectiveness of NSAIDs in the treatment of CMO following cataract surgery.

Search methods

We searched CENTRAL (which contains the Cochrane Eyes and Vision Group Trials Register) (*The Cochrane Library* 2011, Issue 7), MEDLINE (January 1950 to August 2011), EMBASE (January 1980 to August 2011), Latin American and Caribbean Health Sciences Literature Database (LILACS) (January 1982 to August 2011), the metaRegister of Controlled Trials (mRCT) (www.controlled-trials.com) (August 2011) and ClinicalTrials.gov (www.clinicaltrials.gov) (August 2011). We searched the reference lists of identified trials. We searched conference abstracts (sessions related to cataract) in The Association for Research in Vision and Ophthalmology (ARVO) 1975 to 2011. We contacted experts in the field and NSAIDs manufacturers for details on published and unpublished trials.There were no language or date restrictions in the search for trials. The electronic databases were last searched on 5 August 2011.

Selection criteria

We included randomised controlled trials evaluating the effects of NSAIDs in the treatment of CMO following cataract surgery.

Data collection and analysis

Two review authors independently extracted data. Since considerable heterogeneity was observed between studies we did not conduct meta-analyses.

Copyright © 2012 The Cochrane Collaboration. Published by John Wiley & Sons, Ltd.

[Intervention Review]

Omega 3 fatty acids for preventing or slowing the progression of age-related macular degeneration

John G Lawrenson[1], Jennifer R Evans[2]

[1]Division of Optometry & Visual Science, City University London, London, UK. [2]Cochrane Eyes and Vision Group, ICEH, London School of Hygiene & Tropical Medicine, London, UK

Contact address: John G Lawrenson, Division of Optometry & Visual Science, City University London, Northampton Square, London, EC1V 0HB, UK. j.g.lawrenson@city.ac.uk.

Editorial group: Cochrane Eyes and Vision Group.
Publication status and date: Edited (no change to conclusions), published in Issue 4, 2015.
Review content assessed as up-to-date: 2 February 2015.

Citation: Lawrenson JG, Evans JR. Omega 3 fatty acids for preventing or slowing the progression of age-related macular degeneration. *Cochrane Database of Systematic Reviews* 2015, Issue 4. Art. No.: CD010015. DOI: 10.1002/14651858.CD010015.pub3.

Copyright © 2015 The Cochrane Collaboration. Published by John Wiley & Sons, Ltd.

ABSTRACT

Background

Evidence from animal models and observational studies in humans has suggested that there is an inverse relationship between dietary intake of omega 3 long-chain polyunsaturated fatty acids (LCPUFA) and risk of developing age-related macular degeneration (AMD) or progression to advanced AMD.

Objectives

To review the evidence that increasing the levels of omega 3 LCPUFA in the diet (either by eating more foods rich in omega 3 or by taking nutritional supplements) prevents AMD or slows the progression of AMD.

Search methods

We searched CENTRAL (which contains the Cochrane Eyes and Vision Group Trials Register) (2015, Issue 1), Ovid MEDLINE, Ovid MEDLINE In-Process and Other Non-Indexed Citations, Ovid MEDLINE Daily, Ovid OLDMEDLINE (January 1946 to February 2015), EMBASE (January 1980 to February 2015), Latin American and Caribbean Health Sciences Literature Database (LILACS) (January 1982 to February 2015), the ISRCTN registry (www.isrctn.com/editAdvancedSearch), ClinicalTrials.gov (www.clinicaltrials.gov) and the World Health Organization (WHO) International Clinical Trials Registry Platform (ICTRP) (www.who.int/ictrp/search/en). We did not use any date or language restrictions in the electronic searches for trials. We last searched the electronic databases on 2 February 2015.

Selection criteria

We included randomised controlled trials (RCTs) where increased dietary intake of omega 3 LCPUFA was compared to placebo or no intervention with the aim of preventing the development of AMD, or slowing its progression.

Data collection and analysis

Both authors independently selected studies, assessed them for risk of bias and extracted data. One author entered data into RevMan 5 and the other author checked the data entry. We conducted a meta-analysis for one primary outcome, progression of AMD, using a fixed-effect inverse variance model.

Copyright © 2015 The Cochrane Collaboration. Published by John Wiley & Sons, Ltd.

[Intervention Review]

Orientation and mobility training for adults with low vision

Gianni Virgili[1], Gary Rubin[2]

[1]Department of Specialised Surgical Sciences, University of Florence, Florence, Italy. [2]Institute of Ophthalmology, London, UK

Contact address: Gianni Virgili, Department of Specialised Surgical Sciences, University of Florence, Via le Morgagni 85, Florence, 50134, Italy. gianni.virgili@unifi.it.

Editorial group: Cochrane Eyes and Vision Group.
Publication status and date: New search for studies and content updated (no change to conclusions), published in Issue 5, 2010.

Citation: Virgili G, Rubin G. Orientation and mobility training for adults with low vision. *Cochrane Database of Systematic Reviews* 2010, Issue 5. Art. No.: CD003925. DOI: 10.1002/14651858.CD003925.pub3.

Copyright © 2010 The Cochrane Collaboration. Published by John Wiley & Sons, Ltd.

ABSTRACT

Background

Orientation and mobility (O&M) training is provided to people who are visually impaired to help them maintain travel independence. It teaches them new orientation and mobility skills to compensate for reduced visual information.

Objectives

The objective of this review was to assess the effects of O&M training, with or without associated devices, for adults with low vision.

Search methods

We searched the Cochrane Central Register of Controlled Trials (CENTRAL) (which contains the Cochrane Eyes and Vision Group Trials Register) (*The Cochrane Library*, 2010, Issue 3), MEDLINE (January 1950 to March 2010), EMBASE (January 1980 to March 2010), Latin American and Caribbean Literature on Health Sciences (LILACS) (January 1982 to March 2010), System for Information on Grey Literature in Europe (OpenSIGLE) (March 2010), the *meta*Register of Controlled Trials (*m*RCT) (www.controlled-trials.com) (March 2010), ClinicalTrials.gov (http://clinicaltrials.gov) (March 2010), ZETOC (March 2010) and the reference lists of retrieved articles. There were no language or date restrictions in the search for trials. The electronic databases were last searched on 31 March 2010.

Selection criteria

We planned to include randomised or quasi-randomised trials comparing O&M training with no training in adults with low vision.

Data collection and analysis

Two authors independently assessed the search results for eligibility, evaluated study quality and extracted the data.

Main results

Two small studies satisfied the inclusion criteria. They were consecutive phases of development of the same training curriculum and assessment tool. The intervention was administered by a volunteer on the basis of written and oral instruction. In both studies the randomisation technique was inadequate, being based on alternation, and masking was not achieved. Training had no effect in the first study but tended to be beneficial in the second but not to a statistically significant extent. Reasons for differences between studies may have been: the high scores obtained in the first study, suggestive of little need for training and small room for further improvement (a ceiling effect), and the refinement of the curriculum allowing better tailoring to patients' specific needs and characteristics, in the second study.

Copyright © 2010 The Cochrane Collaboration. Published by John Wiley & Sons, Ltd.

[Intervention Review]

Psychosocial interventions for improving quality of life outcomes in adults undergoing strabismus surgery

Kelly MacKenzie[1], Joanne Hancox[1], Hayley McBain[2], Daniel G Ezra[3], Gill Adams[4], Stanton Newman[5]

[1]Paediatrics and Strabismus, Moorfields Eye Hospital NHS Foundation Trust, London, UK. [2]School of Health Sciences, City University London, London, UK. [3]Moorfields and UCL Institute of Ophthalmology BMRC, Moorfields Eye Hospital NHS Foundation Trust, London, UK. [4]Moorfields Eye Hospital NHS Foundation Trust, London, UK. [5]City University, London, UK

Contact address: Joanne Hancox, Paediatrics and Strabismus, Moorfields Eye Hospital NHS Foundation Trust, City Road, London, EC1V 2PD, UK. johancox@doctors.org.uk.

Editorial group: Cochrane Eyes and Vision Group.
Publication status and date: New, published in Issue 5, 2016.

Citation: MacKenzie K, Hancox J, McBain H, Ezra DG, Adams G, Newman S. Psychosocial interventions for improving quality of life outcomes in adults undergoing strabismus surgery. *Cochrane Database of Systematic Reviews* 2016, Issue 5. Art. No.: CD010092. DOI: 10.1002/14651858.CD010092.pub4.

Copyright © 2016 The Cochrane Collaboration. Published by John Wiley & Sons, Ltd.

ABSTRACT

Background

Strabismus, also known as squint, can have a debilitating effect on a person's self-esteem, quality of life and mood, as well as increase their feelings of social anxiety and avoidance behaviour. Strabismus surgery can improve both the alignment of a person's eyes and, in appropriate cases, relieve symptoms such as double vision. However, evidence indicates that not all patients experience a meaningful improvement in their quality of life postsurgery. Pre-surgical psychosocial interventions have been found to improve patient reported outcomes in other long-term conditions.

Objectives

To assess the effects of psychosocial interventions versus no intervention on quality of life and psychosocial outcomes in adults undergoing strabismus surgery.

Search methods

We searched CENTRAL (which contains the Cochrane Eyes and Vision group Trials Register) (2016, Issue 1), Ovid MEDLINE, Ovid MEDLINE In-Process and Other Non-Indexed Citations, Ovid MEDLINE Daily, Ovid OLDMEDLINE (January 1946 to February 2016), EMBASE (January 1980 to February 2016), Latin American and Caribbean Health Sciences (LILACS) (January 1982 to February 2016), PsycINFO (January 1967 to February 2016), the ISRCTN registry (www.isrctn.com/editAdvancedSearch), ClinicalTrials.gov (www.clinicaltrials.gov) and the World Health Organization (WHO) International Clinical Trials Registry Platform (ICTRP) (www.who.int/ictrp/search/en). We did not use any date or language restrictions in the electronic searches for trials. We last searched the electronic databases on 15 February 2016.

We also manually searched the *British Orthoptic Journal*, proceedings of the European Strabismological Association (ESA), International Strabismological Association (ISA) and published transactions from the meetings of European Strabismus Association (ESA) and American Association for Pediatric Ophthalmology and Strabismus (AAPOS). These were searched from 1980 to present. We also carried out handsearches of *Psychology and Health*, *British Journal of Health Psychology*, *Health Psychology* and *Annals of Behavioral Medicine*.

Copyright © 2016 The Cochrane Collaboration. Published by John Wiley & Sons, Ltd.

[Intervention Review]

Pentoxifylline for diabetic retinopathy

Carlos César Lopes de Jesus[1], Álvaro N Atallah[2], Orsine Valente[3], Virginia Fernandes Moça Trevisani[4]

[1]Department of Internal Medicine and Therapeutics Discipline, Universidade Federal de São Paulo / Escola Paulista de Medicina, São Paulo, Brazil. [2]Brazilian Cochrane Centre, Universidade Federal de São Paulo / Escola Paulista de Medicina, São Paulo, Brazil. [3]Department of Internal Medicine, Universidade Federal de São Paulo / Escola Paulista de Medicina, São Paulo, Brazil. [4]Rheumatology/Internal Medicine and Therapeutics, UNISA (Santo Amaro University)/UNIFESP (Paulista Medicine School), Jardim Marajoara, Brazil

Contact address: Carlos César Lopes de Jesus, Department of Internal Medicine and Therapeutics Discipline, Universidade Federal de São Paulo / Escola Paulista de Medicina, Rua Pedro de Toledo, 598, São Paulo, Vila Clementino, CEP 04039-001, Brazil. caceloje@gmail.com, caceloje@uol.com.br.

Editorial group: Cochrane Metabolic and Endocrine Disorders Group.
Publication status and date: Edited (no change to conclusions), published in Issue 1, 2009.

Citation: Lopes de Jesus CC, Atallah ÁN, Valente O, Trevisani VFM. Pentoxifylline for diabetic retinopathy. *Cochrane Database of Systematic Reviews* 2008, Issue 2. Art. No.: CD006693. DOI: 10.1002/14651858.CD006693.pub2.

Copyright © 2009 The Cochrane Collaboration. Published by John Wiley & Sons, Ltd.

ABSTRACT

Background

There is increasing evidence that capillary occlusion plays an important part in the development of diabetic retinopathy. Disaggregants, such as pentoxyfilline may influence the outcome and progression of diabetic retinopathy, but no systematic review of the literature on its efficacy and safety has been published to examine this hypothesis.

Objectives

The aim of the current research was to review the literature in a systematic way in order to assess the effects of pentoxyfilline for diabetic retinopathy in methodologically robust trials. The null hypothesis was that pentoxyfilline has no influence on the progression of diabetic retinopathy or blindness.

Search methods

A systematic search of electronic databases was carried out to identify publications. Relevant papers, written in any language, were accessed and assessed for data.

Selection criteria

Only randomized controlled clinical trials (RCTs) evaluating the effects of pentoxyfilline in the treatment of diabetic retinopathy were to be included.

Data collection and analysis

Two authors independently assessed studies for inclusion criteria and for risk of bias.

Main results

A total of 97 publications were identified by the electronic search and two authors checked the abstracts. Of these, 17 were identified as potentially relevant trials providing information about treatment of patients with diabetic retinopathy using pentoxyfilline and were read in full. Unfortunately, no publication fulfilled our inclusion criteria.

Copyright © 2009 The Cochrane Collaboration. Published by John Wiley & Sons, Ltd.

[Intervention Review]

Peripheral iridotomy for pigmentary glaucoma

Manuele Michelessi[1], Kristina Lindsley[2]

[1]Ophthalmology, Fondazione G.B. Bietti per lo studio e la ricerca in Oftalmolologia-IRCCS, Rome, Italy. [2]Department of Epidemiology, Johns Hopkins Bloomberg School of Public Health, Baltimore, Maryland, USA

Contact address: Manuele Michelessi, Ophthalmology, Fondazione G.B. Bietti per lo studio e la ricerca in Oftalmolologia-IRCCS, Via Livenza n 3, Rome, 00198, Italy. manuele_michelessi@yahoo.it.

Editorial group: Cochrane Eyes and Vision Group.
Publication status and date: New, published in Issue 2, 2016.
Review content assessed as up-to-date: 2 November 2015.

Citation: Michelessi M, Lindsley K. Peripheral iridotomy for pigmentary glaucoma. *Cochrane Database of Systematic Reviews* 2016, Issue 2. Art. No.: CD005655. DOI: 10.1002/14651858.CD005655.pub2.

Copyright © 2016 The Cochrane Collaboration. Published by John Wiley & Sons, Ltd.

ABSTRACT

Background

Glaucoma is a chronic optic neuropathy characterized by retinal ganglion cell death resulting in damage to the optic nerve head and the retinal nerve fiber layer. Pigment dispersion syndrome is characterized by a structural disturbance in the iris pigment epithelium (the densely pigmented posterior surface of the iris) that leads to dispersion of the pigment and its deposition on various structures within the eye. Pigmentary glaucoma is a specific form of open-angle glaucoma found in patients with pigment dispersion syndrome.

Topcial medical therapy is usually the first-line treatment; however, peripheral laser iridotomy has been proposed as an alternate treatment. Peripheral laser iridotomy involves creating an opening in the iris tissue to allow drainage of fluid from the posterior chamber to the anterior chamber and vice versa. Equalizing the pressure within the eye may help to alleviate the friction that leads to pigment dispersion and prevent visual field deterioration. However, the effectiveness of peripheral laser iridotomy in reducing the development or progression of pigmentary glaucoma is unknown.

Objectives

The objective of this review was to assess the effects of peripheral laser iridotomy compared with other interventions, including medication, trabeculoplasty, and trabeculectomy, or no treatment, for pigment dispersion syndrome and pigmentary glaucoma.

Search methods

We searched a number of electronic databases including CENTRAL, MEDLINE and EMBASE and clinical trials websites such as (*m*RCT) and ClinicalTrials.gov. We last searched the electronic databases on 2 November 2015.

Selection criteria

We included randomized controlled trials (RCTs) that had compared peripheral laser iridotomy versus no treatment or other treatments for pigment dispersion syndrome and pigmentary glaucoma.

Data collection and analysis

We used standard methodological procedures for systematic reviews. Two review authors independently screened articles for eligibility, extracted data, and assessed included trials for risk of bias. We did not perform a meta-analysis because of variability in reporting and follow-up intervals for primary and secondary outcomes of interest.

Copyright © 2016 The Cochrane Collaboration. Published by John Wiley & Sons, Ltd.

[Intervention Review]

Photorefractive keratectomy (PRK) versus laser assisted in situ keratomileusis (LASIK) for hyperopia correction

George Settas[1], Clare Settas[2], Evangelos Minos[3], Ian YL Yeung[4]

[1]Optimax plc, London, UK. [2]Fitzwilliam Hospital, Peterborough, UK. [3]Ophthalmology Department, University Hospital of Heraklion, Crete, Greece. [4]Ophthalmology Department, Level S8, Queen Mary Hospital, Hong Kong SAR, China

Contact address: George Settas, Optimax plc, 128 Finchley Road, London, NW3 5HT, UK. settasg@doctors.org.uk.

Editorial group: Cochrane Eyes and Vision Group.
Publication status and date: New search for studies and content updated (no change to conclusions), published in Issue 6, 2012.
Review content assessed as up-to-date: 17 February 2012.

Citation: Settas G, Settas C, Minos E, Yeung IYL. Photorefractive keratectomy (PRK) versus laser assisted in situ keratomileusis (LASIK) for hyperopia correction. *Cochrane Database of Systematic Reviews* 2012, Issue 6. Art. No.: CD007112. DOI: 10.1002/14651858.CD007112.pub3.

Copyright © 2012 The Cochrane Collaboration. Published by John Wiley & Sons, Ltd.

ABSTRACT

Background

Hyperopia, or hypermetropia (also known as long-sightedness or far-sightedness), is the condition where the unaccommodating eye brings parallel light to a focus behind the retina instead of on it. Hyperopia can be corrected with both non-surgical and surgical methods, among them photorefractive keratectomy (PRK) and laser assisted In situ keratomileusis (LASIK). There is uncertainty as to whether hyperopic-PRK or hyperopic-LASIK is the better method.

Objectives

The objectives of this review were to determine whether PRK or LASIK leads to more reliable, stable and safe results when correcting a hyperopic refractive error.

Search methods

We searched CENTRAL (which contains the Cochrane Eyes and Vision Group Trials Register) (*The Cochrane Library* 2012, Issue 2), MEDLINE (January 1950 to February 2012), EMBASE (January 1980 to February 2012), Latin American and Caribbean Literature on Health Sciences (LILACS) (January 1982 to February 2012), the *meta*Register of Controlled Trials (*m*RCT) (www.controlled-trials.com), ClinicalTrials.gov (www.clinicaltrials.gov) and the WHO International Clinical Trials Registry Platform (ICTRP) (www.who.int/ictrp/search/en). There were no date or language restrictions in the electronic searches for trials. The electronic databases were last searched on 17 February 2012. When trials are included in the review we will search the reference lists of the studies included in the review for information about further trials. We will use the Science Citation Index to search for papers that cite any studies included in this review. We did not handsearch journals or conference proceedings specifically for this review.

Selection criteria

We planned to include only randomised controlled trials (RCTs) comparing PRK against LASIK for correction of hyperopia and then perform a sensitivity analysis of pre- and post-millennial trials since this is the mid-point in the history of both PRK and LASIK.

Data collection and analysis

We did not identify any studies that met the inclusion criteria for this review.

[Intervention Review]

Punctal occlusion for dry eye syndrome

Ann-Margret Ervin[1], Andrew Law[1], Andrew D Pucker[2]

[1]Department of Epidemiology, Johns Hopkins Bloomberg School of Public Health, Baltimore, Maryland, USA. [2]Optometry & Vision Science, University of Alabama at Birmingham, Birmingham, Alabama, USA

Contact address: Ann-Margret Ervin, Department of Epidemiology, Johns Hopkins Bloomberg School of Public Health, 615 N. Wolfe Street, E6146, Baltimore, Maryland, 21205, USA. aervin@jhsph.edu.

Editorial group: Cochrane Eyes and Vision Group.
Publication status and date: New search for studies and content updated (conclusions changed), published in Issue 6, 2017.

Citation: Ervin AM, Law A, Pucker AD. Punctal occlusion for dry eye syndrome. *Cochrane Database of Systematic Reviews* 2017, Issue 6. Art. No.: CD006775. DOI: 10.1002/14651858.CD006775.pub3.

Copyright © 2017 The Cochrane Collaboration. Published by John Wiley & Sons, Ltd.

ABSTRACT

Background

Dry eye syndrome is a disorder of the tear film that is associated with symptoms of ocular discomfort. Punctal occlusion is a mechanical treatment that blocks the tear drainage system in order to aid in the preservation of natural tears on the ocular surface.

Objectives

To assess the effects of punctal plugs versus no punctal plugs, different types of punctal plugs, and other interventions for managing dry eye.

Search methods

We searched the Cochrane Central Register of Controlled Trials (CENTRAL) (which contains the Cochrane Eyes and Vision Trials Register) (2016, Issue 11), MEDLINE Ovid (1946 to 8 December 2016), Embase.com (1947 to 8 December 2016), PubMed (1948 to 8 December 2016), LILACS (Latin American and Caribbean Health Sciences Literature Database) (1982 to 8 December 2016), the *meta*Register of Controlled Trials (*m*RCT) (www.controlled-trials.com; last searched 18 November 2012 - this resource is now archived), ClinicalTrials.gov (www.clinicaltrials.gov; searched 8 December 2016), and the WHO International Clinical Trials Registry Platform (ICTRP) (www.who.int/ictrp/search/en; searched 8 December 2016). We did not use any date or language restrictions in the electronic searches for trials. We also searched the Science Citation Index-Expanded database and reference lists of included studies. The evidence was last updated on 8 December 2016

Selection criteria

We included randomized and quasi-randomized controlled trials of collagen or silicone punctal plugs in symptomatic participants diagnosed with aqueous tear deficiency or dry eye syndrome.

Data collection and analysis

Two review authors independently assessed trial quality and extracted data. We contacted study investigators for additional information when needed.

Copyright © 2017 The Cochrane Collaboration. Published by John Wiley & Sons, Ltd.

[Intervention Review]

Radiotherapy for neovascular age-related macular degeneration

Jennifer R Evans[2], Vasuki Sivagnanavel[3], Victor Chong[1]

[1]Oxford Eye Hospital, Oxford, UK. [2]Cochrane Eyes and Vision Group, ICEH, London School of Hygiene & Tropical Medicine, London, UK. [3]Moorfields Eye Hospital NHS Foundation Trust, London, UK

Contact address: Victor Chong, Oxford Eye Hospital, Headley Way, Oxford, OX3 9DU, UK. victor@eretina.org.

Editorial group: Cochrane Eyes and Vision Group.
Publication status and date: New search for studies and content updated (no change to conclusions), published in Issue 5, 2010.
Review content assessed as up-to-date: 22 March 2010.

Citation: Evans JR, Sivagnanavel V, Chong V. Radiotherapy for neovascular age-related macular degeneration. *Cochrane Database of Systematic Reviews* 2010, Issue 5. Art. No.: CD004004. DOI: 10.1002/14651858.CD004004.pub3.

Copyright © 2010 The Cochrane Collaboration. Published by John Wiley & Sons, Ltd.

ABSTRACT

Background

Radiotherapy has been proposed as a treatment to prevent new vessel growth in people with neovascular age-related macular degeneration (AMD).

Objectives

The aim of this review was to examine the effects of radiotherapy on neovascular AMD.

Search methods

We searched the Cochrane Central Register of Controlled Trials (CENTRAL) (which contains the Cochrane Eyes and Vision Group Trials Register) in *The Cochrane Library* Issue 3, 2010, MEDLINE (January 1950 to March 2010), EMBASE (January 1980 to March 2010), Latin American and Caribbean Health Sciences Literature Database (LILACS) (January 1982 to March 2010), the *meta*Register of Controlled Trials (*m*RCT) (www.controlled-trials.com) (March 2010) and ClinicalTrials.gov (http://clinicaltrials.gov) (March 2010). There were no language or date restrictions in the search for trials. The electronic databases were last searched on 23 March 2010. We also wrote to investigators of trials included in the review to ask if they were aware of any other studies.

Selection criteria

We included all randomised controlled trials in which radiotherapy was compared to another treatment, sham treatment, low dosage irradiation or no treatment in people with choroidal neovascularisation secondary to AMD.

Data collection and analysis

Two review authors independently extracted the data. We combined relative risks using a random-effects model. We estimated the percentage of the variability in effect estimates that was due to heterogeneity, rather than sampling error, using I^2.

Main results

Thirteen trials (n=1154) investigated external beam radiotherapy with dosages ranging from 7.5 to 24 Gy; one additional trial (n=88) used plaque brachytherapy (15Gy at 1.75mm for 54 minutes/12.6 Gy at 4mm for 11 minutes). Most studies found effects (not always significant) that favoured treatment. Overall there was a small statistically significant reduction in risk of visual acuity loss in the treatment group. There was considerable inconsistency between trials and the trials were considered to be at risk of bias, in particular

[Intervention Review]

Reading aids for adults with low vision

Gianni Virgili[1], Ruthy Acosta[2], Sharon A Bentley[3], Giovanni Giacomelli[1], Claire Allcock[4], Jennifer R Evans[5]

[1]Department of Translational Surgery and Medicine, Eye Clinic, University of Florence, Florence, Italy. [2]Growth in Health Research, Barcelona, Spain. [3]School of Optometry and Vision Science, Queensland University of Technology, Brisbane, Australia. [4]Loughborough, UK. [5]Cochrane Eyes and Vision, ICEH, London School of Hygiene & Tropical Medicine, London, UK

Contact address: Gianni Virgili, Department of Translational Surgery and Medicine, Eye Clinic, University of Florence, Largo Brambilla, 3, Florence, 50134, Italy. gianni.virgili@unifi.it.

Editorial group: Cochrane Eyes and Vision Group.
Publication status and date: New search for studies and content updated (no change to conclusions), published in Issue 4, 2018.

Citation: Virgili G, Acosta R, Bentley SA, Giacomelli G, Allcock C, Evans JR. Reading aids for adults with low vision. *Cochrane Database of Systematic Reviews* 2018, Issue 4. Art. No.: CD003303. DOI: 10.1002/14651858.CD003303.pub4.

Copyright © 2018 The Cochrane Collaboration. Published by John Wiley & Sons, Ltd.

ABSTRACT

Background

The purpose of low-vision rehabilitation is to allow people to resume or to continue to perform daily living tasks, with reading being one of the most important. This is achieved by providing appropriate optical devices and special training in the use of residual-vision and low-vision aids, which range from simple optical magnifiers to high-magnification video magnifiers.

Objectives

To assess the effects of different visual reading aids for adults with low vision.

Search methods

We searched the Cochrane Central Register of Controlled Trials (CENTRAL) (which contains the Cochrane Eyes and Vision Trials Register) (2017, Issue 12); MEDLINE Ovid; Embase Ovid; BIREME LILACS, OpenGrey, the ISRCTN registry; ClinicalTrials.gov and the World Health Organization (WHO) International Clinical Trials Registry Platform (ICTRP). The date of the search was 17 January 2018.

Selection criteria

This review includes randomised and quasi-randomised trials that compared any device or aid used for reading to another device or aid in people aged 16 or over with low vision as defined by the study investigators. We did not compare low-vision aids with no low-vision aid since it is obviously not possible to measure reading speed, our primary outcome, in people that cannot read ordinary print. We considered reading aids that maximise the person's visual reading capacity, for example by increasing image magnification (optical and electronic magnifiers), augmenting text contrast (coloured filters) or trying to optimise the viewing angle or gaze position (such as prisms). We have not included studies investigating reading aids that allow reading through hearing, such as talking books or screen readers, or through touch, such as Braille-based devices and we did not consider rehabilitation strategies or complex low-vision interventions.

Data collection and analysis

We used standard methods expected by Cochrane. At least two authors independently assessed trial quality and extracted data. The primary outcome of the review was reading speed in words per minute. Secondary outcomes included reading duration and acuity, ease and frequency of use, quality of life and adverse outcomes. We graded the certainty of the evidence using GRADE.

Copyright © 2018 The Cochrane Collaboration. Published by John Wiley & Sons, Ltd.

[Intervention Review]

Lens extraction for chronic angle-closure glaucoma

David Friedman[1], Satyanarayana S Vedula[2]

[1]Ophthalmology Department, Wilmer Eye Institute / Johns Hopkins University, Baltimore, USA. [2]Cochrane Eyes and Vision Group US Project, Johns Hopkins Bloomberg School of Public Health, Baltimore, MD, USA

Contact address: David Friedman, Ophthalmology Department, Wilmer Eye Institute / Johns Hopkins University, 600 North Wolfe Street, Wilmer 120, Baltimore, 21287, USA. david.friedman@jhu.edu.

Editorial group: Cochrane Eyes and Vision Group.
Publication status and date: Edited (no change to conclusions), published in Issue 1, 2009.
Review content assessed as up-to-date: 7 March 2006.

Citation: Friedman D, Vedula SS. Lens extraction for chronic angle-closure glaucoma. *Cochrane Database of Systematic Reviews* 2006, Issue 3. Art. No.: CD005555. DOI: 10.1002/14651858.CD005555.pub2.

Copyright © 2009 The Cochrane Collaboration. Published by John Wiley & Sons, Ltd.

ABSTRACT

Background

Angle-closure glaucoma is characterized by obstruction to the outflow of aqueous humor and consequent rise in intraocular pressure. The obstruction may result from an anatomical predisposition of the eye or may be due to pathophysiologic processes in any part of the eye. The former is considered the primary form and the latter a secondary form of angle closure. Relative pupillary block obstructing free flow of aqueous from the posterior chamber of the eye to the anterior chamber is considered to be the most common mechanism of angle closure. Crowding of the angle is another mechanism, which often coexists with pupillary block. This can result from an anterior placement of the lens due to an increase in the thickness of the lens (as occurs with aging), anterior displacement by a posterior force (for example choroidal effusion), or laxity of the zonules.

Objectives

The objective of this review was to assess the effectiveness of lens extraction for chronic primary angle-closure glaucoma compared with other interventions for the condition in people without past history of acute-angle closure attacks.

Search methods

We searched CENTRAL (2005, Issue 3), MEDLINE (1950 to April 2006), EMBASE (1980 to April 2006), and LILACS (to August 2005). We searched the reference lists of included studies and used the Science Citation Index database.

Selection criteria

In the absence of any randomized trials we included non-randomized studies comparing lens extraction with other treatment modalities for chronic primary angle-closure glaucoma including, but not limited to, laser iridotomy, medications, and laser iridoplasty. We excluded studies with a case-series design.

Data collection and analysis

Two authors independently extracted data on methodological quality of the included studies, outcomes for the review, and study characteristics including participant characteristics, interventions, and sources of funding. Differences were resolved through discussion.

Copyright © 2009 The Cochrane Collaboration. Published by John Wiley & Sons, Ltd.

[Intervention Review]

Rituximab for thyroid-associated ophthalmopathy

Neda Minakaran[1], Daniel G Ezra[2]

[1]Department of Ophthalmology, Moorfields Eye Hospital NHS Foundation Trust, London, UK. [2]Moorfields and UCL Institute of Ophthalmology BMRC, Moorfields Eye Hospital NHS Foundation Trust, London, UK

Contact address: Neda Minakaran, Department of Ophthalmology, Moorfields Eye Hospital NHS Foundation Trust, 162 City Road, London, EC1V 2PD, UK. neda.minakaran@gmail.com, nedaminakaran@hotmail.com.

Editorial group: Cochrane Eyes and Vision Group.
Publication status and date: Edited (no change to conclusions), published in Issue 6, 2013.

Citation: Minakaran N, Ezra DG. Rituximab for thyroid-associated ophthalmopathy. *Cochrane Database of Systematic Reviews* 2013, Issue 5. Art. No.: CD009226. DOI: 10.1002/14651858.CD009226.pub2.

Copyright © 2013 The Cochrane Collaboration. Published by John Wiley & Sons, Ltd.

ABSTRACT

Background

Thyroid associated ophthalmopathy (TAO) is the most frequent extrathyroidal manifestation of Graves' disease, affecting up to 50% of patients, and has a great impact on quality of life. Rituximab is a human/murine chimeric monoclonal antibody that targets CD20, a transmembrane protein expressed on the surface of pre-B and mature B lymphocytes, but not on stem cells, pro-B lymphocytes or plasma cells. Preliminary work has shown that blocking the CD20 receptor on B-lymphocytes with rituximab affects the clinical course of TAO, by reducing inflammation and the degree of proptosis.

Objectives

The aim of this review was to investigate the effectiveness and safety of rituximab for the treatment of TAO.

Search methods

We searched CENTRAL (which contains the Cochrane Eyes and Vision Group Trials Register) (*The Cochrane Library* 2013, Issue 3), Ovid MEDLINE, Ovid MEDLINE In-Process and Other Non-Indexed Citations, Ovid MEDLINE Daily, Ovid OLDMEDLINE, (January 1950 to April 2013), EMBASE (January 1980 to April 2013), Latin American and Caribbean Literature on Health Sciences (LILACS) (January 1982 to April 2013), OpenGrey (System for Information on Grey Literature in Europe) (www.opengrey.eu/), the *meta*Register of Controlled Trials (*m*RCT) (www.controlled-trials.com), ClinicalTrials.gov (www.clinicaltrials.gov), the WHO International Clinical Trials Registry Platform (ICTRP) (www.who.int/ictrp/search/en) and the EU Clinical Trials Register (www.clinicaltrialsregister.eu). We did not use any date or language restrictions in the electronic searches for trials. We last searched the electronic databases on 15 April 2013. We manually searched references of review articles and used the Science Citation Index to identify additional studies citing trials. We contacted the lead investigators of relevant trials on ClinicalTrials.gov and the WHO ICTRP for information and data from as yet unpublished clinical trials. We contacted experts in the field for information about any ongoing trials. We contacted the manufacturers of rituximab for details of any sponsored trials.

Selection criteria

We sought to include randomised controlled trials (RCTs) of rituximab treatment by intravenous infusion for the treatment of patients with TAO, compared with placebo or intravenous glucocorticoid treatment.

Data collection and analysis

Two review authors independently scanned titles and abstracts, as well as independently screened the full reports of the potentially relevant studies. At each stage, the results were compared and disagreements were solved by discussion.

Copyright © 2013 The Cochrane Collaboration. Published by John Wiley & Sons, Ltd.

[Intervention Review]

Vision screening for correctable visual acuity deficits in school-age children and adolescents

Jennifer R Evans[1], Priya Morjaria[2], Christine Powell[3]

[1]Cochrane Eyes and Vision, ICEH, London School of Hygiene & Tropical Medicine, London, UK. [2]London School of Hygiene & Tropical Medicine, London, UK. [3]Department of Ophthalmology, Royal Victoria Infirmary, Newcastle upon Tyne, UK

Contact address: Jennifer R Evans, Cochrane Eyes and Vision, ICEH, London School of Hygiene & Tropical Medicine, Keppel Street, London, WC1E 7HT, UK. jennifer.evans@lshtm.ac.uk.

Editorial group: Cochrane Eyes and Vision Group.
Publication status and date: New search for studies and content updated (conclusions changed), published in Issue 2, 2018.

Citation: Evans JR, Morjaria P, Powell C. Vision screening for correctable visual acuity deficits in school-age children and adolescents. *Cochrane Database of Systematic Reviews* 2018, Issue 2. Art. No.: CD005023. DOI: 10.1002/14651858.CD005023.pub3.

Copyright © 2018 The Cochrane Collaboration. Published by John Wiley & Sons, Ltd.

ABSTRACT

Background

Although the benefits of vision screening seem intuitive, the value of such programmes in junior and senior schools has been questioned. In addition there exists a lack of clarity regarding the optimum age for screening and frequency at which to carry out screening.

Objectives

To evaluate the effectiveness of vision screening programmes carried out in schools to reduce the prevalence of correctable visual acuity deficits due to refractive error in school-age children.

Search methods

We searched the Cochrane Central Register of Controlled Trials (CENTRAL) (which contains the Cochrane Eyes and Vision Trials Register) (2017, Issue 4); Ovid MEDLINE; Ovid Embase; the ISRCTN registry; ClinicalTrials.gov and the ICTRP. The date of the search was 3 May 2017.

Selection criteria

We included randomised controlled trials (RCTs), including cluster-randomised trials, that compared vision screening with no vision screening, or compared interventions to improve uptake of spectacles or efficiency of vision screening.

Data collection and analysis

Two review authors independently screened search results and extracted data. Our pre-specified primary outcome was uncorrected, or suboptimally corrected, visual acuity deficit due to refractive error six months after screening. Pre-specified secondary outcomes included visual acuity deficit due to refractive error more than six months after screening, visual acuity deficit due to causes other than refractive error, spectacle wearing, quality of life, costs, and adverse effects. We graded the certainty of the evidence using GRADE.

Main results

We identified seven relevant studies. Five of these studies were conducted in China with one study in India and one in Tanzania. A total of 9858 children aged between 10 and 18 years were randomised in these studies, 8240 of whom (84%) were followed up between one and eight months after screening. Overall we judged the studies to be at low risk of bias. None of these studies compared vision screening for correctable visual acuity deficits with not screening.

Copyright © 2018 The Cochrane Collaboration. Published by John Wiley & Sons, Ltd.

[Intervention Review]

Screening for prevention of optic nerve damage due to chronic open angle glaucoma

Sarah R Hatt[2], Richard Wormald[1], Jennifer Burr[3]

[1]Cochrane Eyes and Vision Group, ICEH, London School of Hygiene & Tropical Medicine, London, UK. [2]Ophthalmology Research, Mayo Clinic, Rochester, USA. [3]Health Services Research Unit, University of Aberdeen, Aberdeen, UK

Contact address: Richard Wormald, Cochrane Eyes and Vision Group, ICEH, London School of Hygiene & Tropical Medicine, Keppel Street, London, WC1E 7HT, UK. r.wormald@ucl.ac.uk.

Editorial group: Cochrane Eyes and Vision Group.
Publication status and date: New search for studies and content updated (no change to conclusions), published in Issue 2, 2009.
Review content assessed as up-to-date: 11 January 2009.

Citation: Hatt SR, Wormald R, Burr J. Screening for prevention of optic nerve damage due to chronic open angle glaucoma. *Cochrane Database of Systematic Reviews* 2006, Issue 4. Art. No.: CD006129. DOI: 10.1002/14651858.CD006129.pub2.

Copyright © 2009 The Cochrane Collaboration. Published by John Wiley & Sons, Ltd.

ABSTRACT

Background

Open angle glaucoma (OAG) is a primary, progressive optic neuropathy; the onset is without symptoms and progression occurs silently until the advanced stages of the disease, when it affects central vision. The blindness caused by OAG is irreversible. It has often been assumed to be a condition that fulfils the criteria for population screening, although this has not been supported by other in-depth non-systematic reviews. The focus of this review was to examine the evidence for the effectiveness of screening for OAG.

Objectives

To determine the impact of screening for OAG compared with opportunistic case findings or current referral practices on the prevalence of and the degree of optic nerve damage due to OAG in screened and unscreened populations.

Search methods

We included any randomised controlled trial (RCT) evaluating population-based screening programmes for OAG with a minimum one year follow up. We searched the Cochrane Central Register of Controlled Trials (CENTRAL) (which contains the Cochrane Eyes and Vision Group Trials Register) (*The Cochrane Library*, Issue 4, 2008), MEDLINE (January 1950 to January 2009), EMBASE (January 1980 to January 2009), the UK Clinical Trials Gateway (UKCTG) and ZETOC (January 1993 to January 2009). There were no language or date restrictions in the search for trials. The electronic databases were last searched on 12 January 2009.

Selection criteria

We planned to include RCTs, including cluster RCTs.

Data collection and analysis

Two review authors independently assessed the study abstracts identified by the electronic searches. We did not find any trials that met the inclusion criteria.

Main results

As no trials were identified, no formal analysis was performed.

Copyright © 2009 The Cochrane Collaboration. Published by John Wiley & Sons, Ltd.

[Intervention Review]

Statins for age-related macular degeneration

Peter Gehlbach[1], Tianjing Li[2], Elham Hatef[3]

[1]Retina Division, Wilmer Eye Institute, Johns Hopkins University School of Medicine, Baltimore, Maryland, USA. [2]Department of Epidemiology, Johns Hopkins Bloomberg School of Public Health, Baltimore, Maryland, USA. [3]Department of Health Policy and Management, Johns Hopkins Bloomberg School of Public Health (JHBSPH), Baltimore, Maryland, USA

Contact address: Peter Gehlbach, Retina Division, Wilmer Eye Institute, Johns Hopkins University School of Medicine, 1550 Orleans Street, Cancer Research Building #2, Baltimore, Maryland, 21231, USA. pgelbach@jhmi.edu.

Editorial group: Cochrane Eyes and Vision Group.
Publication status and date: New search for studies and content updated (no change to conclusions), published in Issue 8, 2016.

Citation: Gehlbach P, Li T, Hatef E. Statins for age-related macular degeneration. *Cochrane Database of Systematic Reviews* 2016, Issue 8. Art. No.: CD006927. DOI: 10.1002/14651858.CD006927.pub5.

Copyright © 2016 The Cochrane Collaboration. Published by John Wiley & Sons, Ltd.

ABSTRACT

Background

Age-related macular degeneration (AMD) is a progressive, late-onset disorder of the macula affecting central vision. It is the leading cause of blindness in people over 65 years in industrialized countries. Recent epidemiologic, genetic, and pathological evidence has shown that AMD shares a number of risk factors with atherosclerosis, leading to the hypothesis that statins may exert protective effects in AMD.

Objectives

The objective of this review was to examine the effectiveness of statins compared with other treatments, no treatment, or placebo in delaying the onset and progression of AMD.

Search methods

We searched the Cochrane Central Register of Controlled Trials (CENTRAL) (which contains the Cochrane Eyes and Vision Trials Register) (2016, Issue 3), Ovid MEDLINE, Ovid MEDLINE In-Process and Other Non-Indexed Citations, Ovid MEDLINE Daily, Ovid OLDMEDLINE (January 1946 to March 2016), EMBASE (January 1980 to March 2016), Latin American and Caribbean Health Sciences Literature Database (LILACS) (January 1982 to March 2016), PubMed (January 1946 to March 2016), the *meta*Register of Controlled Trials (*m*RCT) (www.controlled-trials.com) (last searched 5 June 2014), ClinicalTrials.gov (www.clinicaltrials.gov), and the WHO International Clinical Trials Registry Platform (ICTRP) (www.who.int/ictrp/search/en). We did not use any date or language restrictions in the electronic searches for trials. We last searched the electronic databases on 31 March 2016.

Selection criteria

We included randomized controlled trials (RCTs) and quasi-randomized trials that compared statins with other treatments, no treatment, or placebo in people who were diagnosed as having the early stages of AMD.

Data collection and analysis

We used standard methodological procedures expected by Cochrane. Two review authors independently evaluated the search results against the selection criteria, abstracted data, and assessed risk of bias. We did not perform meta-analysis due to heterogeneity in the interventions and outcomes between the included studies.

Copyright © 2016 The Cochrane Collaboration. Published by John Wiley & Sons, Ltd.

[Intervention Review]

Intravitreal steroids versus observation for macular edema secondary to central retinal vein occlusion

Dina Gewaily[1,2], Karthikeyan Muthuswamy[3], Paul B Greenberg[4,5]

[1]Deglin and Greene Retinal Center, Wynnewood, Pennsylvania, USA. [2]Department of Ophthalmology, Scheie Eye Institute, University of Pennsylvania, Philadelphia, Pennsylvania, USA. [3]Cooper University Hospital, Camden, New Jersey, USA. [4]Section of Ophthalmology, VA Medical Center, Providence, Rhode Island, USA. [5]Division of Ophthalmology, Warren Alpert Medical School of Brown University, Providence, Rhode Island, USA

Contact address: Paul B Greenberg, Section of Ophthalmology, VA Medical Center, 830 Chalkstone Avenue, Providence, Rhode Island, 02908, USA. paul_greenberg@brown.edu.

Editorial group: Cochrane Eyes and Vision Group.
Publication status and date: New search for studies and content updated (no change to conclusions), published in Issue 9, 2015.

Citation: Gewaily D, Muthuswamy K, Greenberg PB. Intravitreal steroids versus observation for macular edema secondary to central retinal vein occlusion. *Cochrane Database of Systematic Reviews* 2015, Issue 9. Art. No.: CD007324. DOI: 10.1002/14651858.CD007324.pub3.

Copyright © 2015 The Cochrane Collaboration. Published by John Wiley & Sons, Ltd.

ABSTRACT

Background

Central retinal vein occlusion (CRVO) is a common retinal vascular abnormality associated with conditions such as hypertension, diabetes, glaucoma, and a wide variety of hematologic disorders. Macular edema (ME) represents an important vision-threatening complication of CRVO. Intravitreal steroids (IVS), such as triamcinolone acetonide, have been utilized to treat macular edema stemming from a variety of etiologies and may be a treatment option for CRVO-ME.

Objectives

To explore the effectiveness and safety of intravitreal steroids in the treatment of CRVO-ME.

Search methods

We searched CENTRAL (which contains the Cochrane Eyes and Vision Group Trials Register) (2014 Issue 10), Ovid MEDLINE, Ovid MEDLINE In-Process and Other Non-Indexed Citations, Ovid MEDLINE Daily, Ovid OLDMEDLINE (January 1946 to November 2014), EMBASE (January 1980 to November 2014), the *meta*Register of Controlled Trials (*m*RCT) (www.controlled-trials.com), ClinicalTrials.gov (www.clinicaltrials.gov) and the World Health Organization (WHO) International Clinical Trials Registry Platform (ICTRP) (www.who.int/ictrp/search/en). We did not use any date or language restrictions in the electronic searches for trials. We last searched the electronic databases on 13 November 2014. For all included primary studies, we used The Science Citation Index (3 December 2014) and manually reviewed reference lists to identify other possible relevant trials.

Selection criteria

We included randomized controlled trials (RCTs) that compared intravitreal steroids, of any dosage and duration of treatment of at least six months, with observation for the treatment of CRVO-ME.

Data collection and analysis

Two review authors independently screened titles and abstracts identified from the electronic searches and assessed full-text articles from potentially eligible trials. Two review authors independently assessed trial characteristics, risk of bias, and extracted data from included trials. We contacted investigators of included trials for desired data not provided in the trial reports.

Copyright © 2015 The Cochrane Collaboration. Published by John Wiley & Sons, Ltd.

[Intervention Review]

Adjunctive steroid therapy versus antibiotics alone for acute endophthalmitis after intraocular procedure

Carole H Kim[1], Monica F Chen[1], Anne L Coleman[1]

[1]Stein Eye Institute, UCLA, Los Angeles, California, USA

Contact address: Anne L Coleman, Stein Eye Institute, UCLA, 100 Stein Plaza, Los Angeles, California, 90095, USA. coleman@jsei.ucla.edu.

Editorial group: Cochrane Eyes and Vision Group.
Publication status and date: New, published in Issue 2, 2017.

Citation: Kim CH, Chen MF, Coleman AL. Adjunctive steroid therapy versus antibiotics alone for acute endophthalmitis after intraocular procedure. *Cochrane Database of Systematic Reviews* 2017, Issue 2. Art. No.: CD012131. DOI: 10.1002/14651858.CD012131.pub2.

Copyright © 2017 The Cochrane Collaboration. Published by John Wiley & Sons, Ltd.

ABSTRACT

Background

Endophthalmitis refers to severe infection within the eye that involves the aqueous humor or vitreous humor, or both, and threatens vision. Most cases of endophthalmitis are exogenous (i.e. due to inoculation of organisms from an outside source), and most exogenous endophthalmitis is acute and occurs after an intraocular procedure. The mainstay of treatment is emergent administration of broad-spectrum intravitreous antibiotics. Due to their anti-inflammatory effects, steroids in conjunction with antibiotics have been proposed to be beneficial in endophthalmitis management.

Objectives

To assess the effects of antibiotics combined with steroids versus antibiotics alone for the treatment of acute endophthalmitis following intraocular surgery or intravitreous injection.

Search methods

We searched the Cochrane Central Register of Controlled Trials (CENTRAL) (which contains the Cochrane Eyes and Vision Trials Register) (2016, Issue 11), MEDLINE Ovid (1946 to 8 December 2016), Embase Ovid (1980 to 8 December 2016), LILACS (Latin American and Caribbean Health Sciences Literature Database) (1982 to 8 December 2016), the ISRCTN registry (www.isrctn.com/editAdvancedSearch); searched 8 December 2016, ClinicalTrials.gov (www.clinicaltrials.gov); searched 8 December 2016, and the WHO International Clinical Trials Registry Platform (ICTRP) (www.who.int/ictrp/search/en); searched 8 December 2016. We did not use any date or language restrictions in the electronic searches for trials.

Selection criteria

We included randomized controlled trials comparing the effectiveness of adjunctive steroids with antibiotics alone in the management of acute, clinically diagnosed endophthalmitis following intraocular surgery or intravitreous injection. We excluded trials with participants with endogenous endophthalmitis unless outcomes were reported by source of infection. We imposed no restrictions on the method or order of administration, dose, frequency, or duration of antibiotics and steroids.

Data collection and analysis

Two review authors independently screened the search results, assessed risk of bias, and extracted data using methods expected by Cochrane. We contacted study authors to try to obtain missing information or information to clarify risk of bias. We conducted a meta-analysis for any outcomes that were reported by at least two studies. Outcomes reported from single studies were summarized in the text. We assessed the certainty of the evidence using GRADE.

Copyright © 2017 The Cochrane Collaboration. Published by John Wiley & Sons, Ltd.

[Intervention Review]

Surgical implantation of steroids with antiangiogenic characteristics for treating neovascular age-related macular degeneration

Arthur Geltzer[1], Angela Turalba[2], Satyanarayana S Vedula[3]

[1]Brown University, Providence, Rhode Island, USA. [2]Massachusetts Eye and Ear Infirmary, Boston, Massachusetts, USA. [3]Department of Epidemiology, Johns Hopkins Bloomberg School of Public Health, Baltimore, Maryland, USA

Contact address: Arthur Geltzer, Brown University, 389 Benefit Street, Providence, Rhode Island, 02906, USA. youngheeart@mac.com.

Editorial group: Cochrane Eyes and Vision Group.
Publication status and date: New search for studies and content updated (no change to conclusions), published in Issue 1, 2013.

Citation: Geltzer A, Turalba A, Vedula SS. Surgical implantation of steroids with antiangiogenic characteristics for treating neovascular age-related macular degeneration. *Cochrane Database of Systematic Reviews* 2013, Issue 1. Art. No.: CD005022. DOI: 10.1002/14651858.CD005022.pub3.

Copyright © 2013 The Cochrane Collaboration. Published by John Wiley & Sons, Ltd.

ABSTRACT

Background

Neovascular age-related macular degeneration (AMD) is associated with rapid vision loss due to choroidal neovascularization (CNV), leakage, and scarring. Steroids have gained attention in their role for the treatment of neovascular AMD for their antiangiogenic and anti-inflammatory properties.

Objectives

This review aims to examine effects of steroids with antiangiogenic properties in the treatment of neovascular AMD.

Search methods

We searched CENTRAL (which contains the Cochrane Eyes and Vision Group Trials Register) (*The Cochrane Library* 2012, Issue 11), Ovid MEDLINE, Ovid MEDLINE In-Process and Other Non-Indexed Citations, Ovid MEDLINE Daily, Ovid OLDMEDLINE (January 1946 to November 2012), EMBASE (January 1980 to November 2012), Latin American and Caribbean Literature on Health Sciences (LILACS) (January 1982 to November 2012), the *meta*Register of Controlled Trials (*m*RCT) (www.controlled-trials.com), ClinicalTrials.gov (www.clinicaltrials.gov) and the WHO International Clinical Trials Registry Platform (ICTRP) (www.who.int/ictrp/search/en). We did not use any date or language restrictions in the electronic searches for trials. We last searched the electronic databases on 21 November 2012.

Selection criteria

We included randomized controlled clinical trials of intra- and peri-ocular antiangiogenic steroids in people diagnosed with neovascular AMD.

Data collection and analysis

Two authors independently screened abstracts and full-text articles, assessed risk of bias in the included trials, and extracted data. We did not conduct a meta-analysis.

[Intervention Review]

Surgical interventions for bilateral congenital cataract

Vernon Long[1], Sean Chen[2], Sarah R Hatt[3]

[1]Ophthalmology Department, General Infirmary, Leeds, UK. [2]Department of Ophthalmology, The Royal Liverpool Children's NHS Trust, Liverpool, UK. [3]Ophthalmology Research, Mayo Clinic, Rochester, USA

Contact address: Vernon Long, Ophthalmology Department, General Infirmary, Belmont Grove, Leeds, LS2 9NS, UK. vernon_long@hotmail.com.

Editorial group: Cochrane Eyes and Vision Group.
Publication status and date: Edited (no change to conclusions), published in Issue 4, 2008.
Review content assessed as up-to-date: 28 February 2006.

Citation: Long V, Chen S, Hatt SR. Surgical interventions for bilateral congenital cataract. *Cochrane Database of Systematic Reviews* 2006, Issue 3. Art. No.: CD003171. DOI: 10.1002/14651858.CD003171.pub2.

Copyright © 2008 The Cochrane Collaboration. Published by John Wiley & Sons, Ltd.

ABSTRACT

Background

Congenital cataracts are opacities of the lens in one or both eyes of children that cause a reduction in vision severe enough to require surgery. Cataract is the largest treatable cause of visual loss in childhood. Paediatric cataracts provide different challenges to those in adults. Intense inflammation, amblyopia and posterior capsule opacification can affect results of treatment. Two treatments commonly considered for congenital cataract are lensectomy and lens aspiration.

Objectives

The objective of this review was to assess the effects of surgical treatments for bilateral symmetrical congenital cataracts. Success was measured according to the vision attained and occurrence of adverse events.

Search methods

We searched the Cochrane Central Register of Controlled Trials (CENTRAL) on *The Cochane Library*, which contains the Cochrane Eyes and Vision Group Trials Register (2005, Issue 2), MEDLINE (1966 to June 2005), EMBASE (1980 to June 2005, week 27), LILACS (6 July 2005), the Science Citation Index and the reference list of the included studies. We also contacted trial investigators and experts in the field for details of further studies.

Selection criteria

We included all prospective, randomised controlled trials that compared one type of cataract surgery to another, or to no surgery, in children with bilateral congenital cataracts aged 15 years or younger.

Data collection and analysis

Two authors extracted data. No meta-analysis was performed.

Main results

Four trials met the inclusion criteria. All trials were concerned with reducing the development of visual axis opacification (VAO). This was achieved with techniques that included an anterior vitrectomy or optic capture. Posterior capsulotomy alone was inadequate except in older children.

Copyright © 2008 The Cochrane Collaboration. Published by John Wiley & Sons, Ltd.

[Intervention Review]

Surgery for traumatic optic neuropathy

Patrick Yu-Wai-Man[1], Philip G Griffiths[1]

[1]Department of Ophthalmology, Royal Victoria Infirmary, Newcastle upon Tyne, UK

Contact address: Patrick Yu-Wai-Man, Department of Ophthalmology, Royal Victoria Infirmary, Newcastle upon Tyne, NE1 4LP, UK. patrick.yu-wai-man@ncl.ac.uk.

Editorial group: Cochrane Eyes and Vision Group.
Publication status and date: New search for studies and content updated (no change to conclusions), published in Issue 6, 2013.
Review content assessed as up-to-date: 28 May 2013.

Citation: Yu-Wai-Man P, Griffiths PG. Surgery for traumatic optic neuropathy. *Cochrane Database of Systematic Reviews* 2013, Issue 6. Art. No.: CD005024. DOI: 10.1002/14651858.CD005024.pub3.

Copyright © 2013 The Cochrane Collaboration. Published by John Wiley & Sons, Ltd.

ABSTRACT

Background

Traumatic optic neuropathy (TON) is an important cause of severe visual loss following blunt or penetrating head trauma. Following the initial insult optic nerve swelling within the optic nerve canal or compression by bone fragments are thought to result in secondary retinal ganglion cell loss. Optic nerve decompression with steroids or surgical interventions or both have therefore been advocated to improve visual prognosis in TON.

Objectives

To examine the effects and safety of surgical interventions in the management of TON.

Search methods

We searched CENTRAL (which contains the Cochrane Eyes and Vision Group Trials Register) (*The Cochrane Library* 2013, Issue 4), Ovid MEDLINE, Ovid MEDLINE In-Process and Other Non-Indexed Citations, Ovid MEDLINE Daily, Ovid OLDMEDLINE, (January 1950 to May 2013), EMBASE (January 1980 to May 2013), Latin American and Caribbean Literature on Health Sciences (LILACS) (January 1982 to May 2013), the *meta*Register of Controlled Trials (*m*RCT) (www.controlled-trials.com), ClinicalTrials.gov (http://clinicaltrials.gov) and the WHO International Clinical Trials Registry Platform (ICTRP) (www.who.int/ictrp/search/en). We did not use any date or language restrictions in the electronic searches for trials. We last searched the electronic databases on 28 May 2013. We also searched the reference lists of other reviews and book chapters on TON. We also contacted researchers in the field.

Selection criteria

We planned to include only randomised controlled trials (RCTs) of TON in which any form of surgical intervention either on its own or in combination with steroids was compared to steroids alone or no treatment.

Data collection and analysis

Two authors independently assessed the titles and abstracts identified from the search strategy. No studies were found that met our inclusion criteria and therefore none were included for analysis.

Main results

No studies were found that met our inclusion criteria.

Copyright © 2013 The Cochrane Collaboration. Published by John Wiley & Sons, Ltd.

[Intervention Review]

Surgery for postvitrectomy cataract

Diana V Do[1], Stephen Gichuhi[2], Satyanarayana S Vedula[3], Barbara S Hawkins[4]

[1]Byers Eye Institute, Stanford University School of Medicine, Palo Alto, California, USA. [2]Department of Ophthalmology, University of Nairobi, Nairobi, Kenya. [3]Johns Hopkins University, Baltimore, Maryland, USA. [4]Wilmer Eye Institute, Johns Hopkins University School of Medicine, Baltimore, Maryland, USA

Contact address: Diana V Do, Byers Eye Institute, Stanford University School of Medicine, 2452 Watson Court, Palo Alto, California, 94303, USA. dianado@stanford.edu.

Editorial group: Cochrane Eyes and Vision Group.
Publication status and date: New search for studies and content updated (no change to conclusions), published in Issue 1, 2018.

Citation: Do DV, Gichuhi S, Vedula SS, Hawkins BS. Surgery for postvitrectomy cataract. *Cochrane Database of Systematic Reviews* 2018, Issue 1. Art. No.: CD006366. DOI: 10.1002/14651858.CD006366.pub4.

Copyright © 2018 The Cochrane Collaboration. Published by John Wiley & Sons, Ltd.

ABSTRACT

Background

Cataract formation or acceleration can occur after intraocular surgery, especially following vitrectomy, a surgical technique for removing the vitreous that is used in the treatment of many disorders that affect the posterior segment of the eye. The underlying problem that led to vitrectomy may limit the benefit from removal of the cataractous lens.

Objectives

To evaluate the effectiveness and safety of surgery versus no surgery for postvitrectomy cataract with respect to visual acuity, quality of life, and other outcomes.

Search methods

We searched the Cochrane Central Register of Controlled Trials (CENTRAL) (which contains the Cochrane Eyes and Vision Trials Register) (2017, Issue 5), MEDLINE Ovid (1946 to 17 May 2017), Embase.com (1947 to 17 May 2017), PubMed (1946 to 17 May 2017), Latin American and Caribbean Health Sciences Literature database (LILACS) (January 1982 to 17 May 2017), the *meta*Register of Controlled Trials (*m*RCT) (www.controlled-trials.com); last searched May 2013, ClinicalTrials.gov (www.clinicaltrials.gov); searched 17 May 2017, and the World Health Organization (WHO) International Clinical Trials Registry Platform (ICTRP) (www.who.int/ictrp/search/en); searched 17 May 2017. We did not use any date or language restrictions in the electronic searches for trials.

Selection criteria

We planned to include randomized controlled trials (RCTs) and quasi-RCTs that had compared surgery versus no surgery to remove the lens from eyes of adults in which cataracts had developed following vitrectomy.

Data collection and analysis

Two review authors independently screened the search results according to the standard methodological procedures expected by Cochrane.

Main results

We found no RCTs or quasi-RCTs that had compared surgery versus no surgery to remove the lens from eyes of adults in which cataracts had developed following vitrectomy.

Copyright © 2018 The Cochrane Collaboration. Published by John Wiley & Sons, Ltd.

[Intervention Review]

Surgical interventions for primary congenital glaucoma

Deepta Ghate[1], Xue Wang[2]

[1]Department of Ophthalmology and Visual Sciences, University of Nebraska Medical Center, Omaha, Nebraska, USA. [2]Department of Epidemiology, Johns Hopkins Bloomberg School of Public Health, Baltimore, Maryland, USA

Contact address: Deepta Ghate, Department of Ophthalmology and Visual Sciences, University of Nebraska Medical Center, 985540 Nebraska Medical Center, Omaha, Nebraska, 68198-5540, USA. deeptaghate@gmail.com.

Editorial group: Cochrane Eyes and Vision Group.
Publication status and date: New, published in Issue 1, 2015.

Citation: Ghate D, Wang X. Surgical interventions for primary congenital glaucoma. *Cochrane Database of Systematic Reviews* 2015, Issue 1. Art. No.: CD008213. DOI: 10.1002/14651858.CD008213.pub2.

Copyright © 2015 The Cochrane Collaboration. Published by John Wiley & Sons, Ltd.

ABSTRACT

Background

Primary congenital glaucoma (PCG) manifests within the first few years of a child's life and is not associated with any other systemic or ocular abnormalities. PCG results in considerable morbidity even in developed countries. Several surgical techniques for treating this condition, and lowering the intraocular pressure (IOP) associated with it, have been described.

Objectives

To compare the effectiveness and safety of different surgical techniques for PCG.

Search methods

We searched CENTRAL (which contains the Cochrane Eyes and Vision Group Trials Register) (*The Cochrane Library* 2014, Issue 6), Ovid MEDLINE, Ovid MEDLINE In-Process and Other Non-Indexed Citations, Ovid MEDLINE Daily, Ovid OLDMEDLINE (January 1946 to June 2014), EMBASE (January 1980 to June 2014), (January 1982 to June 2014), PubMed (January 1946 to June 2014), the *meta*Register of Controlled Trials (*m*RCT) (www.controlled-trials.com), ClinicalTrials.gov (www.clinicaltrials.gov), the WHO International Clinical Trials Registry Platform (ICTRP) (www.who.int/ictrp/search/en). We did not use any date or language restrictions in the electronic searches for trials. We last searched the electronic databases on 23 June 2014.

Selection criteria

We included all randomized and quasi-randomized trials in which different types of surgical interventions were compared in children under five years of age with PCG.

Data collection and analysis

We used standard methodological procedures specified by The Cochrane Collaboration.

Main results

We included a total of six trials (four randomized and two quasi-randomized) with 102 eyes in 61 children. Two trials were conducted in the USA and one trial each in Egypt, Israel, Lebanon and Saudi Arabia. All trials included children aged younger than one year when diagnosed with PCG, and followed them for periods ranging from six months to five years.

No two trials compared the same pair of surgical interventions, so we did not perform any meta-analysis. One trial compared trabeculotomy versus goniotomy; a second trial compared combined trabeculectomy-trabeculotomy with mitomycin C versus trabeculectomy-trabeculotomy with mitomycin C and deep sclerectomy; a third trial compared combined trabeculotomy-trabeculectomy versus

Copyright © 2015 The Cochrane Collaboration. Published by John Wiley & Sons, Ltd.

[Intervention Review]

Pneumatic retinopexy versus scleral buckle for repairing simple rhegmatogenous retinal detachments

Elham Hatef[1], Dayse F Sena[2], Katherine A Fallano[3], Jonathan Crews[4], Diana V Do[4]

[1]Wilmer Eye Institute, Johns Hopkins University School of Medicine, Baltimore, Maryland, USA. [2]Massachusetts Eye and Ear Infirmary, Boston, Massachusetts, USA. [3]Flaum Eye Institute, University of Rochester School of Medicine, Rochester, New York, USA. [4]Stanley M. Truhlsen Eye Institute, University of Nebraska Medical Center, Omaha, Nebraska, USA

Contact address: Elham Hatef, Wilmer Eye Institute, Johns Hopkins University School of Medicine, 600 North Wolfe Street, Wilmer B-43, Baltimore, Maryland, 21287, USA. ehatef@jhsph.edu.

Editorial group: Cochrane Eyes and Vision Group.
Publication status and date: New, published in Issue 5, 2015.
Review content assessed as up-to-date: 13 January 2015.

Citation: Hatef E, Sena DF, Fallano KA, Crews J, Do DV. Pneumatic retinopexy versus scleral buckle for repairing simple rhegmatogenous retinal detachments. *Cochrane Database of Systematic Reviews* 2015, Issue 5. Art. No.: CD008350. DOI: 10.1002/14651858.CD008350.pub2.

Copyright © 2015 The Cochrane Collaboration. Published by John Wiley & Sons, Ltd.

ABSTRACT

Background

Rhegmatogenous retinal detachment (RRD) is a full-thickness break in the sensory retina, caused by vitreous traction on the retina. While pneumatic retinopexy, scleral buckle, and vitrectomy are the accepted surgical interventions for eyes with RRD, their relative effectiveness has remained controversial.

Objectives

The objectives of this review were to assess the effectiveness and safety of pneumatic retinopexy versus scleral buckle or pneumatic retinopexy versus a combination treatment of scleral buckle and vitrectomy for people with RRD. The secondary objectives were to summarize any data on economic measures and quality of life.

Search methods

We searched CENTRAL (which contains the Cochrane Eyes and Vision Group Trials Register) (2014, Issue 12), Ovid MEDLINE, Ovid MEDLINE In-Process and Other Non-Indexed Citations, Ovid MEDLINE Daily, Ovid OLDMEDLINE (January 1946 to January 2015), EMBASE (January 1980 to January 2015), Latin American and Caribbean Health Sciences Literature Database (LILACS) (January 1982 to January 2015), the ISRCTN registry (www.isrctn.com/editAdvancedSearch), ClinicalTrials.gov (www.clinicaltrials.gov) and the World Health Organization (WHO) International Clinical Trials Registry Platform (ICTRP) (www.who.int/ictrp/search/en). We did not use any date or language restrictions in the electronic searches for trials. We last searched the electronic databases on 13 January 2015.

Selection criteria

We included all randomized or quasi-randomized controlled trials comparing the effectiveness of pneumatic retinopexy versus scleral buckle (with or without vitrectomy) for eyes with RRD.

Data collection and analysis

After screening for eligibility, two review authors independently extracted study characteristics, methods, and outcomes. We followed systematic review standards as set forth by The Cochrane Collaboration.

[Intervention Review]

Surgical orbital decompression for thyroid eye disease

Kostas G Boboridis[1], Catey Bunce[2]

[1]Aristotle University of Thessaloniki, 54622 Thessaloniki, Greece. [2]Research and Development Department, Moorfields Eye Hospital NHS Foundation Trust, London, UK

Contact address: Kostas G Boboridis, Aristotle University of Thessaloniki, Pavlou Mela 16, 54622 Thessaloniki, Greece. kosbob@otenet.gr.

Editorial group: Cochrane Eyes and Vision Group.
Publication status and date: New, published in Issue 12, 2011.
Review content assessed as up-to-date: 6 October 2011.

Citation: Boboridis KG, Bunce C. Surgical orbital decompression for thyroid eye disease. *Cochrane Database of Systematic Reviews* 2011, Issue 12. Art. No.: CD007630. DOI: 10.1002/14651858.CD007630.pub2.

Copyright © 2011 The Cochrane Collaboration. Published by John Wiley & Sons, Ltd.

ABSTRACT

Background

Orbital decompression is an established procedure for the management of exophthalmos and visual rehabilitation from optic neuropathy in cases of thyroid eye disease. Numerous procedures for removal of orbital bony wall, fat or a combination of these for a variety of indications in different stages of the disease have been well reported in the medical literature. However, the relative effectiveness and safety of these procedures in relation to the various indications remains unclear.

Objectives

To review current published evidence for the effectiveness of surgical orbital decompression for disfiguring proptosis in adult thyroid eye disease and summa rise information on possible complications and the quality of life from the studies identified.

Search methods

We searched CENTRAL (which contains the Cochrane Eyes and Vision Group Trials Register) (*The Cochrane Library* 2011, Issue 10), MEDLINE (January 1950 to October 2011), EMBASE (January 1980 to October 2011), the *meta*Register of Controlled Trials (*m*RCT) (www.controlled-trials.com) and ClinicalTrials.gov (http://clinicaltrials.gov). There were no date or language restrictions in the electronic searches for trials. The electronic databases were last searched on 6 October 2011. We searched oculoplastic textbooks, conference proceedings from the European and American Society of Ophthalmic Plastic and Reconstructive Surgery (ESOPRS, ASOPRS), European Ophthalmological Society (SOE), the Association for Research in Vision and Ophthalmology (ARVO) and American Academy of Ophthalmology (AAO) for the years 2000 to 2009 to identify relevant data. We attempted to contact researchers who are active in this field for information about further published or unpublished studies.

Selection criteria

We included randomised controlled trials (RCTs) with no restriction on date or language comparing two or more surgical methods for orbital decompression with removal of bony wall, orbital fat or a combination of both for disfiguring proptosis or comparison of surgical techniques with any form of medical decompression.

Data collection and analysis

Each review author independently assessed study abstracts identified from the electronic and manual searches. Author analysis was then compared and full papers for appropriate studies were obtained according to the inclusion criteria. Disagreements between the authors were resolved by discussion.

Copyright © 2011 The Cochrane Collaboration. Published by John Wiley & Sons, Ltd.

[Intervention Review]

Surgical interventions for vertical strabismus in superior oblique palsy

Melinda Y Chang[1], Anne L Coleman[1], Victoria L Tseng[1], Joseph L Demer[2]

[1]Stein Eye Institute, UCLA, Los Angeles, California, USA. [2]Ophthalmology, Stein Eye Institute, UCLA, Los Angeles, California, USA

Contact address: Melinda Y Chang, Stein Eye Institute, UCLA, 100 Stein Plaza, Los Angeles, California, 90025, USA. melinda.y.wu@gmail.com.

Editorial group: Cochrane Eyes and Vision Group.
Publication status and date: New, published in Issue 11, 2017.

Citation: Chang MY, Coleman AL, Tseng VL, Demer JL. Surgical interventions for vertical strabismus in superior oblique palsy. *Cochrane Database of Systematic Reviews* 2017, Issue 11. Art. No.: CD012447. DOI: 10.1002/14651858.CD012447.pub2.

Copyright © 2017 The Cochrane Collaboration. Published by John Wiley & Sons, Ltd.

ABSTRACT

Background

Superior oblique palsy is a common cause of vertical strabismus in adults and children. Patients may be symptomatic from binocular vertical diplopia or compensatory head tilt required to maintain single vision. Most patients who are symptomatic elect to undergo strabismus surgery, but the optimal surgical treatment for vertical strabismus in people with superior oblique palsy is unknown.

Objectives

To assess the relative effects of surgical treatments compared with another surgical intervention, non-surgical intervention, or observation for vertical strabismus in people with superior oblique palsy.

Search methods

We searched the Cochrane Central Register of Controlled Trials (CENTRAL) (which contains the Cochrane Eyes and Vision Trials Register) (2016, Issue 12), MEDLINE Ovid (1946 to 13 December 2016), Embase Ovid (1947 to 13 December 2016), Latin American and Caribbean Health Sciences Literature Database (LILACS) (1982 to 13 December 2016), the ISRCTN registry (www.isrctn.com/editAdvancedSearch); searched 13 December 2016, ClinicalTrials.gov (www.clinicaltrials.gov); searched 13 December 2016, and the World Health Organization (WHO) International Clinical Trials Registry Platform (ICTRP) (www.who.int/ictrp/search/en); searched 13 December 2016. We did not use any date or language restrictions in the electronic searches for trials.

Selection criteria

We included randomized trials that compared at least one type of surgical intervention to another surgical or non-surgical intervention or observation.

Data collection and analysis

Two review authors independently completed eligibility screening, data abstraction, 'Risk of bias' assessment, and grading of the evidence.

Main results

We identified two randomized trials comparing four different surgical treatments for this condition, two methods in each trial. The studies included a total of 45 children and adults. The surgical treatments were all procedures to weaken the ipsilateral inferior oblique

[Intervention Review]

Systemic treatment for blepharokeratoconjunctivitis in children

Michael O'Gallagher[1], Marina Banteka[2], Catey Bunce[3], Frank Larkin[4], Stephen Tuft[4], Annegret Dahlmann-Noor[2]

[1]Moorfields Eye Hospital NHS Foundation Trust, London, UK. [2]NIHR Biomedical Research Centre at Moorfields Eye Hospital NHS Foundation Trust and UCL Institute of Ophthalmology, London, UK. [3]Research and Development Department, NIHR Biomedical Research Centre at Moorfields Eye Hospital NHS Foundation Trust and UCL Institute of Ophthalmology, London, UK. [4]Cornea and External Disease Department, Moorfields Eye Hospital NHS Foundation Trust, London, UK

Contact address: Annegret Dahlmann-Noor, NIHR Biomedical Research Centre at Moorfields Eye Hospital NHS Foundation Trust and UCL Institute of Ophthalmology, 162 City Road, London, EC1V 2PD, UK. annegret.dahlmann-noor@moorfields.nhs.uk.

Editorial group: Cochrane Eyes and Vision Group.
Publication status and date: New, published in Issue 5, 2016.

Citation: O'Gallagher M, Banteka M, Bunce C, Larkin F, Tuft S, Dahlmann-Noor A. Systemic treatment for blepharokeratoconjunctivitis in children. *Cochrane Database of Systematic Reviews* 2016, Issue 5. Art. No.: CD011750. DOI: 10.1002/14651858.CD011750.pub2.

Copyright © 2016 The Cochrane Collaboration. Published by John Wiley & Sons, Ltd.

ABSTRACT

Background

Blepharokeratoconjunctivitis (BKC) is a type of inflammation of the surface of the eye and eyelids which can affect children and adults. BKC involves changes of the eyelids, dysfunction of the meibomian glands, and inflammation of the conjunctiva and cornea. Chronic inflammation of the cornea can lead to scarring, vascularisation and opacity. BKC in children can cause significant symptoms which include irritation, watering, photophobia and loss of vision. Loss of vision in children with BKC may be due to corneal opacity, refractive error or amblyopia.

BKC treatment is directed towards the obstruction of meibomian gland openings, the bacterial flora of lid margin and conjunctiva, and ocular surface inflammation. Dietary modifications that involve increased intake in essential fatty acids (EFAs) may also be beneficial. Both topical and systemic treatments are used; this Cochrane review focuses on systemic treatments.

Objectives

To assess and compare data on the efficacy and safety of systemic treatments (including antibiotics, nutritional supplements and immunosuppressants), alone or in combination, for BKC in children aged between zero to 16 years.

Search methods

We searched CENTRAL (which contains the Cochrane Eyes and Vision Trials Register) (2016, Issue 3), Ovid MEDLINE, Ovid MEDLINE In-Process and Other Non-Indexed Citations, Ovid MEDLINE Daily, Ovid OLDMEDLINE (January 1946 to April 2016), EMBASE (January 1980 to April 2016), the ISRCTN registry (www.isrctn.com/editAdvancedSearch), ClinicalTrials.gov (www.clinicaltrials.gov) and the World Health Organization (WHO) International Clinical Trials Registry Platform (ICTRP) (www.who.int/ictrp/search/en). We did not use any date or language restrictions in the electronic searches for trials. We last searched the electronic databases on 21 April 2016.

Selection criteria

We searched for randomised controlled trials that involved systemic treatments in children aged between zero to 16 years with a clinical diagnosis of BKC. We planned to include studies that evaluated a single systemic medication versus placebo, and studies that compared two or multiple active treatments. We planned to include studies in which participants receive additional treatments, such as topical antibiotics, anti-inflammatories and lubricants, warm lid compresses and lid margin cleaning.

Copyright © 2016 The Cochrane Collaboration. Published by John Wiley & Sons, Ltd.

[Intervention Review]

Telerehabilitation for people with low vision

Ava K Bittner[1], Stephanie L Wykstra[2], Patrick D Yoshinaga[3], Tianjing Li[4]

[1]Nova Southeastern University, College of Optometry, Ft Lauderdale, Florida, USA. [2]Innovations for Poverty Action, New Haven, Connecticut, USA. [3]Southern California College of Optometry, Marshall B Ketchum University, Fullerton, California, USA. [4]Department of Epidemiology, Johns Hopkins Bloomberg School of Public Health, Baltimore, Maryland, USA

Contact address: Ava K Bittner, Nova Southeastern University, College of Optometry, 3200 University Drive, Ft Lauderdale, Florida, 33328, USA. abittner@nova.edu.

Editorial group: Cochrane Eyes and Vision Group.
Publication status and date: New, published in Issue 8, 2015.

Citation: Bittner AK, Wykstra SL, Yoshinaga PD, Li T. Telerehabilitation for people with low vision. *Cochrane Database of Systematic Reviews* 2015, Issue 8. Art. No.: CD011019. DOI: 10.1002/14651858.CD011019.pub2.

Copyright © 2015 The Cochrane Collaboration. Published by John Wiley & Sons, Ltd.

ABSTRACT

Background

Low vision affects over 300 million people worldwide and can compromise both activities of daily living and quality of life. Rehabilitative training and vision assistive equipment (VAE) may help, but some visually impaired people have limited resources to attend in-person visits at rehabilitation clinics. These people may be able to overcome barriers to care through remote, Internet-based consultation (i.e., telerehabilitation).

Objectives

To compare the effects of telerehabilitation with face-to-face (e.g., in-office or inpatient) vision rehabilitation services for improving vision-related quality of life and reading speed in people with visual function loss due to any ocular condition. Secondary objectives are to evaluate compliance with scheduled rehabilitation sessions, abandonment rates for visual assistive equipment devices, and patient satisfaction ratings.

Search methods

We searched CENTRAL (which contains the Cochrane Eyes and Vision Group Trials Register) (2015 Issue 5), Ovid MEDLINE, Ovid MEDLINE In-Process and Other Non-Indexed Citations, Ovid MEDLINE Daily, Ovid OLDMEDLINE (January 1980 to June 2015), EMBASE (January 1980 to June 2015), PubMed (1980 to June 2015), ClinicalTrials.gov (www.clinicaltrials.gov) and the World Health Organization (WHO) International Clinical Trials Registry Platform (ICTRP) (www.who.int/ictrp/search/en). We did not use any language restriction or study design filter in the electronic searches; however, we restricted the searches from 1980 onwards because the Internet was not introduced to the public until 1982. We last searched the electronic databases on 15 June 2015.

Selection criteria

We planned to include randomized controlled trials (RCTs) or controlled clinical trials (CCTs) in which participants were diagnosed with low vision and were undergoing low vision rehabilitation using an Internet, web-based technology compared with an approach based on in-person consultations.

Data collection and analysis

Two authors independently screened titles and abstracts, and then full-text articles against the eligibility criteria. We planned to have two authors independently abstract data from included studies. We resolved discrepancies by discussion.

Copyright © 2015 The Cochrane Collaboration. Published by John Wiley & Sons, Ltd.

[Diagnostic Test Accuracy Review]

Tests for detecting strabismus in children aged 1 to 6 years in the community

Sarah Hull[1], Vijay Tailor[1], Sara Balduzzi[2], Jugnoo Rahi[3], Christine Schmucker[4], Gianni Virgili[5], Annegret Dahlmann-Noor[1]

[1]NIHR Biomedical Research Centre at Moorfields Eye Hospital NHS Foundation Trust and UCL Institute of Ophthalmology, London, UK. [2]Cochrane Italy, Department of Diagnostic, Clinical and Public Health Medicine, University of Modena and Reggio Emilia, Modena, Italy. [3]Department of Epidemiology, UCL Institute of Child Health and UCL Institute of Ophthalmology, London, UK. [4]Cochrane Germany, Medical Center - Univ. of Freiburg, Faculty of Medicine, Univ. of Freiburg, Freiburg, Germany. [5]Department of Translational Surgery and Medicine, Eye Clinic, University of Florence, Florence, Italy

Contact address: Annegret Dahlmann-Noor, NIHR Biomedical Research Centre at Moorfields Eye Hospital NHS Foundation Trust and UCL Institute of Ophthalmology, 162 City Road, London, EC1V 2PD, UK. annegret.dahlmann-noor@moorfields.nhs.uk.

Editorial group: Cochrane Eyes and Vision Group.
Publication status and date: New, published in Issue 11, 2017.

Citation: Hull S, Tailor V, Balduzzi S, Rahi J, Schmucker C, Virgili G, Dahlmann-Noor A. Tests for detecting strabismus in children aged 1 to 6 years in the community. *Cochrane Database of Systematic Reviews* 2017, Issue 11. Art. No.: CD011221. DOI: 10.1002/14651858.CD011221.pub2.

Copyright © 2017 The Cochrane Collaboration. Published by John Wiley & Sons, Ltd.

ABSTRACT

Background

Strabismus (misalignment of the eyes) is a risk factor for impaired visual development both of visual acuity and of stereopsis. Detection of strabismus in the community by non-expert examiners may be performed using a number of different index tests that include direct measures of misalignment (corneal or fundus reflex tests), or indirect measures such as stereopsis and visual acuity. The reference test to detect strabismus by trained professionals is the cover‑ uncover test.

Objectives

To assess and compare the accuracy of tests, alone or in combination, for detection of strabismus in children aged 1 to 6 years, in a community setting by non-expert screeners or primary care professionals to inform healthcare commissioners setting up childhood screening programmes.

Secondary objectives were to investigate sources of heterogeneity of diagnostic accuracy.

Search methods

We searched the Cochrane Central Register of Controlled Trials (CENTRAL; 2016, Issue 12) (which contains the Cochrane Eyes and Vision Trials Register) in the Cochrane Library, the Health Technology Assessment Database (HTAD) in the Cochrane Library (2016, Issue 4), MEDLINE Ovid (1946 to 5 January 2017), Embase Ovid (1947 to 5 January 2017), CINAHL (January 1937 to 5 January 2017), Web of Science Conference Proceedings Citation Index-Science (CPCI-S) (January 1990 to 5 January 2017), BIOSIS Previews (January 1969 to 5 January 2017), MEDION (to 18 August 2014), the Aggressive Research Intelligence Facility database (ARIF) (to 5 January 2017), the ISRCTN registry (www.isrctn.com/editAdvancedSearch); searched 5 January 2017, ClinicalTrials.gov (www.clinicaltrials.gov); searched 5 January 2017 and the World Health Organization (WHO) International Clinical Trials Registry Platform (ICTRP) (www.who.int/ictrp/search/en); searched 5 January 2017. We did not use any date or language restrictions in the electronic searches for trials. In addition, orthoptic journals and conference proceedings without electronic listings were searched.

Copyright © 2017 The Cochrane Collaboration. Published by John Wiley & Sons, Ltd.

[Intervention Review]

Topical medication instillation techniques for glaucoma

Li Xu[1], Xuemei Wang[2], Meijing Wu[3]

[1]Hainan Provincial Key Laboratory of Ophthalmology, Hainan Eye Hospital, Zhongshan Ophthalmic Center, Haikou, China. [2]Health Policy and Management, Johns Hopkins Bloomberg School of Public Health, Baltimore, Maryland, USA. [3]Department of Neurological Surgery, Feinberg School of Medicine, Northwestern University, Chicago, Illinois, USA

Contact address: Li Xu, Hainan Provincial Key Laboratory of Ophthalmology, Hainan Eye Hospital, Zhongshan Ophthalmic Center, Haikou, Hainan Province, China. xuli-113@163.com.

Editorial group: Cochrane Eyes and Vision Group.
Publication status and date: New, published in Issue 2, 2017.

Citation: Xu L, Wang X, Wu M. Topical medication instillation techniques for glaucoma. *Cochrane Database of Systematic Reviews* 2017, Issue 2. Art. No.: CD010520. DOI: 10.1002/14651858.CD010520.pub2.

Copyright © 2017 The Cochrane Collaboration. Published by John Wiley & Sons, Ltd.

ABSTRACT

Background

Glaucoma is a leading cause of irreversible blindness worldwide and the second most common cause of blindness after cataracts. The primary treatment for glaucoma aims to lower intraocular pressure (IOP) with the use of topical medicines. Topical medication instillation techniques, such as eyelid closure and nasolacrimal occlusion when instilling drops, have been proposed as potential methods to increase ocular absorption and decrease systemic absorption of the drops.

Objectives

To investigate the effectiveness of topical medication instillation techniques compared with usual care or another method of instillation of topical medication in the management of glaucoma or ocular hypertension.

Search methods

We searched the Cochrane Central Register of Controlled Trials (CENTRAL) (which contains the Cochrane Eyes and Vision Trials Register) (2016, Issue 12), MEDLINE Ovid (1946 to 8 December 2016), Embase Ovid (1947 to 8 December 2016), PubMed (1948 to 8 December 2016), LILACS (Latin American and Caribbean Health Sciences Literature Database) (1982 to 8 December 2016), International Pharmaceutical Abstracts Database (1970 to 8 December 2016), the *meta*Register of Controlled Trials (*m*RCT) (www.controlled-trials.com) (last searched 13 May 2013), ClinicalTrials.gov (www.clinicaltrials.gov) (searched 8 December 2016) and the WHO International Clinical Trials Registry Platform (ICTRP) (www.who.int/ictrp/search/en) (searched 8 December 2016). We did not use any date or language restrictions in the electronic searches for trials.

Selection criteria

We included randomized controlled trials which had compared any topical medication instillation technique with usual care or a different method of instillation of topical medication.

Data collection and analysis

Two review authors independently screened records from the searches for eligibility, assessed the risk of bias, and extracted data. We followed methods recommended by Cochrane.

Copyright © 2017 The Cochrane Collaboration. Published by John Wiley & Sons, Ltd.

[Intervention Review]

Topical non-steroidal anti-inflammatory agents for diabetic cystoid macular oedema

Soumendra Sahoo[1], Ankur Barua[2], Kay Thi Myint[3], Adnaan Haq[4], Adinegara BL Abas[5], N S Nair[6]

[1]Ophthalmology, Melaka Manipal Medical College, Melaka, Malaysia. [2]Department of Community Medicine, International Medical University (IMU), Kuala Lumpur, Malaysia. [3]Ophthalmology, Faculty of Medicine, SEGi University, Sibu, Malaysia. [4]Medical School, St. George's University of London, London, UK. [5]Department of Community Medicine, Melaka-Manipal Medical College, Melaka, Malaysia. [6]Department of Statistics, Manipal University, Manipal, India

Contact address: Soumendra Sahoo, Ophthalmology, Melaka Manipal Medical College, Bukit Baru, Melaka, 75150, Malaysia. soumendra.sahoo@manipal.edu.my.

Editorial group: Cochrane Eyes and Vision Group.
Publication status and date: New, published in Issue 2, 2015.
Review content assessed as up-to-date: 12 January 2015.

Citation: Sahoo S, Barua A, Myint KT, Haq A, Abas ABL, Nair NS. Topical non-steroidal anti-inflammatory agents for diabetic cystoid macular oedema. *Cochrane Database of Systematic Reviews* 2015, Issue 2. Art. No.: CD010009. DOI: 10.1002/14651858.CD010009.pub2.

Copyright © 2015 The Cochrane Collaboration. Published by John Wiley & Sons, Ltd.

ABSTRACT

Background

Diabetic cystoid macular oedema (CMO) is a condition which involves fluid accumulation in the inner portion of the retina. It often follows changes in retinal blood vessels which enhance the fluid to come out of vessels. Although it may be asymptomatic, symptoms are primarily painless loss of central vision, often with the complaint of seeing black spots in front of the eye.

It is reported that CMO may resolve spontaneously, or fluctuate for months, before causing loss of vision. If left untreated or undiagnosed, progression of CMO may lead to permanent visual loss.

It has been noted that patients with diabetic retinopathy have elevated inflammatory markers, and therefore it is likely that inflammation aids in the progression of vascular disease in these patients. Several topical non-steroidal anti-inflammatory drugs (NSAIDs) such as ketorolac 0.5%, bromfenac 0.09%, and nepafenac 0.1%, have therefore also been used topically to treat chronic diabetic CMO. Hence this review was conducted to find out the effects of topical NSAIDs in diabetic CMO.

Objectives

To assess the effects of topical non-steroidal anti-inflammatory drugs (NSAIDs) for diabetic cystoid macular oedema (CMO).

Search methods

We searched CENTRAL (which contains the Cochrane Eyes and Vision Group Trials Register) (2014, Issue 12), Ovid MEDLINE, Ovid MEDLINE In-Process and Other Non-Indexed Citations, Ovid MEDLINE Daily, Ovid OLDMEDLINE (January 1946 to January 2015), EMBASE (January 1980 to January 2015), Latin American and Caribbean Health Sciences Literature Database (LILACS) (January 1982 to January 2015), the ISRCTN registry (www.isrctn.com/editAdvancedSearch), ClinicalTrials.gov (www.clinicaltrials.gov) and the WHO International Clinical Trials Registry Platform (ICTRP) (www.who.int/ictrp/search/en). We did not use any date or language restrictions in the electronic searches for trials. We last searched the electronic databases on 12 January 2015.

Copyright © 2015 The Cochrane Collaboration. Published by John Wiley & Sons, Ltd.

[Intervention Review]

Topical treatments for blepharokeratoconjunctivitis in children

Michael O'Gallagher[1], Catey Bunce[2], Melanie Hingorani[1], Frank Larkin[3], Stephen Tuft[3], Annegret Dahlmann-Noor[4]

[1]Moorfields Eye Hospital NHS Foundation Trust, London, UK. [2]Department of Primary Care & Public Health Sciences, Kings College London, London, UK. [3]Cornea and External Disease Department, Moorfields Eye Hospital NHS Foundation Trust, London, UK. [4]NIHR Biomedical Research Centre at Moorfields Eye Hospital NHS Foundation Trust and UCL Institute of Ophthalmology, London, UK

Contact address: Annegret Dahlmann-Noor, NIHR Biomedical Research Centre at Moorfields Eye Hospital NHS Foundation Trust and UCL Institute of Ophthalmology, 162 City Road, London, EC1V 2PD, UK. annegret.dahlmann-noor@moorfields.nhs.uk.

Editorial group: Cochrane Eyes and Vision Group.
Publication status and date: New, published in Issue 2, 2017.

Citation: O'Gallagher M, Bunce C, Hingorani M, Larkin F, Tuft S, Dahlmann-Noor A. Topical treatments for blepharokeratoconjunctivitis in children. *Cochrane Database of Systematic Reviews* 2017, Issue 2. Art. No.: CD011965. DOI: 10.1002/14651858.CD011965.pub2.

Copyright © 2017 The Cochrane Collaboration. Published by John Wiley & Sons, Ltd.

ABSTRACT

Background

Blepharokeratoconjunctivitis (BKC) is a type of inflammation of the surface of the eye and eyelids that involves changes of the eyelids, dysfunction of the meibomian glands, and inflammation of the conjunctiva and cornea. Chronic inflammation of the cornea can lead to scarring, vascularisation and opacity. BKC in children can cause significant symptoms including irritation, watering, photophobia and loss of vision from corneal opacity, refractive error or amblyopia.

Treatment of BKC is directed towards modification of meibomian gland disease and the bacterial flora of lid margin and conjunctiva, and control of ocular surface inflammation. Although both topical and systemic treatments are used to treat people with BKC, this Cochrane review focuses on topical treatments.

Objectives

To assess and compare data on the efficacy and safety of topical treatments (including antibiotics, steroids, immunosuppressants and lubricants), alone or in combination, for BKC in children from birth to 16 years.

Search methods

We searched CENTRAL (which contains the Cochrane Eyes and Vision Trials Register) (2016, Issue 6), Ovid MEDLINE, Ovid MEDLINE In-Process and Other Non-Indexed Citations, Ovid MEDLINE Daily, Ovid OLDMEDLINE (January 1946 to 11 July 2016), Embase (January 1980 to 11 July 2016), the ISRCTN registry (www.isrctn.com/editAdvancedSearch), ClinicalTrials.gov (www.clinicaltrials.gov) and the World Health Organization (WHO) International Clinical Trials Registry Platform (ICTRP) (www.who.int/ictrp/search/en). We did not use any date or language restrictions in the electronic searches for trials. We last searched the electronic databases on 11 July 2016. We searched the reference lists of identified reports and the Science Citation Index to identify any additional reports of studies that met the inclusion criteria.

Copyright © 2017 The Cochrane Collaboration. Published by John Wiley & Sons, Ltd.

[Intervention Review]

Interventions for intermittent exotropia

Sarah R Hatt[1], Lawrence Gnanaraj[2]

[1]Ophthalmology Research, Mayo Clinic, Rochester, Minnesota, USA. [2]Sunderland Eye Infirmary, Sunderland, UK

Contact address: Sarah R Hatt, Ophthalmology Research, Mayo Clinic, Guggenheim 9, 200 1st St. SW, Rochester, Minnesota, 55905, USA. mickow.sarah@mayo.edu.

Editorial group: Cochrane Eyes and Vision Group.
Publication status and date: New search for studies and content updated (no change to conclusions), published in Issue 5, 2013.
Review content assessed as up-to-date: 17 May 2012.

Citation: Hatt SR, Gnanaraj L. Interventions for intermittent exotropia. *Cochrane Database of Systematic Reviews* 2013, Issue 5. Art. No.: CD003737. DOI: 10.1002/14651858.CD003737.pub3.

Copyright © 2013 The Cochrane Collaboration. Published by John Wiley & Sons, Ltd.

ABSTRACT

Background

The clinical management of intermittent exotropia has been discussed extensively in the literature, yet there remains a lack of clarity regarding indications for intervention, the most effective form of treatment and whether or not there is an optimal time in the evolution of the disease at which any treatment should be carried out.

Objectives

The objective of this review was to analyse the effects of various surgical and non-surgical treatments in randomised trials of participants with intermittent exotropia, and to report intervention criteria and determine the significance of factors such as age with respect to outcome.

Search methods

We searched the Cochrane Central Register of Controlled Trials (CENTRAL) (which contains the Cochrane Eyes and Vision Group Trials Register) (*The Cochrane Library*, Issue 4, 2012), MEDLINE (January 1966 to May 2012), EMBASE (January 1980 to May 2012), Latin American and Caribbean Literature on Health Sciences (LILACS) (January 1982 to May 2012), the *meta*Register of Controlled Trials (*m*RCT) (www.controlled-trials.com), ClinicalTrials.gov (www.clinicaltrials.gov) and the WHO International Clinical Trials Registry Platform (ICTRP) (www.who.int/ictrp/search/en). We did not use any date or language restrictions in the electronic searches for trials. We last searched the electronic databases on 4 May 2012. We are no longer searching the UK Clinical Trials Gateway (UKCTG) for this review. We manually searched the British Orthoptic Journal up to 2002, and the proceedings of the European Strabismological Association (ESA), International Strabismological Association (ISA) and American Academy of Paediatric Ophthalmology and Strabismus meeting (AAPOS) up to 2001. We contacted researchers who are active in the field for information about further published or unpublished studies.

Selection criteria

We included randomised controlled trials of any surgical or non-surgical treatment for intermittent exotropia.

Data collection and analysis

Each review author independently assessed study abstracts identified from the electronic and manual searches. Author analysis was then compared and full papers for appropriate studies were obtained.

Copyright © 2013 The Cochrane Collaboration. Published by John Wiley & Sons, Ltd.

[Intervention Review]

Occlusion for stimulus deprivation amblyopia

Aileen Antonio-Santos[1], Satyanarayana S Vedula[2], Sarah R Hatt[3], Christine Powell[4]

[1]Grand Rapids Medical Education Partners, Grand Rapids, Michigan, USA. [2]Johns Hopkins University, Baltimore, Maryland, USA. [3]Department of Ophthalmology, Mayo Clinic, Rochester, Minnesota, USA. [4]Department of Ophthalmology, Royal Victoria Infirmary, Newcastle upon Tyne, UK

Contact address: Aileen Antonio-Santos, Grand Rapids Medical Education Partners, 25 Michigan Street NE, Grand Rapids, Michigan, 49301, USA. aileen.antonio@ht.msu.edu.

Editorial group: Cochrane Eyes and Vision Group.
Publication status and date: New search for studies and content updated (no change to conclusions), published in Issue 2, 2014.
Review content assessed as up-to-date: 28 October 2013.

Citation: Antonio-Santos A, Vedula SS, Hatt SR, Powell C. Occlusion for stimulus deprivation amblyopia. *Cochrane Database of Systematic Reviews* 2014, Issue 2. Art. No.: CD005136. DOI: 10.1002/14651858.CD005136.pub3.

Copyright © 2014 The Cochrane Collaboration. Published by John Wiley & Sons, Ltd.

ABSTRACT

Background

Stimulus deprivation amblyopia (SDA) develops due to an obstruction to the passage of light secondary to a condition such as cataract. The obstruction prevents formation of a clear image on the retina. SDA can be resistant to treatment, leading to poor visual prognosis. SDA probably constitutes less than 3% of all amblyopia cases, although precise estimates of prevalence are unknown. In developed countries, most patients present under the age of one year; in less developed parts of the world patients are likely to be older at the time of presentation. The mainstay of treatment is removal of the cataract and then occlusion of the better-seeing eye, but regimens vary, can be difficult to execute, and traditionally are believed to lead to disappointing results.

Objectives

Our objective was to evaluate the effectiveness of occlusion therapy for SDA in an attempt to establish realistic treatment outcomes. Where data were available, we also planned to examine evidence of any dose response effect and to assess the effect of the duration, severity, and causative factor on the size and direction of the treatment effect.

Search methods

We searched CENTRAL (which contains the Cochrane Eyes and Vision Group Trials Register) (The Cochrane Library 2013, Issue 9), Ovid MEDLINE, Ovid MEDLINE In-Process and Other Non-Indexed Citations, Ovid MEDLINE Daily, Ovid OLDMEDLINE (January 1946 to October 2013), EMBASE (January 1980 to October 2013), the Latin American and Caribbean Literature on Health Sciences (LILACS) (January 1982 to October 2013), PubMed (January 1946 to October 2013), the metaRegister of Controlled Trials (mRCT) (www.controlled-trials.com), ClinicalTrials.gov (www.clinicaltrials.gov) and the WHO International Clinical Trials Registry Platform (ICTRP) (www.who.int/ictrp/search/en). We did not use any date or language restrictions in the electronic searches for trials. We last searched the electronic databases on 28 October 2013.

Selection criteria

We planned to include randomized and quasi-randomized controlled trials of participants with unilateral SDA with visual acuity worse than 0.2 LogMAR or equivalent. We did not specify any restrictions for inclusion based upon age, gender, ethnicity, co-morbidities, medication use, or the number of participants.

Copyright © 2014 The Cochrane Collaboration. Published by John Wiley & Sons, Ltd.

[Intervention Review]

Interventions for dissociated vertical deviation

Sarah R Hatt[1], Xue Wang[2], Jonathan M Holmes[1]

[1]Department of Ophthalmology, Mayo Clinic, Rochester, Minnesota, USA. [2]Department of Epidemiology, Johns Hopkins Bloomberg School of Public Health, Baltimore, Maryland, USA

Contact address: Sarah R Hatt, Department of Ophthalmology, Mayo Clinic, Guggenheim 9, 200 1st St. SW, Rochester, Minnesota, 55905, USA. mickow.sarah@mayo.edu.

Editorial group: Cochrane Eyes and Vision Group.
Publication status and date: Edited (no change to conclusions), published in Issue 1, 2016.

Citation: Hatt SR, Wang X, Holmes JM. Interventions for dissociated vertical deviation. *Cochrane Database of Systematic Reviews* 2015, Issue 11. Art. No.: CD010868. DOI: 10.1002/14651858.CD010868.pub2.

Copyright © 2016 The Cochrane Collaboration. Published by John Wiley & Sons, Ltd.

ABSTRACT

Background

The term "strabismus" describes misalignment of the eyes. One or both eyes may deviate inward, outward, upward, or downward. Dissociated vertical deviation (DVD) is a well-recognized type of upward drifting of one or both eyes, which can occur in children or adults. DVD often develops in the context of infantile- or childhood-onset horizontal strabismus, either esotropia (inward-turning) or exotropia (outward-turning). For some individuals, DVD remains controlled and can only be detected during clinical testing. For others, DVD becomes spontaneously "manifest" and the eye drifts up of its own accord. Spontaneously manifest DVD can be difficult to control and often causes psychosocial concerns. Traditionally, DVD has been thought to be asymptomatic, although some individuals have double vision. More recently it has been suggested that individuals with DVD may also suffer from eyestrain. Treatment for DVD may be sought either due to psychosocial concerns or because of these symptoms. The standard treatment for DVD is a surgical procedure; non-surgical treatments are offered less commonly. Although there are many studies evaluating different management options for the correction of DVD, a lack of clarity remains regarding which treatments are most effective.

Objectives

The objective of this review was to determine the effectiveness and safety of various surgical and non-surgical interventions in randomized controlled trials of participants with DVD.

Search methods

We searched CENTRAL (which contains the Cochrane Eyes and Vision Trials Register) (2015, Issue 8), Ovid MEDLINE, Ovid MEDLINE In-Process and Other Non-Indexed Citations, Ovid MEDLINE Daily, Ovid OLDMEDLINE (January 1946 to August 2015), EMBASE (January 1980 to August 2015), PubMed (1948 to August 2015), Latin American and Caribbean Health Sciences Literature Database (LILACS) (1982 to August 2015), the *meta*Register of Controlled Trials (*m*RCT) (www.controlled-trials.com) (last searched 3 February 2014), ClinicalTrials.gov (www.clinicaltrials.gov), and the WHO International Clinical Trials Registry Platform (ICTRP) (www.who.int/ictrp/search/en). We did not use any date or language restrictions in the electronic searches for trials. We last searched the electronic databases on 3 August 2015.

Selection criteria

We included randomized controlled trials (RCTs) of surgical and non-surgical interventions for the correction of DVD.

Data collection and analysis

We used standard procedures expected by Cochrane. Two review authors independently completed eligibility screening, data abstraction, 'Risk of bias' assessment, and grading of the evidence.

Copyright © 2016 The Cochrane Collaboration. Published by John Wiley & Sons, Ltd.

[Intervention Review]

Interventions for acute non-arteritic central retinal artery occlusion

Scott G Fraser[1], Wendy Adams[1]

[1]Sunderland Eye Infirmary, Sunderland, UK

Contact address: Scott G Fraser, Sunderland Eye Infirmary, Queen Alexandra Road, Sunderland, SR2 9HB, UK. s.g.fraser@ncl.ac.uk.

Editorial group: Cochrane Eyes and Vision Group.
Publication status and date: New search for studies and content updated (no change to conclusions), published in Issue 1, 2009.

Citation: Fraser SG, Adams W. Interventions for acute non-arteritic central retinal artery occlusion. *Cochrane Database of Systematic Reviews* 2009, Issue 1. Art. No.: CD001989. DOI: 10.1002/14651858.CD001989.pub2.

Copyright © 2009 The Cochrane Collaboration. Published by John Wiley & Sons, Ltd.

ABSTRACT

Background

Acute central retinal artery occlusion (CRAO) occurs as a sudden interruption of the blood supply to the retina and results in an almost complete loss of vision in the affected eye. There is no generally agreed treatment regimen although a number of therapeutic interventions have been proposed.

Objectives

The objective of this review was to examine the effects of treatments used for acute non-arteritic CRAO.

Search methods

We searched the Cochrane Central Register of Controlled Trials (CENTRAL) (which contains the Cochrane Eyes and Vision Group Trials Register) (*The Cochrane Library,* Issue 3, 2008), MEDLINE (January 1966 to September 2008), EMBASE (January 1980 to September 2008) and the reference lists of relevant papers.

Selection criteria

We included randomised controlled trials (RCTs) only in which one treatment aimed to re-establish blood supply to the retina in people with acute CRAO was compared to another treatment.

Data collection and analysis

Two authors independently assessed the search results for relevant trials. Discrepancies were resolved by discussion.

Main results

We found two RCTs that met our inclusion criteria.

Authors' conclusions

The included studies in this review were small and from single centres. Neither study was completely clear about it's method of treatment allocation. One study described the use of pentoxifylline tablets (three 600 mg tablets daily) and the other the use of enhanced external counterpulsation (EECP) combined with haemodilution. Both studies indicated improved retinal perfusion in the non-control group but neither showed an improvement in vision. Large, well-designed RCTs are still required to establish the most effective treatment for acute CRAO. These studies should be looking at factors important to the patient i.e. improved vision with acceptable risk/side-effects.

Copyright © 2009 The Cochrane Collaboration. Published by John Wiley & Sons, Ltd.

[Intervention Review]

Interventions for the management of CMV-associated anterior segment inflammation

Arundhati Anshu[1,2], Donald Tan[1,2], Soon-Phaik Chee[2,3], Jod S Mehta[1,2], Hla M Htoon[1,2]

[1]Singapore National Eye Centre, Singapore, Singapore. [2]Singapore Eye Research Institute, Singapore, Singapore. [3]Ocular Inflammation & Immunology Service, Singapore National Eye Centre, Singapore, Singapore

Contact address: Arundhati Anshu, Singapore National Eye Centre, 11 Third Hospital Avenue, Singapore, 168751, Singapore. trians@singnet.com.sg.

Editorial group: Cochrane Eyes and Vision Group.
Publication status and date: New, published in Issue 8, 2017.

Citation: Anshu A, Tan D, Chee SP, Mehta JS, Htoon HM. Interventions for the management of CMV-associated anterior segment inflammation. *Cochrane Database of Systematic Reviews* 2017, Issue 8. Art. No.: CD011908. DOI: 10.1002/14651858.CD011908.pub2.

Copyright © 2017 The Cochrane Collaboration. Published by John Wiley & Sons, Ltd.

ABSTRACT

Background

Cytomegalovirus (CMV) is a virus that usually affects people with reduced immunity. In recent years, this virus has been thought to cause repeated inflammation in the eye, in otherwise healthy people. This form of inflammation can cause damage to the cornea (the outer layer of the eye) or to the optic nerve by causing secondary glaucoma, or to both, leading to visual loss.

Objectives

Our primary objective was to assess the effects of drug therapies for the treatment of CMV-associated anterior segment inflammation.

Our secondary objective was to determine the optimal dose and duration of treatment with respect to recurrence and adverse effects.

Search methods

We searched the Cochrane Central Register of Controlled Trials (CENTRAL) (which contains the Cochrane Eyes and Vision Trials Register) (2017, Issue 2), MEDLINE Ovid (1946 to 21 March 2017), Embase Ovid (1947 to 21 March 2017), the ISRCTN registry (www.isrctn.com/editAdvancedSearch); searched 21 March 2017, ClinicalTrials.gov (www.clinicaltrials.gov); searched 21 March 2017, and the WHO International Clinical Trials Registry Platform (ICTRP) (www.who.int/ictrp/search/en); searched 21 March 2017. We did not use any date or language restrictions in the electronic searches for trials. Two review authors independently reviewed the titles and abstracts.

Selection criteria

We searched for randomised controlled trials (RCTs) on the management of CMV-associated anterior segment inflammation.

Data collection and analysis

We planned to have two review authors independently extract data from reports of included studies and analyse data based on methods expected by Cochrane.

Main results

We did not identify any RCTs that met our inclusion criteria.

[Intervention Review]

Binocular versus standard occlusion or blurring treatment for unilateral amblyopia in children aged three to eight years

Vijay Tailor[1], Manuela Bossi[2], Catey Bunce[3], John A Greenwood[4], Annegret Dahlmann-Noor[1]

[1]NIHR Biomedical Research Centre at Moorfields Eye Hospital NHS Foundation Trust and UCL Institute of Ophthalmology, London, UK. [2]Department of Visual Neurosciences, UCL Institute of Ophthalmology, London, UK. [3]Research and Development Department, Moorfields Eye Hospital NHS Foundation Trust, London, UK. [4]Experimental Psychology, University College London, London, UK

Contact address: Annegret Dahlmann-Noor, NIHR Biomedical Research Centre at Moorfields Eye Hospital NHS Foundation Trust and UCL Institute of Ophthalmology, 162 City Road, London, EC1V 2PD, UK. annegret.dahlmann-noor@moorfields.nhs.uk.

Editorial group: Cochrane Eyes and Vision Group.
Publication status and date: New, published in Issue 8, 2015.
Review content assessed as up-to-date: 14 April 2015.

Citation: Tailor V, Bossi M, Bunce C, Greenwood JA, Dahlmann-Noor A. Binocular versus standard occlusion or blurring treatment for unilateral amblyopia in children aged three to eight years. *Cochrane Database of Systematic Reviews* 2015, Issue 8. Art. No.: CD011347. DOI: 10.1002/14651858.CD011347.pub2.

Copyright © 2015 The Cochrane Collaboration. Published by John Wiley & Sons, Ltd.

ABSTRACT

Background

Current treatments for amblyopia in children, occlusion and pharmacological blurring, have had limited success, with less than two-thirds of children achieving good visual acuity of at least 0.20 logMAR in the amblyopic eye, limited improvement of stereopsis, and poor compliance. A new treatment approach, based on the dichoptic presentation of movies or computer games (images presented separately to each eye), may yield better results, as it aims to balance the input of visual information from each eye to the brain. Compliance may also improve with these more child-friendly treatment procedures.

Objectives

To determine whether binocular treatments in children aged three to eight years with unilateral amblyopia result in better visual outcomes than conventional occlusion or pharmacological blurring treatment.

Search methods

We searched the Cochrane Eyes and Vision Group Trials Register (last date of searches: 14 April 2015), the Cochrane Central Register of Controlled Trials (CENTRAL; 2015, Issue 3), Ovid MEDLINE, Ovid MEDLINE In-Process and Other Non-Indexed Citations, Ovid MEDLINE Daily, Ovid OLDMEDLINE (January 1946 to April 2015), EMBASE (January 1980 to April 2015), the ISRCTN registry (www.isrctn.com/editAdvancedSearch), ClinicalTrials.gov (www.clinicaltrials.gov), and the World Health Organization (WHO) International Clinical Trials Registry Platform (ICTRP) (www.who.int/ictrp/search/en). We did not use any date or language restrictions in the electronic searches for trials.

Selection criteria

Two review authors independently screened the results of the search in order to identify studies that met the inclusion criteria of the review: randomised controlled trials (RCTs) that enrolled participants between the ages of three and eight years old with unilateral amblyopia, defined as best-corrected visual acuity (BCVA) worse than 0.200 logMAR in the amblyopic eye, and BCVA 0.200 logMAR or better in the fellow eye, in the presence of an amblyogenic risk factor such as anisometropia, strabismus, or both. Prior to enrolment, participants were to have undergone a cycloplegic refraction and comprehensive ophthalmic examination including fundal examination.

Copyright © 2015 The Cochrane Collaboration. Published by John Wiley & Sons, Ltd.

[Intervention Review]

Laser-assisted subepithelial keratectomy (LASEK) versus laser-assisted in-situ keratomileusis (LASIK) for correcting myopia

Jocelyn Kuryan[1], Anjum Cheema[1], Roy S Chuck[1]

[1]Department of Ophthalmology and Visual Sciences, Albert Einstein College of Medicine, Montefiore Medical Center, New York, New York, USA

Contact address: Jocelyn Kuryan, Department of Ophthalmology and Visual Sciences, Albert Einstein College of Medicine, Montefiore Medical Center, 3332 Rochambeau Avenue, 3rd Floor, New York, New York, 10467, USA. jocelyn.kuryan@gmail.com.

Editorial group: Cochrane Eyes and Vision Group.
Publication status and date: New, published in Issue 2, 2017.

Citation: Kuryan J, Cheema A, Chuck RS. Laser-assisted subepithelial keratectomy (LASEK) versus laser-assisted in-situ keratomileusis (LASIK) for correcting myopia. *Cochrane Database of Systematic Reviews* 2017, Issue 2. Art. No.: CD011080. DOI: 10.1002/14651858.CD011080.pub2.

Copyright © 2017 The Cochrane Collaboration. Published by John Wiley & Sons, Ltd.

ABSTRACT

Background

Near-sightedness, or myopia, is a condition in which light rays entering the eye along the visual axis focus in front of the retina, resulting in blurred vision. Myopia can be treated with spectacles, contact lenses, or refractive surgery. Options for refractive surgery include laser-assisted subepithelial keratectomy (LASEK) and laser-assisted in-situ keratomileusis (LASIK). Both procedures utilize a laser to shape the corneal tissue (front of the eye) to correct refractive error, and both create flaps before laser treatment of corneal stromal tissue. Whereas the flap in LASEK is more superficial and epithelial, in LASIK it is thicker and also includes some anterior stromal tissue. LASEK is considered a surface ablation procedure, much like its predecessor, photorefractive keratectomy (PRK). LASEK was developed as an alternative to PRK to address the issue of pain associated with epithelial debridement used for PRK. Assessing the relative benefits and risks/side effects of LASEK and LASIK warrants a systematic review.

Objectives

To assess the effects of LASEK versus LASIK for correcting myopia.

Search methods

We searched the Cochrane Central Register of Controlled Trials (CENTRAL), which contains the Cochrane Eyes and Vision Trials Register (2016, Issue 10); MEDLINE Ovid (1946 to 24 October 2016); Embase.com (1947 to 24 October 2016); PubMed (1948 to 24 October 2016); LILACS (Latin American and Caribbean Health Sciences Literature Database; 1982 to 24 October 2016); the *meta*Register of Controlled Trials (*m*RCT) (www.controlled-trials.com), last searched 20 June 2014; ClinicalTrials.gov (www.clinicaltrials.gov); searched 24 October 2016; and the WHO International Clinical Trials Registry Platform (ICTRP) (www.who.int/ictrp/search/en); searched 24 October 2016. We did not use any date or language restrictions in the electronic searches for trials.

Selection criteria

We considered only randomized controlled trials (RCTs) for the purposes of this review. Eligible RCTs were those in which myopic participants were assigned randomly to receive either LASEK or LASIK in one or both eyes. We also included paired-eye studies in which investigators randomly selected which of the participant's eyes would receive LASEK or LASIK and assigned the other eye to the other procedure. Participants were men or women between the ages of 18 and 60 years with myopia up to 12 diopters (D) and/or myopic astigmatism of severity up to 3 D, who did not have a history of prior refractive surgery.

Copyright © 2017 The Cochrane Collaboration. Published by John Wiley & Sons, Ltd.

[Intervention Review]

Ginkgo biloba extract for age-related macular degeneration

Jennifer R Evans[1]

[1]Cochrane Eyes and Vision Group, ICEH, London School of Hygiene & Tropical Medicine, London, UK

Contact address: Jennifer R Evans, Cochrane Eyes and Vision Group, ICEH, London School of Hygiene & Tropical Medicine, Keppel Street, London, WC1E 7HT, UK. jennifer.evans@lshtm.ac.uk.

Editorial group: Cochrane Eyes and Vision Group.
Publication status and date: New search for studies and content updated (no change to conclusions), published in Issue 1, 2013.
Review content assessed as up-to-date: 5 October 2012.

Citation: Evans JR. Ginkgo biloba extract for age-related macular degeneration. *Cochrane Database of Systematic Reviews* 2013, Issue 1. Art. No.: CD001775. DOI: 10.1002/14651858.CD001775.pub2.

Copyright © 2013 The Cochrane Collaboration. Published by John Wiley & Sons, Ltd.

ABSTRACT

Background

Ginkgo is used in the treatment of peripheral vascular disease and 'cerebral insufficiency'. It is thought to have several potential mechanisms of action including increased blood flow, platelet activating factor antagonism, and prevention of membrane damage caused by free radicals. Vascular factors and oxidative damage are thought to be two potential mechanisms in the pathology of age-related macular degeneration (AMD).

Objectives

The objective of this review was to determine the effect of Ginkgo biloba extract on the progression of AMD.

Search methods

We searched CENTRAL (which contains the Cochrane Eyes and Vision Group Trials Register) (*The Cochrane Library* 2012, Issue 10), Ovid MEDLINE, Ovid MEDLINE In-Process and Other Non-Indexed Citations, Ovid MEDLINE Daily, Ovid OLDMEDLINE (January 1946 to October 2012), EMBASE (January 1980 to October 2012), Allied and Complementary Medicine Database (AMED) (January 1985 to October 2012), OpenGrey (System for Information on Grey Literature in Europe) (www.opengrey.eu/), the *meta*Register of Controlled Trials (*m*RCT) (www.controlled-trials.com), ClinicalTrials.gov (www.clinicaltrials.gov) and the WHO International Clinical Trials Registry Platform (ICTRP) (www.who.int/ictrp/search/en). We did not use any date or language restrictions in the electronic searches for trials. We last searched the electronic databases on 5 October 2012. We searched the reference lists of identified reports and the Science Citation Index. We also contacted investigators of included studies for additional information.

Selection criteria

All randomised trials in people with AMD where Ginkgo biloba extract had been compared to control were included.

Data collection and analysis

The review author extracted data using a standardised form. The data were verified with the trial investigators. Trial quality was assessed.

Main results

Two published trials were identified that randomised a total of 119 people. In one study conducted in France, 20 people were randomly allocated to Gingko biloba extract EGb 761 80 mg twice daily or placebo. In the other study conducted in Germany, 99 people were randomly allocated to two different doses of Ginkgo biloba extract EGb 761 (240 mg per day and 60 mg per day). Treatment duration in both studies was six months. Both trials reported some positive effects of Ginkgo biloba on vision however their results could not be pooled. Adverse effects and quality of life for people with AMD were not reported.

Copyright © 2013 The Cochrane Collaboration. Published by John Wiley & Sons, Ltd.

[Intervention Review]

Vitamin A and fish oils for retinitis pigmentosa

Sobharani Rayapudi[1], Stephen G Schwartz[2], Xue Wang[1], Pamela Chavis[3]

[1]Department of Epidemiology, Johns Hopkins Bloomberg School of Public Health, Baltimore, Maryland, USA. [2]Bascom Palmer Eye Institute, Miami, Florida, USA. [3]Department of Ophthalmology, Medical University of South Carolina, Charleston, South Carolina, USA

Contact address: Stephen G Schwartz, Bascom Palmer Eye Institute, Miami, Florida, USA. sschwartz2@med.miami.edu.

Editorial group: Cochrane Eyes and Vision Group.
Publication status and date: New, published in Issue 12, 2013.
Review content assessed as up-to-date: 20 August 2013.

Citation: Rayapudi S, Schwartz SG, Wang X, Chavis P. Vitamin A and fish oils for retinitis pigmentosa. *Cochrane Database of Systematic Reviews* 2013, Issue 12. Art. No.: CD008428. DOI: 10.1002/14651858.CD008428.pub2.

Copyright © 2013 The Cochrane Collaboration. Published by John Wiley & Sons, Ltd.

ABSTRACT

Background

Retinitis pigmentosa (RP) comprises a group of hereditary eye diseases characterized by progressive degeneration of retinal photoreceptors. It results in severe visual loss that may lead to legal blindness. Symptoms may become manifest during childhood or adulthood, and include poor night vision (nyctalopia) and constriction of peripheral vision (visual field loss). This field loss is progressive and usually does not reduce central vision until late in the disease course.The worldwide prevalence of RP is one in 4000, with 100,000 patients affected in the USA. At this time, there is no proven therapy for RP.

Objectives

The objective of this review was to synthesize the best available evidence regarding the effectiveness and safety of vitamin A and fish oils (docosahexaenoic acid (DHA)) in preventing the progression of RP.

Search methods

We searched CENTRAL (which contains the Cochrane Eyes and Vision Group Trials Register) (2013, Issue 7), Ovid MEDLINE, Ovid MEDLINE In-Process and Other Non-Indexed Citations, Ovid MEDLINE Daily, Ovid OLDMEDLINE (January 1946 to August 2013), EMBASE (January 1980 to August 2013), Latin American and Caribbean Health Sciences Literature Database (LILACS) (January 1982 to August 2013), the metaRegister of Controlled Trials (mRCT) (www.controlled-trials.com), ClinicalTrials.gov (www.clinicaltrials.gov) and the WHO International Clinical Trials Registry Platform (ICTRP) (www.who.int/ictrp/search/en). We did not use any date or language restrictions in the electronic searches for trials. We last searched the electronic databases on 20 August 2013.

Selection criteria

We included randomized controlled trials (RCTs) evaluating the effectiveness of vitamin A, fish oils (DHA) or both, as a treatment for RP. We excluded cluster-randomized trials and cross-over trials.

Data collection and analysis

We pre-specified the following outcomes: mean change from baseline visual field, mean change from baseline electroretinogram (ERG) amplitudes, and anatomic changes as measured by optical coherence tomography (OCT), at one year; as well as mean change in visual acuity at five-year follow-up. Two authors independently evaluated risk of bias for all included trials and extracted data from the publications. We also contacted study investigators for further information on trials with publications that did not report outcomes on all randomized patients.

Copyright © 2013 The Cochrane Collaboration. Published by John Wiley & Sons, Ltd.

[Intervention Review]

Probing for congenital nasolacrimal duct obstruction

Carisa Petris[1], Don Liu[2]

[1]Ophthalmic Plastic, Reconstructive, and Orbital Surgery, Mason Eye Institute, University of Missouri Health Care, Columbia, Missouri, USA. [2]Department of Ophthalmology, Mason Eye Institute, University of Missouri Health Care, Columbia, Missouri, USA

Contact address: Don Liu, Department of Ophthalmology, Mason Eye Institute, University of Missouri Health Care, Columbia, Missouri, 65211, USA. liud@health.missouri.edu.

Editorial group: Cochrane Eyes and Vision Group.
Publication status and date: New, published in Issue 7, 2017.

Citation: Petris C, Liu D. Probing for congenital nasolacrimal duct obstruction. *Cochrane Database of Systematic Reviews* 2017, Issue 7. Art. No.: CD011109. DOI: 10.1002/14651858.CD011109.pub2.

Copyright © 2017 The Cochrane Collaboration. Published by John Wiley & Sons, Ltd.

ABSTRACT

Background

Congenital nasolacrimal duct obstruction (NLDO) is a common condition causing excessive tearing in the first year of life. Infants present with excessive tearing or mucoid discharge from the eyes due to blockage of the nasolacrimal duct system, which can result in maceration of the skin of the eyelids and local infections, such as conjunctivitis, that may require antibiotics. The incidence of nasolacrimal duct obstruction in early childhood ranges from 5% to 20% and often resolves without surgery. Treatment options for this condition are either conservative therapy, including observation (or deferred probing), massage of the lacrimal sac and antibiotics, or probing the nasolacrimal duct to open the membranous obstruction at the distal nasolacrimal duct. Probing may be performed without anesthesia in the office setting or under general anesthesia in the operating room. Probing may serve to resolve the symptoms by opening the membranous obstruction; however, it may not be successful if the obstruction is due to a bony protrusion of the inferior turbinate into the nasolacrimal duct or when the duct is edematous (swollen) due to infection such as dacryocystitis. Additionally, potential complications with probing include creation of a false passage and injury to the nasolacrimal duct, canaliculi and puncta, bleeding, laryngospasm, or aspiration.

Objectives

To assess the effects of probing for congenital nasolacrimal duct obstruction.

Search methods

We searched the Cochrane Central Register of Controlled Trials (CENTRAL), which contains the Cochrane Eyes and Vision Trials Register (2016, Issue 8); MEDLINE Ovid (1946 to 30 August 2016); Embase.com (1947 to 30 August 2016); PubMed (1948 to 30 August 2016); LILACS (Latin American and Caribbean Health Sciences Literature Database; 1982 to 30 August 2016), the *meta*Register of Controlled Trials (*m*RCT) (www.controlled-trials.com), last searched 14 August 2014; ClinicalTrials.gov (www.clinicaltrials.gov), searched 30 August 2016; and the WHO International Clinical Trials Registry Platform (ICTRP) (www.who.int/ictrp/search/en), searched 30 August 2016. We did not use any date or language restrictions in the electronic searches for trials.

Selection criteria

We included randomized controlled trials (RCTs) that compared probing (office-based or hospital-based under general anesthesia) versus no (or deferred) probing or other interventions (observation alone, antibiotic drops only, or antibiotic drops plus massage of the nasolacrimal duct). We did not include studies that compared different probing techniques or probing compared with other surgical procedures. We included studies in children aged three weeks to four years who may have presented with tearing and conjunctivitis.

Copyright © 2017 The Cochrane Collaboration. Published by John Wiley & Sons, Ltd.

[Intervention Review]

Antimetabolites in cataract surgery to prevent failure of a previous trabeculectomy

Roger E Thomas[1], Andrew Crichton[2], Bennett C Thomas[3]

[1]Department of Family Medicine, Faculty of Medicine, University of Calgary, Calgary, Canada. [2]Ophthalmology, Department of Surgery, University of Calgary Medical School, Calgary, Canada. [3]Calgary, Canada

Contact address: Roger E Thomas, Department of Family Medicine, Faculty of Medicine, University of Calgary, UCMC, #1707-1632 14th Avenue, Calgary, AB, T2M 1N7, Canada. rthomas@ucalgary.ca.

Editorial group: Cochrane Eyes and Vision Group.
Publication status and date: New, published in Issue 7, 2014.
Review content assessed as up-to-date: 10 June 2014.

Citation: Thomas RE, Crichton A, Thomas BC. Antimetabolites in cataract surgery to prevent failure of a previous trabeculectomy. *Cochrane Database of Systematic Reviews* 2014, Issue 7. Art. No.: CD010627. DOI: 10.1002/14651858.CD010627.pub2.

Copyright © 2014 The Cochrane Collaboration. Published by John Wiley & Sons, Ltd.

ABSTRACT

Background

Patients having cataract surgery have often earlier undergone a trabeculectomy for glaucoma. However, cataract surgery may be associated with failure of the previous glaucoma surgery and antimetabolites may be used with cataract surgery to prevent such failure. There is no systematic review on whether antimetabolites with cataract surgery prevent failure of a previous trabeculectomy.

Objectives

To assess the effects of antimetabolites with cataract surgery on functioning of a previous trabeculectomy.

Search methods

We searched CENTRAL (which contains the Cochrane Eyes and Vision Group Trials Register) (2014, Issue 5), Ovid MEDLINE, Ovid MEDLINE In-Process and Other Non-Indexed Citations, Ovid MEDLINE Daily, Ovid OLDMEDLINE (January 1946 to June 2014), EMBASE (January 1980 to June 2014), Latin American and Caribbean Health Sciences Literature Database (LILACS) (January 1982 to June 2014), the *meta*Register of Controlled Trials (*m*RCT) (www.controlled-trials.com), ClinicalTrials.gov (www.clinicaltrials.gov) and the World Health Organization (WHO) International Clinical Trials Registry Platform (ICTRP) (www.who.int/ictrp/search/en). We did not use any date or language restrictions in the electronic searches for trials. We last searched the electronic databases on 10 June 2014. We also searched the Science Citation Index database (July 2013) and reference lists of potentially relevant studies.

Selection criteria

Randomised controlled trials (RCTs) of antimetabolites with cataract surgery in people with a functioning trabeculectomy.

Data collection and analysis

Two review authors independently reviewed the titles and abstracts from the electronic searches. Two review authors independently assessed relevant full-text articles and entered data.

Main results

We identified no RCTs to test the effectiveness of antimetabolites with cataract surgery in individuals with the intention of preventing failure of a previous trabeculectomy.

Copyright © 2014 The Cochrane Collaboration. Published by John Wiley & Sons, Ltd.

[Intervention Review]

Valacyclovir versus acyclovir for the treatment of herpes zoster ophthalmicus in immunocompetent patients

Alexander K Schuster[1], Björn C Harder[2], Frank C Schlichtenbrede[2], Marc N Jarczok[3], Jonas Tesarz[4]

[1]Department of Ophthalmology, University Medical Center Mainz, Mainz, Germany. [2]Department of Ophthalmology, Medical Faculty Mannheim, Heidelberg University, Mannheim, Germany. [3]Heidelberg University, Heidelberg, Germany. [4]Department of General Internal Medicine and Psychosomatics, Medical Hospital, Heidelberg University, Heidelberg, Germany

Contact address: Alexander K Schuster, Department of Ophthalmology, University Medical Center Mainz, Langenbeckstr. 1, Mainz, 55131, Germany. alexander.k.schuster@gmx.de.

Editorial group: Cochrane Eyes and Vision Group.
Publication status and date: New, published in Issue 11, 2016.

Citation: Schuster AK, Harder BC, Schlichtenbrede FC, Jarczok MN, Tesarz J. Valacyclovir versus acyclovir for the treatment of herpes zoster ophthalmicus in immunocompetent patients. *Cochrane Database of Systematic Reviews* 2016, Issue 11. Art. No.: CD011503. DOI: 10.1002/14651858.CD011503.pub2.

Copyright © 2016 The Cochrane Collaboration. Published by John Wiley & Sons, Ltd.

ABSTRACT

Background

Herpes zoster ophthalmicus affects the eye and vision, and is caused by the reactivation of the varicella zoster virus in the distribution of the first division of the trigeminal nerve. An aggressive management of acute herpes zoster ophthalmicus with systemic antiviral medication is generally recommended as the standard first-line treatment for herpes zoster ophthalmicus infections. Both acyclovir and its prodrug valacyclovir are medications that are approved for the systemic treatment of herpes zoster. Although it is known that valacyclovir has an improved bioavailability and steadier plasma concentration, it is currently unclear as to whether this leads to better treatment results and less ocular complications.

Objectives

To assess the effects of valacyclovir versus acyclovir for the systemic antiviral treatment of herpes zoster ophthalmicus in immunocompetent patients.

Search methods

We searched CENTRAL (which contains the Cochrane Eyes and Vision Trials Register; 2016, Issue 5), Ovid MEDLINE, Ovid MEDLINE In-Process and Other Non-Indexed Citations, Ovid MEDLINE Daily, Ovid OLDMEDLINE (January 1946 to June 2016), Embase (January 1980 to June 2016), Web of Science Conference Proceedings Citation Index-Science (CPCI-S; January 1990 to June 2016), BIOSIS Previews (January 1969 to June 2016), the ISRCTN registry (www.isrctn.com/editAdvancedSearch), ClinicalTrials.gov (www.clinicaltrials.gov), and the World Health Organization (WHO) International Clinical Trials Registry Platform (ICTRP; www.who.int/ictrp/search/en). We did not use any date or language restrictions in the electronic searches for trials. We last searched the electronic databases on 13 June 2016.

Selection criteria

We considered all randomised controlled trials (RCTs) in which systemic valacyclovir was compared to systemic acyclovir medication for treatment of herpes zoster ophthalmicus. There were no language restrictions.

[Intervention Review]

Vision screening for amblyopia in childhood

Christine Powell[1], Sarah R Hatt[2]

[1]Department of Ophthalmology, Royal Victoria Infirmary, Newcastle upon Tyne, UK. [2]Ophthalmology Research, Mayo Clinic, Rochester, USA

Contact address: Christine Powell, Department of Ophthalmology, Royal Victoria Infirmary, Claremont Wing, Queen Victoria Road, Newcastle upon Tyne, NE1 4LP, UK. christine.powell2@nuth.nhs.uk.

Editorial group: Cochrane Eyes and Vision Group.
Publication status and date: Edited (no change to conclusions), published in Issue 3, 2009.
Review content assessed as up-to-date: 14 August 2008.

Citation: Powell C, Hatt SR. Vision screening for amblyopia in childhood. *Cochrane Database of Systematic Reviews* 2009, Issue 3. Art. No.: CD005020. DOI: 10.1002/14651858.CD005020.pub3.

Copyright © 2009 The Cochrane Collaboration. Published by John Wiley & Sons, Ltd.

ABSTRACT

Background

Amblyopia is a reversible deficit of vision that has to be treated within the sensitive period for visual development. Screening programmes have been set up to detect this largely asymptomatic condition and refer children for treatment while an improvement in vision is still possible. The value of such programmes and the optimum protocol for administering them remain controversial.

Objectives

The objective of this review was to evaluate the effectiveness of vision screening in reducing the prevalence of amblyopia.

Search methods

We searched the Cochrane Central Register of Controlled Trials (*The Cochrane Library* Issue 3, 2008), MEDLINE (January 1950 to August 2008) and EMBASE (January 1947 to August 2008). The electronic databases were last searched on 15 August 2008. No language restrictions were placed on these searches. No handsearching was done.

Selection criteria

We planned to analyse data from randomised controlled trials and cluster-randomised trials comparing the prevalence of amblyopia in screened versus unscreened populations.

Data collection and analysis

Two authors independently assessed study abstracts identified by the electronic searches. Full text copies of appropriate studies were obtained and, where necessary, authors were contacted. No data were available for analysis and no meta-analysis was performed.

Main results

Despite the large amount of literature available regarding vision screening no trials designed to compare the prevalence of amblyopia in screened versus unscreened populations were found.

Copyright © 2009 The Cochrane Collaboration. Published by John Wiley & Sons, Ltd.

[Intervention Review]

Routine vitamin A supplementation for the prevention of blindness due to measles infection in children

Segun Bello[1], Martin M Meremikwu[2], Regina I Ejemot-Nwadiaro[3], Olabisi Oduwole[4]

[1]The Nordic Cochrane Centre, Righospitalet, Copenhagen, Denmark. [2]Department of Paediatrics, University of Calabar Teaching Hospital, Calabar, Nigeria. [3]Department of Public Health, College of Medical Sciences, University of Calabar, Calabar, Nigeria. [4]Institute of Tropical Diseases Research and Prevention, University of Calabar Teaching Hospital (ITDR/P), Calabar, Nigeria

Contact address: Segun Bello, The Nordic Cochrane Centre, Righospitalet, Bledgamsvej 9, 7811, Copenhagen, 2100, Denmark. drsegunbello@yahoo.com, sb@cochrane.dk.

Editorial group: Cochrane Acute Respiratory Infections Group.
Publication status and date: New search for studies and content updated (no change to conclusions), published in Issue 8, 2016.

Citation: Bello S, Meremikwu MM, Ejemot-Nwadiaro RI, Oduwole O. Routine vitamin A supplementation for the prevention of blindness due to measles infection in children. *Cochrane Database of Systematic Reviews* 2016, Issue 8. Art. No.: CD007719. DOI: 10.1002/14651858.CD007719.pub4.

Copyright © 2016 The Cochrane Collaboration. Published by John Wiley & Sons, Ltd.

ABSTRACT

Background

Reduced vitamin A concentration increases the risk of blindness in children infected with the measles virus. Promoting vitamin A supplementation in children with measles contributes to the control of blindness in children, which is a high priority within the World Health Organization (WHO) *VISION 2020 The Right to Sight Program*.

Objectives

To assess the efficacy of vitamin A in preventing blindness in children with measles without prior clinical features of vitamin A deficiency.

Search methods

We searched CENTRAL 2015, Issue 11, MEDLINE (1950 to December week 3, 2015), Embase (1974 to December 2015) and LILACS (1985 to December 2015).

Selection criteria

Randomised controlled trials (RCTs) assessing the efficacy of vitamin A in preventing blindness in well-nourished children diagnosed with measles but with no prior clinical features of vitamin A deficiency.

Data collection and analysis

For the original review, two review authors independently assessed studies for eligibility and extracted data on reported outcomes. We contacted trial authors of the included studies for additional information on unpublished data. We included two RCTs which were clinically heterogenous. We presented the continuous outcomes reported as the mean difference (MD) with 95% confidence interval (CI) and dichotomous outcomes as risk ratio (RR) with 95% CI. Due to marked clinical heterogeneity we considered it inappropriate to perform a meta-analysis.

Copyright © 2016 The Cochrane Collaboration. Published by John Wiley & Sons, Ltd.

[Intervention Review]

Vitamin C and superoxide dismutase (SOD) for diabetic retinopathy

Carlos César Lopes de Jesus[1], Álvaro N Atallah[2], Orsine Valente[3], Virginia Fernandes Moça Trevisani[4]

[1]Department of Internal Medicine and Therapeutics Discipline, Universidade Federal de São Paulo / Escola Paulista de Medicina, São Paulo, Brazil. [2]Brazilian Cochrane Centre, Universidade Federal de São Paulo / Escola Paulista de Medicina, São Paulo, Brazil. [3]Department of Internal Medicine, Universidade Federal de São Paulo / Escola Paulista de Medicina, São Paulo, Brazil. [4]Rheumatology/Internal Medicine and Therapeutics, UNISA (Santo Amaro University)/UNIFESP (Paulista Medicine School), Jardim Marajoara, Brazil

Contact address: Carlos César Lopes de Jesus, Department of Internal Medicine and Therapeutics Discipline, Universidade Federal de São Paulo / Escola Paulista de Medicina, Rua Pedro de Toledo, 598, São Paulo, Vila Clementino, CEP 04039-001, Brazil. caceloje@gmail.com. caceloje@uol.com.br.

Editorial group: Cochrane Metabolic and Endocrine Disorders Group.
Publication status and date: Edited (no change to conclusions), published in Issue 3, 2009.
Review content assessed as up-to-date: 29 June 2006.

Citation: Lopes de Jesus CC, Atallah ÁN, Valente O, Fernandes Moça Trevisani V. Vitamin C and superoxide dismutase (SOD) for diabetic retinopathy. *Cochrane Database of Systematic Reviews* 2008, Issue 1. Art. No.: CD006695. DOI: 10.1002/14651858.CD006695.pub2.

Copyright © 2009 The Cochrane Collaboration. Published by John Wiley & Sons, Ltd.

ABSTRACT

Background

There is increasing evidence that diabetic retinopathy is caused by the action of free radicals. Radical scavengers like vitamin C and superoxide dismutase (SOD) may influence the outcome and progression of diabetic retinopathy, but no systematic review of the literature has been published to examine this hypothesis.

Objectives

The aim of the current research was to review the literature in a standard systematic way in order to assess the effects of vitamin C and superoxide dismutase on diabetic retinopathy in methodologically robust trials.

Search methods

We tried to obtain studies from computerised searches of MEDLINE, EMBASE, CINAHL, Web of Science and *The Cochrane Library*.

Selection criteria

Only randomized clinical trials (RCTs) that evaluated the effect of vitamin C, superoxide dismutase or both in the treatment of diabetic retinopathy were considered.

Data collection and analysis

Two authors independently read all abstracts, titles or both and wanted to assess risk of bias and to perform data extraction. Discrepancies were planned to be resolved by consensus or by the judgement of a third author.

Copyright © 2009 The Cochrane Collaboration. Published by John Wiley & Sons, Ltd.

8.6. Apêndice 6. *Abstract* das revisões sistemáticas da Colaboração Cochrane com desfechos que não possuem evidências para a intervenção e não recomendam novos estudos **(C2)**

[Intervention Review]

Acupuncture for glaucoma

Simon K Law[1], Tianjing Li[2]

[1]Jules Stein Eye Institute, University of California, Los Angeles, Los Angeles, California, USA. [2]Department of Epidemiology, Johns Hopkins Bloomberg School of Public Health, Baltimore, Maryland, USA

Contact address: Simon K Law, Jules Stein Eye Institute, University of California, Los Angeles, 100 Stein Plaza 2-235, Los Angeles, California, 90095, USA. Law@jsei.ucla.edu.

Editorial group: Cochrane Eyes and Vision Group.
Publication status and date: New search for studies and content updated (no change to conclusions), published in Issue 5, 2013.

Citation: Law SK, Li T. Acupuncture for glaucoma. *Cochrane Database of Systematic Reviews* 2013, Issue 5. Art. No.: CD006030. DOI: 10.1002/14651858.CD006030.pub3.

Copyright © 2013 The Cochrane Collaboration. Published by John Wiley & Sons, Ltd.

ABSTRACT

Background

Glaucoma is a multifactorial optic neuropathy characterized by an acquired loss of retinal ganglion cells at levels beyond normal age-related loss and corresponding atrophy of the optic nerve. Although many treatments are available to manage glaucoma, glaucoma is a chronic condition. Some patients may seek complementary or alternative medicine approaches such as acupuncture to supplement their regular treatment. The underlying plausibility of acupuncture is that disorders related to the flow of Chi (the traditional Chinese concept translated as vital force or energy) can be prevented or treated by stimulating relevant points on the body surface.

Objectives

The objective of this review was to assess the effectiveness and safety of acupuncture in people with glaucoma.

Search methods

We searched the Cochrane Central Register of Controlled Trials (CENTRAL) (which contains the Cochrane Eyes and Vision Group Trials Register) (*The Cochrane Library* 2012, Issue 12), Ovid MEDLINE, Ovid MEDLINE In-Process and Other Non-Indexed Citations, Ovid MEDLINE Daily, Ovid OLDMEDLINE (January 1946 to January 2013), EMBASE (January 1980 to January 2013), Latin American and Caribbean Literature on Health Sciences (LILACS) (January 1982 to January 2013), Cumulative Index to Nursing and Allied Health Literature (CINAHL) (January 1937 to January 2013), ZETOC (January 1993 to January 2013), Allied and Complementary Medicine Database (AMED) (January 1985 to January 2013), the *meta*Register of Controlled Trials (*m*RCT) (www.controlled-trials.com), ClinicalTrials.gov (www.clinicaltrials.gov), the WHO International Clinical Trials Registry Platform (ICTRP) (www.who.int/ictrp/search/en) and the National Center for Complementary and Alternative Medicine web site (NCCAM) (http://nccam.nih.gov). We did not use any language or date restrictions in the search for trials. We last searched the electronic databases on 8 January 2013 with the exception of NCCAM which was last searched on 14 July 2010. We also handsearched Chinese medical journals at Peking Union Medical College Library in April 2007.

We searched the Chinese Acupuncture Trials Register, the Traditional Chinese Medical Literature Analysis and Retrieval System (TCMLARS), and the Chinese Biological Database (CBM) for the original review; we did not search these databases for the 2013 review update.

Selection criteria

We included randomized controlled trials (RCTs) in which one arm of the study involved acupuncture treatment.

Copyright © 2013 The Cochrane Collaboration. Published by John Wiley & Sons, Ltd.

[Intervention Review]

Needling for encapsulated trabeculectomy filtering blebs

Andrew Feyi-Waboso[1], Henry OD Ejere[2]

[1]Eye Department, Royal Gwent NHS Trust, Newport, UK. [2]Hode Internal Medicine, Texas, USA

Contact address: Andrew Feyi-Waboso, Eye Department, Royal Gwent NHS Trust, Cardiff Road, Newport, Gwent, Wales, NP20 2UB, UK. andrew.feyiwaboso@gwent.wales.nhs.uk.

Editorial group: Cochrane Eyes and Vision Group.
Publication status and date: New search for studies and content updated (no change to conclusions), published in Issue 8, 2012.

Citation: Feyi-Waboso A, Ejere HOD. Needling for encapsulated trabeculectomy filtering blebs. *Cochrane Database of Systematic Reviews* 2012, Issue 8. Art. No.: CD003658. DOI: 10.1002/14651858.CD003658.pub3.

Copyright © 2012 The Cochrane Collaboration. Published by John Wiley & Sons, Ltd.

ABSTRACT

Background

Encapsulation of a filtering bleb following trabeculectomy may lead to elevation of intraocular pressure, prompting further medical or surgical intervention. It has been suggested that needling of an encapsulated bleb may be effective in re-establishing drainage and lowering intraocular pressure.

Objectives

The objective of this review was to assess the effects of needling encapsulated blebs on intraocular pressure.

Search methods

We searched CENTRAL (which contains the Cochrane Eyes and Vision Group Trials Register) (*The Cochrane Library* 2012, Issue 1), MEDLINE (January 1950 to February 2012), EMBASE (January 1980 to February 2012), Latin American and Caribbean Literature on Health Sciences (LILACS) (January 1982 to February 2012), the *meta*Register of Controlled Trials (*m*RCT) (www.controlled-trials.com), ClinicalTrials.gov (www.clinicaltrials.gov) and the WHO International Clinical Trials Registry Platform (ICTRP) (www.who.int/ictrp/search/en). We did not use any date or language restrictions in the electronic searches for trials. The electronic databases were last searched on 14 February 2012.

Selection criteria

We included randomised and quasi-randomised in which bleb needling was compared with any form of antiglaucoma medication in people with encapsulated trabeculectomy blebs. The primary outcome was mean intraocular pressure measured in millimetres of mercury at day one, one week, one month and at last available follow-up.

Data collection and analysis

Two review authors independently assessed trial quality and extracted data. Study authors were contacted for additional information.

Main results

One trial, which randomised 25 eyes to either needling or medical treatment, met the inclusion criteria. At one day post-treatment, mean intraocular pressure was lower in the needling group (16.28 mmHg, standard deviation 5.9) than the medical group (19.45 mmHg, standard deviation 3.75). The difference was not statistically significant. At all other follow-up points, mean intraocular pressure was consistently higher in the needling group than the medical group, although the differences were not statistically significant. However, only one needled bleb remained successful at the end of follow-up compared to 10 out of the 11 blebs managed conservatively. This difference was statistically highly significant.

Copyright © 2012 The Cochrane Collaboration. Published by John Wiley & Sons, Ltd.

ANEXOS

Anexo 1. Parecer do Comitê de Ética

unesp
UNIVERSIDADE ESTADUAL PAULISTA
"JÚLIO DE MESQUITA FILHO"
Campus de Botucatu

FACULDADE DE MEDICINA FMB 1963 BOTUCATU

Telefone: (14) 38801608/3880-1609/3880-1313
e-mail secretaria: capellup@fmb.unesp.br / kleber@fmb.unesp.br
e-mail coordenação: smolina@fmb.unesp.br

Endereço: Chácara Buttignolli s/n – Rubião Júnior – Botucatu – SP
CEP: 18618-907

Comitê de Ética em Pesquisa em Seres Humanos
Ética 20 anos
Registrado na CONEP em 30/04/1997

Botucatu, 29 de maio de 2017 OF. 73/2017-CEP

Ilustríssima Senhora
Profa. Dra. Eliane Chaves Jorge
Departamento de Oftalmologia, Otorrinolaringologia e CCP da
Faculdade de Medicina de Botucatu

Prezada Profa. Eliane,

Com referência a Pesquisa **"Mapeamento das evidências das Revisões Sistemáticas de Oftalmologia da Base de Dados Cochrane"**, a ser conduzido por Shaira Ferrari Rodor, orientada por Vossa Senhoria, coorientada por Regina Paolucci El Dib, não necessitará de análise ética, haja vista tratar-se de estudo envolvendo Revisão Sistemática da Literatura.

Atenciosamente,

Profª Drª Silvana Andréa Molina Lima
Coordenadora do CEP