



# REVISTA BRASILEIRA DE ANESTESIOLOGIA

Publicação Oficial da Sociedade Brasileira de Anestesiologia  
[www.sba.com.br](http://www.sba.com.br)



## CLINICAL INFORMATION

# Livedo reticularis by hypothermia during anesthesia for dental treatment in Down's syndrome patient



Heber de Moraes Penna<sup>a,b,\*</sup>, Norma Sueli Pinheiro Modolo<sup>b</sup>, Dário Humberto de Paiva<sup>a</sup>

<sup>a</sup> Clínica de Anestesia de Goiânia, Goiânia, GO, Brazil

<sup>b</sup> Universidade Estadual Paulista (UNESP), Faculdade de Medicina de Botucatu, Faculdade de Ciências Médicas e Biológicas de Botucatu, Botucatu, SP, Brazil

Received 22 December 2017; accepted 6 February 2018

Available online 25 June 2018

### KEYWORDS

Down's syndrome;  
Trisomy 21;  
Anesthesia;  
Livedo reticularis;  
Hypothermia;  
Dental treatment

### Abstract

**Background:** Livedo reticularis is a benign dermatological condition characterized by ischemic areas permeated by erythematous-cyanotic areas in a lacy pattern, and may be transient or permanent and is frequently associated with body exposure to cold. Cutaneous arterial vasospasm promotes ischemia, and venous dilation of the congested areas occurs by tissue hypoxia or autonomic dysfunction. Patients with Down's syndrome, due to their physiological peculiarities, constitute a representative part of those who require dental care under general anesthesia, and livedo reticularis has a reported incidence of 8–12% in Down's syndrome patients.

**Objectives:** To describe the physiological livedo reticularis in a Down's syndrome patient, with the onset during the anesthetic-surgical procedure.

**Case report:** 5-year-old female patient with Down's syndrome, admitted for dental treatment under balanced general anesthesia with sevoflurane, fentanyl, and atracurium. Transoperative hypothermia occurred with axillary temperature reaching 34.5 °C after 30 min after the beginning of anesthesia. At the end of the procedure, red-purplish skin lesions interspersed with areas of pallor were observed exclusively on the ventromedial aspect of the right forearm, with no systemic signs suggestive of allergic reactions. The established diagnosis was physiological livedo reticularis. There was a total fading of the lesions within 5 days.

**Conclusion:** This report evidences the need for thermal control of patients undergoing anesthesia, as well as the manifestation of livedo reticularis as a consequence of transoperative hypothermia.

© 2018 Sociedade Brasileira de Anestesiologia. Published by Elsevier Editora Ltda. This is an open access article under the CC BY-NC-ND license (<http://creativecommons.org/licenses/by-nc-nd/4.0/>).

\* Corresponding author.

E-mail: [mrpenna2@gmail.com](mailto:mrpenna2@gmail.com) (H.M. Penna).

**PALAVRAS-CHAVE**

Síndrome de Down;  
Trissomia do 21;  
Anestesia;  
Livedo reticular;  
Hipotermia;  
Tratamento  
odontológico

**Livedo reticular por hipotermia durante anestesia para tratamento odontológico em paciente com síndrome de Down****Resumo:**

**Justificativa:** O livedo reticular representa quadro dermatológico benigno, caracterizado por áreas isquêmicas permeadas por áreas eritematocianóticas em padrão rendilhado, pode ser transitório ou permanente e frequentemente é associado à exposição corporal ao frio. O vasoespasmo arterial cutâneo promove a isquemia e a dilatação venosa das áreas congestionadas e ocorre por hipóxia tecidual ou por disfunção autonômica. Os portadores da síndrome de Down, devido às suas peculiaridades fisiológicas, constituem uma representativa parcela daqueles que necessitam de atendimento odontológico sob anestesia geral e o livedo reticular tem incidência relatada de 8% a 12% em pacientes com síndrome de Down.

**Objetivos:** Descrever quadro de livedo reticular fisiológico em paciente portador de síndrome de Down, com aparecimento durante o ato anestésico-cirúrgico.

**Relato do caso:** Paciente de cinco anos, sexo feminino, síndrome de Down, admitida para tratamento odontológico sob anestesia geral balanceada, com emprego de sevoflurano, fentanil e atracúrio. Houve ocorrência de hipotermia transoperatória, a temperatura axilar atingiu 34,5 °C após 30 minutos do início da anestesia. Ao término do procedimento, notaram-se lesões cutâneas vermelho-arroxeadas, intercaladas com áreas de palidez, exclusivamente na face ventromedial do antebraço direito, sem sinais sistêmicos sugestivos de reações alérgicas. O diagnóstico firmado foi de livedo reticular fisiológico. Houve esmaecimento total das lesões em cinco dias.

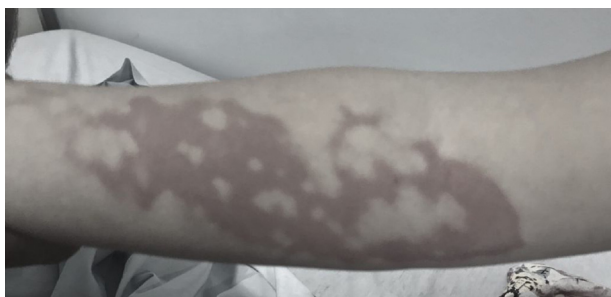**Conclusão:** O relato apresentado evidencia a necessidade de controle térmico de pacientes submetidos a anestésias, bem como registra manifestação de livedo reticular em consequência de hipotermia transoperatória.

© 2018 Sociedade Brasileira de Anestesiologia. Publicado por Elsevier Editora Ltda. Este é um artigo Open Access sob uma licença CC BY-NC-ND (<http://creativecommons.org/licenses/by-nc-nd/4.0/>).

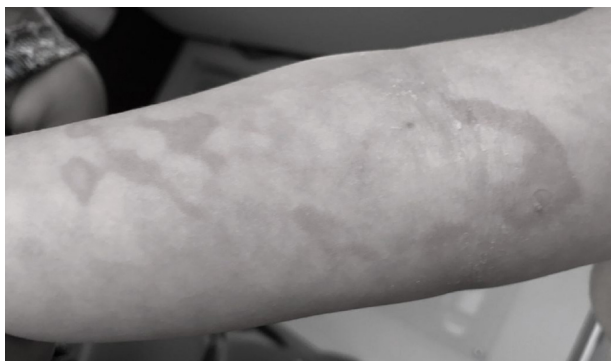
**Case report**

Five-year-old female patient, 26 kg, diagnosed with Down's syndrome (DS) at birth, scheduled for dental treatment, with a history of surgical closure of interatrial and inter-ventricular communication at four months of age without adverse events. No history of allergies. At physical examination, she presented with good general condition, was collaborative, eutrophic, ruddy, hydrated, euphonic, BP 85 × 50 mmHg, HR 90 bpm, normal pulmonary and cardiac auscultation, absence of signs suggestive of difficult airway. Complementary exams showed normal results. Cardiologic report informed absence of cardiovascular changes at the time. The patient with adequate fasting was taken to the operating room under an ambient temperature of 23 °C. Monitors: electrocardiography (ECG), pulse oximetry (SpO<sub>2</sub>), non-invasive blood pressure (NIBP), expired CO<sub>2</sub> fraction (EtCO<sub>2</sub>) and left axillary temperature (36 °C at the beginning of anesthesia). Inhalational induction of general anesthesia performed with a mixture of 100% O<sub>2</sub> and 6% sevoflurane from the vaporizer. After 8 min, venipuncture was performed on the back of the right hand followed by administration of fentanyl (25 μg) and atracurium (13 mg). Nasotracheal intubation was confirmed by EtCO<sub>2</sub>. Controlled mechanical ventilation age-adjusted parameters for an EtCO<sub>2</sub> between 35 and 45 mmHg. Intravenous hydration with Lactate Ringer's solution at room temperature and a rate of 10 mL.kg<sup>-1</sup> in the first hour and 5 mL.kg<sup>-1</sup> after-

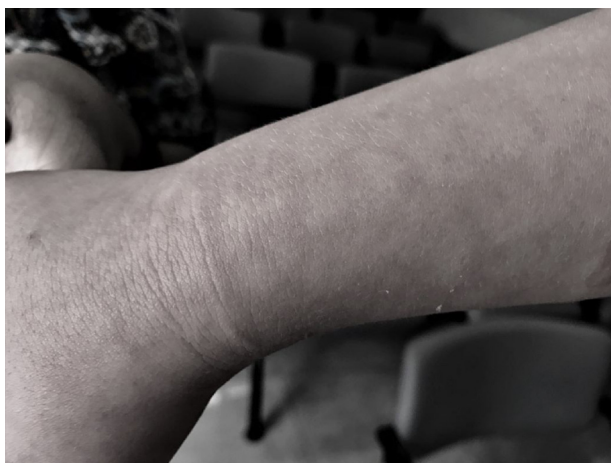ward. Prevention of hypothermia was performed by passive method using conventional blankets and lower limb wrapping with orthopedic cotton. Maintenance of the anesthetic plan was done with 2.5% sevoflurane from the vaporizer. After 30 min of the onset of anesthesia the patient's temperature in the left axillary region reached 34.5 °C. Due to the absence of active body heating equipment we provided for the patient's body to be in contact with heated 0.9% saline solution bottles wrapped in compresses and located under the blanket, between the thorax and arms extended to the side of the body, and in the inguinal regions. After 60 min, the body temperature reached 36 °C, when the heating means was withdrawn. At the end of the surgical procedure reversal of neuromuscular blockade was performed and the patient was extubated awake. The procedure lasted 150 min. When the wraps covering the patient were removed, red-purple lesions with irregular contours, permeated by areas with intense pallor located exclusively on the ventromedial aspect of the right forearm extended from the wrist to the antecubital fold (Fig. 1). At that moment the patient was awake without any painful complaints. The first diagnostic hypothesis was burns caused by some of the saline solution bottles heated above the desired level. After a better examination of the lesions and absence of pain complaint this diagnosis was excluded. The second diagnosis was based on an allergic reaction, but due to the absence of systemic manifestations and lesions being restricted to a limb this was also ruled out. The lesions



**Figure 1** Red-purplish lesion on the ventromedial aspect of the right forearm at the end of anesthesia.

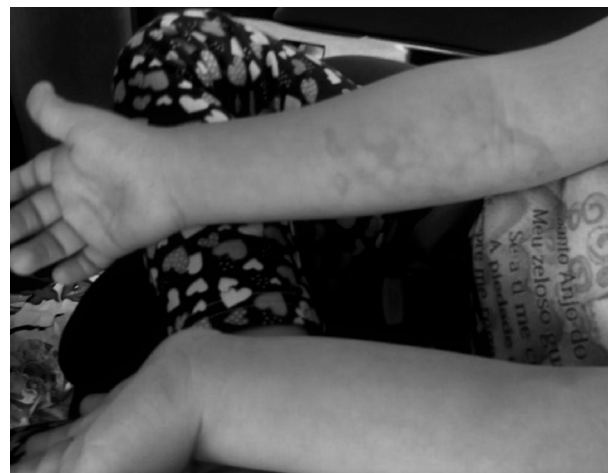

**Figure 2** Fading of the lesions on the ventromedial aspect of the right forearm and appearance of reticular pattern 12 h after hospital discharge.



**Figure 3** Lesions with reticular pattern on the dorsolateral forearm and right hand, 12 h after hospital discharge.

remained unchanged in the first 4 h and, due to the good general condition of the patient, she was discharged at that time. The return to the hospital was requested 12 h later. There was a fading of the most prominent lesions on the ventromedial aspect of the right forearm (Fig. 2), with the appearance of reticular lesions on the same topography and on the dorsal aspect of the right forearm, which reached the back of the right hand (Fig. 3). The patient maintained good general condition and no pain complaints. Once again, the absence of lesions in other topographies was confirmed (Fig. 4). The diagnosis of RL was then established, and explained to the parents that the cutaneous manifesta-



**Figure 4** Absence of lesions in the left forearm.

tion was secondary to the perioperative hypothermia. After that, the mother reported that the patient had already presented with sudden redness in the lower limbs when she was in an air-conditioned environment and with an intense sensation of cold, which disappeared about 1 h after being removed from the environment. This information corroborated the diagnosis of livedo reticularis (LR). Because the patient lived in another state and needed to return home, daily telephone contact was maintained. The patient recovered with a total disappearance of the lesions after five days. After two months, she received an indication for adenotonsillectomy and the parents asked for the same anesthesia team from the previous surgery because they already knew about the patient's condition. In this new procedure, care was taken not to switch on the air conditioner of the operating room prior to the prophylaxis of hypothermia using thermal blanket and heated intravenous hydration fluids at 39°C. The patient's axillary temperature remained between 36 and 36.5°C, and there was no cutaneous manifestation of LR.

## Discussion

Livedo reticularis (LR) is characterized by erythematous skin patches with transient or permanent reticular pattern. Physiological LR has a benign course; it is called *cutis marmorata* and is caused by cutaneous blood flow disorders in physiological situations, mainly body hypothermia. Primary LR also has a floating appearance and differs from physiological LR because it has no relation to hypothermia; whereas idiopathic LR presents a persistence condition. Its course can still be persistent and pathological, named LR *racemosa*, when it is invariably associated with systemic alterations, such as hematological, infectious, neurological, and neoplastic.<sup>1</sup> In physiological LR, cutaneous arteriolar vasospasm causes skin discoloration and may occur due to exposure to cold, by dilation of the venous plexus by autonomic dysfunction or by hypoxia itself induced by vasospasm.<sup>2</sup>

DS is the most frequent chromosomal disorder in live births, currently occurring in 1:700 births. Invariably, DS presents with several congenital, cardiac, and

gastrointestinal malformations, cleft palate, polydactyly, and cataract, often associated with each other. Despite the occurrence of major and minor malformations, DS patients are more likely to undergo surgical procedures than non-DS patients, which make it essential for anesthesiologists to be aware of the possible manifestations and peculiarities of these patients. Relevant concerns during anesthesia include cervical spine instability, occurrence of bradycardia, congenital heart disease, pulmonary hypertension, airway obstruction due to anatomical features, and muscular hypotonia.<sup>3</sup> DS children are resistant to dental caries, a fact justified by the neutralization of saliva which contains a higher concentration of sodium chloride and bicarbonate; however, periodontal disease is more frequent and favors early dental loss. In DS there may be impairment of intellectual abilities to varying degrees, which contributes to the non-cooperation of some patients with conventional sessions in the dental office, requiring general anesthesia for dental treatment.<sup>4</sup> The reported incidence of LR is up to 12.6% in DS patients and frequently related to congenital heart diseases, such as atrial (IAC) and ventricular septal communication (IVC) defects.<sup>5</sup> In the case reported, the patient had IAC and IVC at birth, corrected at four months of age. The occurrence of early hypothermia in this patient may suggest the presence of autonomic dysfunction that may lead to vasodilation associated with cutaneous arteriolar spasm, characterized in Fig. 1, with ischemic areas interspersed with congested areas, which allowed the differentiation of a possible contact burn with the heated bottles of saline solution; in that case, the area affected by heat should be continuous. It is also worth noting the differential diagnosis with allergic reactions excluded by the limitation of the lesions in a single limb and absence of cardiovascular and respiratory manifestations. The exclusive involvement of the right upper limb can be inferred by the venipuncture being located in the same limb, so the hydration fluid temperature lower than the body temperature would have caused a marked

decrease of temperature in this body segment. In general, the treatment of physiological LR is based on the global warming of the patient and follow-up of the lesions until their disappearance. The request for the same anesthesia team during the second procedure reveals the importance of developing a relationship between patients, relatives, and anesthesiologists.

In conclusion, this case report evidences the need for temperature monitoring and prevention of body hypothermia during anesthesia, and that the use of passive methods for hypothermia prophylaxis, considered as reliable by many professionals, may not be sufficient to prevent it. It also revealed the knowledge about the physiological LR, which patients are subjected to when undergoing surgical procedures and that despite the exuberant clinical characteristics, the orientation of the relatives regarding the benignity can provide tranquility regarding the LR.

### Conflicts of interest

The authors declare no conflicts of interest.

### References

1. Criado PR, Faillace C, Magalhães LS, et al. Livedo reticular: classificação, causas e diagnósticos diferenciais. *Acta Reumatol Port.* 2012;37:218–25.
2. Sajjan VV, Lunge S, Swamy MB, et al. Livedo reticularis: a review of the literature. *Indian Dermatol Online J.* 2015;6:315–21.
3. Lewanda AF, Matisoff A, Revenis M, et al. Preoperative evaluation and comprehensive risk assessment for children with Down syndrome. *Pediatr Anesth.* 2016;26:356–62.
4. Nirmala SVSG, Saikrishna D. Dental concerns of children with Down's syndrome – an overview. *J Pediatr Neonatal Care.* 2017;6:1–7.
5. Madan V, Williams J, Lear JT. Dermatological manifestations of Down's syndrome. *Clin Exp Dermatol.* 2006;31:623–9.