


Hepatozoon sp. gamonts as an accidental finding in synovial liquid from an injured maned wolf (*Chrysocyon brachyurus*) in southeastern Brazil

Gamontes de *Hepatozoon* sp. como achado acidental em líquido sinovial de lobo guará (*Chrysocyon brachyurus*) no sudeste do Brasil

Lívia Perles¹; Guilherme Henrique Fernandes Barranco¹; Isabela Maciel Soriano¹; Nathan da Rocha Neves Cruz²; Patrícia Jábali Bueno²; Áureo Evangelista Santana²; Rosângela Zacarias Machado¹; Karin Werther¹; Marcos Rogério André^{1*} 

¹ Departamento de Patologia Veterinária, Universidade Estadual Paulista Júlio de Mesquita Filho – UNESP, Jaboticabal, SP, Brasil

² Departamento de Clínica e Cirurgia Veterinária, Universidade Estadual Paulista Júlio de Mesquita Filho – UNESP, Jaboticabal, SP, Brasil

Received April 15, 2019

Accepted July 04, 2019

Abstract

A free-living, adult male maned wolf (*Chrysocyon brachyurus*) was referred to the Governador “Laudo Natel” – FCAV/Unesp veterinary hospital after being found with skin lesions and a fracture on the right pelvic limb, which had to be amputated due to compromised integrity. Around 20 days later, bilateral accentuated swollen on humerus-radius-ulna articulation was observed. The synovial liquid was drained and sent to the laboratory for synovial cytology with Rosenfeld staining that revealed predominantly degenerated neutrophils with karyolytic chromatin associated with intracellular inclusions suggestive of *Hepatozoon* sp. gametocytes. Blood and synovial liquid samples were submitted to molecular analysis, aiming to amplify the *Hepatozoon* spp. 18S rRNA gene fragment. Despite the positioning of the found *Hepatozoon* sequence together with *Hepatozoon canis* previously detected in domestic carnivores, the BLAST analysis showed only 98% identity with *H. canis*. To the best of the authors’ knowledge, this is the first time a *Hepatozoon* was detected in the synovial liquid by clinical pathology and molecular analyses.

Keywords: Hepatozoonosis, cytopathology, gametocytes, wild canids.

Resumo

Um lobo guará (*Chrysocyon brachyurus*) adulto, macho, de vida livre foi encaminhado para atendimento no hospital veterinário Governador “Laudo Natel” – FCAV/Unesp após ser encontrado com lesões de pele e fratura em membro pélvico direito, sendo amputado devido a comprometimento da integridade do membro. Aproximadamente 20 dias após a chegada ao hospital, foi notado acentuado aumento de volume bilateral em região de articulação úmero-rádio-ulnar. O líquido sinovial foi drenado e enviado para análise citológica com coloração de Rosenfeld, revelando a presença de neutrófilos degenerados com cromatina cariólítica associados a inclusões intracelulares sugestivas de gametócitos de *Hepatozoon* sp. Amostras de sangue e líquido sinovial foram submetidas a análises moleculares visando amplificar um fragmento do gene 18S rRNA de *Hepatozoon* spp. Apesar da sequência de *Hepatozoon* detectada se posicionar filogeneticamente no mesmo clado que *H. canis* previamente detectado em carnívoros domésticos, o resultado da análise do BLAST mostrou somente 98% de identidade com *H. canis*. De acordo com o conhecimento dos autores, esta é a primeira vez que *Hepatozoon* foi detectado no líquido sinovial por meio de patologia clínica e análises moleculares.

Palavras-chave: Hepatozoonose, citopatologia, gametócitos, canídeos selvagens.

*Corresponding author: Marcos Rogério André. Laboratório de Imunoparasitologia, Departamento de Patologia Veterinária, Faculdade de Ciências Agrárias e Veterinárias Júlio de Mesquita Filho – UNESP, Campus de Jaboticabal, Via de Acesso Prof. Paulo Donato Castellane, s/n, Zona Rural, CEP 14884-900, Jaboticabal, SP, Brasil. e-mail: marcosandre.fcav@gmail.com



Introduction

The maned wolf (*Chrysocyon brachyurus*) is known as the largest wild canid species from South America, occurring in Argentina, Bolivia, Brazil, Paraguay, Peru, and Uruguay (DIETZ, 1984, 1985; RUMIZ & SAINZ, 2002). Currently, the red list of the International Union for Conservation of Nature (IUCN) lists this species as “Near Threatened” (PAULA & DEMATTEO, 2015). Diseases are a potential threat for wildlife conservation, but studies on the occurrence of pathogens in maned wolves are scarce (ANDRÉ et al., 2010; CURI et al., 2012; SILVEIRA et al., 2016). Regarding the occurrence of tick-borne agents, fewer studies have been performed.

Hepatozoon spp. are apicomplexan parasites that infect a wide variety of hosts, being described in domestic and wild mammals, birds, reptiles, and amphibians (SMITH, 1996; RAMOS et al., 2015). Domestic and wild canids can be infected with at least two *Hepatozoon* species, *Hepatozoon canis* and *Hepatozoon americanum*, which present distinct clinical signs, pathology, biology, and genetic characteristics (O'DWYER et al., 2011). Although *Hepatozoon* sp. infections in free-living animals are usually subclinical (KOCAN et al., 2000; METZGER et al., 2008), some studies have shown the occurrence of the clinical disease associated with *H. americanum* in coyotes (*Canis latrans*) in the United States (KOCAN et al., 2000) and mortality of hyenas (*Crocuta crocuta*) in Tanzania associated with a *Hepatozoon* sp. genetically distinct from the *H. canis* (EAST et al., 2008). These agents may play a role as potential opportunistic pathogens in immunocompromised animals or with concomitant diseases (BANETH et al., 2001; KUBO et al., 2006). Although several drugs have been proposed for treating the infection, there is no parasitological cure and, currently, no established treatment protocol for treating *H. canis* infection (SAKUMA et al., 2009). There are studies in the literature on treatments with either imidocarb dipropionate only or imidocarb dipropionate associated with doxycycline, toltrazuril, toltrazuril/emodepside, and clindamycin, but none of them proved to be efficient (SAKUMA et al., 2009; SASANELLI et al., 2010; PASA et al., 2011; TOMMASI et al., 2014).

Hepatozoon sp. was detected in the blood of one maned wolf by 18Sr RNA-based PCR for the first time in a Zoo in Sorocaba, southeastern Brazil (ANDRÉ et al., 2010). Interestingly, the found sequence clustered with other sequences detected in wild canids and felids, apart from the *H. canis* and *H. americanum* detected in domestic/wild canids (ANDRÉ et al., 2010). Infection by *Hepatozoon* sp. was also molecularly detected in a free-living, adult female maned wolf in Minas Gerais, southeastern Brazil. In this case, the found 18SrRNA sequence showed 98% identity to *H. americanum* (SILVEIRA et al., 2016). The present work aims to describe the clinical and laboratory findings of a maned wolf naturally infected by *Hepatozoon* sp. that was treated at a veterinary hospital in southeastern Brazil.

Material and Methods

Clinical history

An intact adult male maned wolf (*Chrysocyon brachyurus*), weighting 17kg was referred to the Wildlife Medicine Service at the Veterinary Hospital of the Universidade Estadual “Julio de Mesquita Filho” (UNESP) (Jaboticabal, São Paulo, Brazil) after being found injured near the municipality of Barretos (Sao Paulo, southeastern Brazil). The patient was sedated with Ketamine (8 mg/kg, IM) and Midazolam (0.2 mg/kg, IM) for the clinical procedures. The clinical examination indicated pale mucous (oral and eyes), 163 beats/min heart rate, 36 breaths/min respiratory rate, 37.2°C rectal temperature, 3s capillary refill time (CRT), and dehydration estimated in 8% while following complementary laboratory analysis showed 87 mg/dL glucose. Additionally, the right pelvic limb showed a severe bone and muscle damage compromising limb functionality and three wounds were found on the left pelvic limb. Even though a light tick infestation was observed, they were not sampled.

It was decided for the amputation of the right pelvic limb due to compromised limb integrity. One month after the procedure, it was noticed a swollen on both thoracic limbs near the humerus-radius-ulna articulation. The animal was sedated for physical examination, followed by a trichotomy of both thoracic limbs before synovial liquid sampling performed with a 0.8x25mm needle and 20 mL syringe to collect 50 mL and 22 mL aliquots from the right and left limbs, respectively. Liquid smears were fixed with methanol, stained with Rosenfeld and stored for molecular analyses. Blood smears were also prepared and stained with Fast Panoptic method (Laborclin®). The synovial liquid smear was entirely examined, including the feathered and lateral edges, readable and thick areas, under 40x objective. For blood smear analysis, the smear was first examined at the feathered edge for differential leukocyte count under 40x objective, and then scanned for hemoparasites at the feathered edge and monolayer under 100x objective. Additionally, at the day of synovial liquid sampling, the blood sample was also submitted to buffy coat smear analysis. After draining the synovial liquid, the animal was kept with a compressive bandage on both thoracic limbs medicated with meloxicam (0.2mg/kg, IM, SID, for 3 days), nutritional conditions were improved and the cage was modified to shorten the decubitus period after the amputation procedure. Hematological analyses were performed during the entire hospital care.

DNA extraction and molecular analyses

DNA was extracted from 200 µL whole blood with EDTA and from a 200 µL synovial liquid using the DNeasy Blood & Tissue Kit, according to manufacturer instructions. The 18SrRNA of *Hepatozoon* sp. was amplified based on the PCR protocol described by Ujvari et al. (2004) (targeting a 600 bp fragment). *Hepatozoon* sp. DNA obtained from a naturally infected *Leptodactylus latrans* was used as positive control (accession number MK503643). The PCR amplicon obtained from synovial liquid was purified using the Silica Bead DNA gel extraction kit

(Thermo Fisher Scientific®, Waltham, MA, USA). Sequencing was carried out using the BigDye® Terminator v3.1 Cycle Sequencing Kit (Thermo Fisher Scientific®, Waltham, MA, USA) and ABI PRISM 310DNA Analyzer (Applied Biosystems®, Foster City, CA, EUA) (SANGER et al., 1977). Electropherogram quality and a consensus sequence were obtained through analysis of the sense and antisense sequence using the Phred Phrap software (EWING & GREEN, 1998). The identity values were assessed by BLASTn tool (using default parameters), available in the NCBI GenBank database (ALTSCHUL et al., 1990). Sequences deposited in the GenBank used for phylogenetic inferences were selected from BLAST results and from other studies performed in Brazil and in other countries. Maximum likelihood tree inference was performed with IQ-TREE software using TPM2+F+G evolutionary model (TRIFINOPOULOS et al., 2016). The phylogenetic tree edition and rooting were performed using the Treegraph 2.0 beta software (STOVER & MULLER, 2010). The blood samples were also tested for the presence of DNA from other hemoparasites such as *Babesia/Rangelia/Theileria* targeting the 18SrRNA gene (JEFFERIES et al., 2007), and *Mycoplasma* sp. (MAGGI et al., 2013) and Anaplasmataceae agents (INOKUMA et al., 2000) targeting the 16S rRNA gene.

Results

Blood and synovial liquid smears

No gamont suggestive of *Hepatozoon* spp. infection was observed in the blood smears. The pale red synovial liquid had a low viscosity while the cytology revealed the predominance of degenerate neutrophils with karyolytic chromatin associated with intracellular inclusions suggestive of *Hepatozoon* sp. (Figure 1). Additionally, pyogranulomatous inflammation and red blood cells (hemarthrosis) with loss of windrowing, which reflected the low viscosity of the fluid, were also observed.

DNA extraction and molecular analyses

Both blood and synovial liquid were positive for PCR targeting *Hepatozoon* sp.-18S rRNA. The 18S rRNA sequence detected in synovial liquid was deposited in the GenBank (MK424119) while BLAST results showed 98% identity with *H. canis* sequences detected in wild and domestic canids in Brazil and other countries. The phylogenetic inference, estimated by Maximum Likelihood, clustered sequences in six branches: i.) the first group consisted of *H. canis* sequences detected in domestic carnivores and the maned wolf of this study; ii.) the second, *H. canis* sequences detected in domestic and wild canids; iii.) the third, *H. procyonis*, detected in coatis (*Nasua nasua*); iv.) *H. felis* and *Hepatozoon* spp. detected in domestic and wild felids; v.) *H. americanum* and *Hepatozoon* spp. detected in domestic and wild canids; vi.) *Hepatozoon* sp. detected in rodents and reptiles (Figure 2). The clades showed considerable statistical support. *Haemogregarina* spp. sequences were used as outgroups.

The maned wolf was negative for piroplasmids, hemoplasmas, and Anaplasmataceae agents according to the results of the PCR assays.

Discussion

Infection caused by *H. canis* may be often a subclinical disease, usually associated with low parasitemia, but in some cases, *H. canis* infection can lead to severe disease that includes muscle lesions, anorexia, weight loss, pale mucous membranes and other clinical signs (BANETH & WEIGLER, 1997; PALUDO et al., 2005). Animals with severe disease symptoms have been shown to have extreme neutrophilia and high levels of parasitemia (BANETH; SHKAP, 2003). *H. canis* were detected in three Brazilian dogs with persistent parasitemia, causing muscle degeneration and atrophy, and degenerating/regenerating myofibers, similar to the muscle degeneration caused by *H. americanum* (PALUDO et al., 2005). Although no gametocyte was observed in the peripheral blood

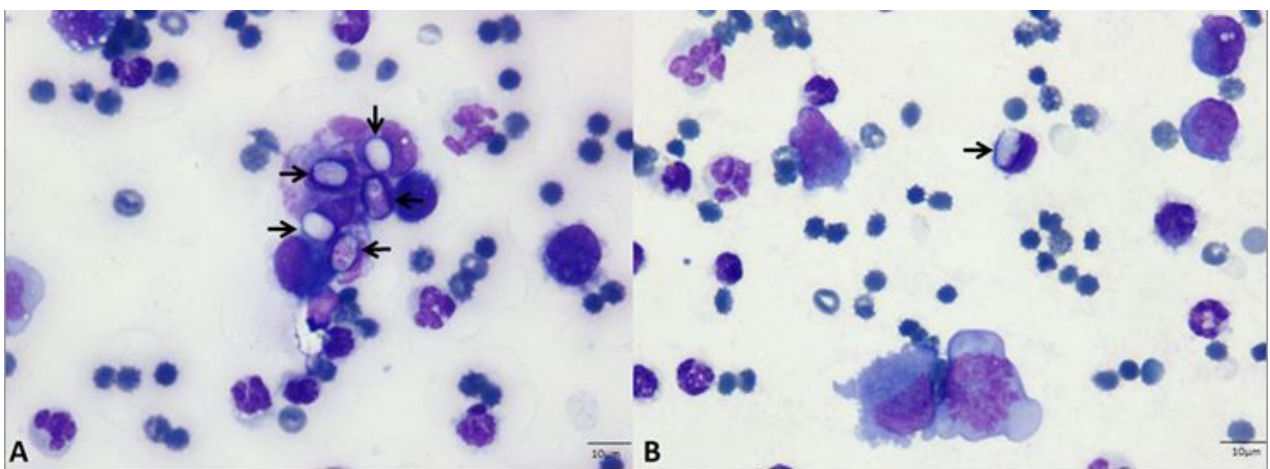


Figure 1. Synovial liquid smear stained with Rosenfeld (100x obj.). (A) Degenerate neutrophils with karyolytic chromatin associated with intracellular inclusions suggestive of *Hepatozoon* sp. gametocytes (arrow); (B) Pyogranulomatous inflammation, red blood cells (hemarthrosis) with loss of windrowing and intracellular inclusions suggestive of *Hepatozoon* sp. gametocytes (arrow).

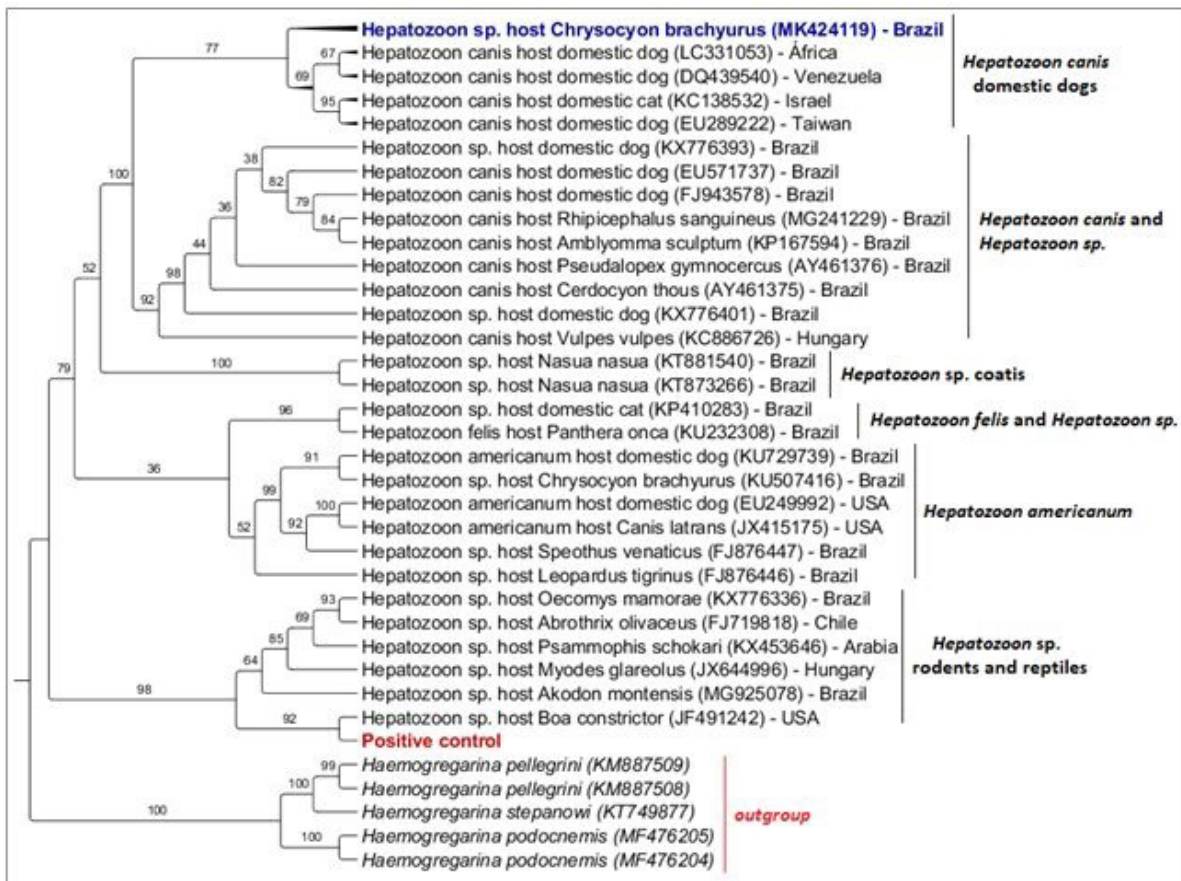


Figure 2. Phylogenetic tree based on the 600 bp fragment (UJVARI et al., 2004) of *Hepatozoon* spp. 18S rRNA sequences, using the Maximum likelihood inference (ML) method and TPM2+F+G evolutionary model. Numbers at nodes correspond to bootstrap. Accession numbers are indicated in the sequences. The sequence of *Hepatozoon* spp. detected in the present study is highlighted in blue. The positive control is highlighted in red.

smears, the maned wolf from this study presented neutrophilia with toxic granules, which probably resulted from the infected skin lesions and limb injury, with no relation with *Hepatozoon* infection. After 59 days, the animal did not present leukocytosis anymore, which indicated that the neutrophilia was associated with bacterial infection, which was resolved after antibiotic therapy. At the day of discharge from hospital (3 months after the entrance of the animal at the Veterinary Hospital), the animal was still positive for *Hepatozoon* spp. by PCR, which shows that the neutrophilia was not associated with *Hepatozoon* infection.

The swollen on both thoracic limbs, near the humerus-radius-ulna articulation, allowed the detection of *Hepatozoon* gamonts in synovial liquid smears. In fact, the observed swollen might have been the result of an extensive period of decubitus that the animal showed after the amputation procedure. Results of synovial liquid cytology indicated inflammation, which may have resulted in migration of leukocytes to the region. It is most likely that the migration of leukocytes to humerus-radius-ulna articulation generated an increase of the presence of neutrophils in the area, which in association with immunosuppression due to anesthesia/hospitalization procedures, allowed the detection of

Hepatozoon gamonts. It is known that immunosuppression caused by concomitant infections or immunosuppressive medications may influence the pathogenesis of new infection by *H. canis* or reactivate an existing infection (BANETH et al., 2001).

Unlike other tick-borne diseases, hepatozoonosis is transmitted by ingestion of ticks by the intermediary host (BANETH & SHKAP, 2003). In tropical and subtropical regions, including Brazil and the United States, studies showed that *H. canis* is transmitted by *Amblyomma ovale* ticks, *Haemaphysalis longicornis*, *Haemaphysalis flava*, and *Rhipicephalus sanguineus* sensu lato (MURATA et al., 1995; FORLANO et al., 2005, 2007; RUBINI et al., 2009). In Brazil, the participation of *R. sanguineus* s.l. in the transmission of *H. canis* should be better investigated (GOMES et al., 2016). The maned wolf from this report had a light infestation of ticks, which, unfortunately, were not sampled. To understand better the transmission of hepatozoonosis and other hemoparasites, ectoparasites should always be sampled and identified, and molecular analyses should be performed to identify possible pathogens.

Studies in the literature have reported that *H. canis* has been commonly detected in domestic dogs from all Brazilian regions (RUBINI et al., 2008; SPOLIDORIO et al., 2009; RAMOS et al.,

2010, 2015; SOUSA et al., 2017). *Hepatozoon* phylogenetically related to *H. americanum* has been recently described in domestic dogs in Belém, northern Brazil (GOMES et al., 2016), while both *Hepatozoon* species have been detected in wild canids from Brazil. While *Hepatozoon* sp. related to *H. americanum* has been detected in maned wolf and crab-eating fox (*Cerdocyon thous*) (CRIADO-FORNELIO et al., 2006; ANDRÉ et al., 2010; SOUSA et al., 2017), *H. canis* was detected in *Cerdocyon thous* and Pampas fox (*Lycalopex gymnocercus*) (CRIADO-FORNELIO et al., 2006; SILVA et al., 2018). Additionally, a possible new *Hepatozoon* species that clustered separately from *H. canis* and *H. americanum* based on 18S rRNA phylogenetic inference has been detected in maned wolf, bush dog (*Speothus venaticus*) and hoary fox (*Pseudalopex vetulus*) maintained in captivity in Brazil (ANDRÉ et al., 2010). In this study, the molecular and phylogenetic analyses of the *Hepatozoon*-18SrRNA sequence found in the synovial liquid from the maned wolf clustered with *H. canis* sequences detected only in domestic carnivores. The increased contact between wild and domestic canids in disturbed environments may facilitate pathogen exchanges, constituting one of the main threats against the maned wolf populations (PAULA et al., 2013; OROZCO et al., 2013). The animal evaluated in this report was found on a road, near a peri-urban area, and its presence in such an area may have facilitated contact with domestic animals and infection by *H. canis*. Although clustering with *H. canis* sequences, the amplified sequences showed only 98% of identity with *H. canis* by BLAST analysis, which may suggest that the maned wolf was infected with another closely related *Hepatozoon* species. Considering that the 18S rDNA gene has been the only molecular marker used for phylogenetic analyses of *Hepatozoon* spp. so far, problems for discriminating closely related species might occur due to its high degree of conservation (MORRISON et al., 2004). Recently, the complete genome of *H. canis* was sequenced, which may allow the use of new target genes, aiming at achieving better discrimination of *Hepatozoon* species (LÉVEILLÉ et al., 2019).

The *Hepatozoon* sp. epidemiology in wild canids in Brazil has not been fully elucidated yet. Although not producing the clinical disease, Brazilian wild canids apparently have subclinical canine hepatozoonosis, which may be aggravated when associated with other parasites. For instance, Silva et al. (2018) detected co-infection between *Rangelia vitalii* and *H. canis* in a free-living *L. gymnocercus* from the state of Santa Catarina, southern Brazil. Quadros et al. (2015) also reported the co-infection by *R. vitalii*, *H. canis*, and *Capillaria hepatica* in an *L. gymnocercus* specimen, which developed a fatal illness, in the state of Santa Catarina. In Minas Gerais, southeastern Brazil, Silveira et al. (2016) reported the co-infection by *R. vitalii*, *Hepatozoon* sp., *Leishmania* sp., *Entamoeba* spp. and intestinal helminths in a maned wolf. In the present case report, co-infections by piroplasmids, hemoplasmas, and Anaplasmataceae agents were not found.

Conclusion

To the best of authors' knowledge, this is the first report of *Hepatozoon* sp. gametocytes in synovial liquid of a maned wolf. Although clustering with *H. canis* previously detected in domestic

carnivores in phylogenetic analyses, BLAST results may indicate that the maned wolf was infected with another closely related *Hepatozoon* species. Keeping in mind that an increase contact between wild and domestic animals may facilitate pathogen exchange, special attention should be given for vector-borne agents in endangered wild carnivores maintained in captivity.

Acknowledgements

We are thankful to “Fundação de Amparo à Pesquisa do Estado de São Paulo” (FAPESP) for the financial support (Process #2018/02753-0) and “Conselho Nacional de Desenvolvimento Científico e Tecnológico” (CNPq – Research Productivity Scholarship - Process number 302420/2017-7) for Researcher Fellowship delivered to MRA.

References

- Altschul SF, Gish W, Miller W, Myers EW, Lipman DJ. Basic local alignment search tool. *J Mol Biol* 1990; 215(3): 403-410. [http://dx.doi.org/10.1016/S0022-2836\(05\)80360-2](http://dx.doi.org/10.1016/S0022-2836(05)80360-2). PMID:2231712.
- André MR, Adania CH, Teixeira RHF, Vargas GH, Falcade M, Sousa L, et al. Molecular detection of *Hepatozoon* spp. in Brazilian and exotic wild carnivores. *Vet Parasitol* 2010; 173(1-2): 134-138. <http://dx.doi.org/10.1016/j.vetpar.2010.06.014>. PMID:20630658.
- Baneth G, Samish M, Alekseev E, Aroch I, Shkap V. Transmission of *Hepatozoon canis* to dogs by naturally-fed or percutaneously-injected *Rhipicephalus sanguineus* ticks. *J Parasitol* 2001; 87(3): 606-611. [http://dx.doi.org/10.1645/0022-3395\(2001\)087\[0606:TOHCTD\]2.0.CO;2](http://dx.doi.org/10.1645/0022-3395(2001)087[0606:TOHCTD]2.0.CO;2). PMID:11426725.
- Baneth G, Shkap V. Monozoic cysts of *Hepatozoon canis*. *J Parasitol* 2003; 89(2): 379-381. [http://dx.doi.org/10.1645/0022-3395\(2003\)089\[0379:MC OHC\]2.0.CO;2](http://dx.doi.org/10.1645/0022-3395(2003)089[0379:MC OHC]2.0.CO;2). PMID:12760658.
- Baneth G, Weigler B. Retrospective case-control study of hepatozoonosis in dogs in Israel. *J Vet Intern Med* 1997; 11(6): 365-370. <http://dx.doi.org/10.1111/j.1939-1676.1997.tb00482.x>. PMID:9470163.
- Criado-Fornelio A, Ruas JL, Casado N, Farias NA, Soares MP, Müller G, et al. New molecular data on mammalian *Hepatozoon* species (Apicomplexa: Adeleorina) from Brazil and Spain. *J Parasitol* 2006; 92(1): 93-99. <http://dx.doi.org/10.1645/GE-464R.1>. PMID:16629322.
- Curi NHA, Coelho CM, Campo MCM, Magni EM, Sábato MA, Araújo AS, et al. Pathogens of Wild Maned Wolves (*Chrysocyon brachyurus*) in Brazil. *J Wildl Dis* 2012; 48(4): 1052-1056. <http://dx.doi.org/10.7589/2011-10-304>. PMID:23060508.
- Dietz JM. *Ecology and social organization of maned wolf (Chrysocyon brachyurus)*. Washington: Smithsonian Institution Press; 1984. (Smithsonian Contributions to Zoology; no. 392). <https://doi.org/10.5479/si.00810282.392>.
- Dietz JM. *Chrysocyon brachyurus*. *Mamm Species* 1985; 234(234): 1-4. <http://dx.doi.org/10.2307/13503796>.
- East ML, Wibbelt G, Lieckfeldt D, Ludwig A, Goller K, Wilhelm K, et al. A *Hepatozoon* species genetically distinct from *H. canis* infecting spotted hyenas in the Serengeti ecosystem, Tanzania. *J Wildl Dis* 2008; 44(1): 45-52. <http://dx.doi.org/10.7589/0090-3558-44.1.45>. PMID:18263820.

- Ewing B, Green P. Base-calling of automated sequencer traces using phred. II. Error probabilities. *Genome Res* 1998; 8(3): 186-194. <http://dx.doi.org/10.1101/gr.8.3.186>. PMID:9521922.
- Forlano M, Scofield A, Elisei C, Fernandes KR, Ewing SA, Massard CL. Diagnosis of *Hepatozoon* spp. in *Amblyomma ovale* and its experimental transmission in domestic dogs in Brazil. *Vet Parasitol* 2005; 134(1-2): 1-7. <http://dx.doi.org/10.1016/j.vetpar.2005.05.066>. PMID:16081219.
- Forlano M, Teixeira KRS, Scofield A, Elisei C, Yotoko KS, Fernandes KR, et al. Molecular characterization of *Hepatozoon* sp. from Brazilian dogs and its phylogenetic relationship with other *Hepatozoon* spp. *Vet Parasitol* 2007; 145(1-2): 21-30. <http://dx.doi.org/10.1016/j.vetpar.2006.10.023>. PMID:17134837.
- Gomes LA, Moraes PHG, Nascimento LCS, O'Dwyer LH, Nunes MRT, Rossi ARP, et al. Molecular analysis reveals the diversity of *Hepatozoon* species naturally infecting domestic dogs in a northern region of Brazil. *Ticks Tick Borne Dis* 2016; 7(6): 1061-1066. <http://dx.doi.org/10.1016/j.ttbdis.2016.09.008>. PMID:27665264.
- Inokuma H, Raoult D, Brouqui P. Detection of *Ehrlichia platys* DNA in brown dog ticks (*Rhipicephalus sanguineus*) in Okinawa Island, Japan. *J Clin Microbiol* 2000; 38(11): 4219-4221. PMID:11060094.
- Jefferies R, Ryan UM, Irwin PJ. PCR-RFLP for the detection and differentiation of the canine piroplasm species and its use with filter paper-based technologies. *Vet Parasitol* 2007; 144(1-2): 20-27. <http://dx.doi.org/10.1016/j.vetpar.2006.09.022>. PMID:17127005.
- Kocan AA, Cummings CA, Panciera RJ, Mathew JS, Ewing SA, Barker RW. Naturally occurring and experimentally transmitted *Hepatozoon americanum* in coyotes from Oklahoma. *J Wildl Dis* 2000; 36(1): 149-153. <http://dx.doi.org/10.7589/0090-3558-36.1.149>. PMID:10682757.
- Kubo M, Miyoshi N, Yasuda N. Hepatozoonosis in two species of Japanese wild cat. *J Vet Med Sci* 2006; 68(8): 833-837. <http://dx.doi.org/10.1292/jvms.68.833>. PMID:16953084.
- Léveillé AN, Baneth G, Barta JR. Next generation sequencing from *Hepatozoon canis* (Apicomplexa: Coccidia: Adeleorina): complete apicoplast genome and multiple mitochondrion-associated sequences. *Int J Parasitol* 2019; 49(5): 375-387. <http://dx.doi.org/10.1016/j.ijpara.2018.12.001>. PMID:30790556.
- Maggi RG, Mascarelli PE, Havenga LN, Naidoo V, Breitschwerdt EB. Co-infection with *Anaplasma platys*, *Bartonella henselae* and *Candidatus Mycoplasma haematoparvum* in a veterinarian. *Parasit Vectors* 2013; 6(1): 103. <http://dx.doi.org/10.1186/1756-3305-6-103>. PMID:23587235.
- Metzger B, Paduan KS, Rubini AS, Oliveira TG, Pereira C, O'Dwyer LH. The first report of *Hepatozoon* sp. (Apicomplexa: Hepatozoidae) in neotropical felids from Brazil. *Vet Parasitol* 2008; 152(1-2): 28-33. <http://dx.doi.org/10.1016/j.vetpar.2007.12.006>. PMID:18243562.
- Morrison DA, Bornstein S, Thebo P, Wernery U, Kinne J, Mattsson JG. The current status of the small subunit rRNA phylogeny of the coccidia (Sporozoa). *Int J Parasitol* 2004; 34(4): 501-514. <http://dx.doi.org/10.1016/j.ijpara.2003.11.006>. PMID:15013740.
- Murata T, Inoue M, Taura Y, Nakama S, Abe H, Fujisaki K. Detection of *Hepatozoon canis* oocyst from ticks collected from the infected dogs. *J Vet Med Sci* 1995; 57(1): 111-112. <http://dx.doi.org/10.1292/jvms.57.111>. PMID:7756400.
- O'Dwyer LH, Saito ME, Hasegawa MY, Kohayagawa A. Brazilian canine hepatozoonosis. *Rev Bras Parasitol Vet* 2011; 20(3): 181-193. <http://dx.doi.org/10.1590/S1984-29612011000300002>. PMID:21961746.
- Orozco M, Ceballos LA, Pino MC, Gurtler RE. Local threats and potential infectious hazards to maned wolves (*Chrysocyon brachyurus*) in the southeastern Argentine Chaco. *Mammalia* 2013; 78(3): 339-349. <http://dx.doi.org/10.1515/mammalia-2013-0067>.
- Paludo GR, Friedmann H, Dell'Porto A, Macintire DK, Whitley EM, Boudreaux MK, et al. *Hepatozoon* spp.: pathological and partial 18S rRNA sequence analysis from three Brazilian dogs. *Parasitol Res* 2005; 97(2): 167-170. <http://dx.doi.org/10.1007/s00436-005-1419-2>. PMID:15988602.
- Pasa S, Voyvoda H, Karagenc T, Atasoy A, Gazyagci S. Failure of combination therapy with imidocarb dipropionate and toltrazuril to clear *Hepatozoon canis* infection in dogs. *Parasitol Res* 2011; 109(3): 919-926. <http://dx.doi.org/10.1007/s00436-011-2334-3>. PMID:21472405.
- Paula RC, DeMatteo K. *Chrysocyon brachyurus*, *Maned Wolf*. USA: International Union for Conservation of Nature and Natural Resources; 2015. The IUCN Red List of Threatened Species. <http://dx.doi.org/10.2305/IUCN.UK.2015-4.RLTS.T4819A82316878.en>
- Paula RC, Rodrigues FHG, Queirolo D, Jorge RPS, Lemos FG, Almeida Rodrigues L. Avaliação do estado de conservação do Lobo-guará *Chrysocyon brachyurus* (Illiger, 1815) no Brasil. *Biodiver Bras* 2013; 3: 146-159.
- Quadros RM, Soares JE, Xavier JS, Pilati C, Costa JL, Miotto BA, et al. Natural Infection of the Wild Canid *Lycalopex gymnocercus* by the Protozoan *Rangelia vitalii*, the Agent of Canine Rangeliosis. *J Wildl Dis* 2015; 51(3): 787-789. <http://dx.doi.org/10.7589/2014-08-194>. PMID:25932667.
- Ramos CAN, Babo-Terra VJ, Pedrosa TC, Souza AF Fo, Araújo FR, Cleveland HPK. Molecular identification of *Hepatozoon canis* in dogs from Campo Grande, Mato Grosso do Sul, Brazil. *Rev Bras Parasitol Vet* 2015; 24(2): 247-250. <http://dx.doi.org/10.1590/S1984-29612015019>. PMID:26154969.
- Ramos R, Ramos C, Araújo F, Oliveira R, Souza I, Pimentel D, et al. Molecular survey and genetic characterization of tick-borne pathogens in dogs in metropolitan Recife (north-eastern Brazil). *Parasitol Res* 2010; 107(5): 1115-1120. <http://dx.doi.org/10.1007/s00436-010-1979-7>. PMID:20680344.
- Rubini AS, Paduan KS, Martins TF, Labruna MB, O'Dwyer LH. Acquisition and transmission of *Hepatozoon canis* (Apicomplexa: Hepatozoidae) by the tick *Amblyomma ovale* (Acari: Ixodidae). *Vet Parasitol* 2009; 164(2-4): 324-327. <http://dx.doi.org/10.1016/j.vetpar.2009.05.009>. PMID:19501969.
- Rubini AS, Paduan KS, Von Ah Lopes V, O'Dwyer LH. Molecular and parasitological survey of *Hepatozoon canis* (Apicomplexa: Hepatozoidae) in dogs from rural area of Sao Paulo state, Brazil. *Parasitol Res* 2008; 102(5): 895-899. <http://dx.doi.org/10.1007/s00436-007-0846-7>. PMID:18188597.
- Rumiz D, Sainz LA. Estimación del hábitat útil y la abundancia potencial del lobo de crin o borochi (*Chrysocyon brachyurus*) em Huanchaca, Santa Cruz – Bolivia. *Rev Bol Ecol* 2002; 11: 3-16.
- Sakuma M, Nakahara Y, Suzuki H, Uchimura M, Sekiya Z, Setoguchi A, et al. A case report: a dog with acute onset of *Hepatozoon canis* infection. *J Vet Med Sci* 2009; 71(6): 835-838. <http://dx.doi.org/10.1292/jvms.71.835>. PMID:19578300.
- Sanger F, Nicklen S, Coulson AR. DNA sequencing with chain-terminating inhibitors. *Proc Natl Acad Sci USA* 1977; 74(12): 5463-5467. <http://dx.doi.org/10.1073/pnas.74.12.5463>. PMID:271968.
- Sasanelli M, Paradies P, Greco B, Eyal O, Zaza V, Baneth G. Failure of imidocarb dipropionate to eliminate *Hepatozoon canis* in naturally infected dogs based on parasitological and molecular evaluation methods. *Vet Parasitol* 2010; 171(3-4): 194-199. <http://dx.doi.org/10.1016/j.vetpar.2010.03.042>. PMID:20444549.

- Silva MRL, Mattoso CRS, Costa A, Saito ME, Tchaicka L, O'Dwyer LH. *Rangelia vitalii* and *Hepatozoon canis* coinfection in pampas fox *Lycalopex gymnocercus* from Santa Catarina State, Brazil. *Rev Bras Parasitol Vet* 2018; 27(3): 377-383. <http://dx.doi.org/10.1590/s1984-296120180018>. PMID:29846457.
- Silveira JA, D'Elia ML, Oliveira Avelar I, Almeida LR, Santos HÁ, Soares DFM, et al. *Rangelia vitalii* in a free-ranging maned wolf (*Chrysocyon brachyurus*) and co-infections. *Int J Parasitol Parasites Wildl* 2016; 5(3): 280-285. <http://dx.doi.org/10.1016/j.ijppaw.2016.09.003>. PMID:27761403.
- Smith TG. The genus *Hepatozoon* (Apicomplexa: adeleina). *J Parasitol* 1996; 82(4): 565-585. <http://dx.doi.org/10.2307/3283781>. PMID:8691364.
- Sousa KCM, Fernandes MP, Herrera HM, Benevenuto JL, Santos FM, Rocha FL, et al. Molecular detection of *Hepatozoon* spp. in domestic dogs and wild mammals in southern Pantanal, Brazil with implications in the transmission route. *Vet Parasitol* 2017; 237: 37-46. <http://dx.doi.org/10.1016/j.vetpar.2017.02.023>. PMID:28291601.
- Spolidorio MG, Labruna MB, Zago AM, Donatle DM, Caliani KM, Yoshinari NH. *Hepatozoon canis* infecting dogs in the state of Espírito Santo, southeastern Brazil. *Vet Parasitol* 2009; 163(4): 357-361. <http://dx.doi.org/10.1016/j.vetpar.2009.05.002>. PMID:19482427.
- Stover BC, Muller KF. TreeGraph 2: combining and visualizing evidence from different phylogenetic analyses. *BMC Bioinformatics* 2010; 11(1): 7. <http://dx.doi.org/10.1186/1471-2105-11-7>. PMID:20051126.
- Tommasi AS, Giannelli A, Caprariis D, Ramos RAN, di Paola G, Crescenzo G, et al. Failure of imidocarb dipropionate and toltrazuril/emodepside plus clindamycin in treating *Hepatozoon canis* infection. *Vet Parasitol* 2014; 200(3-4): 242-245. <http://dx.doi.org/10.1016/j.vetpar.2013.12.013>. PMID:24439769.
- Trifinopoulos J, Nguyen LT, von Haeseler A, Minh BQ. W-IQ-TREE: a fast online phylogenetic tool for maximum likelihood analysis. *Nucleic Acids Res* 2016; 44(W1): W232-235. <http://dx.doi.org/10.1093/nar/gkw256>. PMID:27084950.
- Ujvari B, Madsen T, Olsson M. High prevalence of *Hepatozoon* spp. (Apicomplexa, Hepatozoidae) infection in water pythons (*Liasis fuscus*) from tropical Australia. *J Parasitol* 2004; 90(3): 670-672. <http://dx.doi.org/10.1645/GE-204R>. PMID:15270125.