

Influence of the banded Herbst appliance on dental changes in mixed dentition

Luana Paz Sampaio*, Dirceu Barnabé Raveli**, Ary dos Santos-Pinto**,
Denise Rocha Goes Landázuri***, Savana de Alencar Maia****

Abstract

Objective: This prospective clinical study was conducted with the purpose of evaluating the influence of the banded Herbst appliance on dental changes during the early treatment of Class II malocclusion. **Method:** The sample consisted of 15 prepubertal subjects (12 boys and 3 girls, initial age: 9 years and 6 months) who were treated with the Herbst appliance. Treatment effects were compared with those of a Class II Division 1 group of 15 subjects (8 boys and 7 girls, mean initial age 9 years and 1 month), not treated orthodontically. Statistical analysis was performed using Student t-test with 5% significance level. **Results:** The results showed that treatment with the banded Herbst appliance in the mixed dentition stage tended to upright maxillary incisors (mean: 4.14°). The maxillary molars were distalized and intruded significantly (mean 2.65 mm and 1.24 mm, respectively), the lower incisors slightly protruded anteriorly (mean 1.64 mm) and the molars showed no significant changes in the horizontal and vertical directions. Furthermore, significant improvements were noted in overbite (1.26 mm), overjet (4.8 mm) and molar relationship (12.08 mm). **Conclusions:** Changes in the upper dental arch were found to be greater than changes in the lower arch. Furthermore, mandibular anchorage loss was reduced due to the anchorage system used in the study.

Keywords: Herbst appliance. Anchorage system. Mixed dentition. Orthodontics. Cephalometry.

How to cite this article: Sampaio LP, Raveli DB, Santos-Pinto A, Landázuri DRG, Maia SA. Influence of the banded Herbst appliance on dental changes in mixed dentition. *Dental Press J Orthod.* 2012 Jan-Feb;17(1):44.e1-10.

» The author reports no commercial, proprietary, or financial interest in the products or companies described in this article.

* PhD in Orthodontics, Araraquara Dental School (FOAr-UNESP). Assistant professor, specialization course in Orthodontics, GESTOS/FA-MOSP, Araraquara.

** Full professor, FOAr-UNESP. Associate professor in Orthodontics, FOAr-UNESP.

*** MSc and PhD student in Orthodontics, FOAr-UNESP.

**** MSc and PhD student in Orthodontics, FOAr-UNESP. Professor, Amazonas State University.

INTRODUCTION

Class II malocclusion is a maxillomandibular discrepancy that not only affects a significant percentage of the population²⁶ but is also considered one of the most frequent problems in orthodontic practice as it triggers a wide range of aesthetic and functional problems. During correction of this malocclusion, a variety of alterations may occur in the antero-posterior relationship, including distalization of maxillary teeth, mesialization of mandibular teeth, growth and/or orthopedic changes in the apical bases. Within this context, the Herbst appliance, developed by Emil Herbst in 1905,¹⁸ has been used in an attempt to change the amount and direction of growth of the maxilla and mandible.

Having as its main goal to stimulate mandibular growth and correct Class II malocclusion, it is reasonable to assume that tooth movement during treatment with the Herbst appliance is not desirable. However, it is difficult to avoid anchorage loss in both upper and lower teeth,¹⁵ which therefore renders anchorage with the Herbst appliance a daunting task.

Thus, throughout all these years the Herbst appliance has prompted researchers to develop different types of anchorage that are comfortable for the patient while reducing side effects to a great extent. Fixed anchorage, as proposed by Pancherz,¹⁸ has been significantly modified in an attempt to enhance treatment effectiveness. For example, bands have been replaced by steel crowns on the anchorage teeth.¹¹ The use of metal¹⁵ or acrylic⁶ splints has also been suggested in order to enhance anchorage and reduce breakage in regions where attachments are welded to bands. Mayes¹² recommended that anchorage be achieved with the aid of a cantilever if treatment is performed early, prior to the eruption of first premolars. Therefore, this prospective clinical study was conducted in order to evaluate the influence of the banded

Herbst appliance on dental changes during the early treatment of Class II malocclusion.

MATERIAL AND METHODS

Sample characterization

The treatment group comprised 15 Caucasian children (12 boys and 3 girls), aged 8-10 years (mean initial age of 9.4 ± 0.64 years, mean final age of 10.1 ± 0.64 years). Subjects were selected according to the following criteria:

- » Class II, Division 1 facial pattern associated with mandibular retrusion.
- » Class II, Division 1 dental relationship.
- » Central and lateral permanent maxillary and mandibular incisors either erupted or erupting.
- » Mixed dentition.
- » Absence of severe crowding in the lower arch and absence of transversal issues.

To determine Class II facial pattern and Class II dental relationship a clinical analysis of the face and occlusion was performed. Thus, a certain amount of subjectivity was present, as no measurable data obtained from lateral cephalograms were used. Facial analysis disclosed some features that helped to determine the Class II facial pattern, such as: Morphological evaluation of the nasolabial angle (straight, acute and obtuse) and length of the chin-neck line. Thus, individuals who had a convex profile, a straight or slightly acute angle, and a short chin-neck line, were classified as Class II facial pattern. Dental Class II, Division 1 relationship was determined by the sagittal position of the first permanent molars and deciduous or permanent canines, and overjet. Subjects with molar Class II equal to or greater than half a cusp, and overjet equal to or greater than 4 mm, were included in the sample.

Facial morphological pattern was determined by Jarabak's Facial Index. In this study, 60% of the subjects had mesofacial pattern, 33.33%, brachyfacial and 6.66%, dolichofacial pattern.

Patients were treated with a modified Herbst appliance, where the first permanent molars were

banded and bound together by a transpalatal arch welded to the bands and 2 mm away from the palate⁶ (Fig 1A). A modified Nance lingual arch made with 1.2 mm steel wire welded to the bands of the first permanent molars was used for anchorage. A cantilever extending to the region of primary or permanent canines was welded to the buccal side of mandibular first molar bands. The cantilever was attached to the lingual arch in the region of primary canines and first molars or permanent canines and first premolars, using 0.9 mm wire in order to avoid occlusal interference²² (Fig 1B). The anterior protrusion of the mandible with the Herbst appliance was performed as recommended by Pancherz¹⁶, i.e., single mandibular advancement to an extent that an incisor end-to-end bite was achieved (Fig 1C). The appliance was used for a period of 7 months.

The control group was selected among the patient records of the Burlington Growth Centre, located at the University of Toronto, and comprised 15 children (7 girls and 8 boys). The criteria for selection of the control group were:

- » Class II, Division 1 facial pattern associated with mandibular retrusion.
- » Class II, Division 1 dental relationship.
- » Erupted maxillary and mandibular permanent central incisors.
- » No prior orthodontic treatment.

The mean initial age in the control group was

9 years and 1 month (SD=0.09) and mean final age was 10 years (SD=0.05). Regarding facial morphology in the control group, 73% of the subjects had mesofacial pattern, 20 % brachyfacial and 7% dolichofacial patterns.

Skeletal age in both groups was assessed by means of lateral cephalometric radiography, using cervical vertebrae indicators of skeletal maturity. Bone age was determined by the same operator and in the form of a blind study (without identifying the patient being assessed), which reduces the subjectivity effect in the evaluation. The subjects of this study were in maturation stages 1 and 2, i.e., before the period of pubertal growth spurt, according to Baccetti et al² and O'Reilly and Yanniello.¹⁴

Methods

For each subject in the experimental group two lateral cephalograms were obtained at maximum intercuspation. They were named T1 (Beginning of treatment) and T2 (Seven months after treatment). Radiographs were obtained using an X-ray machine (model MR05 Rotograph Plus) set at 85 kVp and 10 mA and exposure time of 0.5 seconds. For the control group two lateral cephalograms were obtained at maximum intercuspation.

They were named T1, at 9 years of age, and T2 at age 10. The radiographs were taken in a Keleket device set to 120 kVp, 25 mA and exposure time of 0.3 seconds.

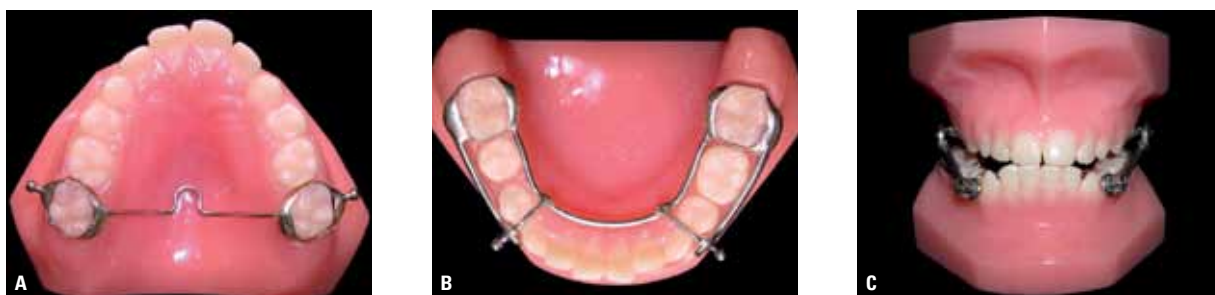

FIGURE 1 - **A)** Maxillary anchorage system with bands and palatal bar. **B)** Mandibular anchorage system with bands and cantilever. **C)** Herbst appliance telescope system after placement.

Although these radiographs were obtained by different X-ray machines, image magnification was not corrected. Image magnification, i.e., the percentage of magnification of the experimental sample, was 10%, equivalent to an increase of 0.1000 cm (1.000 mm), according to Sakima.²³ In the control group, a 9.84% magnification was reported, according to the records provided by the Burlington Growth Centre, as reported by Popovich and Thompson.²¹ Since the percentage difference in magnification between the samples was 0.16%, it would not affect the comparison of variables obtained by radiographs taken with different X-ray machines. This difference in magnification corresponds to a difference of 0.0016 cm (0.016 mm) between the radiographs. All radiographs were traced manually by one operator and then the cephalometric points (landmarks) were entered into a Numonics AccuGrid tablet and evaluated through computer software Dentofacial Planner Plus 1.2 to obtain the cephalometric measurements (Fig 2 and Table 1).

Statistical planning

To assess the potential occurrence of errors in measurements attributable to the observer or the measurement process all tracings were once again digitized and measured by the same operator with an interval of 2 weeks between the first and second evaluation. Intraclass correlation coefficient (ICC) was used to evaluate method error (reproducibility).

To compare the changes that occurred in the cephalometric measures, with and without treatment, it was necessary to eliminate the effect of the difference in time between measurements performed in the experimental and control groups. To this end, changes in measures were annualized.

To evaluate the data the following statistical tests were conducted:

a) Student t-test for equality of means of two independent populations: To examine the hypothesis that the mean of each cephalometric measure is equal to the experimental group at baseline (Table 2).

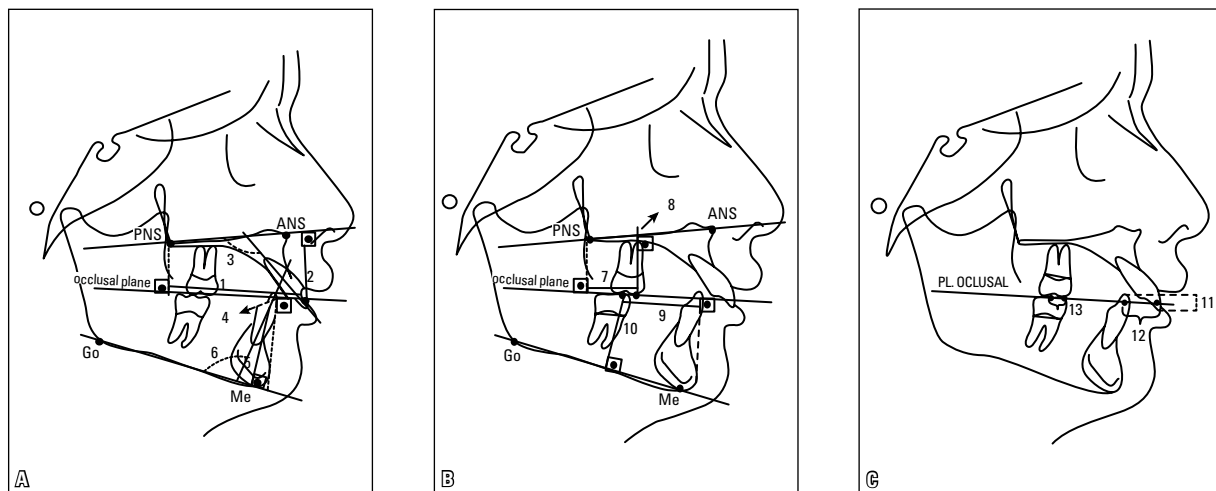


FIGURE 2 - Dental cephalometric measures: **A**) 1= IIs-PNS, 2= IIs-PP, 3= IIs.PP, 4= Ili-Pog, 5= Ili-MP, 6= Ili.MP; **B**) 7= CMs-PNS, 8= CMs-PP, 9= CMI-Pog, 10= CMI-MP; **C**) 11= overbite, 12= overjet, 13= molar relationship.

TABLE 1 - Linear and angular cephalometric measures.

Cephalometric measure	Definition
1) IIs-PNS	Linear distance from points IIs and PNS reflected perpendicularly in the occlusal plane. Represents the anteroposterior relationship between incisors and PNS
2) IIs-PP	Linear distance from the edge of the maxillary incisor perpendicularly to the palatal plane. Represents the vertical position of the incisors relative to PP
3) IIs-PP	Angle formed by the long axis of the maxillary incisors relative to the palatal plane. Represents incisor inclination with PP
4) Ili-Pog	Linear distance from points Ili and Pog reflected perpendicularly in the occlusal plane. Represents the anteroposterior relationship between incisor and pogonion
5) Ili-MP	Linear distance from the edge of the mandibular incisor perpendicularly to the mandibular plane. Represents the vertical position of the incisor relative to MP
6) Ili.MP	Angle formed by the long axis of the mandibular incisor and the mandibular plane. Represents incisor inclination relative to the mandibular plane
7) CMs-PNS	Linear distance from points CMs and PNS reflected perpendicularly in the occlusal plane. Represents the anteroposterior relationship between first molar and PNS
8) CMs-PP	Linear distance from the tip of the mesiobuccal cusp of the first permanent maxillary molar perpendicularly to the palatal plane. Represents the vertical position of the first molar relative to PP
9) CMi-Pog	Linear distance from points CMi and Pog reflected perpendicularly in the occlusal plane. Represents the anteroposterior relationship between molar and pogonion
10) CMi-MP	Linear distance from the tip of the mesiobuccal cusp of the first permanent mandibular molar perpendicularly to the mandibular plane. Represents the vertical position of first molar relative to MP
11) Overbite	Linear measurement which represents the vertical relationship between the edges of the maxillary and mandibular central incisors relative to the occlusal plane
12) Overjet	Linear measurement which represents the horizontal relationship between the edges of the maxillary and mandibular central incisors relative to the occlusal plane
13) Molar relationship	Linear distance from points CMs and CMi reflected perpendicularly in the occlusal plane. Represents the horizontal relationship between maxillary and mandibular molars

TABLE 2 - Mean and standard deviation of cephalometric measurements in experimental and control groups and mean differences between distances, before treatment, and Student t-test for differences in cephalometric measures.

Cephalometric measure	Experimental Group		Control group		Mean difference	t-test		
	Mean	SD	Mean	SD		t	df	p
Overbite	5.46	1.96	2.56	1.78	2.90	4.24	28	0.000*
Molar relationship	1.11	0.87	0.90	0.62	0.20	0.74	28	0.466
IIs-PP	115.69	7.90	112.53	6.62	3.16	1.19	28	0.245
Ili.MP	96.23	4.51	99.67	6.05	-3.45	-1.77	28	0.088
IIs-PP	29.30	1.97	25.32	2.29	3.98	5.11	28	0.000*
Ili-MP	39.41	3.20	36.47	2.58	2.94	2.77	28	0.010*
CMs-PP	20.48	2.21	18.78	1.43	1.70	2.51	28	0.018*
CMi-MP	28.66	2.99	27.68	2.02	0.98	1.05	28	0.302
CMs-PNS	18.36	3.09	16.50	1.98	1.86	1.97	28	0.059
IIs-PNS	58.06	4.63	50.45	2.21	7.61	5.75	20.1	0.000*
Ili-Pog	0.58	3.71	-1.54	3.53	2.12	1.60	28	0.121
CMi-Pog	28.71	4.09	27.00	3.77	1.71	1.19	28	0.245
Overjet	8.65	2.60	5.33	1.68	3.32	4.16	28	0.000*

* Statistically significant at 5% significance level.

Source: SPSS software package (Statistical Package for the Social Sciences, for Windows, version 10.0, SPSS Inc., Chicago, IL, USA).

b) Student t-test for equality of means of two populations with independent samples: To examine the hypothesis that the observed changes in a given cephalometric measure between times 1 and 2 are identical, on average, in the control and experimental groups (Table 3).

RESULTS

The results indicated that the measurement process was highly accurate since the expected ICC value was at least 0.983 and, for most variables, the ICC was above 0.99. Given the high degree of agreement between the two measurements, it was decided that the mean obtained in both measurements would be used for each variable at each time.

Assessment of equivalence between the experimental and control groups regarding the variables of interest at baseline (Table 2) showed that the experimental group had greater overjet and overbite.

TABLE 3 - Means and results of Student t-tests of equality of means in the experimental group and control group, for each of the variables under study.

Cephalometric measures	Means		t-test		
	Experimental Group	Control group	t	gl	p
Overbite	-1.26	0.62	-2.98	28	0.006*
Molar relationship	-12.08	0.23	-13.41	14.8	0.000*
IIs.PP	-4.14	-0.32	-2.01	28	0.054
Ili.MP	1.37	0.46	0.61	28	0.550
IIs-PP	0.76	0.64	0.27	28	0.787
Ili-MP	1.05	0.70	0.91	28	0.369
CMs-PP	-1.24	0.29	-5.12	28	0.000*
CMi-MP	0.72	0.29	1.04	28	0.306
CMs-PNS	-2.65	1.20	-4.37	21.0	0.000*
IIs-PNS	0.34	1.28	-1.30	28	0.205
Ili-Pog	-1.64	0.60	-2.82	28	0.009*
CMi-Pog	-1.11	-0.24	-1.27	28	0.214
Overjet	-4.80	0.17	-7.37	20.1	0.000*

(*) Statistically significant at 5% significance level.

Source: SPSS software package (Statistical Package for the Social Sciences, for Windows, version 10.0, SPSS Inc., Chicago, IL, USA).

According to Table 3, it can be seen that in 6 (overbite, molar relationship, CMs-PP, CMs-PNS, Ili-Pog, overjet) of the 13 variables studied, the mean changes that occurred in the treated population is statistically different from the mean changes which occurred in the untreated population.

DISCUSSION

Orthopedic appliances are meant to provide maximum orthopedic effect, so it is reasonable to assume that tooth movement during treatment is not desirable. However, no matter how good the performance of the appliance, it is difficult to avoid anchorage loss in both maxillary and mandibular teeth.¹⁵ This limitation in the skeletal effect of orthopedic devices is due in part to what is referred to as “distance” anchorage, i.e., including both the upper and lower dental arches.²⁵ Therefore, when the telescoping system of the Herbst appliance is fitted, it produces a force in the superior and posterior direction in maxillary teeth, and a force in the anterior and inferior direction in mandibular teeth.⁸

Therefore, when analyzing the changes occurred in maxillary incisors, it was found that while in the control group variable IIs-PNS increased significantly (1.28 mm/year) in the experimental group the change was not significant in the same direction (0.34 mm), although much smaller than in the untreated group. This finding suggests that since in the untreated group the upper incisors tended to follow maxillary growth, the experimental group tended to show inhibited anterior drift of these teeth. By observing variable IIs.PP, it was found that in the experimental group it showed a significant -4.14° /year decrease, whereas in the control group it showed no significant alteration. This finding confirms that in this study maxillary incisors were uprighted during treatment. This outcome stood out due to the fact that the maxillary incisors were not incorporated in the anchorage

system. It is believed that this uprighting was caused by vertical mandibular postural change toward the anterior region, thereby yielding improved lip competence. Rego²² found in their study that maxillary incisors were uprighted by about 6° in patients subjected to early treatment with the Herbst appliance. Several studies^{1,3,7,16,20,29,30} have reported a similar movement in maxillary incisors. However, other authors observed no changes in the position of these teeth during treatment with the Herbst appliance.^{17,27}

As regards the vertical behavior of maxillary incisors, it was observed that while in the control group variable IIs-PP increased significantly (0.64 mm/year), in the experimental group it experienced no significant change during the treatment period. Lai and McNamara⁹ also observed no change in upper incisors in the vertical plane in subjects treated with the Herbst appliance. Likewise, Valant and Sinclair²⁷ found that maxillary incisors did not change position during treatment.

Regarding changes in maxillary molars, it was observed that in the experimental group there was a significant change in the sagittal position of these teeth when variable CMs-PNS was measured (-2.65 mm/year). This alteration in the treated group occurred in opposite direction of the untreated group (1.2 mm/year). This reversal in the direction of the change showed that in the experimental group maxillary molars were distalized during treatment with the Herbst appliance while in the control group these teeth followed maxillary growth, thus worsening the Class II. This finding was also reported by Franchi et al,⁵ who found an upper molar distalization of -1.71 mm during treatment with the Herbst appliance. Konik et al⁷ also noted a distalization of -2.6 mm in patients undergoing early treatment with the Herbst appliance, and Pancherz¹⁶ found a -2.8 mm distalization of maxillary molars during treatment with the Herbst appliance. In most studies, upper molar distalization contributes significantly to the correction of molar

relationship. There is, however, substantial variation in the amount of distalization between studies, ranging from 1.8 mm⁵ to 2.8 mm.¹⁶ When using the Herbst appliance with bands, distalization is responsible for 25% to 40% of molar correction.^{7,20} On the other hand, when using the Herbst appliance combined with an acrylic splint, distalization is responsible for 20% to 25% of molar correction.^{5,9,30}

Regarding the behavior of upper molars in the vertical plane, a significant decrease (-1.24 mm/year) was observed in the CMs-PP measure, while the control group showed that a non-significant change took place in this measure, but in the opposite direction. It is therefore reasonable to conclude that the Herbst appliance acted by restricting molar eruption. Almeida et al¹ also found that the Herbst appliance produced greater inhibition of upper molar eruption (-0.7 mm) in subjects undergoing treatment with mixed dentition. Likewise, Pancherz¹⁷ found that molar eruption was inhibited by -1.0 mm during treatment, and Flores-Mir et al⁴ identified a change of -0.9 mm in the vertical plane of maxillary molars during treatment with the Herbst appliance. These effects, which were observed in molars in this study, may be explained by the fact that the telescopic mechanism of the Herbst appliance, once installed, produces a force in the posterior and superior direction in the upper dental arch, thus simulating the effect of a high-pull hegear.^{5,13,17,30}

As regards the sagittal changes that occurred in mandibular incisors, these teeth tended to procline, although not significantly, when measure Ili.MP was examined (1.37°/year). The change observed in the treated group occurred in the same direction as in the control group, but with greater impact. Major changes in the sagittal position of mandibular incisors can be found by comparing variable Ili-Pog (-1.64 mm/year) in the experimental

group and the control group (0.60 mm/year), showing that the lower incisors moved anteriorly relative to the pogonion. Anterior mandibular incisor inclination occurred as a result of anchorage loss due to the anterior force exerted by the telescoping system in mandibular teeth.^{18,20} These data are consistent with other studies.^{1,4,7,9,13,16,19,20,22,24,29,30} In these studies, the degree of inclination of mandibular incisors was very high and extremely variable (ranging from 2.0° to 8.4°). In this study, we found a smaller amount of flaring, an outcome similar to that recorded by Valant, Sinclair²⁷ and Croft et al.³ This slight flaring of lower incisors is probably due to the mandibular anchorage structure that was used. This mandibular structure consisted of a lingual arch placed 3 mm away from the anterior mandibular teeth, i.e., there was no direct contact between the anchorage system and these teeth, thereby reducing the force produced by the telescoping system in this region.

As regards the vertical behavior of mandibular incisors, it was observed that variable Iii-MP showed a significant change both in the experimental group (1.05 mm/year) and in the control group (0.70 mm/year). However, a comparison between the experimental and control groups showed that there was no statistically significant change between them. According to this finding, it was noted that the Herbst appliance does not influence the process of mandibular incisor eruption. Rego²² concluded that mandibular incisors did not suffer any change in the vertical direction after 12 months of treatment with the Herbst appliance. Similarly, McNamara et al¹³ and Pancherz^{16,17} found no vertical changes in these teeth.

In assessing the molar, a significant change was identified in variable CMi-Pog (-1.11 mm/year), indicating that the molar was mesialized during treatment. Comparing this outcome with that of the control group, a change in the same direction was identified, although more intense in the treated group. However, no statistically

significant difference was found between the groups. Konik et al⁷ found that the mandibular molar was mesialized by 1.3 mm in patients subjected to an early treatment. Franchi et al⁵ also found a 1.44 mm movement in the anterior direction in the lower molar, while Pancherz and Hägg¹⁹ found a change of 1.5 mm in these same teeth in patients treated with the Herbst appliance. Mesialization of mandibular molars also contributes to the correction of Class II molar relationship, ranging from 0.8 mm⁵ to 2.2 mm.³⁰ In studies that use the banded Herbst appliance, mesialization of mandibular molars is usually smaller than maxillary molar distalization, and contributes about 20 to 30% to the correction of malocclusion as a whole. In studies using the Herbst appliance with an acrylic splint these changes are similar and contribute 25% to correcting molar relationship.^{5,9,30}

In analyzing measure CMi-MP, it was found that there was no significant vertical change in the mandibular molar in both groups. This finding is consistent with the findings of Flores-Mir et al,⁴ Valant and Sinclair.²⁷ However, the results of this study disagreed with those of Almeida et al;¹ Lai, McNamara⁹; Pancherz¹⁷ and Rego,²² who found significant molar eruption during treatment with the Herbst appliance.

In assessing the effects caused by the use of the Herbst appliance on the horizontal relationship of incisors, it was observed that while the control group tended to increase this variable, but not significantly, in the experimental group there was a statistically significant decrease of -4.8 mm/year in this measure. Pancherz and Hansen²⁰ observed a reduction of 6.9 mm in overjet in patients treated with the banded Herbst appliance.

In assessing the vertical distance between the incisors, it was found that in the control group there was a significant increase in this variable. This result suggests that overbite was severe in patients who received no treatment, since in the experimental group a significant decrease of

-1.26 mm was observed in this measure. This result is in agreement with Croft et al,³ who found a decrease of -2.0 mm in the treated group. Pancherz¹⁷ also reported a -2.5 mm decrease in overbite during treatment with the Herbst appliance.

An analysis of molar relationship showed that there was a statistically significant change for this measure, equivalent to -12.08 mm/year. By comparing these changes with those observed in the control group, which had been in the opposite direction to this group (0.23 mm/year), it can be argued that the Herbst appliance caused a positive change in the correction of molar relationship in the present study.

According to the results, it was noted that dental changes did occur, and therefore to avoid such changes, it is recommended that more teeth be incorporated in the anchorage system. However, no anchorage system exists

today which is capable of preventing dental changes. Weschler and Pancherz²⁸ evaluated the effects of three different anchorage systems and concluded that anchorage loss was inevitable, regardless of the type of anchorage used. They further argued that anchorage loss in Class II treatment with the Herbst appliance always occurs, and orthodontists should therefore learn to cope with this reality.

CONCLUSIONS

The use of the banded Herbst appliance in the mixed dentition stage induced changes in both dental arches which contributed to the correction of Class II malocclusion. Such changes were most evident in the upper dental arch. Furthermore, mandibular anchorage loss was adequately reduced thanks to the anchorage system used in the present study.

REFERENCES

- Almeida MR, Henriques JF, Almeida RR, Weber U, McNamara JA Jr. Short-term treatment effects produced by the Herbst appliance in the mixed dentition. *Angle Orthod.* 2005;75(4):540-7.
- Baccetti T, Franchi L, McNamara JA. The cervical vertebral maturation (CVM) method for the assessment of optimal treatment timing in dentofacial orthopedics. *Semin Orthod.* 2005;11(3):119-29.
- Croft RS, Buschang PH, English JD, Meyer R. A cephalometric and tomographic evaluation of Herbst treatment in the mixed dentition. *Am J Orthod Dentofacial Orthop.* 1999;116(4):435-43.
- Flores-Mir C, Ayeh A, Goswami A, Charkhandeh S. Skeletal and dental changes in Class II division 1 malocclusions treated with splint-type Herbst appliance. A systematic review. *Angle Orthod.* 2007;77(2):376-81.
- Franchi L, Baccetti T, McNamara JA Jr. Treatment and post treatment effects of acrylic splint Herbst appliance therapy. *Am J Orthod Dentofacial Orthop.* 1999 Apr;115(4):429-38.
- Howe RP. The bonded Herbst appliance. *J Clin Orthod.* 1982;16(10):663-67.
- Konik M, Pancherz H, Hansen K. The mechanics of Class II corrections in late Herbst treatment. *Am J Orthod Dentofacial Orthop.* 1997;112(1):87-91.
- Lai M. Molar distalization with the Herbst appliance. *Semin Orthod.* 2000;6(2):119-28.
- Lai M, McNamara JA Jr. A evaluation of two-phase treatment with the Herbst appliance and pre-adjusted Edgewise therapy. *Semin Orthod.* 1998;4(1):46-58.
- Lamparski DG. Skeletal age assessment utilizing cervical vertebrae. *Am J Orthod.* 1975;67(4):458-9.
- Langford NM Jr. Updating fabrication of the Herbst appliance. *J Clin Orthod.* 1982;16(3):173-4.
- Mayes JH. Improving appliance efficiency with the cantilever Herbst. A new answer to old problems. *Clin Impressions.* 1994;3(2):2-5,17-9.
- McNamara JA Jr, Howe RP, Dischinger TG. A comparison of the Herbst and Fränkel appliances in the treatment of Class II malocclusion. *Am J Orthod Dentofacial Orthop.* 1990;98(2):134-44.
- O'Reilly MT, Yanniello GJ. Mandibular growth changes and maturation of cervical vertebrae — A longitudinal cephalometric study. *Angle Orthod.* 1988;58(2):179-84.
- Pancherz H. History, background, and development of the Herbst appliance. *Semin Orthod.* 2003;9(1):3-11.
- Pancherz H. The mechanism of Class II correction in Herbst appliance treatment. *Am J Orthod.* 1982;82(2):104-13.
- Pancherz H. The Herbst appliance — Its biologic effects and clinical use. *Am J Orthod.* 1985;87(1):1-20.
- Pancherz H. Treatment of Class II malocclusions by jumping the bite with the Herbst appliance. *Am J Orthod.* 1979;76(4):423-42.
- Pancherz H, Hägg U. Dentofacial orthopedics in relation to somatic maturation. An analysis of 70 consecutive cases treated with the Herbst appliance. *Am J Orthod.* 1985;88(4):273-87.
- Pancherz H, Hansen K. Occlusal changes during and after Herbst treatment: a cephalometric investigation. *Eur J Orthod.* 1986;8(4):215-28.
- Popovich F, Thompson GW. Craniofacial templates for orthodontic case analysis. In: Clark JW. *Clinical dentistry.* Philadelphia: Harper & Row; 1983. p. 1-24.
- Rego MVNN. Estudo cefalométrico das alterações esqueléticas, dentárias e tegumentares induzidas pelo aparelho Herbst no tratamento da má oclusão Classe II, 1ª divisão de Angle. [dissertação]. Porto Alegre (RS): Pontifícia Universidade Católica; 2003.
- Sakima PRT. Efeitos dos erros de projeção sobre as grandezas cefalométricas das análises de Steiner e McNamara. [dissertação]. Araraquara (SP): Universidade Estadual de São Paulo; 2001.
- Schiavoni R, Grenga V, Macri V. Treatment of Class II high angle malocclusions with the Herbst appliance. A cephalometric investigation. *Am J Orthod Dentofacial Orthop.* 1992;102(5):393-409.
- Silva Filho OG. Aparelho de Herbst - variação para uso na dentadura mista. *Rev Dental Press Ortod Ortop Facial.* 2000; 5(5):58-67.
- Silva Filho OG, Freitas SF, Cavassan AO. Prevalência de oclusão normal e má oclusão na dentadura mista em escolares da cidade de Bauru (São Paulo). *Rev Assoc Paul Cir Dent.* 1989; 43(6):287-90.
- Valant JR, Sinclair P. Treatment effects of the Herbst appliance. *Am J Orthod Dentofacial Orthop.* 1989; 95(2):138-47.
- Weschler D, Pancherz H. Efficiency of three mandibular anchorage forms in Herbst treatment: a cephalometric investigation. *Angle Orthod.* 2005;75(1):23-7.
- Wieslander L. Intensive treatment of severe Class II malocclusion with a headgear-Herbst appliance in the early mixed dentition. *Am J Orthod.* 1984;86(1):1-13.
- Windmiller EC. The acrylic-splint Herbst appliance: a cephalometric evaluation. *Am J Orthod Dentofacial Orthop.* 1993;104(1):73-84.

Submitted: November 3, 2008
 Revised and accepted: April 21, 2009

Contact address

Luana Paz Sampaio
 Av. Portugal, 887, Centro
 Zip code: 14.801-075 – Araraquara/SP, Brazil
 E-mail: lusampaz@hotmail.com