



ELSEVIER

CASE REPORT

Aesthetic and functional ocular rehabilitation

Marcelo Coelho Goiato ^{a,*}, Daniela Nardi Mancuso ^a,
Maria Lucia Marçal Mazza Sundefeld ^a, Marcelo Basilio Da Motta Gabriel ^a,
Ana Cristina Murakawa ^a, Aimée Maria Guiotti ^{a,b}

^a *Oral Oncology Center, School of Dentistry, UNESP—São Paulo State University, Ruo José Bonifácio 1193, CEP 16015-050 Araçatuba, São Paulo, Brazil*

^b *School of Dentistry—FISA, Brazil*

Received 12 April 2005; accepted 12 April 2005

KEYWORDS

Eye injuries;
Blindness monocular;
Ocular prosthesis;
Artificial eye

Summary The ocular losses are embarrassing to the bearer because they commit the face which has the essential organs for the human relationship. The present study shows the multidiscipline interaction in the treatment of a child who lost his left eye victim of a fire gun and needed an ocular plastic surgery for a correct prosthesis insertion. The ocular prosthesis fills in the ocular cavity simulating the facial growth and restoring its symmetry. Therefore, there are aesthetics, anatomic and physiological improvement on the child's face that allows her to be reinstated in society without being discriminated for her differences.

© 2005 Elsevier Ltd. All rights reserved.

Introduction

The orbital defects are embarrassing to the bearer because they commit the face which has the essential organs for the human relationship. Orbital defects may be associated with congenital deformities, tumors, or acquired traumatic lesions and may affect the soft tissues within the orbital cavity

or may include the surrounding muscles and bones.¹

Trauma can be considered as the most important cause of unilateral loss of vision in developing countries. American studies shows that trauma is the most common cause of unilateral loss of vision and responsible for 7% of bilateral loss in people aged 20–64 years.^{2,3}

In study of de Gottrau et al.⁴ the clinicopathological data of 1146 enucleated eyes obtained from 1146 patients (485 females and 661 males; mean age 57.4 (SD 21.6) years) between 1980 and 1990 were reviewed. The most common underlying diseases included trauma (37.4%) and the most frequent indications for enucleation were recent

* Corresponding author. Fax: +55 18 3642 5777.

E-mail addresses: goiato@foa.unesp.br (M.C. Goiato), danimancuso@msn.com (D.N. Mancuso), mlsundef@foa.unesp.br (M.L.M.M. Sundefeld), marcelo.gab.m@zaz.com.br (M.B. Da Motta Gabriel), murakawa@bol.com.br (A.C. Murakawa), aime-emia@ig.com.br (A.M. Guiotti).

trauma (enucleation was performed within the first month after trauma) (11.2%).

After that, Marshall et al.⁵ studied the proportion of enucleation procedures attributable to injuries from air guns in people aged 18 years or less. Eighty-five patients were identified as having undergone enucleation. Trauma accounted for 51 cases (60%), of which 13 (25%) were caused by air guns, the largest single cause of enucleation secondary to trauma. All air gun injuries were in boys (median age 14 years, range 9–16 years). Of the 13 eyes with air gun injuries 7 had ocular perforation and 6 had ocular penetration. In all cases the intra-ocular structures were severely disrupted.

In 2003, Kitzmann et al.⁶ shows that among 523 enucleated globes (81.0%), 59 (11.3%) are due to recent trauma.

Ocular trauma and corneal ulceration are significant causes of corneal blindness that are often underreported but may be responsible for 1.5–2.0 million new cases of monocular blindness every year.⁷

Enucleation or evisceration causes constriction of the tissues around the cavity. In some cases, a deformity caused by trauma need an ocular plastic surgery permitting a correct prosthesis insertion. However, the fabrication of a definitive ocular prosthesis should begin as soon as the socket has healed to avoid the deformity of this area.⁸ Therefore, the patient quality of life will be improved, and consequently his self-esteem will be increased.

The purpose of this article is to show the multidiscipline interaction in the treatment of a child who lost his left eye victim of a fire gun and needed an ocular plastic surgery for a correct prosthesis insertion.

Clinical report

A 12-year-old boy lost his left eye victim of a fire gun (Fig. 1). The projectile dilacerated his upper eyelid tissue and an ocular plastic surgery was planned to facilitate the correct prosthesis insertion and to improve the aesthetic.

At the moment of the plastic surgery planning a photograph showing the bilateral eye was asked for the patient's parent to facilitate the manufacturing of the prosthesis and the reconstruction of the upper eyelid tissue (Fig. 2). During the plastic surgery planning a multidiscipline interaction is very important to the treatment success.

The plastic surgery was done and a provisional prosthesis was inserted into the eye socket to

maintain the volume of the anophthalmic socket (Fig. 3).

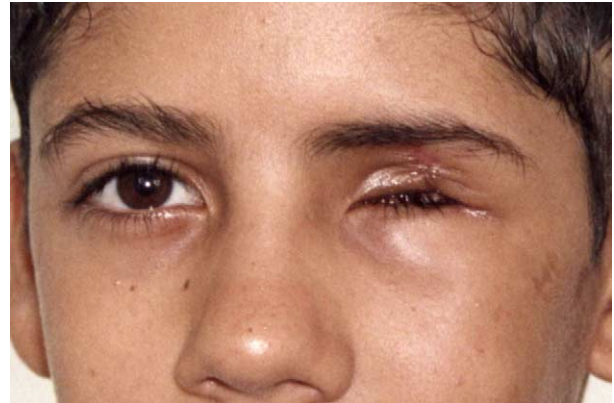

Figure 1 A 12-year-old boy who lost his left eye victim of a fire gun.

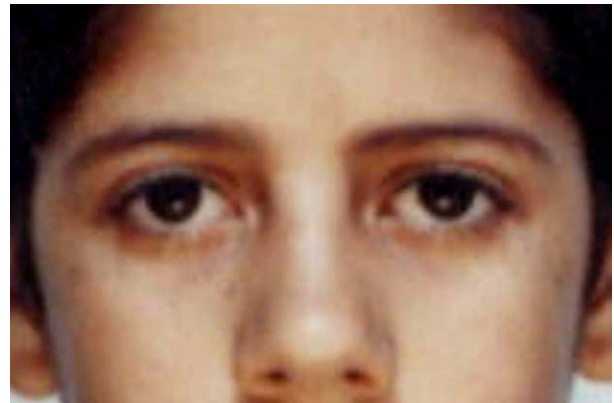


Figure 2 Patients photograph showing the bilateral eye before accident.

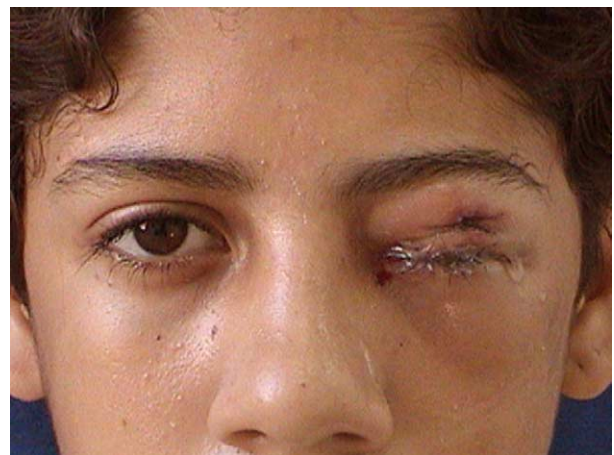

Figure 3 Provisional prosthesis inserted into the eye socket to maintain the volume of the anophthalmic socket during plastic surgery.

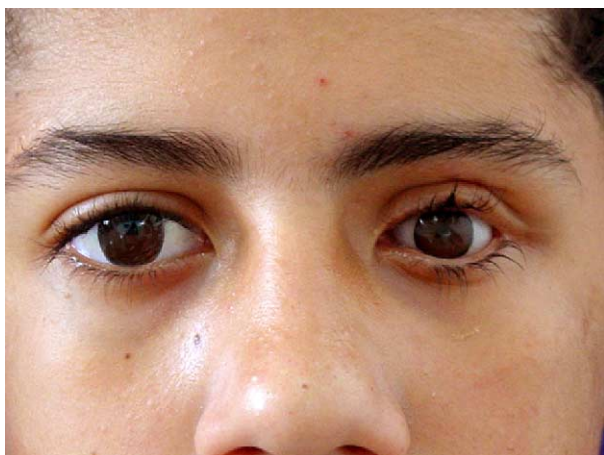


Figure 4 Aesthetics is improved after placement of an ocular prosthesis.

A molding of the socket was taken with an irreversible hydrocolloid material for the manufacture of a definitive ocular prosthesis after the socket healing to avoid the deformity of this area.

Socket expansion, which uses prosthesis of progressively larger sizes over an extended period, will be need. The patient was instructed to return in six months to change the prosthesis for another one. This procedure will be repeated until the correct size of the socket is obtained. Aesthetics was improved after placement of an ocular prosthesis (Fig. 4).

Results

The ocular prosthesis fills in the ocular cavity simulating the facial growth and restoring its symmetry. Therefore, there are aesthetics, anatomic and physiological improvement on the child's face allowing her to be reinstated in society without being discriminated for its difference.

Conclusion

Any kind of deformity, facial or not, can cause to the patient psychological and emotional disturbance, and social annihilation. Rehabilitate according to certain dictionaries is to recover the credit, the self-esteem, or be well-thought-of by society. To have it done, there is the need to give the lost organ back, even though if it is in an alloplastic form. In addition to that, a multidiscipline interaction is very important to the treatment success.

With this prosthesis the patient will be able to protect the area from infection and in a lot of cases it will help him psychologically. At the same time, the patient could be easier reinstated in society.

References

1. Ivy RH. *Manual of standard practice of plastic and maxillo-facial surgery*, vol. 13. WB Saunders: Philadelphia, London; 1942. p. 341–75.
2. Kuhn F, Morris R, Witherspoon CD, Heimann K, Jeffers JB, Treister G. A standardized classification of ocular trauma. *Ophthalmology* 1996;**103**(2):240–3.
3. Pieramici DJ, Sternber Jr. P, Aaberg TM, et al. A system for classifying mechanical injuries of the eye (globe). The ocular trauma classification group. *Am J Ophthalmol* 1997;**123**(6):820–31.
4. de Gottrau P, Holbach LM, Naumann GO. Clinicopathological review of 1146 enucleations (1980–90). *Br J Ophthalmol* 1994;**78**(4):260–5.
5. Marshall DH, Brownstein S, Addison DJ, Mackenzie SG, Jordan WN, Clarke WN. Air guns: the main cause of enucleation secondary to trauma in children and young adults in the greater Ottawa area in 1974–93. *Can J Ophthalmol* 1995;**30**(4):187–92.
6. Kitzmann AS, Weaver AL, Lohse CM, Buettner H, Salomao DR. Clinicopathologic correlations in 646 consecutive surgical eye specimens, 1990–2000. *Am J Clin Pathol* 2003;**119**(4):594–601.
7. Whitcher JP, Srinivasan M, Upadhyay M. Corneal blindness: a global perspective. *Bull World Health Organ* 2001;**79**(3):214–21.
8. Sykes LM. Custom made ocular prostheses: a clinical report. *J Prosthet Dent* 1996;**75**(1):1–3.