

Effects of topical application of 5 -FU on the corneoscleral limbus of rabbits

Lucieni C B Ferraz¹, Silvana A Schellini¹, Mariangela E A Marques²

Foundation item: Supported by FAPESP

¹ Department of Ophthalmology, Faculdade de Medicina de Botucatu, São Paulo State, Brazil

² Department of Pathology, Faculdade de Medicina de Botucatu, São Paulo State, Brazil

Correspondence to: Silvana A Schellini. Department of T/ORL/CCP, Faculdade de Medicina de Botucatu, CEP 18618-000-Botucatu-São Paulo State, Brazil. sartioli@fmb.unesp.br

Received:2009-03-15 Accepted:2009-07-29

Abstract

- **AIM:** To observe the effects of topical 5-fluorouracil (5-FU) application on the rabbits corneal limbus.
- **METHODS:** 5-FU was applied topically to the corneoscleral region of rabbits' eyes. The animals were sacrificed immediately or 7, 15, 30 and 60 days later, and tissues were submitted to histological examination.
- **RESULTS:** All animals presented corneoscleral deepithelization close to the site of application during the immediate postoperative period, whereas on the 4th postoperative day ulceration was no longer present. Histological examination showed absence of epithelium and slight edema. After one week (G2), 2 animals presented epithelial defects, thickened epithelium with larger basal cells and loose chromatin, and slight subepithelial edema. The remaining groups showed no alterations.
- **CONCLUSION:** The 5-FU topically applied on the corneoscleral limbus postpones the epithelization.
- **KEYWORDS:** 5-fluorouracil; antimetabolic agent; rabbits; topical application; histopathology

Ferraz LCB, Schellini SA, Marques MEA. Effects of topical application of 5-FU on the corneoscleral limbus of rabbits. *Int J Ophthalmol* 2009;2(3):195-197

INTRODUCTION

The antimetabolic agents were used to increase the success of pterygium excision, preventing recurrence of the lesion ^[1]. The mitomycin C applied in a low concentration

and in a single intraoperative application in the surgical treatment of pterygium and it is an effective and safe adjuvant treatment ^[2]. However, high concentration of mitomycin C provoked corneal inflammation, necrosis of the stroma, loss of endothelium, and hemorrhagic necrosis of the iris, whereas 5-fluorouracil (5-FU) showed no microscopic evidence of toxicity ^[3]. Five-FU and mitomycin C were described at the same time, but mitomycin C has been much more intensively studied and used than 5-FU. A cytostatic drug of antimetabolic action, 5-FU inhibits DNA formation, with potential selective toxicity for displasic epithelium, representing a promising agent for the adjuvant treatment of epithelial neoplasia of conjunctiva and cornea^[4].

The purpose of this experimental study is to determine the effects of topical 5-FU application on the corneoscleral limbus of rabbits.

MATERIALS AND METHODS

Experimental Design The study was conducted on 20 albino rabbits from the Central Animal House, Botucatu Campus-UNESP. The rabbits were anesthetized with sodium pentobarbital (100g/L) at the dose of 1mg/kg body weight. The temporal limbic conjunctiva of the right eye was separated from the sclera and physiologic solution (G1) or 5-FU (Roche, 250mg per 10mL-25g/L solution) (G2) was applied with cotton swab soaked in 0.3mL of the solution on Tenon's capsule and on the sclera for 5 minutes. The ocular bulb was then washed with physiological saline and the conjunctiva was repositioned.

Four animals for each group were sacrificed in five experimental moments (M): immediately after application (M1) or 7 (M2), 15 (M3), 30 (M4) and 60 (M5) days after the application. The sacrifice was done with sodium pentobarbital overdose. The eyes were immediately enucleated and the region submitted to treatment was removed. The fragments were fixed in 40g/L formaldehyde and prepared for histological examination. Slides were stained with hematoxylin-eosin and analyzed by an examiner who was unaware of the group to which the animals belonged.

Evaluated Parameters The rabbits were daily evaluated by eye external examination using a slight lamp and fluorescein staining. After the sacrifice the area that received the 5-FU was evaluated by light microscopy.

RESULTS

Clinical evaluation showed that the site of application had ulcer in all animals immediately after application and that deepithelization was no longer present in any animal after the 4th postoperative day. Secondary infection with bacterial conjunctivitis occurred in one animal, which was sacrificed on the 7th postoperative day.

Histopathological Evaluation G1 group: Absence of epithelium was observed in M1 animals. At M2, wound healing, fibroblasts, newvessels, and thin epithelium were observed. After that, from M3 to M5, normal structure of the region was observed (Figure 1). G2 group: Absence of conjunctivae epithelium was observed at the site of application, with edema, few red blood cells and inflammatory cells in the M1. The remaining structures were unchanged (Figure 2). At M2, the conjunctivae epithelium was thicker than the observed in the G1 animals, with no differentiation, larger nuclei in the basal cells and looser chromatin. The subepithelial edema was less intense than in the M1. An exocytic inflammatory infiltrate permeating the epithelium was observed (Figure 3). At the site of application, the epithelium was absent in two animals and present in the other two. In this group, one animal showed intense inflammation with the presence of inflammatory cells also in the sclera. The remaining structures were normal. In M3, the epithelium showed irregularity of the basal layer, exocytosis was observed in two animals, and scarce globet cells were present. The subepithelial edema and inflammatory infiltrate were discrete in 2 animals and absent in other two. The remaining structures were normal (Figure 4). At the M4 moment, the epithelium was normal and scarce globet cells were present. The remaining structures were normal (Figure 5). At M5, one of the animals presented a mononuclear inflammatory infiltrate localized below the epithelium at the site of 5-FU application. The remaining structures were normal (Figure 6).

DISCUSSION

Clinical evaluation and the use of fluorescein showed corneo-conjunctival deepithelization close to the site treated with 5-FU immediately after application, probably due to the surgical trauma and not because the effect of the antimittotic agent, since neither mitomicyn C nor 5-FU cause apparent

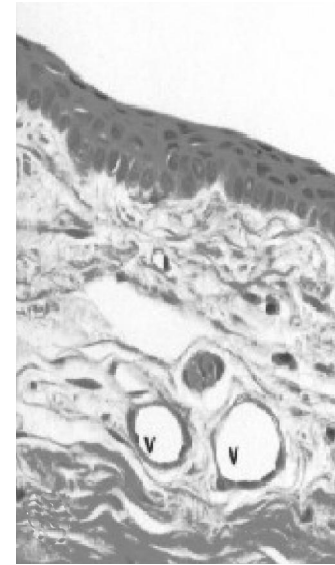


Figure 1 Stratified pavement type epithelium consisting of approximately 5 to 6 cell layers. Blood vessels (v) in the conjunctivae chorion. Sclera (e) with multiple layers of dense connective tissue (G1: M3–M5–HE×100)

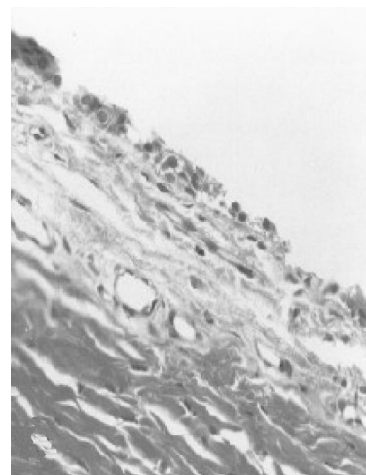

Figure 2 The absence of conjunctivae epithelium was observed at the site of application (G2–M1–HE×200)

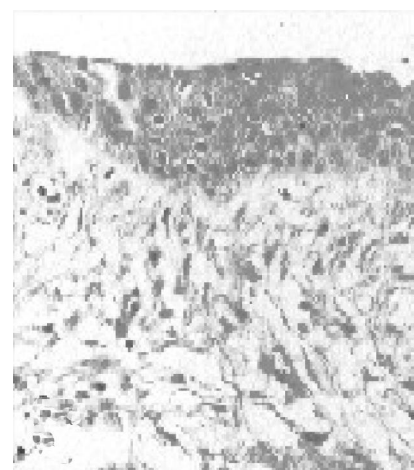


Figure 3 Conjunctiva epithelium without cell differentiation. Subepithelial edema (G2–M2–HE×200)




Figure 4 Irregularity of the basal layer. Discrete subepithelial edema (arrow) (G2-M3-HE×100)

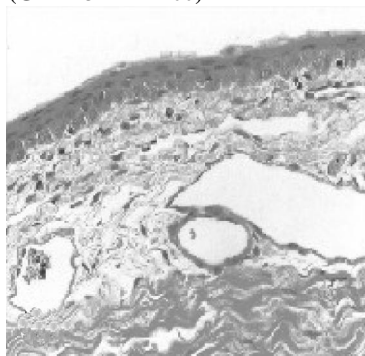


Figure 5 Epithelium were similar to those of the G1(M3-M5) (G2-M4-HE×100)




Figure 6 Epithelium was similar G1 (M3-M5). Where was no subepithelial edema (G2-M5-HE×100)

changes in the intact cornea [5]. We observed edema and an exocytic inflammatory infiltrate permeating the epithelium 7 days after drug application. In two rabbits, exocytosis was present 15 days after application. We also noted bacterial conjunctivitis in one animal, which was sacrificed on the seventh postoperative day and we interpret this as secondary infection. The only previous histological study about topical application of 5-FU was conducted on conjunctivae biopsies from the temporal limbic region after topical application of 5-FU to conjunctivae neoplasia, showing epithelium of normal thickness and rare cells with atypical nuclei^[4].

In the present study, we observed that on the 7th postoperative day the epithelium was thicker than that in

control animals, with loss of differentiation and basal cells of smaller size and with looser chromatin. These may be signs that the epithelium is regenerating. However, knowing that the conjunctivae epithelium regenerates quickly, being totally replaced within 24 hours, we may assume that a delay in epithelial growth occurred at the site treated with 5-FU. Changes in cell morphology were observed in cells of the corneal epithelium of cattle in culture after 5-FU application at the concentration of 2.5mg/L. Five-FU irreversibly inhibited the cellular mitotic activity of the corneal endothelium throughout the healing process^[6].

At the later time, the regenerated conjunctivae epithelium was similar to the normal one, except for a smaller number of goblet cells. Since the goblet cells are responsible for the mucous layer of the lacrimal film, we may expect deficient mucous secretion during the conjunctivae regeneration. There are other studies about 5-FU using cell culture which demonstrated that fibroblasts treated for 5 minutes with the antimetabolites may still influence the behavior of other cells via soluble mediators with implications in scarring after glaucoma filtration surgery^[7].

Our results allow to conclude that 5-FU at the concentration of 25g/L in the region of the corneoscleral limbus has no deleterious effects on adjacent ocular tissues. This drug may be a useful for the postoperative treatment of pterygium in order to reduce recurrence or in the neoplasia treatment.

REFERENCES

- 1 Mastropasqua L, Ciancaglini M, Lobefalo L, Gallenga PE. Effectiveness of intraoperative mitomycin C in the treatment of recurrent pterygium. *Ophthalmologica*1994;208(5):247-249
- 2 Cardillo JA, Alves MR, Ambrosio LE, Poterio MB, José NK. Single intraoperative application versus postoperative mitomycin C eye drops in pterygium surgery. *Ophthalmology*1995;102(12):1949-1952
- 3 Morrow GL, Stein RM, Heathcote JG, Ikeda-Douglas JV, Feldman F. Ocular toxicity of mitomycin C and 5-fluorouracil in the rabbit. *Can J Ophthalmol*1994;29(6):268-273
- 4 Yeatts RP, Ford JG, Stanton CA, Reed JW. Topical 5-fluorouracil in the intraepithelial neoplasia of the conjunctiva and cornea. *Ophthalmology*1995;102(9):1338-1344
- 5 Ando H, Ido-Kawai Y, Yamamoto T, Kitazawa Y. Inhibition of corneal epithelial wound healing: a comparative study of mitomycin C and 5-fluorouracil. *Ophthalmology*1992;99(12):1809-1814
- 6 Mohay J, Mc Laughlin BJ. Corneal endothelial wound repair in normal and mitotically inhibited cultures. *Graefes Arch Clin Exp Ophthalmol*1995;233(11):727-736
- 7 Daniels JT, Occeleston NL, Crowston JG, Khaw PT. Effects of antimetabolite induced cellular growth arrest on fibroblasts interactions. *Exp Eye Res*1999;69(1):117-127