



Contents lists available at ScienceDirect

International Journal of Surgery Case Reports

journal homepage: www.casereports.com

A case report of venous thrombosis after kidney transplantation – We can save the graft? Time is the success factor



Paulo Roberto Kawano^a, Hamilto Akihissa Yamamoto^a, Rodrigo Gerra^a,
Paula Dalsoglio Garcia^b, Mariana Moraes Contti^b, Hong Si Nga^b,
Henrique Mochida Takase^b, Ariane Moyses Bravin^b, Luis Gustavo Modelli de Andrade^{b,*}

^a Department of Urology – UNESP, Univ Estadual Paulista, Brazil

^b Department of Internal Medicine – UNESP, Univ Estadual Paulista, Brazil

ARTICLE INFO

Article history:

Received 3 January 2017

Received in revised form 26 April 2017

Accepted 30 April 2017

Available online 19 May 2017

Keywords:

Case report

Kidney transplantation

Venous thrombosis

Thrombosis

ABSTRACT

INTRODUCTION: Venous thrombosis is a serious surgical complication that frequently results in loss of kidney graft.

CASE PRESENTATION: We report the case of a female patient recipient of a deceased kidney transplant that in the tenth postoperative presented with hematuria, graft pain and oliguria. Ultrasound examination was suggestive of venous thrombosis with abnormal doppler waveform pattern and reversal of diastolic flow. She underwent emergency surgical intervention after 2 h of diagnosis. The vein thrombus was removed by perfusing the renal graft artery with 1000 ml of Euro-Collins solution. The patient evolves with recovery of renal function after 1 week of the procedure

DISCUSSION: Similar reports of graft rescue in the vein thrombosis are scarce and that the time of diagnosis to intervention is a determining factor.

CONCLUSION: Rapid diagnosis of exactly 2 h combined with the early re-operation may be successful in preserving renal graft in cases of venous thrombosis.

© 2017 The Author(s). Published by Elsevier Ltd on behalf of IJS Publishing Group Ltd. This is an open access article under the CC BY-NC-ND license (<http://creativecommons.org/licenses/by-nc-nd/4.0/>).

1. Introduction

The renal vein thrombosis is a serious event after kidney transplantation and graft salvages depend on early diagnosis and intervention. The incidence of allograft vein thrombosis is about 3.4% and generally is higher in the first 2 weeks after transplantation [1]. There are most related to surgical complications, and allograft loss is the usual outcome [2]. The surgical exploration and transplantectomy were the most common treatment, but, there are fewer reports of graft salvage by thrombectomy or re-transplantation [2–7]. Then, to salvage the graft is necessary a high suspicion combined with a low time of diagnostic to intervention [2,8]. We report the case of one patient with venous thrombosis after kidney transplantation that with early intervention resulted in graft rescue. The paper has been reported in line with the SCARE criteria [9].

2. Case report

We report a female patient of 37 years of age and underlying disease reflux nephropathy. The patient had zero panel reactive

antibody class I and II and was submitted to kidney transplantation with deceased donor. The donor had 45 years of age and the cause of death was subarachnoid hemorrhage with final creatinine of 2.6 mg/dl (initial 0.96 mg/dl). The total cold ischemia time was 24 h and 42 min. The immunosuppression was the combination of tacrolimus with mycophenolate and prednisone. The induction therapy was done with basiliximab. The patient had normal kidney function after transplantation with the progressive fall of creatinine and good diuresis (normal control ultrasound with resistive index (RI) of 0.67). The patient in the 10 postoperative presented with severe abdominal pain, hematuria, oliguria and ultrasound showing reverse diastole in segmental arteries with absence of venous flow (Fig. 1A). The diagnostic of renal vein thrombosis was established. The patient was submitted to emergency reoperation in a time of 2 h after the onset of symptoms. The graft was found swollen and purplish with thrombus in renal vein confirming the diagnostics. The kidney graft was clamped and the artery was cannulated with Abocath 14. We performed infusion with Euro-Collins solution at 4° by renal artery resulting in output vein thrombi (Fig. 2A). Perfusion was performed until the total bleaching of the thrombus and appearance of homogeneous kidney perfusion with approximately 1000 ml of infusion solution (Fig. 2B). After we perform the suture of the renal vein and reperfused the graft with satisfactory final aspect (Fig. 2C). We performed a postoperatively ultrasound showing a reduction

* Corresponding author at: Department of Internal Medicine – UNESP, Univ Estadual Paulista, Rubião Jr, s/n – Botucatu/SP, 18.618-970, Brazil.

E-mail address: landrade@fmb.unesp.br (L.G.M. de Andrade).

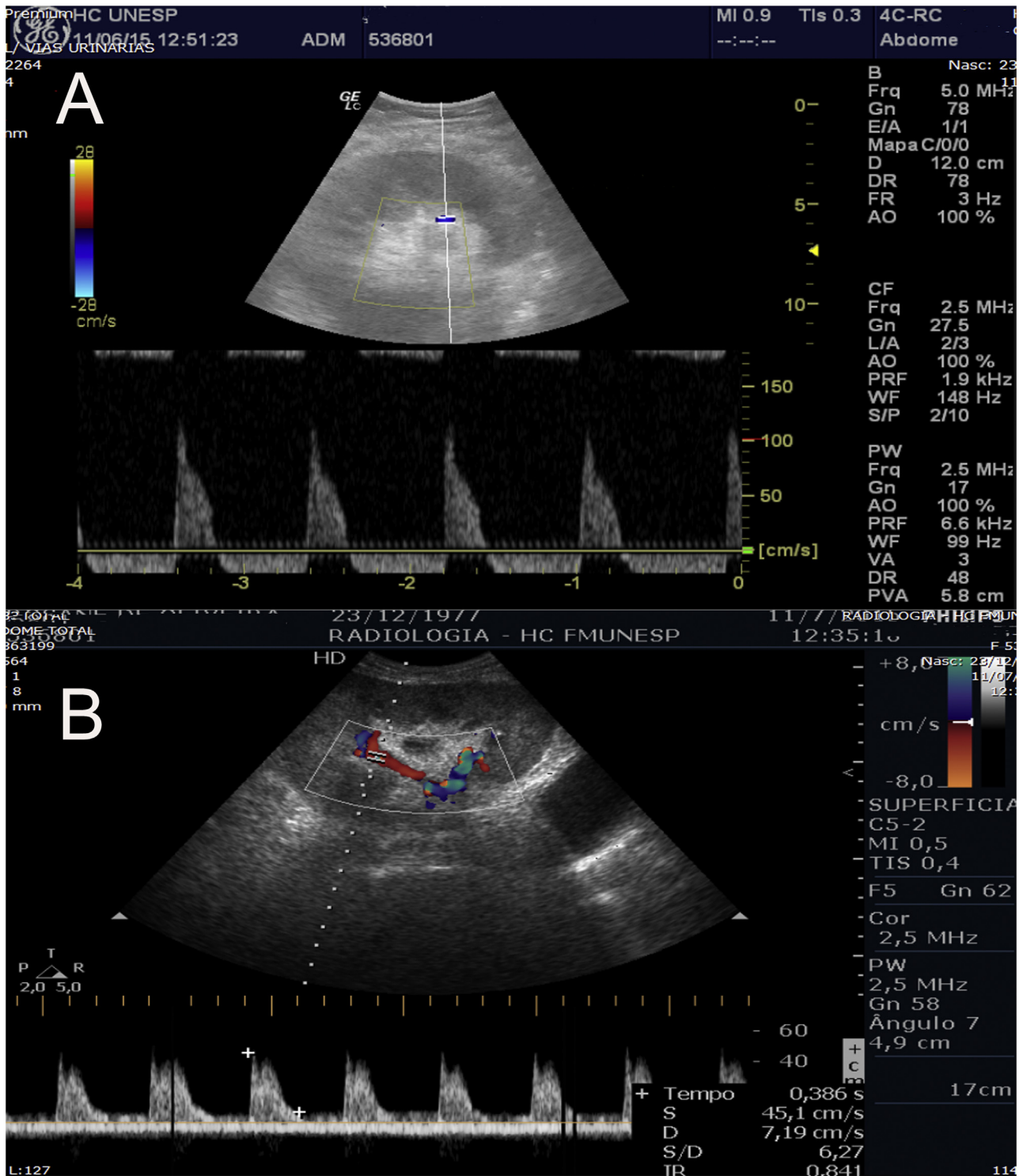


Fig. 1. The Doppler ultrasound showing increased size of the graft and reverse diastole flow in segment artery. B. Doppler ultrasound showing the presence of diastole in segmental artery and resistance index of 0.81.

in RI values and the presence of venous flow (Fig. 1B). We didn't identify causal factors related to venous thrombosis, such as renal vein kicking, hypercoagulable states or alterations in the iliac vessels. The patient recovers urine output and kidney function after 1 week. We maintained the patient with heparin anticoagulation in postoperatively until one week and after with Marevan until 3 months.

3. Discussion

The renal vein thrombosis is a rare event in kidney transplantation, but has a devastating effect. In this paper, we report a case of a patient with venous thrombosis possibly attributed to technique failure whose early surgical intervention resulted in the salvage of the graft. The etiology of venous thrombosis in this report can-

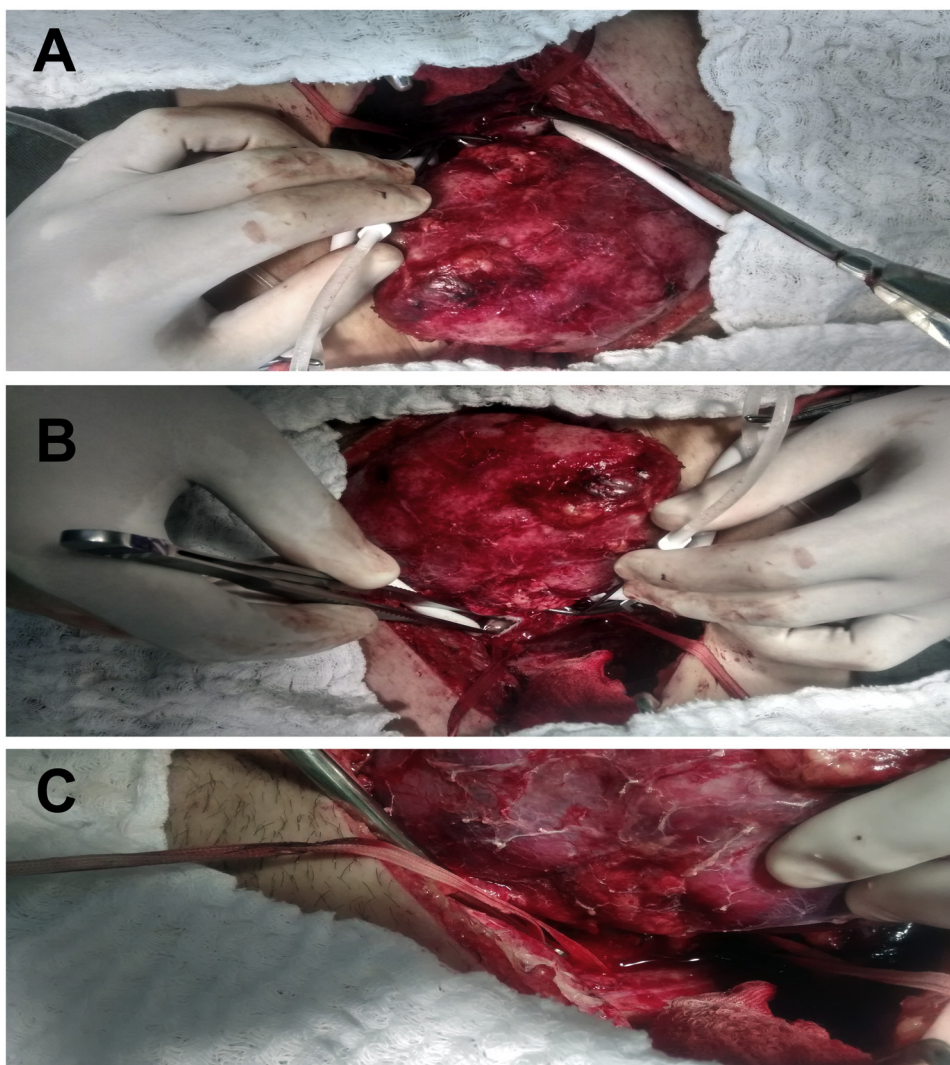


Fig. 2. Pictures showing the intraoperative renal artery clamped and cannulated with Abocath 14 made perfusion with Euro-Collins (A). Thrombus output by renal vein and the complete removal of thrombi (B). The renal reperfusion after remove the venous thrombi and released the arterial clamp (C).

not be attributed to factors associated with an increased risk of thrombosis such as pathology of the iliac vessels, graft atheroma or hypercoagulable states [8]. In similar cases of venous thrombosis the graft rescue is a rare event [2–7]. In the present case report, the fundamental to the success is the time of diagnosis to intervention [2,4–6,10]. Compared to surgery the angiographic percutaneous techniques were described with the use of thrombolytics [5,8], but other authors argue that the surgery should be the first choice. The rationale is that surgery promotes rapid removal of the thrombus and prevents bleeding complications of thrombolytic therapy [6]. Thus the diagnosis of vascular complications should be done as early as possible. We recommend the use of ultrasound that had high sensitivity and specificity in the diagnosis of vein thrombosis with abnormal doppler waveform pattern and reversal of diastolic flow [11,12]. Additional invasive radiologic studies are not necessary because they can delay a definitive diagnosis [6]. In the present case the venous thrombosis was confirmed by ultrasonograft findings combined with strong clinical suspicion and the very fast surgical intervention (2 h of diagnostics to surgery) was responsible for graft rescue. The time of diagnosis to intervention is not described in the reports, but after installing thrombosis the therapeutic window for intervention is a few hours [8,10]. Similarly Harraz et al. [8] describe that a suitable period of time for the

diagnosis to intervention which might contribute to the successful outcome was 2 h. What this report adds to the literature is the exact time of intervention from diagnosis to surgery of 2 h. In conclusion, the venous thrombosis is a rare surgical complication that frequently results in graft loss, but the rapid diagnosis and early intervention can lead to graft rescue.

Conflicts of interest

The authors declare that they have no conflict of interest in this study.

Funding

There is no any financial support for this study.

Ethical approval

The study was approved by the institutional review board (Ethics committee of UNESP, Universidade Estadual Paulista - ethics number 63799417.2.0000.5411).

Consent

Written informed consent was obtained from the patient for publication of this case report and accompanying images. A copy of the written consent is available for review by the Editor-in-Chief of this journal on request.

Authors contribution

Paulo Roberto Kawano: Participated in the performance of the research.

Hamilito Akihisa Yamamoto: Participated in the performance of the research.

Rodrigo Gerra: Participated in the performance of the research.

Paula Dalsoglio Garcia: Participated in the performance of the research.

Mariana Moraes Contti: Participated in the performance of the research.

Hong Si Nga: Analysis and interpretation of data.

Henrique Mochida Takase: Analysis and interpretation of data.

Ariane Moyses Bravin: Analysis and interpretation of data.

Luis Gustavo Modelli de Andrade: Conception and design; Final approval of the version to be published.

Guarantor

Luis Gustavo Modelli de Andrade.

References

- [1] N. Bakir, W.J. Sluiter, R.J. Ploeg, W.J. van Son, A.M. Tegzess, Primary renal graft thrombosis, *Nephrol. Dial. Transplant.* 11 (1996) 140–147.
- [2] M. Aschwanden, C. Thalhammer, S. Schaub, T. Wolff, J. Steiger, K.A. Jaeger, Renal vein thrombosis after renal transplantation—early diagnosis by duplex sonography prevented fatal outcome, *Nephrol. Dial. Transplant.* 21 (2006) 825–826.
- [3] P.J. Phelan, C. Magee, P. O’Kelly, J. O’Brien F, D. Little, P.J. Conlon, Immediate re-transplantation following early kidney transplant thrombosis, *Nephrology (Carlton)* 16 (2011) 607–611.
- [4] T. Fathi, M. Samhan, A. Gawish, F. Donia, M. Al-Mousawi, Renal allograft venous thrombosis is salvageable, *Transplant. Proc.* 39 (2007) 1120–1121.
- [5] J.P. Rerolle, C. Antoine, A. Raynaud, B. Beyssen, P. Julia, A. Duboust, et al., Successful endoluminal thrombo-aspiration of renal graft venous thrombosis, *Transpl. Int.* 13 (2000) 82–86.
- [6] E. Renoult, L. Cormier, M. Claudon, T. Cao-Huu, L. Frimat, O. Gaucher, et al., Successful surgical thrombectomy of renal allograft vein thrombosis in the early postoperative period, *Am. J. Kidney Dis.* 35 (2000) E21.
- [7] E. Renoult, C. Amicabile, B. Jonon, M. Kessler, J. L’Hermite, Early and recurrent venous graft thrombosis after kidney transplantation: benefit of an early surgery, *Clin. Nephrol.* 34 (1990) 236–237.
- [8] A.M. Harraz, A.A. Shokeir, S.A. Soliman, Y. Osman, A.S. El-Hefnawy, M.H. Zahran, et al., Salvage of grafts with vascular thrombosis during live donor renal allotransplantation: a critical analysis of successful outcome, *Int. J. Urol.* 21 (2014) 999–1004.
- [9] R.A. Agha, A.J. Fowler, A. Saeta, I. Barai, S. Rajmohan, D.P. Orgill, The SCARE statement: consensus-based surgical case report guidelines, *Int. J. Surg.* 34 (2016) 180–186.
- [10] L. Janousek, M. Kudla, J. Slatinska, O. Viklicky, J. Fronck, Kidney transplant early venous complications managed by reperfusion and re-transplantation – salvage procedure, *Bratisl Lek Listy* 115 (2014) 101–102.
- [11] S.W. Kribs, R.N. Rankin, Doppler ultrasonography after renal transplantation: value of reversed diastolic flow in diagnosing renal vein obstruction, *Can. Assoc. Radiol. J.* 44 (1993) 434–438.
- [12] P. Sadej, R.I. Feld, A. Frank, Transplant renal vein thrombosis: role of preoperative and intraoperative Doppler sonography, *Am. J. Kidney Dis.* 54 (2009) 1167–1170.

Open Access

This article is published Open Access at [sciencedirect.com](https://www.sciencedirect.com). It is distributed under the [IJSCR Supplemental terms and conditions](#), which permits unrestricted non commercial use, distribution, and reproduction in any medium, provided the original authors and source are credited.