

Free Autogenous Cartilage Grafts to the Mandible of Rats - Histological Study

Silas de TULLIO
Tetuo OKAMOTO
Mario Francisco Real GABRIELLI

*Disciplina de Cirurgia e Traumatologia Buco-Maxilo-Facial
Faculdade de Odontologia
Universidade Estadual Paulista "Julio de Mesquita Filho"
Araçatuba, SP, Brasil*

The present study was designed to histologically evaluate the behavior of free autogenous cartilage grafts to the mandible of rats. A 3-mm segment was removed from the last rib of male adult rats and transplanted fresh to a receptor bed prepared on the mandibular ramus. The results showed that the grafts maintained their vitality up to 120 days and the perichondrium was biologically integrated to the osseous bed. Appositional growth of the grafts was found. New bone formation was observed in close proximity to the grafts, but newly formed trabeculae did not arise from perichondrium.

Key Words: autogenous cartilage grafts.

Introduction

Besides bone, cartilage is another frequently used material for grafts (Dupertuis, 1941; Urist and McLean, 1952; Carvalho and Okamoto, 1979). Loeb (1926), comparing bone and cartilage grafts, observed a greater survival rate and less pronounced inflammatory reaction for cartilage. More recent studies have shown the same results (Dupertuis, 1941; Blackstone et al., 1956; Goode, 1972; Junqueira and Carneiro, 1974).

Goode (1972) considers cartilage a more malleable material, which does not need functional stimuli to maintain its bulk and position, presenting less resorption as compared to bone. Also, it does not need contact with the same tissue as bone does to survive (Kazanjian and Converse, 1975).

Thus, cartilage grafts survive in contact with bone (Alexander, 1976) and are slowly substituted by bone neof ormation (Urist and McLean, 1952; Peer, 1955; Schaffer, 1956; Blackstone et al., 1956; Harris, 1973). Boyne (1971) and Archer (1975) state that cartilage grafts are less commonly used in oral procedures due to their lesser osteogenic properties as compared to bone. However, the survival of cartilage after transplantation is one of the biological aspects of interest which has received attention from several authors. Carvalho and Okamoto (1979) compared autogenous and homogenous material with high survival

rate and a lesser degree of inflammatory infiltrate. Takai (1973) observed neof ormation of chondrocytes 720 days after transplantation. These cells presented the same morphology as mature chondrocytes, although were smaller in size. Breadon et al. (1979) suggest that the maintenance of the perichondrium is fundamental for the survival of the grafts as well as their growth. The present study was designed to detail and examine the behavior of cartilage grafts at a given site as the first of a series that will test several methods of cartilage preservation.

Materials and Methods

In the present investigation, 42 male albino Wistar rats (*Rattus norvegicus albinus*) weighing 300 to 350 g were used. The animals were kept before and during the whole experimental period on a solid diet with water *ad libitum*; except for the first 24 hours postoperatively.

Graft harvesting

Under general anesthesia, induced by intraperitoneal injection of 50 mg/kg thiopentobarbital, the left thoracic and masseteric regions were depilated. The animals were positioned in the supine position on an operating table and immobilized by the head and members in order to facilitate manipulation.

An incision was made on the skin and subcutaneous tissue with a number 15 blade and extended for approximately 10 mm over the long axis of the last ribs. The intercostal muscles were separated with scissors and the last rib (13th) was sectioned to obtain a segment of approximately 3 mm in length.

The segment removed was then freed of soft tissue attachments, maintaining the perichondrium, and placed in a flask containing saline until the host bed was prepared. 5-0 polyvicryl was used for closure of the wounds.

Grafting procedures

Still under general anesthesia, a skin and subcutaneous tissue flap was developed perpendicular to the inferior border of the mandible. The incision was approximately 10 mm in length. The exact location was determined by measuring 10 mm posteriorly and 15 mm inferiorly from the outer cantus of the eye. The muscles were separated with scissors, exposing the periosteum, which was then incised. A low speed number 703 bur, under saline irrigation, was used to obtain a 3x2-mm osteotomy.

The costal segment was transplanted to the host bed and adapted to the prepared bone cavity. A mean of 6 minutes was necessary to complete the preparation of the bed and positioning of the transplanted cartilage. The wounds were sutured with 4-0 polyvicryl and each animal received an intraperitoneal injection of 16000 IU of penicillin G benzathine.

Histological preparation

Six animals were sacrificed at the end of each experimental period, corresponding to 2, 5, 10, 20, 30, 60 and 120 days postoperatively. The specimens were dissected, fixed in 10% formalin solution for 24 hours and decalcified in sodium citrate and formic acid solution for 30 days, following routine laboratory procedures for hematoxylin and eosin staining. Six micrometer-thick sections were obtained for histological evaluation.

Results

Two days postoperatively, the cartilage was apparently vital and an intense neutrophilic infiltrate could be seen. At some sites, numerous fibroblasts and capillaries could be seen in close proximity to the graft. A moderate number of lymphocytes and plasma cells were also evident. In some cases, a small amount of clotted blood with numerous histiocytes was found.

After 5 days, the graft presented signs of vitality and in most instances the limits between perichondrium and newly formed connective tissue were poorly visible (Figure 1). Throughout, the graft was covered by newly formed connective tissue which was well vascularized and rich in fibroblasts. At some sites, however, poorly organized connective tissue and remaining blood clots were seen. In these cases, numerous histiocytes were seen exhibiting hemosiderin pigmentation. In other instances, intense lymphocytic infiltrate could be found close to the grafts.



Figure 1 - Cartilage graft presenting signs of vitality after 5 days. The limits between the graft and newly formed connective tissue are usually poorly visible. (H.E., 160X).

After 10 days, in one of the specimens, only 1/3 of the specimen seemed to be vital. The remaining area previously filled by cartilage was now occupied by well-vascularized connective tissue with newly formed bone trabeculae. In other cases, grafts were vital and showed discrete growth (Figure 2). Around the cartilage, well vascularized connective tissue, rich in fibroblasts, was seen. At several sites, however, intense bone neoformation (Figure 3) was encountered. Several times the newly formed trabeculae were very close to the graft.

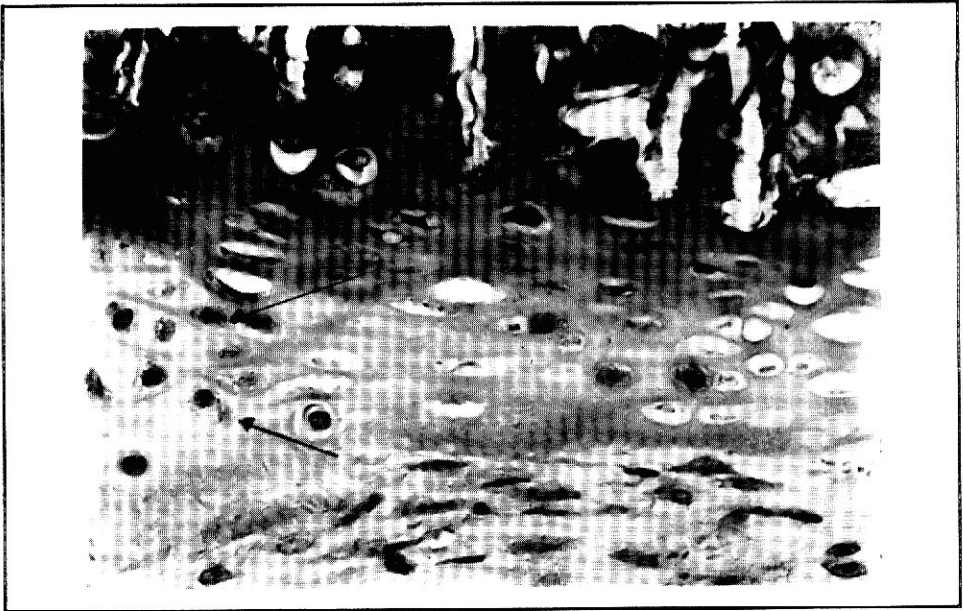

Figure 2 - After 10 days discrete growth of the graft (arrows) can be observed and the grafts are apparently vital. (H.E., 250X).

After 20 days, graft growth had progressed in most cases (Figure 4). In one of the animals, the graft was inserted in the dental papilla of the incisors and growth was very intense. In the same period, the newly formed trabeculae were in close contact with the material (Figure 5). At several sites there was no separation between cartilage and the newly formed bone.

On the 30th postoperative day, the morphological characteristics of the grafts were similar to the ones presented for the previous stage. However, the growth of the grafts was a little more pronounced. Bone neoformation in proximity to the graft was also more intense and the trabeculae were more differentiated. Besides, in some cases, small portions of cartilage covered by newly formed bone were seen, without separation. Other times, areas of cartilage were seen in contact with connective tissue without bone formation.

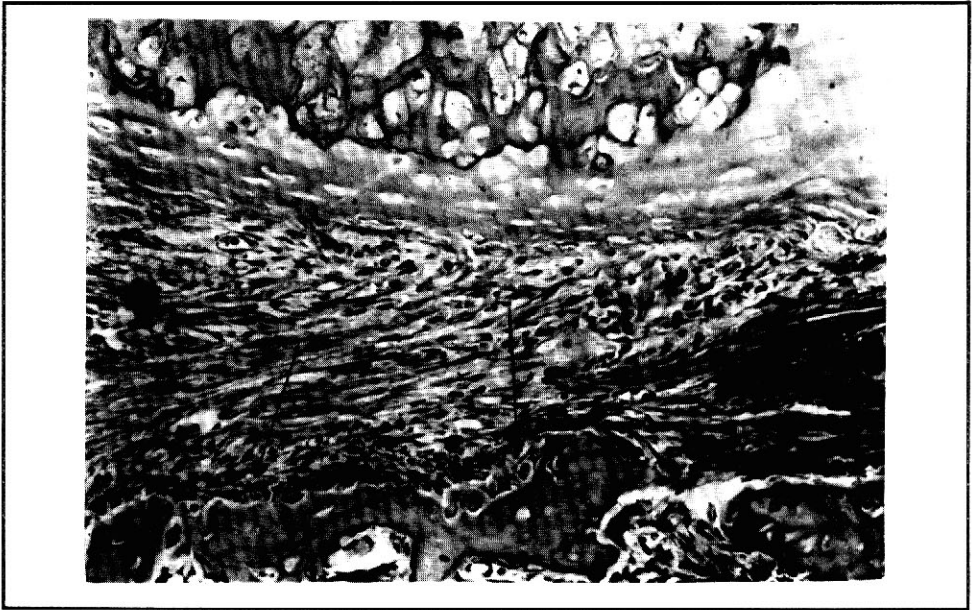


Figure 3 - 10 days. Connective tissue showing intense bone neoformation (arrow). (H.E., 160X).

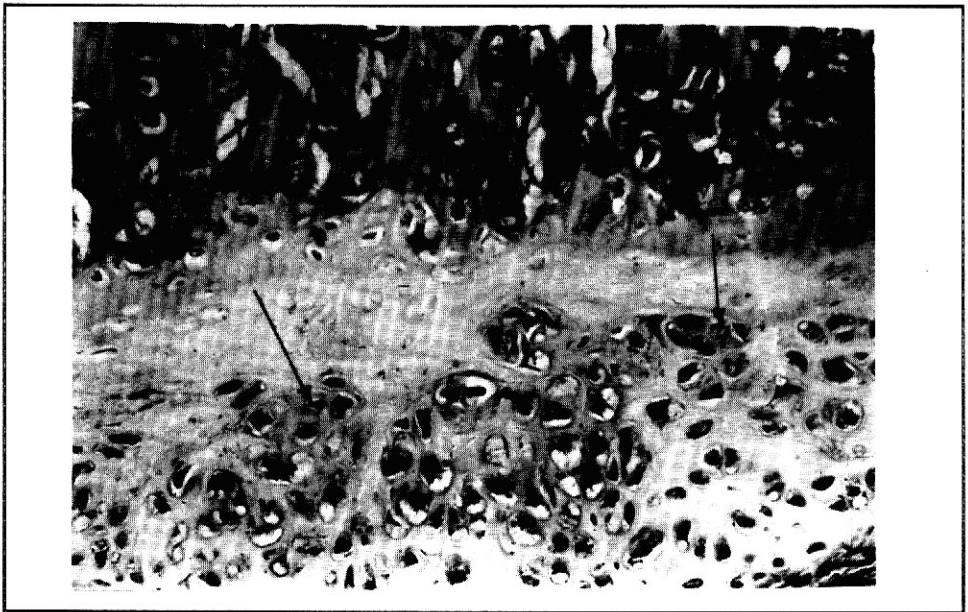


Figure 4 - After 20 days, graft growth (arrows) has progressed in most cases. (H.E., 160X).




Figure 5 - 20 days. At several sites no separation can be seen between cartilage and newly formed bone (arrows). (H.E., 160X).

After 60 days, the graft showed comparable growth to that observed in the previous stage, for all specimens. At some sites, the growth was less pronounced, especially where contact with newly formed bone had occurred (Figure 6). On the other hand, bone trabeculae were well defined close to the graft, and the osteotomy limits were not readily distinguishable.

After 120 days, the cartilage was, in most cases, included in well organized bone (Figure 7). Only at some points a small amount of connective tissue was found, without bone differentiation, between the grafts and newly formed trabeculae (Figure 8).

Discussion

The results of Peacock et al. (1960) suggest that the maintenance of the grafts occurs due to the protection of the transplanted chondrocytes by the matrix. Humphrey and White (1972) consider that homologous cartilage grafts are readily incorporated even in subjects chosen at random. Since cartilage is avascular, much of the antigenic property of the tissue is probably eliminated. The matrix is only mildly antigenic and corresponds to a physical barrier to the invasion of inflammatory cells from the host bed. Usually, hyaline cartilage does not present osteogenic induction potential (Lacroix, 1951), although that may happen with transplanted material (Shaffer and Packer, 1962a). In the present study, endochondral



Figure 6 - 60 days. Growth of the grafts is less pronounced where bone contact occurs. (I.E., 160X).

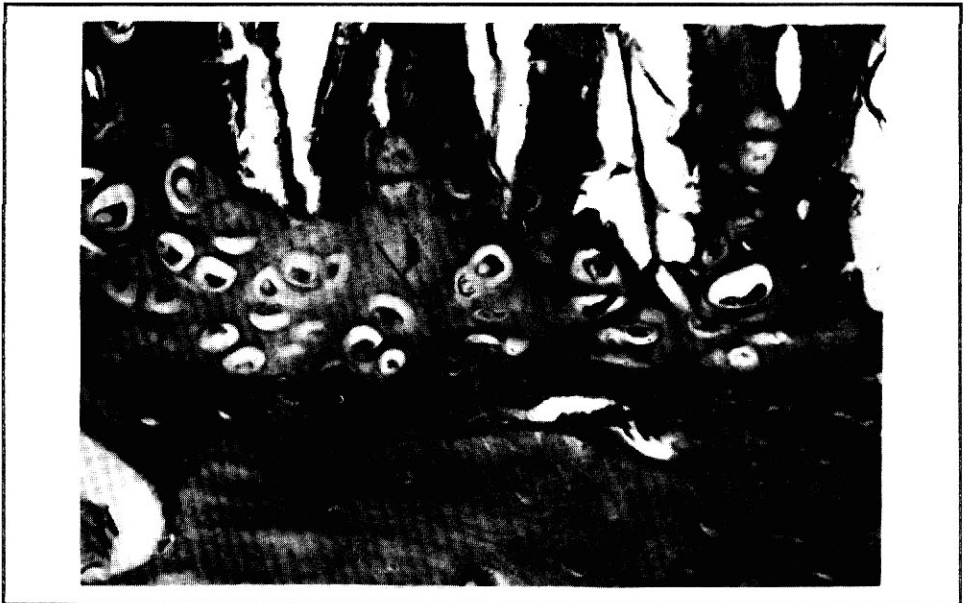

Figure 7 - 120 days. In most cases the remaining cartilage is included in well organized bone (arrows). (I.E., 160X).

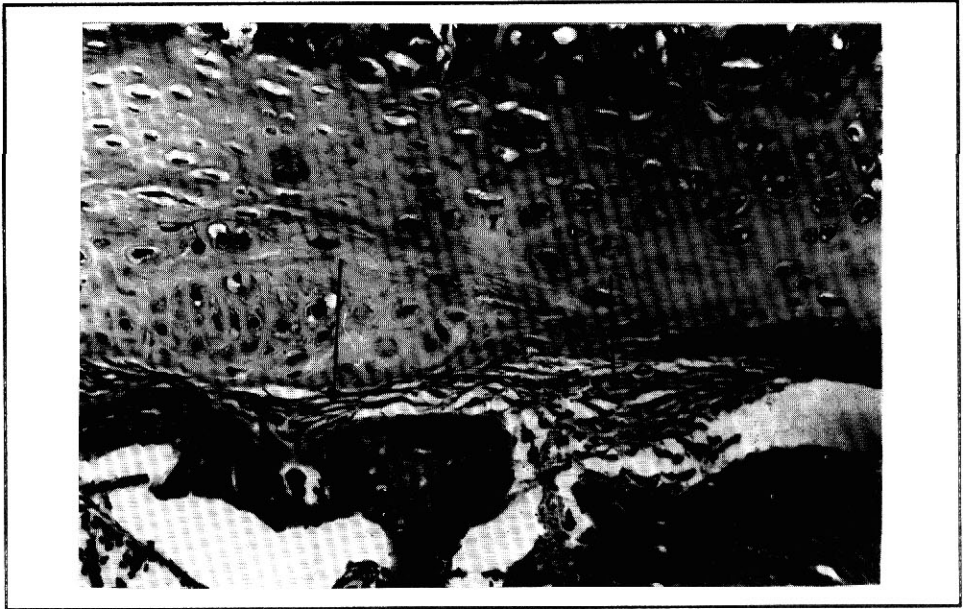


Figure 8 - 120 days. Small amount of connective tissue is found in only a few sites, between the grafts and newly formed bone (arrows). (H.E., 160X).

ossification did not occur as previously described (Urist and McLean, 1952; Peer, 1955; Shaffer and Packer, 1962a). This may occur more frequently with devitalized cartilage (Shaffer and Packer, 1962b). In the present study, both matrix and perichondrium were sound and in close contact with newly formed connective tissue indicating survival and acceptance of the graft, as one would expect in autogenous transplantation.

According to Laskin and Sarnat (1953), cartilage would survive hypoxic periods due to its low cellularity and high levels of anaerobic metabolism. Dupertius (1941) and Ham and Leeson (1963) consider the perichondrium fundamental for the survival of cartilage. It also plays a major role on appositional growth (Ham and Leeson, 1962; Junqueira and Carneiro, 1974) and stimulates marginal bone formation.

As occurs with normal tissue, we were able to find hyperplasia of the inner layer of the transplanted perichondrium and consequent growth of the graft. According to Willians (1963), the transplanted tissue may stimulate metaplasia of the host bed or differentiation of perichondrial cells. Takai (1973) observed metaplasia of host cells. In the present study, growth was appositional and derived from the transplanted perichondrium.

In only one of the specimens, after 10 days, the cartilage had been partially substituted by newly formed connective tissue, also with bone trabeculae. That was an isolated case that may reflect partial degeneration by metabolism problems. The devitalization most certainly did not inhibit osteogenesis in that case.

Schaffer (1956) reports that cartilage presents an important role in bone induction around its periphery. In the present study, the perichondrium was probably not responsible for the bone neoformation adjacent to the grafts.

On the other hand, the grafts maintained their vitality even though the host bed which was chosen was mostly compact bone, less irrigated than medullar bone, with lower osteogenic potential (Willians, 1963), and even though no means of graft fixation were used. These facts indicate a very high survival rate, although it is important to point out that the growth rates were not uniform around the whole periphery of the graft.

Conclusions

1. The grafts maintained their vitality up to 120 days.
2. The perichondrium was biologically integrated to the osseous bed.
3. Appositional growth of the grafts was found, but growth rates were not uniform around the whole periphery of the graft.

References

- Alexander JN: Alloplastic augmentation of middle third facial deformities. *J Oral Surg* 34: 165-172, 1976
- Archer WII: Oral and maxillofacial surgery. 5th ed. W.H. Saunders, Philadelphia, Vol 2: 1522-1523, 1975
- Blackstone CII, Valley C, Pareker MK: Rebuilding the resorbed alveolar ridge. *J Oral Surg* 14: 45, 1956
- Boyne PJ: Transplantation, implantation and grafts. *Dent Clin N Am* 15: 433-453, 1971
- Breadon GE, Kern EB, Neel HB: Autografts uncrushed and crushed bone cartilage. Experimental observations and clinical implications. *Arch Otolaryngol* 105: 75-80, 1979
- Carvalho ACP, Okamoto T: A histological study of cartilage autografts and allografts placed in dental sockets of rats. *J Oral Surg* 37: 11-15, 1979
- Dupertuis SM: Actual growth of young cartilage transplants in rabbits. *Arch Surg* 43: 32-63, 1941
- Goode RL: Bone and cartilage grafts: current concepts. *Otolaryng Clin N Am* 5: 447-455, 1972
- Ham AW, Leeson TS: *Histologia*. 2nd ed. Guanabara Koogan, Rio de Janeiro, 243-251, 1963
- Harris R: The reaction of the oral tissues to the implants. *Austr Dent J* 18: 143-151, 1973
- Humphrey JII, White RG: *Imunologia médica*. 3rd ed. Guanabara Koogan, Rio de Janeiro, 639, 1972
- Junqueira LC, Carneiro J: *Histologia básica*. 3rd ed. Guanabara Koogan, Rio de Janeiro, 122-131, 1974
- Kazanjian VII, Converse JM: Surgical treatment of facial injuries. 3rd ed. Williams and Wilkins, Baltimore, Vol 1: 561-564, 1975
- Lacroix P: The organization of bones. Blakiston Co., Philadelphia, 145, 1951
- Laskin DM, Samat BG: The metabolism of fresh, transplanted, and preserved cartilage. *Surg Gynec Obst* 96: 493-499, 1953
- Loeb L: Autotransplantation and homotransplantation of cartilage in the guinea pig. *Am J Pathol* 2: 111-122, 1926
- Peacock Jr EE, Weeks PM, Petty JM: Some studies on the antigenicity of cartilage. *Ann N Y Acad Sci* 87: 175-183, 1960
- Peer LA: Transplantation of tissue. Williams and Wilkins, Baltimore, Vol 1: 65-137, 1955

- Schaffer EM: Cartilage transplants into the periodontium of rhesus monkeys. OS, OM and OP 9: 1233-1246, 1956
- Schaffer EM, Packer MW: Bone regeneration and tooth grafts in periodontal pockets. Dent Clin N Am. W.B. Saunders Co., 459-469, 1962a
- Schaffer EM, Packer MW: Periodontal regeneration with cartilage implants. Dent Prog 2: 76-81, 1962b
- Takal Y: Experimental study on cartilage transplantation. I. Auto-transplantation and homo-transplantation of ear cartilage in immature rabbits. Aichi Gakuin J Dent Sci 11: 18-19, 1973
- Urist MR, McLean FC: Osteogenic potency and new bone formation by induction in transplants to the anterior chamber of the eye. J Bone Joint Surg 34a: 443-476, 1952
- Willians RG: Studies of cartilage and osteoid arising spontaneously and experimental attempts to induce their formation in ear chambers. Anat Rec 146: 93-107, 1963

Correspondence: Professor Mario Francisco Real Gabrielli, Disciplina de Cirurgia e Traumatologia Buco-Maxilo-Facial, Faculdade de Odontologia, UNESP, Campus de Araçatuba, Rua José Bonifácio, 1193, 16100 Araçatuba, SP, Brasil.

Accepted June 8, 1992