UNIVERSIDADE ESTADUAL PAULISTA
“JÚLIO DE MESQUITA FILHO”
FACULDADE DE CIÊNCIAS AGRÁRIAS E VETERINÁRIAS
CÂMPUS DE JABOTICABAL

USO DE ESPONJA CIRÚRGICA EM ENXERTOS CUTÂNEOS ASSOCIADO AO PLASMA RICO EM PLAQUETAS EM COELHOS (*Oryctolagus cuniculus*)

Josiane Morais Pazzini
Médica Veterinária

2017

UNIVERSIDADE ESTADUAL PAULISTA
“JÚLIO DE MESQUITA FILHO”
FACULDADE DE CIÊNCIAS AGRÁRIAS E VETERINÁRIAS
CÂMPUS DE JABOTICABAL

USO DE ESPONJA CIRÚRGICA EM ENXERTOS CUTÂNEOS ASSOCIADO AO PLASMA RICO EM PLAQUETAS EM COELHOS (*Oryctolagus cuniculus*)

Josiane Morais Pazzini

Orientador: Prof° Dr. Andrigo Barboza De Nardi

Co-orientadora: Profª Dra.Paola Castro Moraes

Tese apresentada à Faculdade de Ciências Agrárias e Veterinárias – UNESP, Câmpus de Jaboticabal, como parte das exigências para a obtenção do título de Doutora em Cirurgia Veterinária.

2017

Pazzini, Josiane Morais
P348u Uso de esponja cirúrgica em enxertos cutâneos associado ao plasma rico em plaquetas em coelhos (O*ryctolagus cuniculus*) / Josiane Morais Pazzini. – – Jaboticabal, 2017
ix, 74 p. : il. ; 29 cm

Tese (doutorado) - Universidade Estadual Paulista, Faculdade de Ciências Agrárias e Veterinárias, 2017
Orientador: Andrigo Barboza De Nardi
Banca examinadora: Bruno Watanabe Minto, Jorge Luiz Costa Castro, Rafael Ricardo Huppes, Pâmela Rodrigues Reina Moreira.
Bibliografia

1. Enxertos cutâneos. 2. Curativo compressivo. 3. Angiogênese. 4. PRP. 5. Coelhos. I. Título. II. Jaboticabal-Faculdade de Ciências Agrárias e Veterinárias.

CDU 619:616.5:636.92

Ficha catalográfica elaborada pela Seção Técnica de Aquisição e Tratamento da Informação– Serviço Técnico de Biblioteca e Documentação - UNESP, Câmpus de Jaboticabal.

UNIVERSIDADE ESTADUAL PAULISTA

Câmpus de Jaboticabal

CERTIFICADO DE APROVAÇÃO

TÍTULO: USO DE ESPONJA CIRÚRGICA EM ENXERTOS CUTÂNEOS ASSOCIADO AO PLASMA RICO EM PLAQUETAS EM COELHOS *(Oryctolagus cuniculus)*

AUTORA: JOSIANE MORAIS PAZZINI
ORIENTADOR: ANDRIGO BARBOZA DE NARDI
COORIENTADORA: PAOLA CASTRO MORAES

Aprovada como parte das exigências para obtenção do Título de Doutora em CIRURGIA VETERINÁRIA, pela Comissão Examinadora:

Prof. Dr. ANDRIGO BARBOZA DE NARDI
Departamento de Clinica e Cirurgia Veterinária / FCAV / UNESP - Jaboticabal

Prof. Dr. RAFAEL RICARDO HUPPES
Departamento de Clínica e Cirurgia Veterinária / UNICESUMAR - Maringá/PR

Prof. Dr. JORGE LUIZ COSTA CASTRO
Departamento de Cirurgia Veterinária / PUC/Pontifícia Universidade Católica do Paraná - Curitiba/PR

Prof. Dr. BRUNO WATANABE MINTO
Departamento de Clinica e Cirurgia Veterinária / FCAV / UNESP - Jaboticabal

Profa. Dra. PAMELA RODRIGUES REINA MOREIRA
Departamento de Patologia Veterinária / FCAV / UNESP - Jaboticabal

Jaboticabal, 23 de março de 2017.

DADOS CURRICULARES DA AUTORA

JOSIANE MORAIS PAZZINI – filha de Antonio Celso Pazzini e Roseli Prado de Morais Pazzini, nasceu em São José dos Campos – SP, no dia 02 de Dezembro de 1988. Formada pela Faculdade Doutor Francisco Maeda – FAFRAM, em julho de 2012. Mestre em Cirurgia Veterinária, Área de Concentração em Cirurgia Reconstrutiva, pela Faculdade de Ciências Agrárias e Veterinárias – UNESP – Câmpus de Jaboticabal, SP, em fevereiro de 2014. Em Março de 2014 iniciou o curso de Doutorado em Cirurgia Veterinária, Área de Concentração em Cirurgia Reconstrutiva, pela Faculdade de Ciências Agrárias e Veterinárias – UNESP – Câmpus de Jaboticabal, SP. Atendeu no Serviço de Oncologia Veterinária na Faculdade de Ciências Agrárias e Veterinárias – UNESP – Câmpus de Jaboticabal, SP durante o período da pós graduação. Realizou um período de mobilidade na Universidade do Porto, Portugal, no laboratório de Patologia Veterinária, de Setembro de 2015 à Agosto de 2016, pelo Programa de Doutorado Sanduíche no Exterior – PDSE financiado pela Capes.

Dedico este trabalho aos meus pais
Antônio Celso Pazzini e Roseli Prado de Morais Pazzini,
a minha irmã Juliana Morais Pazzini,meu avô e ao Eduardo Luis Serafim
que com o amor e carinho
sempre me apoiaram nas minhas conquistas.

AGRADECIMENTOS

À Deus que sempre esteve me guiando e iluminando durante o caminho para tudo dar certo.

Aos meus pais pela força e incentivo na minha formação.

Ao Eduardo Serafim pela força, carinho e compreensão durante toda essa caminhada.

Aos amigos e companheiros das cirurgias, anestesiologia, patologia e estatística, Rafael Ricardo Huppes, Vivian Tavares, Camila Pinto Baltazar da Silveira, Ricardo Uscategui, Marília Ferreira, Nazilton Reis, Luciana Sfrizzo,João Ademir e Alfredo Calpaa.

Às minhas coorientadoras Profª Paola Castro Moraes e Profª Dr. Fátima Gartner, pelo apoio na execução do meu experimento, amizade e contribuição na minha formação profissional.

Às minhas amigas do laboratório de Patologia Veterinária da Universidade do Porto Fátima Faria e Alexandra Rêma pelo apoio na execução do meu experimento e amizade.

À Profª Drª. Irina Amorim pelo apoio na execução do meu experimento, contribuição na minha formação profissional e amizade.

À Faculdade de Ciências Agrárias e Veterinárias (FCAV); à Universidade do Porto; Departamento de Clínica e Cirurgia Veterinária, Serviço de Oncologia Veterinária e a Pós Graduação.

Aos funcionários da Faculdade de Ciências Agrárias e Veterinárias (FCAV) Lauro César, Márcia, Dona Izilda, Carlos e Edson que colaboraram na realização deste trabalho

À Capes e ao Cnpq pela concesão da bolsa de doutorado, e à Capes pela bolsa do PDSE.

Àqueles que, direta e indiretamente, colaboraram na realização deste trabalho.

SUMÁRIO

LISTA DE ABREVIATURAS iv

LISTA DE FIGURAS v

LISTA DE TABELAS vii

RESUMO viii

ABSTRACT ix

CAPÍTULO 1 – Considerações gerais 1

1.1 Introdução 1

1.2 Objetivos 3

1.3 Referências 3

CAPÍTULO 2 – Skin grafts associated with platelet rich plasma and surgical sponge - Literature Review 5

CAPÍTULO 3 – Esponja cirúrgica associada com plasma rico em plaquetas em enxertos cutâneos em malha e camada em coelhos (*Oryctolagus cuniculus)* 15

RESUMO 16

ABSTRACT 16

Introduction 16

Material and methods 17

Results and Discussion 20

Conclusions 26

Referências 27

CAPÍTULO 4 – Using layer grafts and mesh grafts to correct significant defects induced in the carpals of rabbits (*Oryctolagus Cuniculus*) by associating platelet-rich plasma 30

ABSTRACT 31

Introduction 31

Material and methods 32

Statistical analysis 34

Results and Discussion 35

Conclusions 39

Author's contribution 39

Acknowledgements 39

References.....40

CAPÍTULO 5 – Histochemical and immunohistochemical evaluation of angiogenesis in rabbits having undergone skin grafts associated with platelet-rich plasma 42

ABSTRACT .– 42

RESUMO.- 42

INTRODUCTION 43

MATERIAL AND METHODS 44

RESULTS AND DISCUSSIONS 46

CONCLUSIONS 48

Acknowledgements. 48

REFERENCES 48

CAPÍTULO 6 – Emprego de plasma rico em plaquetas associado à esponja cirúrgica em enxertos cutâneos em coelhos (Oryctolagus cuniculus)* 50

ABSTRACT.- 50

RESUMO. 51

MATERIAL E MÉTODOS 53

RESULTADOS 61

DISCUSSÃO 63

CONCLUSÃO 65

Agradecimentos.....65

REFERÊNCIAS 65

CAPÍTULO 7 – Considerações finais 67

ANEXO I 68

ANEXO II 71

ANEXO III 73

ANEXO IV 74

unesp
UNIVERSIDADE ESTADUAL PAULISTA
"JÚLIO DE MESQUITA FILHO"
Câmpus de Jaboticabal

CEUA – COMISSÃO DE ÉTICA NO USO DE ANIMAIS

CERTIFICADO

Certificamos que o Protocolo nº 11767/14 do trabalho de pesquisa intitulado **"Uso de esponja cirúrgica em enxertos cutâneos associado ao plasma rico em plaquetas em coelhos (*Oryctolagus cuniculus*)",** sob a responsabilidade do Prof. Dr. Andrigo Barboza De Nardi está de acordo com os Princípios Éticos na Experimentação Animal adotado pelo Conselho Nacional de Controle de Experimentação Animal (CONCEA) e foi aprovado pela COMISSÃO DE ÉTICA NO USO DE ANIMAIS (CEUA), em reunião ordinária de 07 de julho de 2014.

Jaboticabal, 07 de julho de 2014.

Prof.ª Dr.ª Paola Castro Moraes
Coordenadora – CEUA

Faculdade de Ciências Agrárias e Veterinárias
Via de Acesso Prof. Paulo Donato Castellane, s/n CEP 14884-900 - Jaboticabal - SP - Brasil
Tel. 16 3209 2600 - fax 16 3202 4275 www.fcav.unesp.br

LISTA DE ABREVIATURAS

cm: Centímetro

EGF: Fator de crescimento de endotelial

Fcs: Fator de crescimento

FGF: Fator de crescimento fibroblástico

Gcc: Grupo controle em camada

Gcce: Grupo controle em camada com esponja cirúrgica

Gprpc: Grupo plasma rico em plaquetas em camada

Gprpce: Grupo plasma rico em plaquetas em camada com esponja cirúrgica

Gcm: Grupo controle em malha

Gprpm: Grupo plasma rico em plaquetas em malha

Gprpme: Grupo plasma rico em plaquetas em camada com esponja cirúrgica

Gcme: Grupo controle em malha com esponja cirúrgica

HE: Hematoxilina e eosina

IGF: Fator de crescimento semelhante à insulina

kg: Quilograma

KGF: Fator de crescimento de queratinócitos

L: Litro

mg: Miligrama

min: Minuto

mL: Mililitro

mm: Milímetro

PDGF: Fator de crescimento derivado das plaquetas

PPP: Plasma pobre em plaquetas

PRP: Plasma rico em plaquetas

RPM: Rotação por minuto

TGFβ: Fator de crescimento tranformador beta

µm: micrômetros

µL: microlitros

VEGF: Fator de crescimento endotelial vascular

LISTA DE FIGURAS

CAPÍTULO 2

Figura 1 Images of the lesion in the left forelimb in carpal region of rabbits (Oryctolagus cuniculus) showing the necrosis macroscopic variables with 15 days that were submitted to the reconstructive surgery..... 7

Figura 2 Images of the lesion in the left forelimb in carpal region of rabbits (Oryctolagus cuniculus) showing the pressure dressing used sponge (Arrow) with 15 days that were submitted to the reconstructive surgery..... 9

Figura 3 Images of platelet-rich plasma (PRP) 11

CAPÍTULO 3

Figura 1 Photographic images of the lesion in the left forelimb in carpal region of rabbits (Oryctolagus cuniculus) showing the edema macroscopic variables with three days that were significant between groups (*p<0.05*) submitted to the reconstructive surgery..... 21

Figura 2 Histology of vascular proliferation intensity in rabbits (Oryctolagus cuniculus). Photomicrography optical dermal animals submitted to reconstructive surgery..... 23

Figura 3 Histology of vascular proliferation in rabbits (Oryctolagus cuniculus). Photomicrography optical dermal animals submitted to reconstructive surgery..... 24

CAPÍTULO 4

Figura 1 Histology of vascular proliferation in rabbits (Oryctolagus cuniculus). Photomicrography optical dermal animals submitted to reconstructive surgery..... 36

Figura 2 Colagenous in rabbits (Oryctolagus cuniculus). Photomicrography optical polarized light of the dermis of animals submitted to reconstructive surgery..... 38

CAPÍTULO 5

Figura 1 Histologic aspect of vascular proliferation intensity in rabbits (Oryctolagus cuniculus). Photomicrograph perspective of animal dermis submitted to the reconstructive surgery..... 46

Figura 2 Histologic aspect of microvessel count (MVC) in rabbits (Oryctolagus cuniculus). Photomicrography optical dermal animals submitted to the reconstructive surgery..... 47

CAPÍTULO 6

Figura 1 Imagens fotográficas da diérese do procedimento cirúrgico de reconstrução 55

Figura 2 Imagens fotográficas da diérese do procedimento cirúrgico de reconstrução..... 56

Figura 3 Imagens fotográficas da diérese e síntese do procedimento cirúrgico de reconstrução..... 58

Figura 4 Imagens fotográficas da lesão no membro torácico esquerdo na região do carpo de coelhos (*Oryctolagus cuniculus*) mostrando as variáveis macroscópicas exsudato com 3 dias que foram significativas entre os grupos ($p<0,05$) submetidos ao procedimento de cirurgia reconstrutiva..... 62

Figura 5 Aspecto histológico da Intensidade de proliferação vascular em coelhos (*Oryctolagus cuniculus*). Fotomicrografia óptica da derme de animais do Gprpme e Gcme submetidos ao procedimento de cirurgia reconstrutiva..... 63

LISTA DE TABELAS

CAPÍTULO 3

Tabela 1 Antibodies used for immunohistochemistry cutaneous tissues of rabbits conducted in Veterinary Pathology Laboratory of the University of Porto, Portugal……..... 19

CAPÍTULO 4

Tabela 1 Antibodies used for immunohistochemistry cutaneous tissues of rabbits conducted in Veterinary Pathology Laboratory of the University of Porto, Portugal…….. 34

CAPÍTULO 5

Tabela 1 Antibodies used for immunohistochemistry cutaneous tissues of rabbits conducted in Veterinary Pathology Laboratory of the University of Porto, Portugal…….. 45

USO DE ESPONJA CIRÚRGICA EM ENXERTOS CUTÂNEOS ASSOCIADO AO PLASMA RICO EM PLAQUETAS EM COELHOS (*Oryctolagus cuniculus*)

RESUMO – Enxertos cutâneos são segmentos da epiderme e derme completamente removido da região doadora e transferidos para o local receptor, sem a presença de pedículo vascular. O curativo compressivo é recomendado por otimizar o contato do enxerto com o leito da ferida. O sucesso da cicatrização dos enxertos depende de adequada angiogênese, e por serem desprovidos de pedículo vascular o procedimento cirúrgico pode ser comprometido. Assim, para evitar complicações o plasma rico em plaquetas (PRP) é uma substância que estimula a angiogênese e auxilia na reparação tecidual. Sendo assim, delineou-se um estudo a fim de avaliar a eficácia do gel de PRP associado com esponjas cirúrgicas favorecerem a integração do enxerto ao leito receptor nos modelos de enxertos em camada e malha. Foi realizado no Hospital Veterinário da UNESP, câmpus de Jaboticabal – SP, um estudo com 64 coelhos, separados em oito grupos, com oito animais, todos submetidos à técnica de cirurgia reconstrutiva para confecção de enxerto. Os grupos foram compreendidos em: Gprpc (gel de PRP sem associação da esponja cirúrgica no enxerto de camada), Gprpce (gel de PRP associado com esponja cirúrgica como forma de curativo no enxerto de camada), Gcc (solução fisiológica 0,9% sem associação da esponja cirúrgica no enxerto de camada), Gcce (solução fisiológica 0,9% associada com esponjas cirúrgicas no enxerto de camada), Gprpm (gel de plasma PRP sem associação da esponja cirúrgica no enxerto de malha), Gprpme (gel de PRP associado com esponja cirúrgica como forma de curativo no enxerto de malha), Gcm (solução fisiológica 0,9% sem associação da esponja cirúrgica no enxerto de malha), e Gcce (solução fisiológica 0,9% associada com esponjas cirúrgicas no enxerto de malha). Realizaram-se avaliações macroscópicas das lesões após três, sete e 14 dia. Realizou-se as avaliações microscópicas com 15 dias do procedimento cirúrgico após a eutanásia dos animais. Os dados obtidos foram submetidos à análise estatística (teste t emparelhado, teste de Kruskal-Wallis, análise de variância (teste F), teste de Tukey, sendo $p<0,05$). A concentração plaquetária da amostra final do PRP foi significativa quando comparada com a inicial, indicando aumento do número de plaquetas; presença de edema foi significativa nos grupos Gprpc e Gcce com 3 e 7 dias; exsudato foi significativo no 3º e 7º no Gprpme e Gprpm; coloração no 14º dia foi signifivativa no Gprpm e Gprpc; aspecto cosmético no 7º dia foi significativo no Gprpce e no 14º dia foi significativo no Gprpc e Gcc; presença das células mononucleares foi significativo no Gcme; presença de polimorfonucleares foi significativa no Gcme e Gcc; proliferação de fibroblastos foi significativa no Gprpc e Gprpm; a colagenização avaliando colágeno tipo I e III houve diferença significativa, sendo presença significativa o tipo I no Gprpme; hemorragia foi significativa no Gcme.Dessa forma, conclui-se que o emprego do plasma rico em plaquetas na forma de gel em enxertos cutâneos associando no pós-operatório esponjas cirúrgicas como curativo compressivo favorecerem sua integração ao leito receptor sem a presença prévia de tecido de granulação.

Palavras-chave: Enxertos cutâneos, curativo compressivo, angiogênese, PRP, coelho.

USE OF SURGICAL SPONGE IN SKIN GRAFTS ASSOCIATED WITH PLATELETS RICH PLASMA ON RABBIT (Oryctolagus cuniculus)

ABSTRACT - Skin grafts are segments of the epidermis and dermis completely removed from the donor region and transferred to the receptor site without the presence of vascular pedicle. Pressure dressing after surgery is recommended to optimize the contact of the graft to the wound bed, and allow proper angiogenesis. The success of the healing of the grafts depends on proper angiogenesis, and being devoid of vascular pedicle the surgical procedure may be compromised. Thus, to avoid complications platelet rich plasma (PRP) is a substance that has been investigated for having angiogenesis factors which stimulate and aid in tissue repair. Thus, it outlined a study to assess the efficacy of PRP gel employment associated with surgical sponges to improve the integration of the graft in the recipient bed models grafts mesh and tier. It was held at the Veterinary Hospital UNESP, campus of Jaboticabal - SP, a study of 64 rabbits, divided into eight groups with eight animals, all underwent reconstructive surgery technique for making graft. The groups were comprised of: Gprpc received PRP gel unassociated surgical sponge in the tier graft, Gprpce received PRP gel associated with surgical sponge as a way of dressing in tier graft, Gcc received 0.9% saline without association surgical sponge in tier graft, Gcce received 0.9% saline solution associated with surgical sponges in the tier graft, Gprpm received plasma PRP gel unassociated surgical sponge in mesh graft, Gprpme received PRP gel associated with surgical sponge as way of dressing in mesh graft, Gcm receive 0.9% saline solution without associated surgical sponge in mesh graft and Gcce receive 0.9% saline solution associated with surgical sponges in mesh graft. Evaluations were performed macroscopic lesions after three, seven, and 14 days of surgery. To evaluate the wound healing took place microscopic evaluations with 15 days of surgery after euthanasia of animals. The data were submitted to statistical analysis (paired t test, Kruskal-Wallis test, F test, Tukey test, $p < 0.05$). Platelet concentration of PRP final sample was significant when compared to the baseline, indicating an increase in platelets; edema was significant in Gprpc and Gcce with 3 and 7 days, respectively; exudate was significant in 3rd and 7th in Gprpme and Gprpm respectively; coloring on the 14th day was significant in Gprpm and Gprpc; cosmetic appearance on the 7th day was significant in Gprpce and at day 14 was significant in Gprpc and Gcc; presence of mononuclear cells was significant in Gcme; presence of polymorphonuclear, was significant in Gcme and Gcc; fibroblast proliferation was significant in Gprpc and Gprpm; colagenous evaluating collagen type I and III were no significant differences when compared, with a significant presence in the type I in Gprpme; hemorrhage was significant in Gcme. It is concluded that the use of platelet-rich plasma in the form of gel skin grafts involving postoperative surgical sponge as a pressure dressing to improve the integration of the graft to the receptor without previous presence of granulation tissue.

Keywords: Skin grafts, compressive dressing, angiogenesis, PRP, rabbit.

CAPÍTULO 1 – Considerações gerais

1.1 Introdução

As cirurgias reconstrutivas são constituídas por diversas técnicas, as quais podem ser utilizadas para reparar defeitos extensos que comprometam a cicatrização. Assim, nesses casos o emprego de retalhos ou enxertos de pele são opções de tratamento (PAVLETIC, 2010).

Os retalhos consistem de uma porção de tecido que é removido parcialmente do seu local de origem e transferido para outro (leito receptor) onde irá recobrir o defeito. A grande vantagem de empregar os retalhos cutâneos é pela cobertura imediata da região afetada, além de reduzirem o tempo de cicatrização do tecido, proporcionando ao paciente melhores resultados estéticos e funcionais (HEDLUND, 2005).

Logo os enxertos são segmento da epiderme e da derme que são completamente removidos do local doador e transferidos para o local receptor (HEADLUND, 2008). Entretanto, por serem desprovidos de artéria e veia na sua constituição são muito prejudicados pela necrose e isquemia após serem implantados no leito receptor (POPE, 1996).

Segundo Almeida et al. (2004), a vascularização dos retalhos e enxertos é importante e muito discutida, as proporções de comprimento e largura dos retalhos são de fundamental determinação de sua viabilidade, pois quando este é extenso, ocorre comprometimento vascular e as regiões distais ficam sem irrigação sanguínea, ocasionando necrose nas margens distais. Já os enxertos, por serem desprovidos de artéria e veia na sua constituição, são prejudicados pela necrose após serem implantados no leito receptor (TOBIAS, 2011). Diante desses problemas, muitos autores têm relatado o uso de substâncias que visam melhorar a cicatrização, por meio da estimulação de angiogênese, empregando o plasma rico em plaquetas (PRP) nas feridas cirúrgicas (VENDRAMIN et al., 2010; PAZZINI et al., 2016a).

A confecção dos enxertos é feita somente com presença do tecido de granulação saudável no leito receptor, no entanto, essa condição torna o procedimento demorado em virtude de ser realizado em três etapas: primeiro

realizando a desinfecção da ferida, na sequência aguardar presença de tecido de granulação, e por fim a correção cirúrgica (PAZZINI et al., 2015). Após o procedimento cirúrgico o emprego de curativo é fundamental, visto que os enxertos são desprovidos de pedículo vascular, e assim utilizando curativos compressivos é possível otimizar o contato do enxerto com o leito da ferida e permitir adequada angiogênese (PAZZINI et al., 2015).

O curativo também reduz a possibilidade de deslocamentos do enxerto, bem como reduz a presença de hematomas e seromas, eventos que habitualmente conduzem à perda da viabilidade do enxerto, e posteriormente sua falência (PAZZINI et al., 2015). Sendo assim, os curativos compressivos mais usados são *Tie over* (FOSSUM, 2007), que consiste em suturar o material sobre a ferida cirúrgica, podendo ser feito com algodão, gazes, espumas e esponjas cirúrgicas. A idéia das esponjas cirúrgicas ou espumas é prática, por distribuir uniformemente a pressão na ferida (ZANINI, 2004), e favorecer a cicatrização e integração do enxerto ao leito receptor.

Dessa forma, deliniou-se um estudo a fim de utilizar o gel produzido a partir do plasma rico em plaquetas (PRP) em enxertos cutâneos de espessura completa do tipo camada e em malha associando esponjas cirúrgicas no curativo, para avaliar a possibilidade de favorecer a integração do enxerto no leito receptor por meio da estimulação da angiogênese sem a presença prévia de tecido de granulação.

O presente estudo será apresentado em forma de capítulos em virtude da extensão do material, e por facilitar o entendimento, bem como sendo um conteúdo que está submetido e também aceito para publicação em periódicos.

1.2 Objetivos

- Avaliar a eficácia do gel produzido a partir do plasma rico em plaquetas (PRP) em enxertos cutâneos de espessura completa do tipo malha e camada em coelhos (*Oryctolagus cuniculus*), associando no pós-operatório esponjas cirúrgicas como curativo compressivo.

- Avaliar a angiogênese local onde o procedimento foi realizado.

- Avaliar se o PRP e as esponjas cirúrgicas favorecem a integração do enxerto ao leito receptor sem a presença prévia de tecido de granulação.

- Avaliar os diferentes métodos de identificação da angiogênese em coelhos.

1.3 Referências[1]

ALMEIDA, K.G.; FAGUNDES,D.J.; MANNA, M.C.B; MONTERO, E.F.S. Ação do dimetil-sulfóxido na isquemia de retalhos randômicos de pele em ratos. **Acta Cirúrgica Brasileira**, v.19, n.6, 2004.

FOSSUM, T.W (2007). **Cirurgia de pequenos animais:** In: FOSSUM, T.W. Cirurgias reconstrutivas. 3. ed. São Paulo: Roca. Cap.18, p. 135-186, 2007.

HEDLUND, C.S. Cirurgia do sistema tegumentar. In: Fossum, TW. Cirurgia **de pequenos animais.** 3ª Ed. São Paulo: Elsevier; 2008; p. 224-278.

HEDLUND, C.S. Cirurgia dos Sistema tegumentar. In: FOSSUM,T.W. **Cirurgia de pequenos animais.** 2.ed. São Paulo: Roca, 2005. Cap. 18, p.135-230.

PAZZINI, J.M; DE NARDI, A.B; HUPPES, R.R; GERING, A.P; FERREIRA, M.G.P.A; SILVEIRA, C.B.P; LUZZI, M.C; OLIVEIRA, J.A. Utilização de plasma rico em plaquetas para estimulação da angiogênese em flape de padrão axial toracordosal

[1] ASSOCIAÇÃO BRASILEIRA DE NORMAS TÉCNICAS. *NBR 6023*: informação e documentação: referências: elaboração. Rio de Janeiro, 2002. 23 p.

em coelhos (Oryctolagus cuniculus). **Pesquisa Veterinária Brasileira**, v. 36, n.2, 108-118, 2016a.

PAZZINI J.M & MORAES P.C. **Princípios e Técnicas de Cirurgias Reconstrutivas da Pele de Cães e Gatos (Atlas Colorido).** 1ªed. Medvep, Curitiba, 2015, p.95-102.

PAVLETIC, M.M. **Small Animal Wound Magementand Reconstructive Surgery:** In: Free Grafts. 3.ed. Iowa: Wiley – Blackwell, Cap. 14, p. 404 – 431, 2010.

POPE, E.R. Enxertadura cutânea em malha. In: BOJRAB. **Técnicas atuais em cirurgia de pequenos animais**. 3. ed. São Paulo: Roca; 1996. p.447-51.

TOBIAS, K.M. **Manual de cirurgia de tecidos moles pequenos animais:** Enxertos em Malha de Espessura total. São Paulo: Roca, Cap. 5, p. 44 – 52, 2011.

VENDRAMIN, F.S.; FRANCO, D.; SCHAMALL, R.F.;FRANCO, T.R. Utilização do plasma rico em plaquetas (PRP) autólogo em enxertos cutâneos em coelho. **Revista Brasileira de Cirurgia Plástica.** v.25, n., p. 4-10, 2010.

ZANINI, M.; MACHADO FILHO, C.A.S.; TIMONER, F. Uso de esponja cirúrgica para curativo compressivo de enxerto cutâneo. **Anais Brasileiro de. Dermatologia**. v.79 n.3, 2004

CAPÍTULO 2 – Skin grafts associated with platelet rich plasma and surgical sponge - Literature Review

Skin grafts associated with platelet rich plasma and surgical sponge - Literature Review

Josiane M. Pazzini[1*], Eduardo L. Serafim[1], Ricardo R. A. Uscategui[1], Vivian T. Almeida[1], Carlos A. C. Oliva[1], Fátima Gärtner[2], Irina Amorim[2], Fátima Faria[2], Alexandra Rêma[2], Nazilton P. R. Filho[1], Marília G. P. A. Ferreira[1], Ana C.Silva[1], Rafael R. Huppes[3], Paola Castro Moraes[1], João A. Oliveira[4], Andrigo B. De Nardi[1]

[1] Department of University of Veterinary Surgery, Faculty of Agricultural and Veterinary Sciences of Jaboticabal (FCAV/Unesp), Access way Professor Paulo Donato Castellane without number, Jaboticabal, SP 14884-900, Brasil. Research with the support of Capes and PDSE-Doctoral Program Sandwich, and Cnpq (Process number:147728/2016-9).

[2] Department of Veterinary Pathology, University of Porto/ICBAS- Abel Salazar Biomedical Sciences Institute (UP-ICSBAS), Jorge Viterbo Ferreira Street, 228, Porto, Portugal.

[1] Department of University of Veterinary Surgery Unicesumar, Avenue Guedner, 1610- Jd Aclimação.

[3] Department of University of Veterinary Surgery Unicesumar, Avenue Guedner, 1610- Jd Aclimação, Maringá-PR.

[4] Statistical, PhD, Department of Statistics, Faculty of Agricultural and Veterinary Sciences of Jaboticabal (FCAV/Unesp), Access way Professor Paulo Donato Castellane without number, Jaboticabal.

*Correspondence: Rua Alexandria, 91, Paruqe Itamaraty, Jacereí, SP, Brasil. Tel.: +55 16991515157. E-mail: josipazzini@hotmail.com

Received: January, 5,2016 Accpeted: Februery, 13, 2017 Online Published: March, 15, 2017

doi:10.5539/jas.v9n4pxx URL: http://dx.doi.org/10.5539/jas.v9n4pxx

Abstract

Skin graft is one of the techniques used to reconstruct surgical wounds. The graft is composed of epidermal and dermal segments that are completely removed from the donor region and transferred to the recipient bed. After its implantation it's recommended to make compressive dressing at receiver bed. Since the grafts do not have a vascular pedicle, it's important to make the compressive dressing to improve graft contact with the wound and to allow adequate angiogenesis. The compressive dressing is made with a sponge or foam, which offers adequate protection and reduces the discomfort of the patient in the postoperative period. The use of platelet-rich plasma (PRP) is the objective of several studies associated with the reduction of postoperative surgical complications, especially necrosis. This product is a result of the centrifugation of the patient's blood that promotes the separation of its constituents and allows the extraction of plasma with higher concentration of platelets. PRP improves the tissue healing process by releasing biological mediators and growth factors at the site of application. Researches on platelet-rich plasma used in reconstructive surgery are important because this product has therapeutic characteristics to promote healing. When it's used in skin grafts, platelet-rich plasma is able to improve graft integration in the recipient bed, and reduce necrosis after the surgical procedure. The use of postoperative surgical sponges associated with platelet-rich plasma is indicated to improve the healing of the graft and to avoid its displacement of the recipient bed.

Key-words: Reconstructive surgery, skins grafts, PRP, compressive dressing.

Introduction

Reconstructive surgeries are formed by various techniques which can be used to repair large defects with loss of continuity of the integument or lack of skin elasticity, that compromise wound healing. Thus, in these cases, the use of skin grafts or flaps are options for treatments (Pavletic 2010).

Flaps consisted of a tissue segment partially removed from its original location and dislocated to another which will overlie the defect. The greatest advantage of using skin flaps is the immediate closure of the affected region, as well as reducing the tissue healing time, which gives the patient not only better functional but also aesthetic results (Hedlund 2005).

Therefore, grafts are epidermis and dermis segment that are completely removed from the donor site and transferred to the receiving region (Hedlund 2008, William *et al* 2013). However, being devoid of an artery and vein in its constitution are very affected by necrosis and ischemia after being implanted in the receiving region (Pope 1996).

According to Adams et al (2005), vascularization of the flaps and grafts is necessary, and much have discussed about the proportions of length and width of the flaps are fundamentally determine their viability, as when it is extensive, occurs vascular compromise and distal regions are left without blood supply, causing necrosis in distal margins. The grafts are devoid of artery and vein in its constitution, so are affected by necrosis after implanted in the recipient region (Tobias 2011). After faced with these problems, many authors have reported the use of substances to improve healing, by stimulating angiogenesis, which was boosted by the use of platelet-rich plasma (PRP) in surgical wounds (Vendramin *et al* 2010, Pazzini *et al* 2016a).

The preparation of grafts is done only with the presence of healthy granulation tissue into the receiving region; however, this condition makes the lengthy procedure being conducted in three steps: first carrying out disinfection of the wound, next after following it wait for the presence of tissue granulation, and finally the surgical correction (Pazzini *et al* 2015). As soon as the surgery is done, the dressing employment is essential, knowing that grafts are devoid of vascular pedicle, thus using compressive dressings can optimize the contact between the graft and the wound and then it allows proper angiogenesis (Pavletic 2010).

Curatives also reduce the possibility of graft dislocations, as well as minimize the presence of hematomas and seromas, events which usually leads to loss of viability of the graft and subsequently death (Pazzini *et al* 2015). Moreover, the more compressive dressings are used Tie over (Fossum 2007), which consists of suture material on the wound, and can be done with cotton, surgical sponges and foams. The idea of surgical sponges or foam is practical, by evenly distributing pressure on the wound (Zanini 2004), and to promote healing and integration of the graft to the receiving region.

The aim of this study is to make a review of the main features and answer questions about platelet-rich plasma, skin grafts and surgical sponges.

Reconstructive Surgery

Wound large areas caused by trauma, congenital abnormalities, and tumors that result in loss of viability of tissues and lead to healing by secondary intention, are cases that need to use reconstructive surgical techniques (Castro *et al* 2015). However, the procedure success will depend on upon the extent of an injury and the amount of how involved structures (Slatter 2007). Reconstructive surgery should be planned by considering the wound location, tissue elasticity available blood supply and quality of wound local (Fossum 2007).

Throughout the execution of reconstructive surgery, it is essential to preserve the microcirculation of the skin to maintain its viability (Mota *et al* 2012). However, when microcirculation is not conserved, due to inadequate surgical manipulation, you can begin a process of ischemia and subsequently lead to local necrosis of the surgical procedure involving the entire region (Slatter 2007, Amsellem 2011) (Figure 1).

Figure 1 Image of the lesion in the left forelimb in carpal region of rabbits (Oryctolagus cuniculus) showing the necrosis macroscopic variables (arrow) with 15 days that were submitted to the reconstructive surgery procedure at the Veterinary Hospital Faculty of Agricultural and Veterinary Sciences (FCAV) of Unesp, Jaboticabal Campus, 2015.

According to Pavletic (2007), wounds that have difficulty in healing by primary sutures should be treated with reconstructive techniques which can be either adopted flaps or skin grafts for correction. The use of these techniques is a useful therapeutic alternative to reconstructing injuries resulting from trauma, removing tumors, or ischemia.

Skin grafts

A skin graft is useful to reconstruct surgical wounds since preserved the principles of vascularization, antisepsis, and hemostasis (Zanini 2004). A skin graft is a segment the epidermis and dermis that are completely removed from the donating region and transferred to the receiving area (Hedlund 2008).

The grafts receive their nomenclature as their origins, such as autograft, isografts, allografts, and xenografts. In the autograft donor and recipient are obtained from the same patient. Isografts are obtained from donors of the same species and genetically identical to the receiver as monozygotic twins. Already allografts are obtained from donors of the same species, but genetically different. And xenografts are derived from animals of different species (Pavletic 2010).

Grafts are classified according to their thickness, and it may be complete or partial (William *et al* 2013). Full thickness consists of the epidermis and dermis full and partial thickness composed of epidermis and dermis variable layers (Pazzini *et al* 2015).

The advantage of partial-thickness grafts is associated with viability greater than the total thickness. However, significant disadvantages are more essential fragility, lack of hair growth in some cases; in addition to collecting require specific material (Fossum 2007). For these reasons, use is preferably the full thickness grafts (Corr 2009).

According to Fowler (2006), full-thickness grafts have some advantages when compared with partial thickness, have components responsible for similar cicatrization of the healthy skin, promoting hair growth and being able to withstand injury as well as to normal skin. Also provide good color and texture to the receiving region, and are characterized by having minimal shrinkage of the wound, and adnexal structures remain intact dermis (Ratner 1998). Different from the partial grafts, full thickness does not require specialized equipment for collect, addition success rate is as good as that obtained with partial grafts (Pazzini *et al* 2015).

Application of grafts is limited in veterinary medicine, by being necessary to await the formation of the previous granulation tissue before surgery, making it impossible in some cases their use (Pavletic 2007). Therefore use components that stimulate angiogenesis and promote healing are options to allow use graft surgical routine (Pazzini *et al* 2016a).

Types of grafts

Skin Grafts are produced in lateral chest wall and areas containing abundant skin (Fossum 2007). Skin grafts are divided into full and partial thickness. Full thickness grafts consist of dermis and complete epidermis. And partial thickness grafts consist of a dermis and a variable dermis layer (Pope 1996). Full-thickness grafts are better than partial thickness grafts because they are more resistant to trauma. On healing, hair growth is similar to normal skin, and the grafting can be done with a scalpel only, and the grafts in partial thickness Are fragile, hair growth does not occur during healing, and for making this graft, special material is needed (Pope 1996).

Layer grafts are used in places with free granulation tissue infection, but have disadvantages in the degree of expansion, by being less flexible and less adaptable (Pavletic 1999). The grafts mesh have parallel incisions in the shape of slits, which promote drainage, flexibility, conformation and expanding (Hedlund 2008). This type of graft has many advantages and can be expanded to close large defects, conform well to irregular surfaces, this occurs presence of the slits is better drainage of exudate, and for this purpose can be used in difficult areas to immobilize (Pope 1996, Pazzini *et al* 2015).

Such a graft can be made with particular device expansion or manually. Grafts mechanically processed into mesh are more expandables than those created manually because first expands into more than one direction, and second in only one direction, however, the therapeutic effect is similar and is manually accessible and inexpensive (Pazzini *et al* 2015). It is known that cosmetic appearance is better when the slits are placed in parallel the skin tension lines (Pavletic 2010, Fossum, 2007).

Graft survival is a widely discussed issue because of the lack of a vascular pedicle to perform its nutrition in the recipient bed, and healing can be compromised because of the absence of vessels (Hedlund 2007).

After implanted the graft into the receiving region, the cicatrization begins with plasmatic imbibition phase, following inosculation, revascularization and finally contraction (Fossum 2007).

Plasmatic imbibition phase happens approximately 24 hours after surgery, this period occurs the ischemia of the graft (Ratner 1998), due to its removal from the donor area. Blood vessels have a spasm, and eliminate part of blood components by the edges of sectional overhead vessels, such as erythrocytes and leukocytes, and these accumulate between the graft and its receiving region (Pope 1996).

Soon after the implantation of the graft in the receiving area, happens transudation of plasma, for the nutrition and to assist graft fixation. This phenomenon consists of the graft to adhere the mesh of fibrin, and fibrin filaments shrink for coating the wound (Pazzini *et al* 2015). Fibroblasts, leukocytes, and phagocytes invade the fibrin mesh, converting it into the fibrous tissue between the graft and its receiving region (Pope 1996). In this phase, there may be a presence of edema because of inadequate circulation to promote venous and lymphatic drainage. After reestablished drainage, a liquid is removed and happens regression the edema, normalizing aspect of the graft (Pazzini *et al* 2015). According to Ratner (1998), this fibrin present in the graft is gradually replaced by granulation tissue, being able to promote permanent graft adherence to his local, favoring the process of revascularization.

Following in inosculation phase where it occurs the anastomosis of small capillaries which are between responsible for communicating the graft surface to the receiving region, this phenomenon happens within 24 hours after the surgery, and at that stage the fibrin mesh keeps the graft the fixed to his local, assisting as a support structure for the formation of vascular sprouts in receiving region graft (Pope 1996). It is known that many vessels can contact and suffer anastomosis, but few that survive, so it is only possible to know if the surgery went well after the phase of revascularization (Pazzini *et al* 2015).

In revascularization phase, the graft is still fragile and cyanotic, because it does not have real vessels. This step happens approximately five to seven days of surgery, and there is the formation of new blood vessels, which are responsible for the actual graft flow (Ratner 1998). The neoformed capillaries have about 5 to 15 µm in diameter, and by constant divisions of the arterioles they give rise to the venules (Konig *et al.*, 2011). Besides blood vessels, they are also formed new lymphatics, which promote lymphatic drainage graft (Hedlund 2008).

Finally, the last phase of healing of the grafts is the contraction which happens so late, and can last up to six months of surgery. In this phase myofibroblasts and contractile ptoteínas are responsible for the contraction of the graft in the receiving region. This moment some adverse cosmetic effects can occur, such as the presence of irregular scars and bad cosmetic aspects (Pazzini *et al* 2015).

Skin graft: Immobilization and dressings

Once the graft is done, the fixation of the pressure dressing on the receiving area is fundamental to the success of the surgical procedure. This dressing is necessary for large and thickness grafts. However, there are some situations where the pressure dressing is not recommended, as in infected wounds or located in areas that potentially produce a large amount of lymph, as an inguinal region (Vasconez 1994).

It is known that the graft does not have vascular pedicle, and for this reason recommended compression bandage to optimize the contact of the graft to the wound and allow for adequate angiogenesis. In between three to five days begin communications with vascular arise transplanted skin, so the pressure dressing reduces a possibility of dislocations that affect this communication. Furthermore, they enable reduced occurrence of seroma and hematoma, events that frequently leads to loss of vitality and, consequently, to graft failure (Leffel 1994).

According to Larson (1990), the appropriate pressure on the graft varies from 15 to 30 mmHg, so if the weight is not suitable may predispose fluid collections. However, excessive pressure can compress the capillaries and determine necrosis of the graft (Amsellem 2011). Ideal compression is achieved with some materials such as surgical gauze, cotton, and sponge (Figura 2).

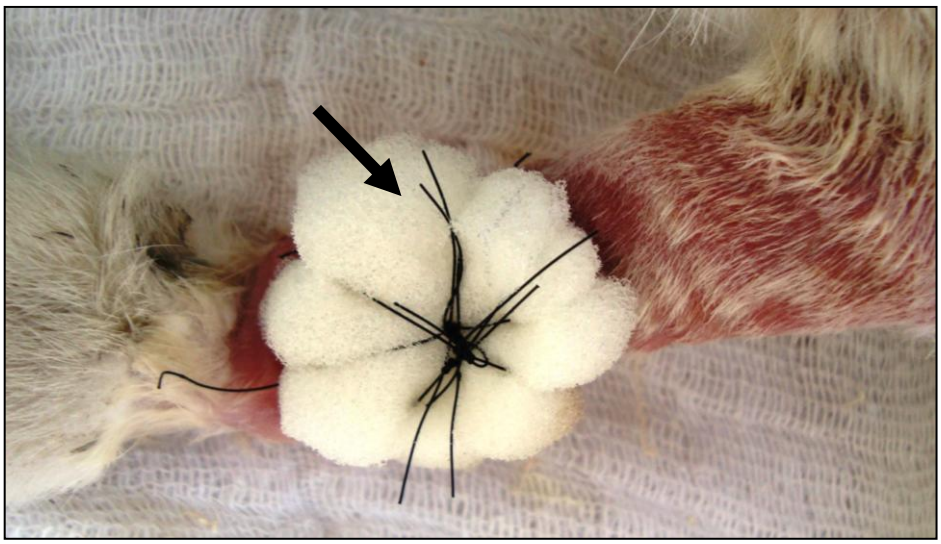

Figure 2 Image of the lesion in the left forelimb in carpal region of rabbits (Oryctolagus cuniculus) showing the pressure dressing used sponge (arrow) with 15 days that were submitted to the reconstructive surgery procedure at the Veterinary Hospital Faculty of Agricultural and Veterinary Sciences (FCAV) of Unesp, Jaboticabal Campus, 2015.

The usual technique of pressure dressing is suture surgical gauze agglomerate on the graft, known as Tie over (Pavletic 2010). This dressing is kept for a period which ranges from seven to fourteen days, since there are no signs of infection, hemorrhage, and loss of immobilization. Otherwise, the dressing should be removed, and the graft reevaluated (Hedlund 2008).

However, other materials can be used as compressive dressings like gauze, cotton, plastic discs and wax molds (Vasconez 1994). The idea of sponge or foam use appeared in 1929 (Blair *et al* 1929), the authors of this discovery, better pressure on the graft was from the utilization of the sponge.

According to Zanini et al (2004), to use the surgical sponge, should initially make their preparation, being done in two steps. First, highlight the brush sponge, being a simple process. Furthermore, by using scissors or a scalpel blade, it reduces the thickness of the sponge to 0.8 or 1 cm. It is important to leave a portion of about 0.5cm around the edge of the graft. Before starting the placement of the dressing evaluates absence of bleeding and verify correct placement of the graft. The suture should exercise adequate tension to keep set the graft. The evaluation must be done in a period that can range from 24 to 72 hours to observe any surgical complication. The dressings and sutures are removed in seven days face and two weeks elsewhere.

The main advantages of using sponge are low cost, by offering adequate protection of the graft, easily performed a technique, formable into different shapes, have uniformly distributed pressure, easy removal, and provide a reduction of post-operative patient discomfort. When compared to post-operative care of the usual technique with gauze or cotton, sponge seems to be more practical for do not accede to the graft, but if this occurs in some case, it can remove it more quickly (Blair *et al* 1929). In cases where there is a need to evaluate the graft, both as to the sponge removal replacement is easier than other techniques. The reduction of patient discomfort means that any bleedings occurring in post-operative likely to be completely absorbed by the sponge (Zanini *et al* 2004).

The great benefit of reconstructive surgery is to allow the patient to return their normal routine more quickly and with satisfactory cosmetic results. In some cases, complications can occur, such as inadequate

vascularization, graft handling and infection, and factors that predispose the occurrence of necrosis (Amsellem 2011). In such cases, the graft will present inviability signals in about three to four days after surgery, with paler staining, which moves rapidly to black segment indicating necrosis (Richard 1999). Thus, the neovascularization-related problems in surgical procedures are the focus of studies in various medical fields, especially in orthopedics and dentistry. Thus, the platelet-rich plasma (PRP) is the subject of several studies associated with complications in these areas.

This product, platelet rich plasma results from the patient's blood processing centrifuges which promote the separation of its constituents, and allows extraction from plasma with a higher concentration of platelets and is capable of potentializing the wound healing process through the release of biological mediators and growth factors at the application site (Pagliosa *et al* 2007). It is believed that this product stimulates various processes involved in tissue recovery including mitosis, cell differentiation, chemotaxis and angiogenesis (Garcez *et al* 2013).

Platelet-rich plasma (PRP)

According to Jain (1993), blood is a fluid tissue that circulates through the blood vessels carrying essential elements to the cells and receives the waste metabolites to take them in excretory organs. Blood contains three components being red blood cells, platelets, and leucocytes, which are dissolved in the liquid known as plasma (Reece *et al* 2006).

PRP is obtained by the centrifugation of autologous blood, which results in increased concentration of platelets in a smaller volume of plasma (Pagliosa *et al* 2007). Evidence of the effectiveness of its use is subject to many studies. However, researchers are seeking knowledge of the effectiveness of its biological effects when applied to soft tissue, bone, and skin (Anitua *et al* 2007, Silva *et al* 2011).

Production of the PRP at first was to reduce the presence of bleeding during surgical procedures; however, its use was propagated in various human healing modalities. In 1998 it was published a study reporting the success of the healing bone graft when combined with platelet-rich plasma (Marx *et al* 1998, Albuquerque *et al* 2008, Garcez *et al* 2013.). Thus, with this episode, the product started to be used in orthopedic surgery, cardiac, plastic, general, vascular, neurological, obstetric, gynecological and ophthalmic, to avoid complications and achieve success in the proceedings (Floryan *et al* 2004).

Platelet rich plasma has a gelatinous consistency. In order to obtain the gel it is necessary to carry out the enrichment process. First, platelets go through an enrichment process in which one searches obtain greater numbers of platelets to activate at least 60 their biologically active substances. This activation is essential because of tissue repair processes, which are responsible for promoting chemotaxis, proliferation, cell differentiation, immune modulation, remodeling and microbial activity (Bolta 2007, Vendramin *et al* 2010). However for this process to happen in all its phases, it is important the participation of an agonist agent at the time of platelet activation (Jain 1993).

Platelet activation is to modify the format of the projection of the platelets to release their inside contents (Reece *et al* 2006). Inside the platelets there are three types of storage compartments that are α granule, dense and lissosomais, and most of the substances found are stored in α granule. The granules secrete biological mediators after platelet activation and the liberated elements are thrombin, thromboxane A^2, adenosine diphosphate, thromboplastin, coagulation factors, calcium, serotonin, histamine, von Willebrand factor, fibrinogen, and catecholamines, being the growth factor a greater substance in the production of platelet rich plasma is (GF) (Bolta 2007).

The growth factor production happens in several tissues and cells such as fibroblasts, macrophages, endothelial cells, osteoblasts, and leukocytes, salivary and lacrimal glands. However, in the platelet studies are the subject of most interest, because they are easy to obtain and incorporate other essential substances in the regeneration process and tissue repair (Santos 2007).

One of the growth factors and most abundant found in α-platelet granules are growth factors derived from platelets (PDGF), and growth factor beta transformer (TGFb) that have specific activities as angiogenesis, mitogenesis and activation of macrophages, (Camargo *et al* 2002). Functions performed by these factors are critical to body functioning, and angiogenesis becomes more important when it comes to surgical wound healing and reduction of post-operative complications, especially tissue ischemia and necrosis (Clifford *et al* 2001).

Platelet rich plasma is easy to produce and is inexpensive. However, in the past, its production was more complicated, with high costs (Maia *et al* 2009). Lemos *et al*. (2002), Macedo (2004), Barbosa *et al*. (2008) developed other protocols to obtain platelet-rich plasma, using laboratory centrifuges to facilitate their production. Currently many researches are carried out using this methodology with good results (Textor *et al* 2011, Pazzini *et al* 2016b).

According to Camargo *et a.* (2002), to obtain the platelet-rich plasma is initially done by centrifugation, which can be performed in a single time or in two steps depending on the protocols used. Jameson (2007), Pazzini *et al* (2016b) describe a protocol double centrifuging, after the first centrifugation (1600 revolutions per minute (rpm) for 10 minutes), red cells are discarded, then the plasma returns the centrifuge to second centrifugation (2000 revolutions per minute (rpm) for 10 minutes), resulting in the precipitation of platelets and very few erythrocytes in the bottom of the tube. Subsequent to this process, an average of 80% of the top of the plasma corresponds to the platelet-poor plasma (PPP), which is discarded, and observed the presence of platelet button bottom of the vial, which is resuspended in the remainder of plasma to form the platelet-rich plasma (PRP) (Figure 3).

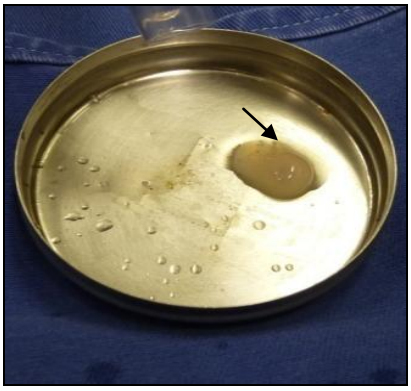

Figure 3 Image of platelet-rich plasma (PRP) (arrow) procedure at the Veterinary Hospital Faculty of Agricultural and Veterinary Sciences (FCAV) of Unesp, Jaboticabal Campus, 2015.

Then, the platelets are activated by the degranulation process and thus releasing growth factors (Albuquerque et at 2008). Some protocols recommended platelet activation with addition of bovine thrombin, thromboplastin or thrombin autogenous (Bolta 2007), although others recommend calcium gluconate as a platelet activator (Pazzini *et al* 2016b). The use of such substances results in the formation of a gelatinous substance similar to a thrombus called platelet gel (Bolta 2007).

After its production is carried out the platelet count, it is essential that the count is greater than the whole blood, to occur the proper release of growth factors in the region of its implementation (Pagliosa *et al* 2007). The count must provide platelet concentration greater than 1.000.000/uL, which can be performed on automatic machine in hemocytometer or by indirect counts in blood smears (Lemos *et al* 2002).

It is essential that the final product is appropriate; all stages of preparation are carried out with precision, from the collection of blood to obtain the gel in order to avoid the occurrence of inadequate fragmentation of platelets and early release of growth factors in the solution responsible for reducing the effectiveness of the product. Platelet activation should be performed only at the time of application of the product, because after this process the release of growth factors occurs immediately, about 10 minutes, and hour in the first 70% to 100% of them have been released. Immediately after release of these factors, the product acquires a gelatinous consistency, which provides greater ease for application to the desired site (Albuquerque *et al* 2008) Platelet concentrate can also be applied directly on the wound or incision, without being in the form of gel (Jameson 2007).

Platelet-rich plasma is regarded as an adjuvant product in the healing process of reconstructive surgery because of its auxiliary potential in stimulating processes of new blood vessels (Pazzini *et al* 2016a). However, other authors report some contradictory results through the use of the product, and suggest that more experimental studies need to be done in order to really demonstrate efficacy of the product, and also emphasize that more research is needed in veterinary medicine because there are few experimental works related to the use of PRP (Garcia 2005).

Conclusions

Researches on platelet-rich plasma used in reconstructive surgery are important because this product has therapeutic characteristics to promote healing. When it’s used in skin grafts, platelet-rich plasma is able to improve graft integration in the recipient bed, and reduce necrosis after the surgical procedure. The use of

postoperative surgical sponges associated with platelet-rich plasma is indicated to improve the healing of the graft and to avoid its displacement of the recipient bed.

Conflict of interest statement

None of the authors of this paper has a financial or personal relationship with other people or organisations that could inappropriately influence or bias the content of the paper.

Acknowledgements. In the Faculty of Agricultural and Veterinary Sciences (FCAV), Universidade Estadual Paulista (Unesp), and the University of Porto by structural and laboratory support; Capes (Coordenação de Aperfeitoçoamento de Pessoal do Nível Superior) to the scholarship granted in Brazil and Portugal (PDSE).

Ethics committee

This study was approved by the Ethics Committee on Animal Use (CEUA) of the Universidade Estadual Paulista (UNESP), Jaboticabal Campus, protocol number: 11767/14.

References

Adams, C.D. , Ramsey, L.M. (2005).Grafts in Dermatologic Surgery: Review and Update on Full- And Split Thickness Skin Grafts, Free Cartilage Grafts, and Composite Grafts. *Dermatol Surg*, 31, 1055-1067. DOI: 10.1111/j.1524-4725.2005.31831.

Albuquerque, D.P., Oliveira, T.F.M., Maranhão, Filho A.W.A., Milhomens, Filho F., Gusmão, E.S. (2008). Aplicação clínico-cirúrgica do plasma rico em plaquetas – estudo revisional. *Odont Clín Cient,* 7(2),119-122.

Amsellem, P. (2011). Complications of reconstructive surgery in companion animals. *Vet Clin Small Ani,* 41, 995-1006.

Anitua, E. (2007). Effectiveness of autologus preparation rich in growth factors for the treatment of chronic cutaneous ulcers. DOI:10.1002/jbm.b.30886

Barbosa, A.L.T., Del Carlo, R.J., Gomes, H.C., Oliveira, A.C., Monteiro, B.S., Olta, P.R.Z. (2008). Use of platelet growth factors in treating wounds and soft-tissue injuries. *Acta Dermat APA* .16(4), 156-165.

Bolta, P.R.Z. (2007). Use of platelet growth factors in treating wounds and soft-tissue injuries. *Acta Dermat APA*, 16(4), 156-165.

Blair, V.P., Brown J.B. Use and uses of large split skin grafts of intermediate thickness. *Surgery Gynecology Obstettrics*, 49:82-97, 1929. DOI: 10.1201/b17524-2.

Camargo, P.M., Lekovic, V., Weinlaender, M., Vasilic, N., Madzarevic, M., Kenney, E.B. (2002). Platelet-rich plasma and bovine porous bone mineral combined with guided tissue regeneration in the treatment of intrabony defects in humans. *J Period Res,* 37,300-306. DOI: 10.1034/j.1600-0765.2002.01001.

Castro, J.L.C., Huppes, R.R., De Nardi, A.B., Pazzini, J.M. (2015). Princípios e técnicas de cirurgias reconstrutivas da pele de cães e gatos (atlas colorido). 1ªed. Medvep, Curitiba, Pp.10-16.

Corr, S. (2009). Intensive, extensive, expansive. managment of distal limb shearing injuries in cats. *J fel med surg,* 11, 747-57. DOI: 10.1016/j.jfms.2009.07.009.

Clifford, C.A., Hughes, D, Beal, M.W., Mackin, A.J., Henry, C.J., Shofer, F.S., Sorenmo, K.U. (2001). Plasma vascular endothelial growth factor concentrations in healthy dogs and dogs with hemangiosarcoma. *J Vet Int Med,* 15(2),131-135. DOI: 10.1111/j.1939-1676.2001.tb01244.x

Fossum, T.W. (2007). Cirurgia de pequenos animais: Cirurgias reconstrutivas. 3. ed. São Paulo: Roca. Pp. 135-186.

Fowler, D. (2006). Distal limb and paw injuries. *Vet Clin Small Ani* 36, 819-845. DOI: http://dx.doi.org/10.1016/j.cvsm.2006.02.004.

Floryan, K.M., Berghoff, W.J. (2004). Intraoperative use of autologous platelet-rich and platelet-poor plasma for orthopedic surgery patients. *Aorn J,* 80(4), 668-674. DOI: http://dx.doi.org/10.1016/S0001-2092(06)61320-3.

Garcez, T.N.A., Rosa Paz, A.H., Magrisso, A.B., Mello, H.F., Gonçalves, F.C., Meyer, F.S., Contesini, E.A., Cirne-Lima, E.O. (2013). Comparação entre três protocolos de obtenção de plasma rico em plaquetas (prp) utilizando o coelho como modelo experimental. *Acta Scien Vet,* 41,1134.

Garcia, R.V. (2005). Utilização de plasma rico em plaquetas (prp) associado a implantes intra-ósseos em mandíbulas de cães. análise histológica. 2005. 93f. tese (doutorado em odontologia) – Universidade Estadual Paulista – Unesp- Araraquara.

Hedlund, C.S. (2008). Cirurgia do sistema tegumentar. In: Fossum TW. Cirurgia de pequenos animais. 3ª ed. São Paulo: Elsevier, Pp. 224-278.

Hedlund, C.S. (2005). Cirurgia dos sistema tegumentar. In: Fossum TW. Cirurgia de pequenos animais. 2.ed. São Paulo: Roca, Pp. 135-230.

Jain, N.C. (1993). Examination of the blood and bone marrow. In:_____. Essentials of veterinary hematology, Philadelphia: Lea & Febiger, Pp. 1-18.

Jameso,n C.A. (2007). Autologous platelet concentrate for the production of platelet gel. *Ladmedicine,* 38(1), 39-42.

Konig, H.E., Liebich, H.G. (2011). Anatomia dos animais domésticos – Textos e atlas colorido. 4.ed. Porto Alegre: Artmed. Pp.56-58.

Leffell, D.J. (1996). Split-thickness skin grafts. In: _____.Atlas of cutaneous surgery**.** Philadelphia: W.B Saunders C.O, Pp. 149-56.

Lefkovits, J., Plow, E.F., Topol, E.J. (1995). Platelet glycoprotein iib/iiia receptors in cardiovascular medicine. *New Engl J Med,* 332, 1553-1559.

Lemos, J.J., Junior Rossi, R.., Píspico, R. (2002). Utilização de plasma rico em plaquetas em enxertos ósseos – proposta de um protocolo de obtenção simplificado. Disponivel em: http://www.odontologia.com.br/artigos.asp?id-225. acesso em 21.09.15.

Maia, L., Souza, M.V. (2009). Componetes ricos em plaquetas na reparação de afecções tendo-ligamentosas e osteoarticulares em animais. *Ciência Rural,* 39(4), 1267-1274.

Macedo, A.P. (2004). Plasma rico em plaquetas: uma análise quantitativa e qualitativa de dois protocolos de obtenção. 2004. 63f. dissertação (mestrado em odontologia) – Universidade Federal de Santa Catarina, Santa Catarina.

Marx, R.E., Carlson, E.R., Eichstaedt, R.M., Schimmele, S.R., Strauss, J.E., Georgeff, K.R. (1998). Platelet-rich plasma: Growth factor enhancement for bone grafts. Oral Surg Oral Med Oral Pathol Oral Radiol Endod, 85(6):638-46. DOI: http://dx.doi.org/10.1016/S1079-2104(98)90029-4.

Mota, A.K.R., Lacerda, M.A., Aleixo, G.A., Andrade, L.S.S., Coelho, M.C.C.O. (2012). Integração de retalhos de plexo subdérmico para o recobrimento de feridas traumáticas em membros de cães – Avaliação clínica. *Medicina Veterinária,* 6(2):1-9.

Pagliosa, G.M., Alves, G.E.S. (2007). Considerações sobre a obtenção e o uso do plasma rico em plaquetas e das células mesenquimais indiferenciadas em enxertos ósseos. *Ciência Rural,* 37(4), 1202-1205. http://dx.doi.org/10.1590/S0103-84782007000400050.

Pavletic, M.M. (1999). Atlas of small animal reconstructive surgery. 2.ed. Philadelphia, Pennsylvania: W.B. Saunders Company, Pp.680,1999.

Pavletic, M.M. (2007). Tegumento. In: Slatter, D. Manual de Cirurgia de Pequenos Animais. 3.ed. vol.1. São Paulo: Manole, Pp. 292-321.

Pavletic, M.M. (2010). Small Animal Wound Magementand Reconstructive Surgery. In: Free Grafts. 3.ed. Iowa: Wiley – Blackwell, cap. 14, Pp. 404 – 431.

Pazzini, J.M., Moraes, P.C. (2015). Princípios e técnicas de cirurgias reconstrutivas da pele de cães e gatos (atlas colorido). In: Castro JLC, Huppes RR., De Nardi AB, Pazzini JM. Príncípios e técnicas para realização de enxertos cutâneos. 1ªed. Medvep, Curitiba, cap. 8, pp.95-102.

Pazzini, J.M., De Nardi, A.B., Huppes, R.R., Gering, A.P., Ferreira, M.G.P.A., Silveira, C.B.P., Luzzi, M.C., Oliveira, J.A. (2016ª). Utilização de plasma rico em plaquetas para estimulação da angiogênese em flape de padrão axial toracordosal em coelhos (oryctolagus cuniculus). *Pesq Vet Bras,* 36(2), 108-118. http://dx.doi.org/10.1590/S0100-736X2016000200008.

Pazzini, J.M., De Nardi, A.B., Huppes, R.R., Gering, A.P., Ferreira, M.G.P.A., Silveira, C.B.P., Luzzi, M.C., Santo, R. (2016b). Method to obtain platelet rich plasma from rabbits (oryctolagus cuniculus). *Pesq Vet Bras*, 36(1), 39-44. http://dx.doi.org/10.1590/S0100-736X2016000100007

Pope, E.R. (1996). Enxertadura cutânea em malha. In: Bojrab. Técnicas atuais em cirurgia de pequenos animais. 3. ed. São Paulo: Roca Pp.447-51.

Ratner, D. (1998). Skin grafting: from here to there. *Excision and Repair,* 16(1), 75-90.

Reece, W.O., Swenson, M.J. (2006). Composição e funções do sangue. In: Reece, W.O. Dukes/Fisiologia dos animais domésticos. 12.ed. Rio de Janeiro: Guanabara Koogan cap.3, Pp. 24-48.

Richard, A.S. (1999). Skin graftings. In: Bsava manual of canine and feline wound management and reconstruction. 1.ed. England: British, cap.9 Pp.83-94.

Santos, L.A.U. (2007). Efeitos da utilização do plasma rico em plaquetas na osteointegração dos enxertos ósseos criopreservados: estudo histomorfométrico em coelhos. 140f. dissertação (mestrado em ciências) – Universidade de São Paulo (usp), São Paulo.

Silva, R.F., Rezende, C.M.F., Paes Leme, F.O., Carmona, J.U. (2011). Evaluación del método del tubo para concentrar plaquetas caninas: estudio celular. *Arch med vet,* 43, 95-98. doi.org/10.4067/S0301-732X2011000100014.

Slatter, D. (2007). Manual de cirurgia de pequenos animais: pele e órgãos anexos. 3.ed. São Paulo: Manole, cap.22, Pp.304-309.

Swaim, S.F. (2007). Wound healing. In: Swaim, S.S. (ed). Surgery of traumatized skin: management and reconstruction in the dog and cat. Philadelphia: W.B. Saunders, Pp. 70.

Textor, J.A., Norris, J.W., Tablin, F. (2011). Effects of preparation method, shear force,and exposure to collagen on release of growth factors from equine platelet-rich plasma. *Amer J Vet Res,* 72, 2. doi: 10.2460/ajvr.72.2.271.

Tobias, K.M. (2011). Manual de cirurgia de tecidos moles pequenos animais: enxertos em malha de espessura total. São Paulo: Roca, cap. 5, Pp. 44 – 52.

William, J., Moorms, A. (2013). Enxertos de pele livro. In: William J, Moorms A. BSAVA Manual de feridas em cães e gatos. 2.ed. Roca, p. 276.

Vasconez, L.O., Vasconez, H.C. (1994). Plastic & reconstructive surgery. In: Way, L.W. Surgical diagnosis and treatment. Connecticut: Appleton & Lange Pubs Pp.1130-1134.

Vendramin, F.S., Franco, D., Schamall, R.F., Franco, T.R. (2010). Utilização do plasma rico em plaquetas (prp) autólogo em enxertos cutâneos em coelho. *Rev bras cir plas,* 25(4), 4-10.

Zanini, M., Machado Filho, C.A.S., Timoner, F. (2004). Uso de esponja cirúrgica para curativo compressivo de enxerto cutâneo. *Anais bras Dermat,* 79, 3.

CAPÍTULO 3 – Esponja cirúrgica associada com plasma rico em plaquetas em enxertos cutâneos em malha e camada em coelhos (*Oryctolagus cuniculus*)[2]

Surgical sponge associated with platelets rich plasma in skin mesh grafts and layer in rabbits (*Oryctolagus cuniculus*)

Josiane Morais Pazzini[1*], Eduardo Luis Serafim[2], Ricardo Ramirez Andrez Uscategui[1], Vivian Tavares de Almeida[1], Carlos Alfredo Calpaa Oliva[1], Fátima Gärtner[2], Irina Amorim[4], Fátima Faria[2], Alexandra Rêma[2], Nazilton De Paula Reis Filho[1], Marília Gabriele Prado Albuquerque Ferreira[1], Ana Carolina da Silva[1], Rafael Ricardo Huppes[3], Paola Castro Moraes[1], João Ademir de Oliveira[4], Andrigo Barboza De Nardi[1]

[1] Department of University of Veterinary Surgery, Faculty of Agricultural and Veterinary Sciences of Jaboticabal (FCAV/Unesp), Access way Professor Paulo Donato Castellane without number, Jaboticabal, SP 14884-900, Brasil. Research with the support of Capes and PDSE-Doctoral Program Sandwich, and Cnpq (Process number:147728/2016-9). E-mail: josipazzini@hotmail.com; ramirezuscategui@hotmail.com; vitalmeida21@hotmail.com; nazilton@hotmail.com; calpaa@yahoo.es; mary_pops1@hotmail.com anacarolana@hotmail.com; pcastromoraes@yahoo.com.br; andrigobarboza@yahoo.com.br. *Corresponding author: josipazzini@hotmail.com

[2] Veterinary, Avenue Altiro Arantes, 385, Irapuã, SP 14.990.000, Brasil. E-mail: eduardoluis.serafim@gmail.com

[3] Department of Veterinary Pathology, University of Porto/ICBAS- Abel Salazar Biomedical Sciences Institute (UP-ICSBAS), Jorge Viterbo Ferreira Street, 228, Porto, 4050-313, Portugal. E-mail: fgartner@ipatimup.pt; irinamorim@hotmail.com; fatimafaria10@yahoo.com.br; alexandra.rema@gmail.com

[4] Department of University of Veterinary Surgery Unicesumar, Avenue Guedner, 1610- Jd Aclimação, Maringá-PR, 87050-900, Brasil. E-mail: rafaelhuppes@hotmail.com

[5] Statistical, PhD, Department of Statistics, Faculty of Agricultural and Veterinary Sciences of Jaboticabal (FCAV/Unesp), Access way Professor Paulo Donato Castellane without number, Jaboticabal, SP 14884-900, Brasil. E-mail: jaoliv@fcav.unesp.br

[2] Resultados submetidos ao Arquivo Brasileiro de Medicina Veterinária e Zootecnia. Normas publicação (Anexo I).

RESUMO – O objetivo deste estudo foi avaliar a eficácia do PRP associado com esponjas cirúrgicas favorecerem a integração do enxerto ao leito receptor. Realizou-se no Hospital Veterinário da UNESP, Jaboticabal, SP, um estudo com 64 coelhos, separados em oito grupos, com oito animais. Os grupos foram: Gprpc (PRP, sem esponja cirúrgica, enxerto camada), Gprpce (PRP, esponja cirúrgica, enxerto camada), Gcc (solução fisiológica 0,9%, sem esponja cirúrgica, enxerto camada), Gcce (solução fisiológica 0,9%, esponjas cirúrgicas, enxerto camada), Gprpm (PRP, sem esponja cirúrgica, enxerto malha), Gprpme (PRP, esponja cirúrgica, enxerto malha), Gcm (solução fisiológica 0,9%, sem esponja cirúrgica, enxerto malha), e Gcce (solução fisiológica 0,9%, esponjas cirúrgicas, malha). Os dados foram analisados pelo teste t emparelhado, Kruskal-Wallis, análise de variância, e teste de Tukey (*p<0,05*). Edema e exsudato com 3 e 7 dias ((p<0,05);; coloração no 14º dia (p<0,05); aspecto cosmético no 7º dia (p<0,05); células mononucleares e polimorfonucleares (p<0,05); proliferação de fibroblastos (p<0,05); colagenização (p<0,05); hemorragia (p<0,05); necrose e reepitelização (p>0,05). Conclui-se que o emprego do PRP gel em enxertos cutâneos associando esponjas cirúrgicas como curativo compressivo favorecem sua integração ao leito receptor sem a presença prévia de tecido de granulação.
Palavras-chave: Enxertos cutâneos, curativo compressivo, angiogênese, PRP, coelho.

ABSTRACT - The aim of this study was evaluation of efficacy of PRP employment associated with surgical sponges to improve the integration of the graft in the recipient bed. It was held at the Veterinary Hospital UNESP, Campus of Jaboticabal - SP, a study of 64 rabbits, divided into eight groups with eight animals. The groups were divided in control with saline solution 0,9%, control with PRP both without sponge, surgical sponge with PRP, surgical sponge without PRP, and was used mesh and layer grafts in the respective groups. The data were submitted to statistical analysis (paired t-test, Kruskal-Wallis test, with subsequent use of the multiple comparison test of Dunn, analysis of variance (F) test, Tukey test, *p <0.05*). Edema and exudate with 3 and 7 days (*p<0,05*); coloring on the 14th day (*p<0,05*); cosmetic appearance on the 7th and 14th day (*p<0,05*); mononuclear cells and polymorphonuclear (*p<0,05*); fibroblast proliferation (*p<0,05*); collagenous (*p<0,05*); hemorrhage (*p<0,05*); necrosis and re-epithelialization (*p>0,05*). It is concluded that the use of platelet-rich plasma in the form of gel skin grafts involving postoperative surgical sponge as a pressure dressing to improve the integration of the graft to the receptor without a previous presence of granulation tissue.
Keywords: Skin grafts, compressive dressing, angiogenesis, PRP, rabbit.

Introduction

Skin grafts are a segment of the epidermis and dermis that is completely removed from the donor region and transferred to the receptor site without the presence of vascular pedicle (Pazzini et al., 2015). They are used to repair defects with a large loss of continuity of the integument, or lack of skin elasticity, which compromise healing (Castro *et al*, 2015).

The grafts don't have vascular pedicle, so compressive dressing is recommended to optimize the contact of the graft to the wound bed and allow adequate angiogenesis. In the range of three to five days begin communications vascular in the transplanted skin, so the pressure dressing reduces the possibility of dislocations that affect this communication.

Furthermore, they reduced occurrence of seroma and bruise, events that normally lead to the loss of vitality and, consequently, to graft failure (Pavletic, 2010).

However, the successful healing of the grafts depends on proper angiogenesis (Pazzini *et al*., 2015). Thus, the problems encountered related to neovascularization in surgical procedures are the subject of many studies, and the platelet-rich plasma (PRP) is a substance that has been researched to have factors that stimulate angiogenesis and aid in tissue repair (Santos, 2007). Studies indicate that this product can stimulate various processes involved in tissue recovery mainly epithelialization and angiogenesis (Pazzini *et al*., 2016a).

The purpose of this study was to evaluate the effectiveness of employment platelet-rich plasma gel (PRP) in full thickness skin grafts in layer and mesh to used in rabbits (Oryctolagus cuniculus) associating postoperative surgical sponges as compressive dressing in order to assess the possibility of PRP with the surgical sponges to improve the integration of the graft to receptor site without previous presence of granulation tissue. Also evaluate the local angiogenesis where the procedure was performed, and reduction of occurrence of necrosis.

Material and methods

Surgical procedures of this study were performed in the Veterinary Hospital of the Faculty of Agricultural and Veterinary Sciences (FCAV/UNESP), Jaboticabal Campus. The material destined to histological analysis were made in Veterinary Pathology Laboratory of the University of Porto, Portugal. This study was approved by the Ethics Committee on Animal Use (CEUA) of the Universidade Estadual Paulista (UNESP), Jaboticabal Campus (Protocol number: 11767/14).

The experimental model used to perform the reconstructive surgery was the rabbit (*Oryctolagus cuniculus*). 64 rabbits White New Zealand were used, with 60 days of age, females and an average weight of 3 kg from producer specialized in the creation of the species. The animals were divided into eight groups of eight animals each. The groups were Gprpl (PRP, without surgical sponge, layer graft), Gprple (PRP. with surgical sponge, layer graft), Gcl (control, saline solution 0,9%, without surgical sponge, layer graft), Gcle (control, saline solution 0.9%, with surgical sponges, layer graft), Gprpm (PRP, without surgical sponge, mesh graft) Gprpme (PRP, with surgical sponge, mesh graft), Gcm (control, saline solution 0.9%, without surgical sponge, mesh graft), Gcme (saline solution 0.9%, with surgical sponges, mesh graft). The anesthetic protocol which the animals were submitted consisted of midazolam dose of 0.5 mg/kg intramuscular (IM) and tramadol hydrochloride at

a dose of 5 mg/kg by the same way. After the anesthetic, blood samples were collected from the 64 rabbits and were submitted through the sealed face mask with isoflurane in 3% dose diluted in 100 % oxygen, to produce surgical anesthesia.

The preparation of platelet-rich plasma was conducted as recommended by the literature (Pazzini *et al*., 2016b). The surgical procedure for reconstruction using graft was performed in a single moment, replacing the granulation tissue by platelet-rich plasma. For the realization of the dermal-epidermal wound and marking of the skin segment to be removed in the left carpal region, was used a surgical pen and sterile ruler to create a lesion of 4 cm long by 4 cm wide, the square-shaped. After performing the injury carpus, the skin graft with 9 cm^2 was done in lateral left chest, with skin incision square format with depth limits determined in accordance with the anatomical references described in the literature (Pazzini et al., 2015). In mesh grafts was done the slits, and the layer graft only in the waste cleaning. Subsequently promoted to hemostasis of local vessels in the recipient bed and began the implementation of the graft. Sutures separate simple pattern using 4-0 nylon (Nylon monofilamentar- Point Suture do Brasil IND. de fios cirúrgicos LTDA.-Fortaleza - Ceará – Brasil), was used for the synthesis of the surgical wound.

The gel platelets-rich plasma (PRP 0.7ml) was applied in Gprpl, Gprple, Gprpm and Gprpme before carpal injury synthesis with the aid of the scalpel handle and distributed evenly between the subcutaneous tissue of the donor site and the subcutaneous tissue of the recipient bed, and the beasts of the Gcc, Gcce, Gcm and Gcme received 0.7ml of saline solution 0,9%. After application of the respective solutions proceeded to the synthesis of the surgical wound. The surgical sponges was performed from the brushes used for antisepsis, as described in the literature (Zanini, 2004). In the groups that receiving surgical sponge, after implantation of the graft and application of their solutions, there was the use of surgical sponge at the end of suture as pressure dressing.

Macroscopic assessments were wound evaluated for the exudate, color, edema, and cosmetic appearance of the wound. On the 15th day after surgery, the animals were euthanized for microscopic evaluation of material harvest. The material was referred to for Veterinary Pathology Laboratory at the University of Porto, Portugal, for making the slide for microscopic evaluation.

The samples were processed by conventional routine histological processing, embedded in paraffin blocks, and realization of histological sections. These were cut on a microtome with a thickness of 2 micrometers in a sequence; hydration was carried out at increasing dilutions of alcohols and diaphanization in xylol. The histological analysis was

performed by the same pathologist (FG) without prior knowledge of identification of groups. Histological evaluation of tissue was examined under an optical microscope at 400x magnification. The photomicrographs were held at NIS program - Nikon Imaging Software Elements version 30.4 NIS program - Nikon Imaging Software Elements version 4.30. Hematoxylin & Eosin was used for evaluation of epidermis and dermis for the presence of necrosis, mononuclear cells, polymorphonucleate, fibroblast proliferation and hemorrhage; Hematoxylin & Eosin and Masson's Trichromic (blue contrast) for vascular proliferation; Picrosirius (Easy Path - Sirius Red Staining) for evaluation collagenous.

The data obtained was determined by the semiquantitative and quantitative method of as recommended to the literature (Garros *et al*., 2006). Only for the data of the PicroSirius, sections were analyzed by optical microscopy under polarized light (Olympus BX-53 ®, Japan). The observation of the collagen fibers through this method allowed the differentiation of type I collagen (birefringence yellowish-orange to orange and red) and type III (green or yellow-green birefringence) (Coleman, 2011). Of each slide were selected and photomicrographed ten histological fields with a digital camera (5.0m) in increased 20x. The images were analyzed with the aid of software Image J®, with the plug-in Colour Threshold, obtaining the percentage of collagen by analysis of automated particle according selection and extent of areas based on color as described in the literature (Bedoya *et al.*, 2016)

For the immunohistochemical study, a panel of antibodies specific for several antigens was applied (Table 1). The glass slides was previously cleaned and degreased, prepared with prepared with organosilane-based adhesive (3-aminopropyl triethoxysilane, C.O. Sigma Chemical, USA). Novolink^{tm} Polymer Detection Systems was used according to the manufacturer's instructions.

Table 1. Antibodies used for immunohistochemistry cutaneous tissues of rabbits conducted in Veterinary Pathology Laboratory of the University of Porto, Portugal, in 2016.

Antibody	**Clone**	**Company**	**Diluation**	**Antigenic recovery**	**Incubation period**	**Detection system**	**Positive control**
Ae1/Ae3	Monoclona, Ae1/Ae3	ImPath, USA	1:400	Maria Bath (BM), Novocastra^{tm} Epitope Retrieval Solutions	Over night à 4º	Vectastain elite ABC Kit	Rabbit normal skin
Caveolina-1	Policlonal, anti-Caveolina	BD Pharmingen	1:500	-	45 minutos	Novolink^{tm} Polymer Detection Systems	Rabbit normal skin

The data obtained from the Ae1/Ae3 were evaluated in photomicrographs obtained by an optical microscope, increased 2x, made NIS program - Nikon Elements Imaging Software version 4.30. Subsequently, the images were analyzed with the aid of software Image J®, with the plug-in Colour Threshold to yield the percentage of the total area of reepithelialization of the wound using the automated particle analysis according to the selection and measurement areas with based on the color (Gobi 2013).

The angiogenic index for Caveolin-1 was determined by microvessel counting technique according Maeda et al. (1995). The microvessel count was determined twice by a single rater, at two different times and was expressed as a mean number of vessels in each case studied.

The comparison between groups (Gprpl, Gprple, Gcl, Gcle, Gprpm, Gprpme, Gcm, Gcme) in relation to the categorical variables (exudate, edema, color, cosmetic appearance, vascular proliferation, mononuclear cells, polymorphonuclear cells, fibroblast proliferation, hemorrhage and necrosis) was performed by Kruskal-Wallis test, with subsequent use of the multiple comparison test of Dunn, for cases in which there was significant difference between the medians of the groups. In all tests, p values equal or less than 0.05 ($p<0.05$) was considered significant. For the analysis was used Npar1way procedure computer program SAS (SAS 9.1, SAS Institute, Cary. NC, USA) and the GraphPad Prism program, Version 4.00.

The epithelialization data, and collagen of different types of collagen fibers, according to the degree of differentiation were compared by analysis of variance (F test) for a completely randomized design with eight groups and ten repetitions per group, considering p values equal or less than 0.05 ($p<0.05$) significant. The evaluation data immunohistochemistry using Caveolin-1 were also subjected to analysis of variance, with eight groups (Gprpl, Gprple, Gcl, Gcle, Gprpm, Gprpme, Gcm, Gcme) and five repetitions (average) per group and level of significance of 5%. In both cases, there was a significant difference between means ($p<0.05$), these were compared by Tukey test at the level of significance (5%). For this analysis, we used the General Linear Models Procedure (GLM) of the SAS computer software (SAS 9.1, SAS Institute, Cary. NC, USA).

Results and Discussion

Edema and exudate with 3 and 7 days ($p<0,05$) (Figure 1); coloring on the 14th day ($p<0,05$); cosmetic appearance on the 7th and 14th day ($p<0,05$).

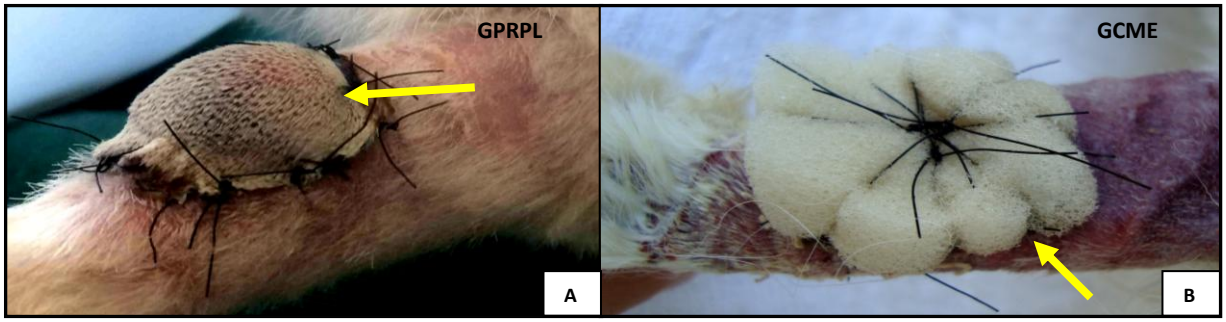

Figure 1 Photographic images of the lesion in the left forelimb in carpal region of rabbits (Oryctolagus cuniculus) showing the edema macroscopic variables with three days that were significant between groups (*p<0.05*) submitted to the reconstructive surgery procedure at the Veterinary Hospital Faculty of Agricultural and Veterinary Sciences (FCAV) of Unesp, Jaboticabal Campus, 2015.) edema presence in the graft region layer (arrow) in Gprpl. B) No edema following surgical sponge (arrow) in Gcme.

The results obtained in this study on the macroscopic variable presence of edema was significant between groups ranging from discreet to intense in Gprpl and Gcle 3 and 7 days of surgery respectively, and the results similar to Bauer *et al*. (2009), which assessed the effects of platelet-rich plasma in the dermal wound repair process in rats and found 24 hours after intense surgical edema procedure in the treated and control group. But another important issue evaluated was the use of surgical sponges associated with PRP, then this work is in agreement with the results of Zanini *et al.* (2004), who used surgical sponge as a pressure dressing for skin grafts in the face of human, and found favorable results with your job, presenting itself as ideal dressing, able to promote ventilation, exudate absorption and reduction of edema, recommending the application sponge as a pressure dressing mode. Given the results, it can infer that surgical sponges favor in reducing post-surgical edema, although there were seven days of surgery mild edema in Gcce animals, yet the use of sponges is justified by improving healing.

Regarding the exudate, such change was significant in some of the groups we used the PRP, appearing in Gprpme and Gprpm during the 3rd and 7th post operative respectively. The results of this testing are contrary to Pazzini *et al.* (2016a), who used the PRP in Thoracodorsal axial pattern flaps in rabbits and observed a significant presence of exsutado in animals that did not receive the product.

As for color, it was found that the cyanotic color was present in Gprpm and Gprpl, this fact can be correlated with the presence of hemorrhagic areas from the anastomosis of neovascularization. Soon as pinkish in Gprpme and Gprple indicated the integrity of grafts. Thus the results suggest that the use of surgical sponges PRP was associated with favorable healing of the grafts. This finding is not consistent with Vendramin *et al.* (2010a), who report

the use of PRP in skin grafts in pelvic limb human being capable of reducing the size of the lesion by promoting the larger amount of granulation tissue and presenting a pinkish appearance of the skin when compared with patients not receiving the product. Thus, it can be assumed that the use of PRP with a combination of surgical sponges resulted in better color since the use of surgical sponges promoted adequate pressure on the wound and attached to the PRP favored healing.

Regarding the cosmetic appearance of the wound, it was found that variable in Gprple and Gprpme ranging from excellent to good, with such features can be inferred that the use of PRP associated with surgical sponges is favorable to the healing of the grafts. At the end of 15 days was found in graft integration receptor site, so the pressure of the sponges and angiogenesis stimulating factors present in the PRP are capable of replacing the granulation tissue and promote proper healing of the grafts. The results of this trial are consistent with Vendramin *et al.* (2010b), who used the platelet rich plasma autologous skin grafts in rabbits, and were favorable results in wound healing. Regarding the use of surgical sponges, the results obtained in this study corroborate Zanini *et al.* (2004), who used a surgical sponge as a pressure dressing for skin grafts in humans, and obtained favorable results in healing, and indicate and advise the use of surgical sponges in skin grafts.

Histological evaluation of the intensity and quantification of vascular proliferation evaluated by histochemical method Hematoxylin & Eosin (HE) and Masson's it was found that this variable was significant in Gprpme ($p=0.01$) (Figure 2A) when compared with the Gprpl (Figure 2B) and Gcme (Figure 2C), mean vessel 55; 33 and 14 shown respectively in groups. In Gprpm proliferation of vessels was compared with Gprpl significant ($p=0.01$) and Gcme ($p=0.01$) with a mean of 32.3 vessel; 34 and 14.6 respectively in our groups, and among the other groups there was no significant difference ($p>0.05$).

Comparing the semi-quantitative and quantitative evaluation methods no significant difference between the two methods ($p>0.05$). However, the more appropriate analysis is quantitative to be reliable, and as the histochemical method, Masson's Trichromic is best for visualization of the vessels compared to HE.

When was evaluated the angiogenesis in wound using Caveolin-1, found a significant presence of vascular proliferation ($p<0.05$). The microvessel count on the of the wound using Caveolin-1 was significant at Gprpme ($p<0.05$) (Figure 3A), compared with the Gprpl (Figure 3B) and Gcme (Figure 3C), averaging 56.5 vessels; 33.5 and 15.3 respectively appear in groups. In Gprpm vascular proliferation was significant ($p<0.05$) compared with Gprpl and

Gcme, with an average of 38.6 vessels; 33.5 and 15.3 respectively in our groups, and among the other groups there was no significant difference (*p>0.05*).

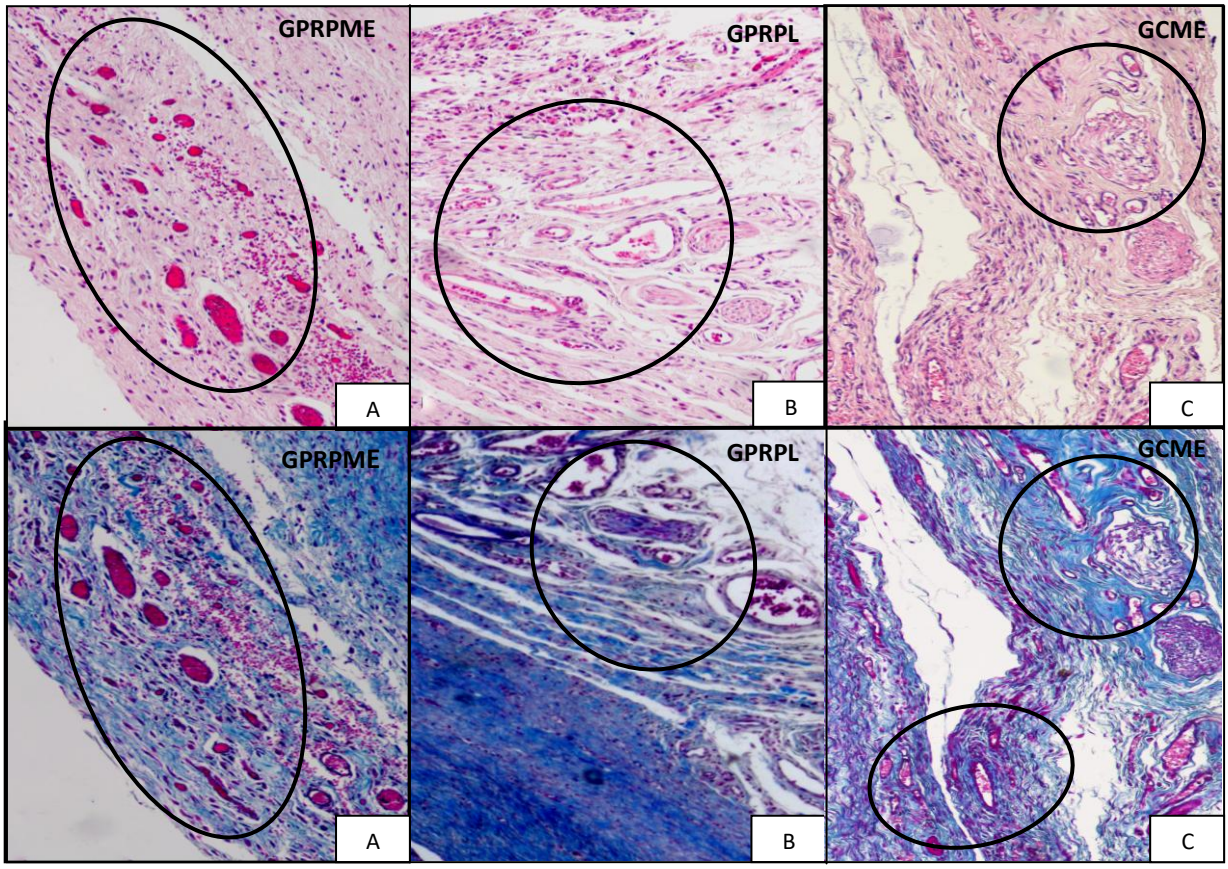

Figure 2 Histology of vascular proliferation intensity in rabbits (Oryctolagus cuniculus). Photomicrography optical dermal animals submitted to reconstructive surgery procedure at the Veterinary Hospital of the Faculty of Agricultural and Veterinary Sciences (FCAV) of Unesp, Jaboticabal Campus, 2015.A) marked presence of neovascularization in circumscribed area in Gprpme. B) Presence of neovascularization circumscribed region in Gprpl. C) discreet presence of neovascularization in circumscribed area in Gcme. 100X. HE staining and Masson's trichrome respectively.

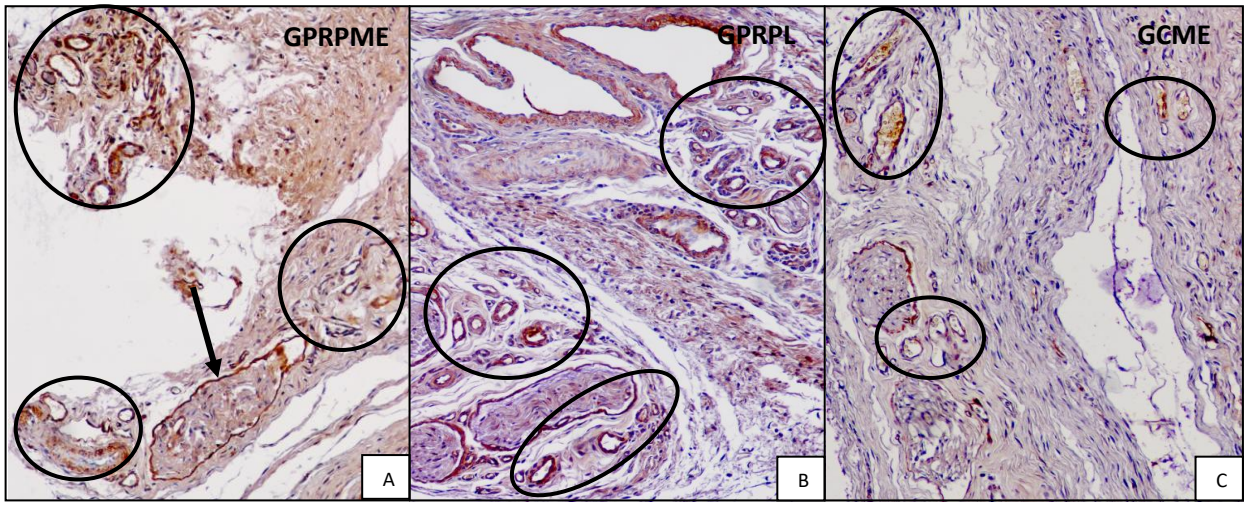

Figure 3 Histology of vascular proliferation in rabbits (Oryctolagus cuniculus). Photomicrography optical dermal animals submitted to reconstructive surgery procedure at the Veterinary Hospital of the Faculty of Agricultural and Veterinary Sciences (FCAV) of Unesp, Jaboticabal Campus, 2015.) Presence marked neovascularization in circumscribed area in Gprpme, noting the presence of nerve skin (arrow). B) Presence of neovascularization circumscribed region in Gprpl. C) discreet presence of neovascularization in circumscribed area in Gcme. 100X. Immunostaining with Caveolin-1. Polymer Detection Systems.

The use platelets plasma rich in the recipient bed subcutaneous wound was provided good results in the Gprpme and Gprpm when compared with other groups that receiving PRP and saline solution, so that the difference found significant as the vascular proliferation is related to the use of PRP as well as the type of graft employed. Therefore, it can be inferred that this compound is efficient of promoting angiogenesis at the site of application and stimulate granulation tissue formation due to its growth factors, this was observed under the receptor site does not present the prior presence of tissue granulation before use of the graft, and applying the PRP was good integration of the graft in the recipient bed as described in the literature (Huppes *et al.*, 2015). Is worth emphasizing that the model of the surgical technique may be related to the success of healing, and this test was clear that use of surgical sponges associated with PRP favored the integration of grafts in the recipient bed, and comparing the models grafts used can infer the mesh graft exhibit best characteristics compared to the layered, and these findings are consistent with Pazzini *et al*. (2015), describing the model mesh as best as compared layer, since this is more easily expand to the receptor, promote drainage of secretions and shows survival rate 90 to 100%.

As to the wound inflammatory response has evaluated the presence of mononuclear cells and polymorphonuclear cells among experimental groups, with the presence of mononuclear Gcme significant ($p=0.01$) when compared with Gprpme, and showing no difference with the other groups. The presence of polymorphonuclear was significant when

compared to the Gcme Gprpl and Gprpm (*p=0.01*), and significant when compared to the Gcl and Gprpl Gprpm (*p=0.01*), indicating the presence of inflammatory reaction resulting from the healing process the surgical wound. The results found in this study are contrary to the Vendramin *et al.* (2010b), who used the PRP skin grafts in rabbits and were significant differences in treated groups compared with the control for the presence of inflammatory cells associated with the use of the product with increased inflammatory response and yet have obtained good results with the use of the product. Also, they are contrary to achieved by Pazzini *et al.* (2016a), which used platelet-rich plasma in a retail thoracodorsal axial pattern in rabbits and found no significant difference in the presence of inflammatory cells between the treated and control groups.

Fibroblast proliferation intensity was found in the Gprpc and Gprpm significant presence compared with Gcme (*p=0.01*) and had no difference with the other groups. The intense proliferation of fibroblasts may be related to the use of PRP, by increasing fibroblast proliferation rate and extracellular matrix synthesis improving the general repairs, however, it was hoped that this fact was present in all groups that received PRP, not only into two groups. The results of this assay for the proliferation of fibroblasts show more intense in some groups that used the PRP are in agreement with Vendramin *et al.* (2010b), who used the PRP in autologous skin grafts in rabbits and found a higher concentration of fibroblasts and macrophages was used as PRP. According to Bhanot *et al*. (2002) also reported that PRP increases collagen production, angiogenesis, fibroblast proliferation and extracellular matrix synthesis improving wound healing in general.

As for collagenous evaluating collagen type I and III had a significant difference between groups (*p<0.05*). Collagen type I and III showed a significant difference when compared with each other, and important type I in Gprpme compared to Gcl (*p=0.05*), this fact can be attributed to the application of PRP, as their implementation significantly improves wound healing, considering the slip model and the use of the surgical sponge. When evaluated were, the collagen fibers type III there was no significant difference between groups. Results of this assay for the significant presence of type I collagen in Gprpme animals when compared with Gcc indicate that the scar properly progresses through the stages of healing and the end of 15 days had mature collagen and tensile strength of the wound. This fact can be justified by the use of PRP, which can stimulate mesenchymal and epithelial cells to migrate to the injured site, resulting in a mitotic division, and ultimately stimulating the matrix synthesis and collagen, resulting in faster healing and efficient (Marx, 2004).

Microscopic findings indicated the slight presence of hemorrhage in all groups, and in sometimes more severe in animals is employed PRP gel. However, it was found the presence of significant hemorrhage in Gcme ($p>0.05$) compared with Gprpme. The presence hemorrhage in Gcme animals indicates to be a case in point, given that using the PRP is the formation of new small and medium vessels caliber, and for being fragile can break up easily, resulting in the presence of local hemorrhage (Pazzini *et al.*, 2016a). Furthermore, the use of surgical sponges is also necessary to avoid the presence of the hemorrhage in the wound (Zanini *et al.*, 2004). Although there was a presence of hemorrhage in association surgical sponge, its use is also advisable, as they occur 15 days after surgery is directly related to the use of PRP and angiogenesis, and not the fact of post-surgical bleeding. The intensity of re-epithelialization and necrosis between groups was not significantly different.

Conclusions

The use of platelet-rich plasma associeted with surgical sponge as a pressure dressing improves the integration of skin grafts into the recipient bed without the prior presence of granulation tissue.PRP can stimulate new vessels and promote the repair phase and integration of the graft in the recipient bed, but when applied without the association of surgical sponges, the results indicated that their use alone is not favorable. Comparison of the graft models into mesh and layer associated with PRP, as well as surgical sponges, indicated that the best graft model is mesh type, and be associated with PRP and surgical sponge to achieve effects favorably.

Referências

BALL, E.; HAMPTON, R.; DE BOER, S.; SHAAD, N., Polyclonal antibodies. In: BALL, E.; HAMPTON, R.; DE BOER, S.; SHAAD, N. Serological methods for detection and identification of viral and bacterial pathogens - a laboratory manual. 1ª.ed., St. Paul: Minessota, USA. 1990, p. 33-54.

BANCROFT'S, J.D.; LAYTON, C.; SUVARNA, S.K. Theory and practice of histological tchniques. 7ª ed. Churchill Livingstone: Elsevier, 2012, p.381- 423.

BAUER, J.A.; CORREA, J.; LIMA, M.F.L.; LIMA, L.A.P.A.; PUSTIGLIONI, F.E. Efeitos do plasma rico em plaquetas no processo de reparação de feridas dérmicas padronizadas em ratos. *Rev. Period*, v.19, n. 3, p. 98-108, 2009.

BEDOYA, S.A.O.; CONCEIÇÃO, L.G.; VILORIA, M.I.V.; LOURES, F.H.; VALENTA, F.L.; AMORIM, R.L.; SILVA, F.F. Caracterização de colágenos tipos I e III no estroma do carcinoma de células escamosas cutâneo em cães. *Arq. Bras. Med Vet. Zootec,*, v.68, n.1, p.147-154, 2016.

BHANOT, S.; ALEX J.C. Current applications of platelet gels in facial plastic surgery. *Fac. Plast. Surg.*, v.18, n.1, p.27-33, 2002

BOLTA, P.R.Z. Use of platelet growth factors in treating wounds and soft-tissue injuries. *Acta Dermat. APA*., v.16, n.4, p.156-165, 2007.

CASTRO, J.L.C.; HUPPES R.R.; DE NARDI, A. B.; PAZZINI J.M. Princípios e Técnicas de Cirurgias Reconstrutivas da Pele de Cães e Gatos (Atlas Colorido). In. CASTRO, J.L.C; HUPPES R.R.; DE NARDI, A. B.; PAZZINI J.M. Introdução à anatomia. 1ªed. Medvep, Curitiba, 2015. Cap. 1, p.10-16.

COLEMAN, R. Picrosirius red staining revisited. *Acta Hist.*, v.113, p.231-233, 2011.

FILHO, N.P.R. Epitelização de enxertos cutâneos em feridas recentes de coelhos tratados com membrana amniótica canina e/ou laserterapia. 2015. 48f. Dissertação (Mestrado) – Universidade Estadual Paulista Júlio de Mesquita Filho, Jaboticabal, São Paulo, 2015.

GARROS, I.C.; CAMPOS, A.C.L.; TÂMBARA, E.M.; TENÓRIO, S.B.; TORRES, O.J.M.; AGULHAM, M.A.; ARAÚJO, A.C.F.; SANTIS-ISOLAN, P.M.B.; OLIVEIRA, R.M.; ARRUDA, E.C.M. Extrato de *Passiflora edulis* na cicatrização de feridas cutâneas abertas em ratos: estudo morfológico e histológico. *Acta Cir. Bras.*, v.21, supl. 3, p.55-65, 2006.

GOBI , G.L.M. Análise cicatricial de úlceras por pressão utilizando o óleo de coco ozinizado. 2013. 99f. Dissertação (Mestrado) – Universidade Camilo Castelo Branco, São José dos Campos, São Paulo, 2013.

HAY, F.C.; WESTWOOD, O.M.R.; NELSON, P.N.; HUDSON, L. Practical immunology. Malden, MA: Blackwell Science; 2002.

HEDLUND, C.S. Cirurgia do sistema tegumentar. In: Fossum, TW. Cirurgia de pequenos animais. 3ª Ed. São Paulo: Elsevier; 2008; p. 224-278.

HUPPES, R.R.; CARNEIRO, S.C.M.C.; DANTAS, A.V.E.; PAZZINI, J.M.; CASTRO, J.L.C.; SPRADA, A.G.; GUEDES, E.O.S. Enxertos cutâneos em cães com diferentes preparos no leito receptor – Relato de caso. *Medvep – Rev. Cient. Med. Vet.,* v.13, n.43,p. 22-28, 2015.

MAEDA, S. et al. Tumor angiogenesis and tumour cell proliferation as prognostic indicador in gastric carcinoma. *Brit. J. Cancer,* v.72, n.2, p. 319-323, 1995.

MARX RE. Platelet-rich plasma: evidence to support its use. *J. Oral Maxil. Surg.,* v.62, n.4, p.489-96, 2004.

PAVLETIC, M.M. Small Animal Wound Magementand Reconstructive Surgery: In: Free Grafts. 3.ed. Iowa: Wiley – Blackwell, Cap. 14, p. 404 – 431, 2010.

PAZZINI, J.M.; MORAES, P.C. Princípios e Técnicas de Cirurgias Reconstrutivas da Pele de Cães e Gatos (Atlas Colorido). 1ªed. Medvep, Curitiba, 2015, p.95-102.

PAZZINI, J.M.; DE NARDI, A.B.; HUPPES, R.R.; GERING, A.P; FERREIRA, M.G.P.A.; SILVEIRA, C.B.P.; LUZZI, M.C.; OLIVEIRA, J.A. Utilização de plasma rico em plaquetas para estimulação da angiogênese em flape de padrão axial toracordosal em coelhos (Oryctolagus cuniculus). *Pesq. Vet. Bras.,* v. 36, n.2, 108-118, 2016a.

PAZZINI, J.M.; DE NARDI, A.B; HUPPES, R.R.; GERING, A.P.; FERREIRA, M.G.P.A.; SILVEIRA, C.B.P.; LUZZI, M.C.; SANTOS, R. Method to obtain platelet rich plasma from rabbits (Oryctolagus cuniculus). *Pesq. Vet. Bras.,* v. 36, n.1, 39-44, 2016b.

RODRIGUES, F. R.; CÂNDIDO, L. C.; ASSAD, L. G.; COSTA, M. C. A.; COUTINHO, V. L. Curativos em cirurgia. In: MARQUES, R. G. Cirurgia – instrumental e fundamentos técnicos. Rio de Janeiro: Cultura Médica, 2001. p. 359-374.

SANTOS, L.A.U. Efeitos da utilização do plasma rico em plaquetas na osteointegração dos enxertos ósseos criopreservados: estudo histomorfométrico em coelhos. 2007. 140f. Dissertação (Mestrado em Ciências) – Universidade de São Paulo (USP), São Paulo, 2007.

SERAFIM, E.L. Fechamento de defeitos em padrão de figura geométrica associado ao emprego de anestesia por tumescência com lidocaína em coelhos (*Oryctolagus cuniculus*).

2016. 68f. Dissertação (Mestrado) – Universidade Estadual Paulista Júlio de Mesquita Filho, Jaboticabal, São Paulo, 2016.

VENDRAMIN, F.S.; FRANCO, D.; SCHAMALL, R.F.; FRANCO, T.R. Utilização do plasma rico em plaquetas autólogo em nas cirurgias de enxertos cutâneos em feridas crônicas. *Rev. Col. Bras. Cir.***,** v.25, N.4, p.589-594, 2010a.

VENDRAMIN, F.S.; FRANCO, D.; FRANCO, T.R. Utilização do plasma rico em plaquetas (PRP) autólogo em enxertos cutâneos em coelho. *Rev. Col. Bras. Cir.***,** v.25, p. 4-10, 2010b.

ZANINI, M.; MACHADO FILHO, C.A.S.; TIMONER, F. Uso de esponja cirúrgica para curativo compressivo de enxerto cutâneo. *Anais Bras. Dermat.*, v.79 n.3, 2004.

CAPÍTULO 4 – Using layer grafts and mesh grafts to correct significant defects induced in the carpals of rabbits (*Oryctolagus Cuniculus*) by associating platelet-rich plasma[3]

Josiane Morais Pazzini[1+], Eduardo Luis Serafim[2], Ricardo Ramirez Andrez Uscategui[1], Vivian Tavares de Almeida[1], Carlos Alfredo Calpaa Oliva[3], Fátima Gärtner[4], Irina Amorim[4], Fátima Faria[5], Alexandra Rêma[5], Nazilton De Paula Reis[1], Marília Gabriele Prado Albuquerque Ferreira[3], Ana Carolina da Silva[3], Rafael Ricardo Huppes[6], Paola Castro Moraes[7], João Ademir de Oliveira[8], Andrigo Barboza De Nardi[7]

[1] DVM, PhD, Graduate Program in Veterinary Surgery, Faculty of Agricultural and Veterinary Sciences of Jaboticabal (FCAV/Unesp), Access way Professor Paulo Donato Castellane without number, Jaboticabal, SP 14884-900, Brasil. PhD Research with the support of Capes and PDSE - Doctoral Program Sandwich, and Cnpq (Process number:147728/2016-9). E-mail: josipazzini@hotmail.com; ramirezuscategui@hotmail.com; vitalmeida21@hotmail.com; nazilton@hotmail.com. +Corresponding author: josipazzini@hotmail.com

[2] DVM, Avenue Altiro Arantes, 385, Irapuã, SP 14.990.000, Brasil. E-mail: eduardoluis.serafim@gmail.com

[3] DVM, PhD, Graduate Program in Veterinary Medicine, Faculty of Agricultural and Veterinary Sciences of Jaboticabal (FCAV/Unesp), Access way Professor Paulo Donato Castellane without number, Jaboticabal, SP 14884-900, Brasil. E-mail: calpaa@yahoo.es; mary_pops1@hotmail.com anacarolana@hotmail.com

[4] DVM, PhD, Department of Veterinary Pathology, University of Porto/ICBAS- Abel Salazar Biomedical Sciences Institute (UP-ICSBAS), Jorge Viterbo Ferreira Street, 228, Porto, 4050-313, Portugal. E-mail: fgartner@ipatimup.pt; irinamorim@hotmail.com

[5] Pathological Anatomy technique, Department of Veterinary Pathology, University of Porto/ICBAS- Abel Salazar Biomedical Sciences Institute (UP-ICSBAS), Jorge Viterbo Ferreira Street, 228, Porto, 4050-313, Portugal. E-mail: fatimafaria10@yahoo.com.br; alexandra.rema@gmail.com

[6] DVM, PhD, Department of University of Veterinary Surgery Unicesumar, Avenue Guedner, 1610- Jd Aclimação, Maringá-PR, 87050-900, Brasil. E-mail: rafaelhuppes@hotmail.com

[7] DVM, PhD, Department of University of Veterinary Surgery, Faculty of Agricultural and Veterinary Sciences of Jaboticabal (FCAV/Unesp), Access way Professor Paulo Donato Castellane without number, Jaboticabal, SP 14884-900, Brasil. E-mail: pcastromoraes@yahoo.com.br; andrigobarboza@yahoo.com.br

[8] Statistical, PhD, Department of Statistics, Faculty of Agricultural and Veterinary Sciences of Jaboticabal (FCAV/Unesp), Access way Professor Paulo Donato Castellane without number, Jaboticabal, SP 14884-900, Brasil. E-mail: jaoliv@fcav.unesp.br

Conflict of Interest declaration: There is no conflict of interest by any of the authors
Word count: Abstract 299, Full text 2872
Number of figure: 2

[3] Resultados submetidos BMC Veterinary Research. Normas publicação (Anexo II).

ABSTRACT - Platelet-rich plasma (PRP) can be used in the healing process of reconstructive surgery due to its stimulation potential in the formation process of new blood vessels. This study was done to evaluate the effectiveness of PRP in full thickness skin grafts layer and mesh rabbits to assess the possibility of PRP in further integration from the graft to the receptor without a prior presence of granulation tissue and also to evaluate which type of graft has a better healing. For this study, thirty two rabbits were used, divided into four groups of eight animals. The groups were divided in Gprpl (PRP, layer graft), Gcl (control, 0.9% saline solution, layer graft), Gprpm (PRP, mesh graft) Gcm (control, 0.9% saline solution, mesh graft). Macroscopic lesions evaluations were performed after three, seven, and 14 days of surgery. Moreover, to evaluate the wound healing it took place with some microscopic evaluations within 15 days of surgery. The data was submitted to statistical analysis (paired t-test, Kruskal-Wallis, analysis of variance, Tukey test, $p<0.05$). Edema, coloring, exudate and cosmetic appearance on the 3rd day were not significant; the 7th day exudate was significant. With 14 days coloring was significant. The quantification of vascular proliferation was significant; although, presence of mononuclear cells and polymorph nucleate was not significant; fibroblast proliferation was also not significant; collagenous on the contrary was significant; re-epithelialization and hemorrhage were no longer significant. We could conclude that the use of PRP in the form of a gel in skin grafts contributes to deploy in the receptor without a prior presence of granulation tissue. The comparison between the grafts models mesh and layer associated with the use or not of PRP indicated that the best graft model is the mesh type, and should be used along with the application of PRP.

Keywords: reconstructive surgery, mesh graft, layer graft, PRP, rabbit.

Introduction

In reconstructive surgery grafts are one of the modalities which is used to correct extensive wounds from trauma and tumors. It's a segment from the epidermis and the dermis which are completely removed from the donor site and transferred to the recipient bed [10] by being devoid of artery and vein in its constitution, they are affected by necrosis after being implanted in the recipient bed [17].

Considering the complications related to angiogenesis grafts, some studies suggest that platelet-rich plasma (PRP) act as an adjuvant in the healing process when having reconstructive surgery because of its auxiliary potential in the stimulation process in a formation of new blood vessels [15]. However, other authors reported some contradictory results when using the product and suggested that more experimental studies needed to be done to prove the evidence and effectiveness of the product [7].

This study aimed to evaluate the efficiency when using platelet-rich plasma (PRP) in skin grafts Full thickness layer and mesh rabbits (Oryctolagus cuniculus) in order to assess the possibility of PRP and promote the integration between the graft to the receptor without a prior presence of granulation tissue and then to evaluate which type of graft has a better healing.

Material and methods

This study surgical procedures were performed in the Veterinary Hospital "Governador Laudo Natel" of the Faculty of Agricultural and Veterinary Sciences (FCAV/UNESP), in Jaboticabal. The blades destined to histological analysis were made in Veterinary Pathology Laboratory of the University of Porto, Portugal. This study was approved by the Ethics Committee on Animal Use (CEUA) of the Faculty of Agricultural and Veterinary Sciences (FCAV/UNESP), Jaboticabal (number protocol: 11767/14).

The experimental model used to perform the reconstructive surgery was the rabbit (*Oryctolagus cuniculus*). It was used 32 rabbits White New Zealand, with about 60 days of age, and were all females. The rabbits were kept at the biotery Postgraduate Course in Veterinary Surgery according to the ethical principles of animal testing recommended by the National Council for Animal Experimentation Control (CONCEA).

The animals were divided into four groups of eight animals each, the reconstructive surgery technique used was grafting layer and mesh. The groups were Gprpl (PRP, layer graft), Gcl (control, 0,9% saline solution, layer graft), Gprpm (PRP, mesh graft), Gcm (control, 0.9% saline solution, mesh graft). The anesthetic protocol which the animals were submitted consisted of midazolam dose of 0.5 mg/kg intramuscular (IM) and tramadol hydrochloride at a dose of 5 mg/kg by the same way. After the anesthetic, blood samples were collected from the 32 rabbits and were submitted through the sealed face mask with isoflurane in 3% dose diluted in 100 % oxygen, to produce surgical anesthesia.

Right after the blood samples were collected, the 32 rabbits underwent the surgical procedure. Blood samples from the Gcl and Gcm were not submitted to the PRP preparation, only collected to have no difference between groups regarding the volume of body blood. The preparation of platelet-rich plasma was conducted as recommended by the literature [16].

Surgical procedure for reconstruction using graft was performed in a single moment, replacing the granulation tissue by platelet-rich plasma. The dermal-epidermal wound was made on the left wrist, which was used by a surgical pen and sterile ruler creating then a lesion of 4 cm long by 4 cm wide in the square format. Following the carpal fragment, it was excised approximately 3 cm below the olecranon, promoting the formation of an extensive wound.

The difference between the layer and mesh grafts are slots in the manufacture of mesh graft. In both grafts residues of fat and subcutaneous were removed.

After performing the injury carpus, it was held in lateral left chest a skin incision in a square format, with limits determined according to the anatomical references described in the literature [14].

The following procedure was performed carefully, a graft dissection and a removal of the donor bed, when finishing this step, a residues removal of a fat and subcutaneous fragment was made. In mesh graft was made the slits, and the layer graft was made only in the waste cleaning. Subsequently it was promoted a hemostasis of local vessels in the recipient bed and it began the implementation of the graft. Sutures were simple interrupted by using 4-0 nylon, beginning of vertices of the square between the donor tissue site with the receptor, to avoid to not have a movement of the graft at the time of suturing, and following, it proceeded to the synthesis of the surgical wound. Platelets-rich plasma (PRP 0.7ml) was applied in Gprpl and Gprpm before carpal injury synthesis with the aid of the scalpel handle and distributed evenly between the subcutaneous tissue of the donor site and the subcutaneous tissue of the recipient bed, and the beasts of the Gcl and Gcm received 0.7ml of saline solution. Next respective solutions were applied to the synthesis of the surgical wound.

Macroscopic assessments were wound evaluated for the exudate, color, edema, and cosmetic appearance of the wound. On the 15th day after the surgery, the animals were euthanized for microscopic evaluation from material collected. Euthanasia was performed according to the ethical principles of animal testing recommended by the Council National Animal Experimentation Control (CONCEA). The material was referred to for Veterinary Pathology Laboratory at the University of Porto, Portugal, for making the slide for microscopic evaluation.

The samples were processed by conventional routine histological processing, embedded in paraffin blocks, and realization of histological sections. These were cut on a microtome with a thickness of 2 micrometers in a sequence; hydration was carried out at increasing dilutions of alcohols and diaphanization in xylol.

A microscopic evaluations regarding quantification and intensity of vascular proliferation in the dermis were performed under an optical microscope to divide analyzes in the cut portions in two parts comprising: distal and proximal subcutaneous region. The histological analysis was performed by the same pathologist (FG) without prior knowledge of identification of groups. Histological evaluation of tissue was examined under an optical microscope at 400x magnification. The photomicrographs were held at NIS program - Nikon Imaging Software Elements version 30.4 NIS program - Nikon Imaging Software Elements version 4.30.

The sections were stained by histochemical method for further analysis in microscopy. We used Hematoxylin & Eosin for evaluation of epidermis and dermis for the presence of necrosis, mononuclear cells, polymorphonucleate, fibroblast proliferation and hemorrhage; Hematoxylin & Eosin and Masson's Trichromic (blue contrast) for vascular proliferation; Picrosirius (Easy Path - Sirius Red Staining) for evaluation collagenous.

The data obtained was determined by the semiquantitative and quantitative method of as recommended to the literature [8,12]. Only for the data of the PicroSirius, sections were analyzed by optical microscopy under polarized light (Olympus BX-53 ®, Japan). The observation of the collagen fibers through this method allowed the differentiation of type I collagen (birefringence yellowish-

orange to orange and red) and type III (green or yellow-green birefringence) [6]. Of each slide were selected and photomicrographed ten histological fields with a digital camera (5.0m) in increased 20x. The images were analyzed with the aid of software Image J®, with the plug-in Colour Threshold, obtaining the percentage of collagen by analysis of automated particle according selection and extent of areas based on color as described in the literature [3].

For the immunohistochemical study, a panel of antibodies specific for several antigens was applied (Table 1). The glass slides was previously cleaned and degreased, prepared with prepared with organosilane-based adhesive (3-aminopropyl triethoxysilane, C.O. Sigma Chemical, USA). Vectastain elite ABC Kit and Novolink^{tm} Polymer Detection Systems were used according to the manufacturer's instructions.

Table 1. Antibodies used for immunohistochemistry cutaneous tissues of rabbits conducted in Veterinary Pathology Laboratory of the University of Porto, Portugal, in 2016.

Maker	Clone	Supplier	Dilution	Antigenic recovery	Incubation period	Detection system	Positive control
Ae1/Ae3	Monoclona, Ae1/Ae3	ImPath, USA	1:400	Maria Bath (BM), Novocastra^{tm} Epitope Retrieval Solutions	Over night à 4º	Vectastain elite ABC Kit	Rabbit normal skin
Caveolina-1	Policlonal, anti-Caveolina	BD Pharmingen	1:500	-	45 minutos (37º)	Novolink^{tm} Polymer Detection Systems	Rabbit normal skin

The data obtained from the Ae1/Ae3 were evaluated in photomicrographs obtained by an optical microscope, increased 2x, made NIS program - Nikon Elements Imaging Software version 4.30. Subsequently, the images were analyzed with the aid of software Image J®, with the plug-in Colour Threshold to yield the percentage of the total area of re-epithelialization of the wound using the automated particle analysis according to the selection and measurement areas with based on the color [9]. The angiogenic index for Caveolin-1 was determined by microvessel counting technique (MVC) according to the literature [12].

Statistical analysis

The comparison between groups (Gprpl, Gcl, Gprpm, Gcm) in relation to the categorical variables (exudate, edema, coloring, cosmetic appearance, vascular proliferation, mononuclear cells, polymorphonuclear cells, fibroblast proliferation, hemorrhage and necrosis) was performed by Kruskal-Wallis test, with subsequent use of the multiple comparison test of Dunn, for cases in which there was significant difference between the medians of the groups. In all tests, p values equal or less than 0.05 ($p < 0.05$) was considered significant. For the analysis was used Npar1way procedure computer program SAS (SAS 9.1, SAS Institute, Cary. NC, USA) and the GraphPad Prism program, Version 4.00.

The data re-epithelialization and collagen of different types of collagen fibers, according to the degree of differentiation were compared by analysis of variance (F test) for an entirely randomized

design with four groups and eight repetitions per group, considering p values equal or less than 0.05 ($p < 0.05$) significant. The evaluation data immunohistochemistry using Caveolin-1 were also subjected to analysis of variance, with four groups (Gprpl, Gcl, Gprpm, Gcm) and five repetitions (average) per group and level of significance of 5%. In both cases, there was a significant difference between means ($p < 0.05$), these were compared by Tukey test at the level of significance (5%). For this analysis we used the General Linear Models Procedure (GLM) of the SAS computer software (SAS 9.1, SAS Institute, Cary. NC, USA).

Results and Discussion

Exudate that has been found in this study in Gprpm ($p=0,03$) the 7th day can be justified by the application of PRP due product stimulation healing presence of exudate is expected in the early stages of healing, and in this case, at the end of 14 days was absent. The results of this study are in agreement with the labor Vendramim et al. [19], who used the platelet rich plasma (PRP) autologous in skin grafts in rabbits and proved the occurrence of increased inflammatory reaction with the utilization of the product, and inflammatory phenomena were expected by the application of PRP due to its ability to enhance the healing can occur such increased presence of exudate.

The cyanotic coloring in Gprpm ($p = 0.01$) was significant when compared to the Gcl, which showed pallid coloration. In Gprpl ($p = 0.01$) cyanotic coloring has been considerable when compared to that presented pallid Gcm. Evaluating the same variable, there was a significant difference of cyanotic color in Gprpm when compared to the Gcm. Thus, evaluating the cyanotic coloration in groups it was used the PRP can be inferred that by the application the product, there was a local inflammatory reaction, due to edema and vasodilation of blood vessels occurred hemorrhage, featuring blackened aspect as described in the literature [1]. However, the results of this test are contrary to those obtained by Bauer et al. [2], which assessed the effects of platelet-rich, plasma in the repair process of standardized dermal wounds in mouse, and found no significant differences in skin color.

The intensity of vascular proliferation evaluated by histochemical method hematoxylin & eosin and Masson's Trichrome was significant in Gprpm (Figure 1A) compared to Gprpl (Figure 1B) ($p=0.01$), and among the other groups were not significant difference ($p > 0.05$). The quantification of vascular proliferation using Caveolin-1 was significant at Gprpm (Figure 1A) ($p < 0.01$) compared with Gprpl (Figure 1B), mean vessels 38.6 and 33.5 respectively in groups presented, and among the other groups there was no significant difference ($p > 0.05$).

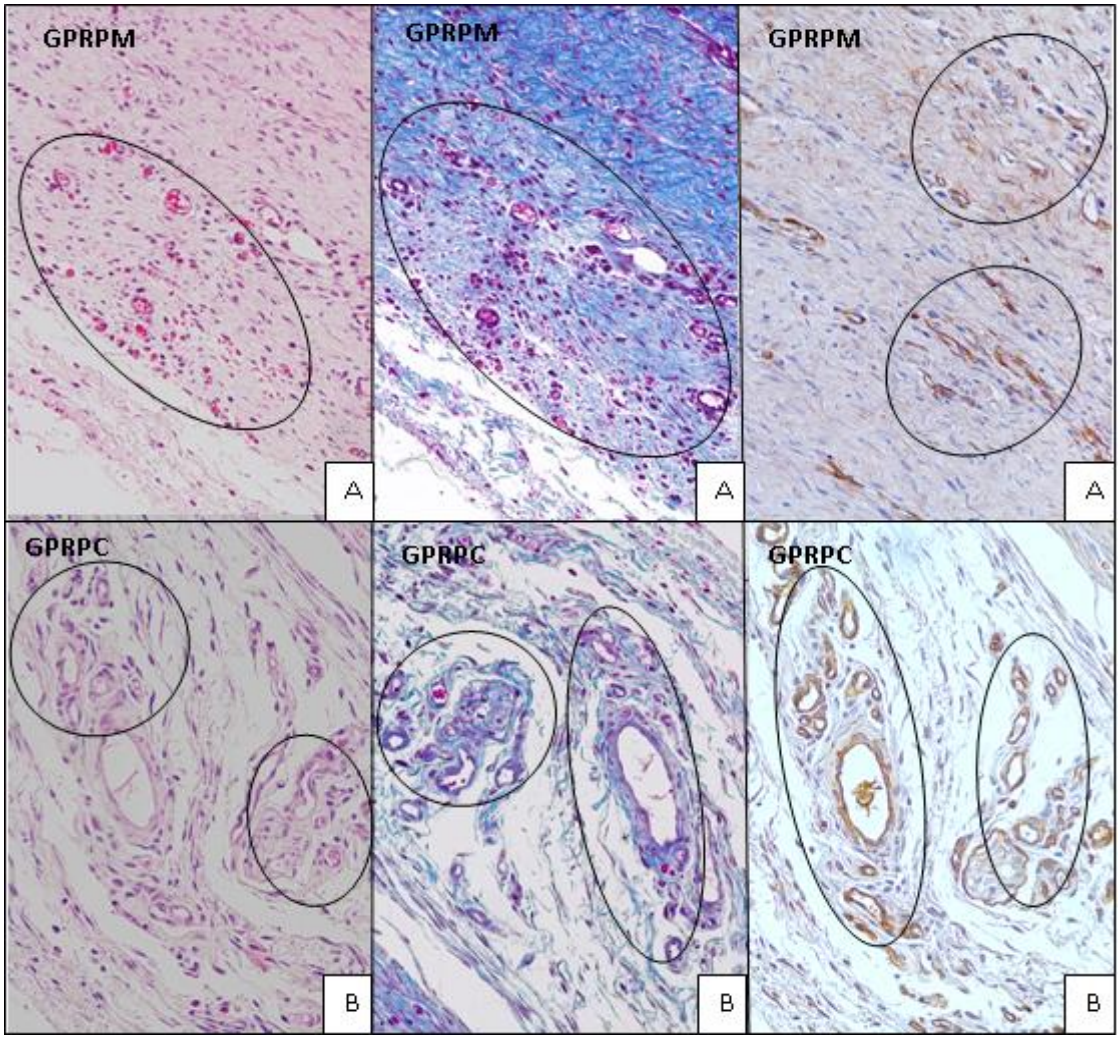

Figure 1. Histology of vascular proliferation in rabbits (Oryctolagus cuniculus). Photomicrography optical dermal animals submitted to reconstructive surgery procedure at the Veterinary Hospital of the Faculty of Agricultural and Veterinary Sciences (FCAV) of Unesp, Jaboticabal Campus, 2015. A) Presence of neovascularization in circumscribed area in Gprpm. B) Presence of discrete neovascularization in circumscribed area in Gprpc. Increase of 200X. HE staining, Masson's trichrome, and Immunohistochemistry with Caveolin-1 (Polymer Detection Systems) respectively.

Vendramin et al. [18] and Pazzini et al. [15], report that the PRP has components that improve healing, by stimulating angiogenesis, which has been used in reconstructive techniques associated in humans and animals. Considering the favorable effects described with the use of PRP, it may be suggested that stimulation of angiogenesis found in this test was made through the use of the product, although it used the product into two groups, differing type of graft, the results indicated that the angiogenesis was higher in Gprpm animals, alluding to Pazzini et al. [14], that describe the mesh grafts are better than in layer, for better promote secretion drainage as well tissue expansion, and the stimulation of angiogenesis findings were consistent with Pazzini et al. [15], who used the platelet-rich plasma to stimulate angiogenesis in Thoracodorsal axial pattern flaps in rabbits, and had significant differences in the presence of vessels when comparing the control group and treated, and claim that the platelet-rich plasma in a gel in reconstructive surgery was able to stimulate angiogenesis.

As for Graft implantation in the recipient bed without the presence of granulation tissue, which was replaced by PRP, it can be seen that the application of PRP gel favored the integration of the graft in the recipient bed as also described by Huppes et al. [11], who used in dog platelet rich plasma in skin grafts implanted into mesh without granulation tissue wounds and had good results.

Inflammatory reaction there was not the significant difference ($p>0.05$) between groups relating the presence of mononuclear cells and polymorphonucleate. The results of this test are contrary to Vendramin et al. [20], who used the PRP skin grafts in rabbits and were significant differences in treated groups compared with the control for the presence of inflammatory cells associated with the use of the product with increased inflammatory response and yet have obtained good results with the use of the product. However, make reference with Pazzini et al. [15], which used platelet-rich plasma in flap thoracodorsal axial pattern in rabbits, and also found no significant difference in the presence of inflammatory cells between the treated and control groups.

Fibroblast proliferation intensity was no significant difference ($p>0.05$) between groups. It is known that fibroblast proliferation may be related to the use of PRP, increasing their rate of proliferation and synthesis of extracellular matrix, promoting repair [4, 13], however in such a fact was observed in this study.

Evaluating collagenous found significant difference ($p<0.05$) between groups. This variable was significant in Gprpm (Figure 2A) compared with Gcm (Figure 2B) ($p=0.05$), Gprpl (Figure 2C) and Gcl (Figure 2D) ($p= 0.05$) that can be attributed the application of PRP, as have occurred considerable improvement in wound healing.

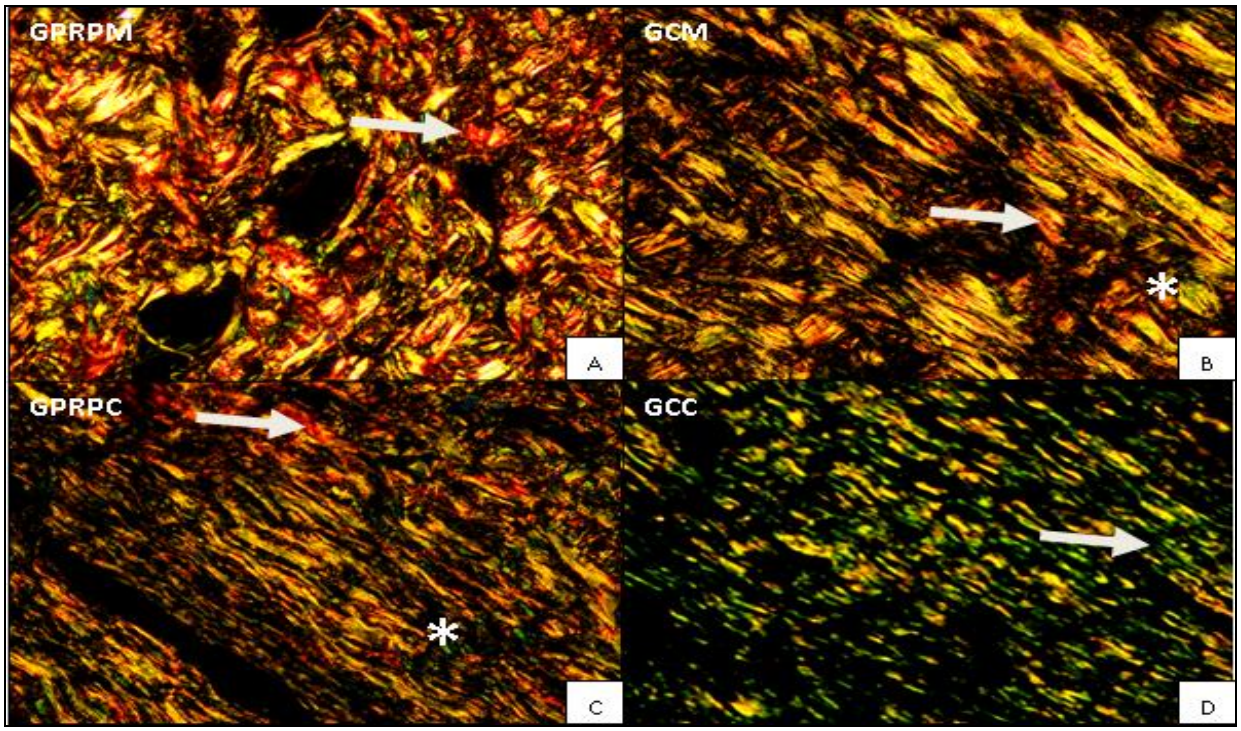

Figure 2. Colagenous in rabbits (Oryctolagus cuniculus). Photomicrography optical polarized light of the dermis of animals submitted to reconstructive surgery procedure at the Veterinary Hospital of the Faculty of Agricultural and Veterinary Sciences (FCAV) of Unesp, Jaboticabal Campus, 2015. Note difenças of collagen fibers in circumscribed area in the different groups. A) Fibers in shades of red and orange suggest collagen type I (arrow). B) Fibers in shades of red and orange suggest collagen type I (arrow) and fibers in shades of green suggest type III collagen (asterisk). C) Fibers in shades of red and orange suggest collagen type I (arrow) and fibers in shades of green suggest type III collagen (asterisk). D) Fibers in shades of green suggest type III collagen (arrow). Increase of 200X. Picrosirius coloring.

The results from this study shows a reference to the findings in the literature [4,13], who also reported that PRP increases collagen production rate by improving the repair. Other authors [15] also found increased collagen deposition in the groups treated with PRP in reconstructive surgery, however, were not significantly different between the groups.

Collagen type I and III showed a significant difference when compared to each other ($p < 0.05$), and significant type I in Gprpm, Gprpl and Gcm ($p < 0.05$) when compared with Gcl, this fact indicates that the application of PRP significantly improves the healing of wounds, it is important to point out that there was a significant presence of collagen type I in one of the groups that did not use the product and may correlate this fact with graft model.

When collagen fibers type III was evaluated, there was not the significant difference between the groups. The results found in this study as the collagenous make a reference with Bolta [5] and Vendramin et al. [19], report the PRP's ability to stimulate angiogenesis, mitogenesis, and chemotaxis, producing new vessels, fibroblasts, collagen, and ultimately resulting in better tissue repair.

Regarding the type of graft employed, it was observed that the model mesh presents better compared to the layer. Although it one of the groups it was used the graft layer associated with the PRP has shown good results, although success rates with mesh graft are larger, and the findings in this

test consistent with Pazzini et al. [14], that describe the model mesh as best as compared to layer, by virtue of this present better drainage of secretions, be easy to expand the recipient bed and can be used in places with low infection rate, and also emphasize that the survival rates vary from 90 to 100%.

The intensity of re-epithelialization and hemorrhage in the groups there was not the significant difference ($p > 0.05$). However, using PRP was expected higher re-epithelialization and hemorrhage due to intense mitogenesis and angiogenesis that the product promotes, resulting in the growth of epithelial layers and formation of new vessels, which can rupture resulting in local hemorrhage, but such changes were not present in this study. Thus, the results are contrary to Pazzini et al. [15], who used the PRP in Thoracodorsal axial pattern flaps in rabbits and had intense re-epithelialization in animals that used the product, but for hemorrhage found no significant difference between the groups, and the hemorrhage findings of this research consistent with the literature [15].

Conclusions

This study results demonstrate that the use of platelet-rich plasma in the form of a gel in skin grafts contributes to their integration into the recipient bed without the prior presence of granulation tissue.

When compared the grafts models mesh and layer associated with the use or not of PRP it was observed that the best graft model is the mesh type, and it should be employed together with the application of PRP.

Author's contribution

JMP - responsible for the project, JMP, ELS - executed the surgery. RRAU, VTA – anesthetist, CACO, MGPAF - PRP production, FG , IA, FF, AR - pathological analysis, NPR, ACS - observers of macroscopic analysis, JAO- written and analyzed the data, ABD, PCM, RRH - advisers the project. All authors critically revised the manuscript for important intellectual contents and approved the final version.

Acknowledgements. Faculty of Agricultural and Veterinary Sciences (FCAV/UNESP) the structure and laboratory support; Capes to the scholarship accorded in Brazil and Portugal (PDSE); Cnpq to the scholarship, the laboratory team at the University of Porto for supporting activities conducted.

References

1. Abbas AK, Kumar V, Fausto N, Aster JC (2013) Robbins & Cotran Patologia - Bases Patológicas das Doenças. Inflamação e reparo. Rio de Janeiro: Elsevier.

2. Bauer JÁ, Correa J, Lima MFL, Lima LAPA, Pustiglioni FE (2009) Efeitos do plasma rico em plaquetas no processo de reparação de feridas dérmicas padronizadas em ratos. Rev Periodontia, 19, 3, 98-108.

3. Bedoya SAO, Conceição LG, Viloria MIV, Loures FH, Valenta FL, Amorim RL, Silva FF (2016) Caracterização de colágenos tipos I e III no estroma do carcinoma de células escamosas cutâneo em cães. Arq Bras Med Vet Zoo, 68, 1, 147-154.

4. Bhanot S, Alex JC (2002) Current applications of platelet gels in facial plastic surgery. Facial Plas Surg, 18,1,.27-33.

5. Bolta PRZ (2007) Use of platelet growth factors in treating wounds and soft-tissue injuries. Acta Dermat APA, 16, 4, 156-165.

6. Coleman R (2011) Picrosirius red staining revisited. Acta Histochem, 113, 231-233.

7. Garcia RV (2005) Utilização de plasma rico em plaquetas (PRP) associado a implantes intra-ósseos em mandíbulas de cães. Análise Histológica. 2005.93f. Tese (Doutorado em Odontologia) – Universidade Estadual Paulista – UNESP- Araraquara.

8. Garros IC, Campos ACL, Tâmbara EM, Tenório SB, Torres OJM, Agulham MA, Araújo ACF, Santis-isolan PMB, Oliveira RM, Arruda ECM (2006) Extrato de *Passiflora edulis* na cicatrização de feridas cutâneas abertas em ratos: estudo morfológico e histológico. Acta Cir Bras, 21, 3, 55-65.

9. Gobi GLM (2013) Análise cicatricial de úlceras por pressão utilizando o óleo de coco ozinizado. 99f. Dissertação (Mestrado) – Universidade Camilo Castelo Branco, São José dos Campos, São Paulo.

10. Hedlund CS. (2008) Cirurgia do sistema tegumentar. In: Fossum, TW. Cirurgia de pequenos animais. São Paulo: Elsevier.

11. Huppes RR, Carneiro SCMC, Dantas AVE, Pazzini JM, Castro JLC, Sprada A.G, Guedes EOS (2015) Enxertos cutâneos em cães com diferentes preparos no leito receptor – Relato de caso. Medvep, 13, 43, 22-28.

12. Maeda S. et al (1995) Tumor angiogenesis and tumour cell proliferation as prognostic indicador in gastric carcinoma. Brit J Cancer, 72,2, 319-323.

13. Man D, Plosker H, Winland-Brown JE (2001) The use of autologous platelet rich plasma (platelet gel) and autologous platelet-poor plasma (fibrin glue) in cosmetic surgery. Plast Reconst Surg, 107, 1, 229-37.

14. Pazzini JM,Moraes PC 2015 Princípios e Técnicas de Cirurgias Reconstrutivas da Pele de Cães e Gatos (Atlas Colorido) Medvep, Curitiba.

15. Pazzini JM, De Nardi AB, Huppes RR, Gering AP, Ferreira MGPA, Silveira CBP, Luzzi MC, Oliveira JA (2016) Utilização de plasma rico em plaquetas para estimulação da angiogênese em flape de padrão axial toracordosal em coelhos (Oryctolagus cuniculus). Pesq Vet Bras, 36, 2, 108-118.
16. Pazzini JM, De Nardi AB, Huppes RR, Gering AP, Ferreira MGPA, Silveira CBP, Luzzi MC, Santos R (2016) Method to obtain platelet rich plasma from rabbits (Oryctolagus cuniculus). Pesq Vet Bras, 36, 1, 39-44.
17. Tobias KM (2011) Manual de cirurgia de tecidos moles pequenos animais: Enxertos em Malha de Espessura total. São Paulo: Roca.
18. Vendramin FS, Franco D, Nogueira CM, Pereira M, Franco TR 2006 Plasma rico em plaquetas e fatores de crescimento: técnica de preparo e utilização em cirurgia plástica. Rev Col Bras Cir, 33, 24-28.
19. Vendramin FS, Franco D, Schamall RF, Franco TR 2010 Utilização do plasma rico em plaquetas autólogo em nas cirurgias de enxertos cutâneos em feridas crônicas. Rev Bras Cir Plás, 25, 4,589-594.
20. Vendramin FS, Franco D, Franco TR 2010 Utilização do plasma rico em plaquetas (PRP) autólogo em enxertos cutâneos em coelho. Rev Bras Cir Plás, 25, 4-10.

CAPÍTULO 5 – Histochemical and immunohistochemical evaluation of angiogenesis in rabbits having undergone skin grafts associated with platelet-rich plasma[4]

Josiane M.Pazzini[2+], Eduardo L. Serafim[2], Fátima Gärtner[3], Irina Amorim[3], Fátima Faria[3], Alexandra Rêma[3], Paola C. Moraes[2], Andrigo B. De Nardi[2]

ABSTRACT .– Pazzini J.M., Serafim E.L., Gartner, F., Amorim, I., Rêma A., Moraes P.C & De Nardi A.B. 2016. **Histochemical and immunohistochemical evaluation of angiogenesis in rabbits (Oryctolagus cuniculus) submitted to the use of skin grafts associated with platelet-rich plasma.** Pesquisa Veterinária Brasileira 00(0):00-00**.** Departamento de Clínica e Cirurgia Veterinária, Faculdade de Ciências Agrárias e Veterinárias, Universidade Estadual Paulista, Campus Jaboticabal, Via de Acesso Paulo Donatto Castellane s/n, Jaboticabal, SP 14884.900, Brazil. E-mail: josipazzini@hotmail.com

Histochemical Staining consists of a set of specific chemical reactions of structures or tissue-endogenous substances. Immunohistochemistry allows the observation proteins in tissues relating to biological and pathological factors.. The standardization of methods assessing angiogenesis resulting from the formation of new blood vessels in procedures utilizing stimulants is important in facilitating the implementation of the research as well as in assisting in the interpretation of data.. In rabbits some markers of angiogenesis antibodies in the skin are not standardized because of cross-reactions that may occur because the antibodies are made from such animals.The aim of this study is to analyze the immunohistochemical methods through dyes and immunohistochemical markers angiogenesis in rabbits (Oryctolagus cuniculus) having undergone reconstructive surgery with skin grafts associated with plasma angiogenesis stimulator rich in platelets, in order to evaluate which method would be better to visualize the vessels, as well as to evaluate which antibody would promote better immunostaining, and find the differences between the methods and to standardize the methodology to be applied in experiments using rabbits 16 rabbits were used, split into two groups of eight animals: Gprp (plasma rich in platelets) and Gc (control, saline solution, 9%). The same technique of reconstructive surgery using graft mesh was performed on each animal.The groups differed only the application of platelet-rich plasma before the surgical wound synthesis. Samples for evaluation of angiogenesis were collected 15 days after the surgical procedure. The dyes Hematoxylin & Eosin and Masson's Trichrome were used in the histochemical study to evaluate vascular proliferation. Markers CD31, CD34 and Caveolin-1 were used for the immunohistochemical study.The evaluation between the groups (Gprp and Gc) in relation the categorical variable (vascular proliferation intensity) used the Kruskal-Wallis test with p values equal to or less than 0.05 being considered significant. The immunohistochemical were subjected to analysis of variance for a completely randomized design, with two groups and five repetitions (medium) and 5% significance level. Multiple comparisons of group resulted in the Tukey test (p=0,05) being used. The amount of vascular proliferation assessed by histochemical method HE and Masson's Trichrome was found to be a significant variable inGprp when compared with group Gc. When evaluating the methods used, there was no significant difference. There was no difference in the three markers which were used for correlating microvessels; however, there was more intense staining of vessels when using Caveolin-1 Antibody This caused intense marking of the capillaries and small vessels, as well as of larger vessels. When using CD31 and CD34, the same was observed, but it was not as intense as with Caveolin-1; though some cases showed sincere and discreet marking. The results of this study demonstrated that the histochemical methods performed are effective for semi-quantitative assessment of angiogenesis. The immunohistochemical comparison of Caveolin-1, CD31, and CD34 as markers of angiogenesis in rabbits showed that both antibodies could immunostain the newly formed vessels, but the Caveolin-1 showed better immunostaining in small and medium-sized vessels, as well as a minor presence in the background. Although not specific markers for angiogenesis, they can be used as immunohistochemical markers of vascular endothelium in rabbits.INDEX TERMS: Angiogenesis, skin grafts, immunohistochemistry, histochemistry, rabbit

RESUMO.- [**Histoquímica e imunohistoquíca na avaliação da angiogênese em coelhos submetidos ao emprego de enxertos cutâneos associado com plasma rico em plaquetas.**] Colorações histoquímicas consistem de um conjunto de reações químicas específicas das estruturas ou substâncias endógenas do tecido. Logo a Imunohistoquímica permite observar proteínas presentes nos tecidos relacionadas com fatores

[4] Resultados submetidos e aceito na Pesquisa Veterinária Brasileira. Normas publicação (Anexo III).

determinantes do comportamento biológico e patológico. A padronização dos métodos que avaliam a angiogênese decorrente de procedimentos que utilizam substâncias estimulantes a formação de novos vasos são importantes, a fim de facilitar a execução das pesquisas, bem como auxiliar na interpretação dos dados, visto que em coelhos alguns anticorpos marcadores de angiogênese na pele ainda não são padronizadas em virtude das reações cruzadas que podem ocorrer devido aos anticorpos serem confeccionados a partir de tais animais. Objetivou-se analisar os métodos histoquímicos por meio das colorações e imunohistoquímicas com marcadores de angiogênese em coelhos (*Oryctolagus cuniculus*) submetidos ao emprego de enxertos cutâneos associado com estimulador de angiogênese plasma rico em plaquetas, a fim de avaliar qual método seria melhor para visualização dos vasos, bem como avaliar qual anticorpo promoveria melhor imunomarcação, buscando-se assim encontrar a diferenças entre os métodos e padronizar a metodologia a ser aplicada em experimentos que utilizem coelhos. Utilizou-se 16 coelhos, separados em dois grupos com oito animais, compreendendo os grupos Gprp (plasma rico em plaquetas) e Gc (controle, solução fisiológica 0,9%). Em todos os animais foi realizada a mesma técnica de cirurgia reconstrutiva de enxertia do tipo malha, os grupos diferiram apenas a aplicação do plasma rico em plaquetas antes da síntese da ferida cirúrgica. As amostras para avaliação da angiogênese foram coletadas após 15 dias do procedimento cirúrgico. Utilizou-se no estudo histoquímico as colorações Hematoxilina & Eosina e Tricrômico de Masson para avaliação da proliferação vascular, e os anticorpos CD31 e CD34 e Caveolina – 1 para avaliação imunohistoquímica. A comparação entre os grupos (Gprp e Gc) em relação à variável categórica (intensidade de proliferação vascular) foi utilizado o teste de Kruskal-Wallis, com valores de p iguais ou inferiores a 0,05 foram considerados significativos. Os dados imuno-histoquímico foram submetidos à análise de variância para um delineamento inteiramente ao acaso, com 2 grupos e 5 repetições (médias) e nível de significância de 5%. Nas comparações múltiplas das médias dos grupos, utilizou-se o teste de Tukey (α = 0,05). A intensidade de proliferação vascular avaliada pelo método histoquímico HE e Tricômico de Masson encontrou-se que tal variável foi significativa no Gprp, quando comparado com o Gc. Avaliando os métodos utilizados não houve diferença significativa. A contagem microvascular (MVC) realizada com os diferentes marcadores (Caveolina-1, CD31 e CD34) foi significativa no Gprp. Correlacionando a contagem microvascular dos três marcadores utilizados não houve diferença significativa, no entanto observou-se marcação mais intensa dos vasos utilizando o anticorpo Caveolina-1, sendo intensa a marcação dos capilares, vasos de pequeno calibre, bem como em vasos maiores. Nas avaliações de CD31 e CD34 observou que houve imunomarcação dos vasos, porém não foi intensa como a Caveolina -1, alguns casos apresentaram fundo, bem como marcação discreta. Os resultados encontrados neste estudo evidenciaram os métodos histoquímicos são eficazes para avaliação semiquantitativa da angiogênese. A comparação imunohistoquímicas da Caveolina-1, CD31 e CD34 como marcadores de angiogênese em coelhos evidenciaram que ambos os anticorpos são capazes de imunomarcar os vasos neoformados, porém a Caveolina – 1 apresentou melhor imunomarcação de vasos de pequeno e médio calibre, bem como menor presença de fundo, embora não seja um marcador específico para angiogênese pode ser utilizada como marcador imunohistoquímico de endotélio vascular em coelhos.
TERMOS DE INDEXAÇÃO: Angiogênese, enxertos cutâneos, imunohistoquímica, histoquímica, coelho

INTRODUCTION

According to Pazzini et al. (2016), the use of gel with platelet-rich plasma in the subcutaneous tissue of the wound recipient bed provides excellent results when compared with saline, indicating that the intense vascular proliferation is related to the use of PRP, suggesting the ability of this compound to promote angiogenesis at the application site Skin grafts are thoroughly studied to be presently effective in correcting wounds on members;however, this method is seldom used due to the time it takes for the formation of granulation tissue (Pazzini et al. 2015), by a segment of the epidermis and dermis being completely removed from the donor region and transferred to the receptor site without the presence of vascular pedicle (Hedlund 2008) These cases are more prone to complications, such as necrosis after surgery.

However, problems encountered related to neovascularization in surgical procedures are targets of studies in various medical areas, and the platelet-rich plasma (PRP) has led to many studies reducind complications caused by the lack of angiogenesis (Vendramin et al. 2006).

Thus, the resources used to assess and quantify the angiogenesis are by histochemical and immunohistochemical methods, which are also employed in situations as prognostic markers as well as for research purposes (Weidner et al. 1991).

Histochemical stains consist of a set of specific chemical reactions of endogenous substances or structures of the tissue. Through this, viewing microorganisms, carbohydrates, connective tissue, amyloid materials and lipids as well as pigments is made possible.

In case, Immunohistochemistry allows for the observation ofproteins in related tissues with determinants of biological and pathological behavior. Through specific reactions between antigen and antibody, the presence of fluorescence or color in the microscopic analysis (Bancroft et al. 2012) can also be noted.

Thus, to evaluate tissue angiogenesis it is possible to use stains such as HE (Hematoxylin & Eosin) and Masson's Trichrome, but they are not specific stains for vessel identification. There are also immunohistochemical markers of vascular endothelium that are specific for angiogenesis evaluation, being the most used for this purpose Factor VIII, CD31, CD34, Vegf and CD105 (Bancroft et al., 2012).

That said, in the evaluation of angiogenesis in tissues, the primary dyes used are HE (hematoxylin & eosin) and Masson's trichromic. The immunohistochemical markers most commonly used vascular endothelium for this purpose such as factor VIII, CD 31, CD34, VEGF and CD 105 (Bancroft et al. 2012), but other endothelial markers for quantification of vessels, such as Caveolin-1 have been used. Nevertheless, an antibody used to identify the cytoplasm, membrane and endothelium presents successful reports of its use for assessing angiogenesis. Serafim (2016) indicates its use and success as an angiogenesis marker in skin fragments of rabbits undergoing reconstructive surgery.

However, there still is not a particular standard method for assessing angiogenesis, especially in laboratory animals, which are used as an experimental model in veterinary medicine as well as in human medicine. Thus, research such as this is necessary to evaluate methods of identifying the formation of new vessels resulting from procedures using stimulants angiogenesis to facilitate the implementation of the investigation, as well as aid in the interpretation of the data.

The purpose of this study was to analyze the immunohistochemical methods through dyes and immunohistochemical markers of angiogenesis in rabbits (Oryctolagus cuniculus) having undergone skin grafts associated with platelet-rich plasma, an angiogenesis stimulator. In order to evaluate which method would be better to visualize the vessels, as well as to evaluate which antibody would promote better immunostaining, in order to find the differences between the methods and to standardize the methodology to be applied in experiments using rabbits

MATERIAL AND METHODS

Ethics statement. This study was approved by the Ethics Committee on Animal Use (CEUA) of the Universidade Estadual Paulista (UNESP), Jaboticabal Campus (Protocol número: 11767/14).

Patient selection. Surgical procedures of this study were performed in the Veterinary Hospital "Governador Report Natel" of the Faculty of Agricultural and Veterinary Sciences (FCAV), Universidade Estadual Paulista (UNESP), Jaboticabal Campus. The slides destined to histological analysis were made in Veterinary Pathology Laboratory of the University of Porto, Portugal.

The experimental model used to perform the reconstructive surgery was the rabbit (Oryctolagus cuniculus). 16 rabbits White New Zealand were used, with about 60 days of age, females and an average weight of 3 kg from producer specialized in the creation of the species. The rabbits were kept at the biotery Postgraduate Course in Veterinary Surgery as recommended by the National Council for Animal Experimentation Control (CONCEA).

The animals were separated into two groups of eight animals : the *GPRP (rich plasma gel platelets)* group and *Gc (saline solution, 9%)* group..

Overall, the same technique of reconstructive surgery grafting mesh type was performed on the animals. The groups differed only in the application of platelet-rich plasma before the surgical wound synthesis.

Specimens for evaluation of angiogenesis were collected 15 days after the surgical procedure. The animals were euthanized with propofol at a dose of 10mg/kg, administered intravenously to deepen the anesthesia, and the infusion of potassium chloride was undertaken immediately according to the ethical principles of animal testing recommended by the Council National Animal Experimentation Control (CONCEA).

Then, the wounds were excised with a margin of 1 cm intact skin around the 16 cm² lesion. . The fascia was at the depth limit. Each fragment was individually identified as fixed on the paper card and placed in a 10% formalin solution[5].After 48 hours, the solution was replaced by 70% alcohol[6]. Then, the material was referred

[5] Formol a 10% tamponado- Indalabor- Dores do Indaiá - Minas Gerais - Brasil.

to the Veterinary Pathology Laboratory at the University Porto, Portugal, for making the slides for microscopic evaluation.

The samples were processed in a conventional histological processing routine, embedded in paraffin blocks, and done with a realization of histological sections. These were cut into microtome[7] with a thickness of 2µm.

Hematoxylin & Eosin were used to evaluate the vascular proliferation in the Histocheminal study. For the immunohistochemical study, a panel of antibodies specific for several antigens was applied (Table 1). The glass slides was previously cleaned and degreased, and prepared with prepared with organosilane-based adhesive (3-aminopropyl triethoxysilane, C.O. Sigma Chemical, USA). Novolink^{tm} Polymer Detection Systems was used according to the manufacturer's instructions.

Maker	Clone	Supplier	Dilution	Antigenic recovery	Incubation period	Detection system	Positive control
CD31 M0823	Monoclonal JC170A	Dako	1:50	Drying oven, Pepsina Porcine Gastric Mucosa – Sigma Life Science, United Kingdom	45 minutes	Novolink^{tm} Polymer Detection Systems	Rabbit normal skin
CD34 550390	Monoclonal ,581	BD Pharmingen	1:10	Maria Bath, Novocastra^{tm} Epitope Retrieval Solutions	45 minutes	Novolink^{tm} Polymer Detection Systems	Rabbit normal skin
Caveolina-1 61040	Policlonal, anti-Caveolina	BD Pharmingen	1:500	-	45 minutes	Novolink^{tm} Polymer Detection Systems	Rabbit normal skin

Table 1. Antibodies used for immunohistochemistry cutaneous tissues of rabbits conducted in Veterinary Pathology Laboratory of the University of Porto, Portugal, in 2016.

Methods of data interpretation. The analysis of histological sections was performed by the same pathologist without prior knowledge of the identification of the groups (*FG*). Histological evaluation of tissue was examined under an optical microscope[8] at 400x magnification. The photomicrographs were held on the NIS program - Nikon Imaging Software Elements version 30.4 NIS program - Nikon Imaging Software Elements version 4.30.

The data obtained using Hematoxylin & Eosin, as well as using Masson's trichrome were determined by the semiquantitative and quantitative method. The semiquantitative technique of vascular proliferation was determined according to the intensity of the vessels were found. The findings were translated into quantitative variables by index assignment for histological findings, as recommended by Garros et al. (2006) and recorded on individual records for each animal.

The angiogenic indexes for Hematoxylin & Eosin, Masson's trichrome, Caveolina-, CD31 and CD34 were determined by microvessel counting technique (MVC) as done under Maeda et al. (1995). The areas were analyzed with the largest number of vessels in the depth of the lesion. Any endothelial cell or cell groupstained positively separate from adjacent microvessel, healthy cells, and other connective tissue elements, were regarded as a unitary vessel, and also, the vessels containing lumen. The vessels containing lumen were considered the same way. Microvessel counting was carried out in five fields, previously selected at a high vascular density, with the microscope set to a magnification of 400x. The microvessel count (MVC) was determined twice by a single evaluator at two different times and was expressed as a mean number of vessels in each case studied.

Statistical analysis. Comparison between groups (Gprp and Gc) from the categorical variable (vascular proliferation intensity) was used the Kruskal-Wallis test with p values equal to or less than 0.05 ($p < 0.05$) were considered significant. For the analysis was used Npar1way procedure computer program SAS (SAS 9.1, SAS Institute, Cary. NC, USA), was used for the anaylsis as well as the GraphPad Prism program, Version 4.00.

The immunohistochemical data were submitted to analysis of variance for a completely randomized design, with two groups with five repetitions (medium) at a 5% significance level. Multiple comparisons of group called for our using the Tukey test ($\alpha = 0.05$). For this analysis, we used the General Linear Models Procedure (GLM) of the SAS computer software (SAS 9.1, SAS Institute, Cary. NC, USA).

[6] Alcool 70%- Tupi- Ibaté-São Paulo, Brasil.
[7] Microtome RM2036, Leica Biosystems- Carnaxibe- Portugal.
[8] Microscope Nikon eclipse – E200

RESULTS AND DISCUSSIONS

The proliferation of vascular were determined by the semiquantitative and quantitative method.by usingHE and Masson's trichrome has been found to be a significant variable in group *GPRP* (*p = 0.01*) (Fig. 1A) when compared with the control group (Fig. 1B). The evaluation of the methods used concluded that there was no significant difference (p> 0.05).

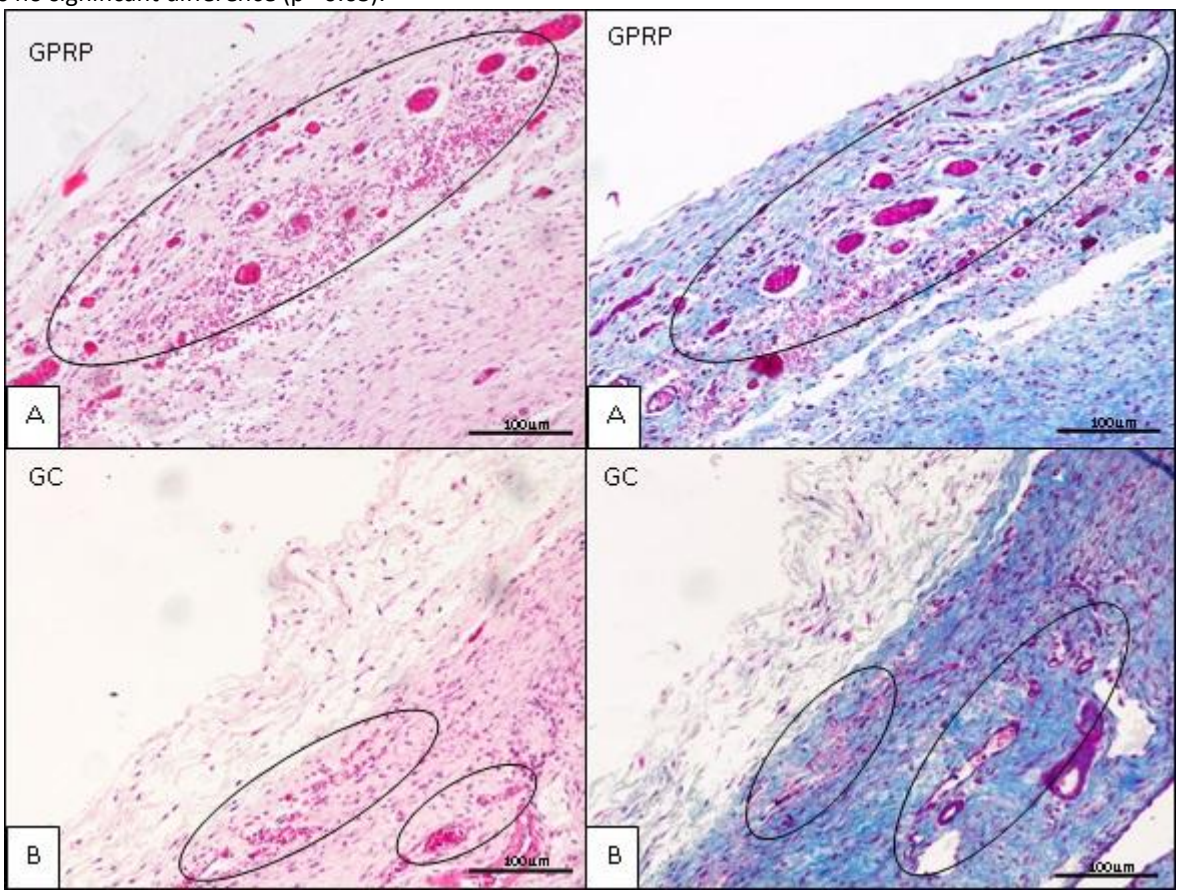

Fig.1. Histologic aspect of vascular proliferation intensity in rabbits (Oryctolagus cuniculus). Photomicrograph perspective of animal dermis submitted to the reconstructive surgery procedure at the Veterinary Hospital of the Faculty of Agricultural and Veterinary Sciences (FCAV) of Unesp, Jaboticabal Campus, 2015. (**A**) Accentuated presence of neovascularization in circumscribed area in GPRP. (**B**) Discreet presence of neovascularization in circumscribed area in Gc. 100X. HE and Trichromatic of Massom respectively.

Low cost and ability to demonstrate various structures are assigned to features in HE staining, which is frequently used in routine laboratories (Bancroft et al. 2012). Masson's trichrome is also used, but to a lesser extent because of its longer preparation time and how it requires different reagents compared to HE; its purpose is to highlight the types of surrounding tissue and to make it possible to distinguish blood vessels from other structures (Bancroft et al. 2012).

The characteristics of the HE and Masson's trichrome were observed during microscopic analysis in this study as described in the literature (Bancroft et al. 2012). One can distinguish the pré-blood vessels apparently formed using Masson's Trichrome, as is evidenced from other structures whenfacilitating the analysis; however, HE has also been observed in the same structures, only requiring further attention during the review because the vessels are not evidencing much compared with Masson's Trichrome.

For semiquantitative evaluation of the vessels, the HE and Masson trichrome staining were chosen to be used because of there being described few methods for assessing angiogenesis in the skin of rabbits. HE staining alone is commonly used for this purpose.Thus, the immunohistochemical methods and analyses performed in this study are in agreement with Reis (2015), and Serafim (2016), who used such dyes in a semiquantitative evaluation of blood vessels in rabbits fragments undergoing reconstructive surgery since they obtained good results.. However, in this study, the quantitative technique for vessel counting using HE and masson trichrome was also performed, in order to evaluate the difference between the methods (*p = 0,05*).

Although there was no significant difference between the two methods of analysis, it is recommended to use the quantitative technique because of its accuracy.

Microvessel count (MVC) was performed with different markers (Caveolin-1, CD31, and CD34) and was significant at GPRP (*p = 0.01*) (Fig. 2A) compared with the control group (Fig. 2B), averaging vessels 56.5 and 20.9 respectively appearing in groups. When correlating microvessel count of the three markers there was no significant difference (*p> 0.05*). However, there was more intense staining of vessels. When using Caveolin-1 Antibody the marking of the capillaries, small vessels were intense, as well as inlarger vessels. When assessing the CD31 and CD34, marking of vessels were observed, but was not as intense as with Caveolin-1. Some cases showed background and discreet marking. The results of this study are similar to Serafim (2016), which reports success in using Caveolin - 1 as a marker of angiogenesis in the skin fragements of rabbits undergoing reconstructive surgery.

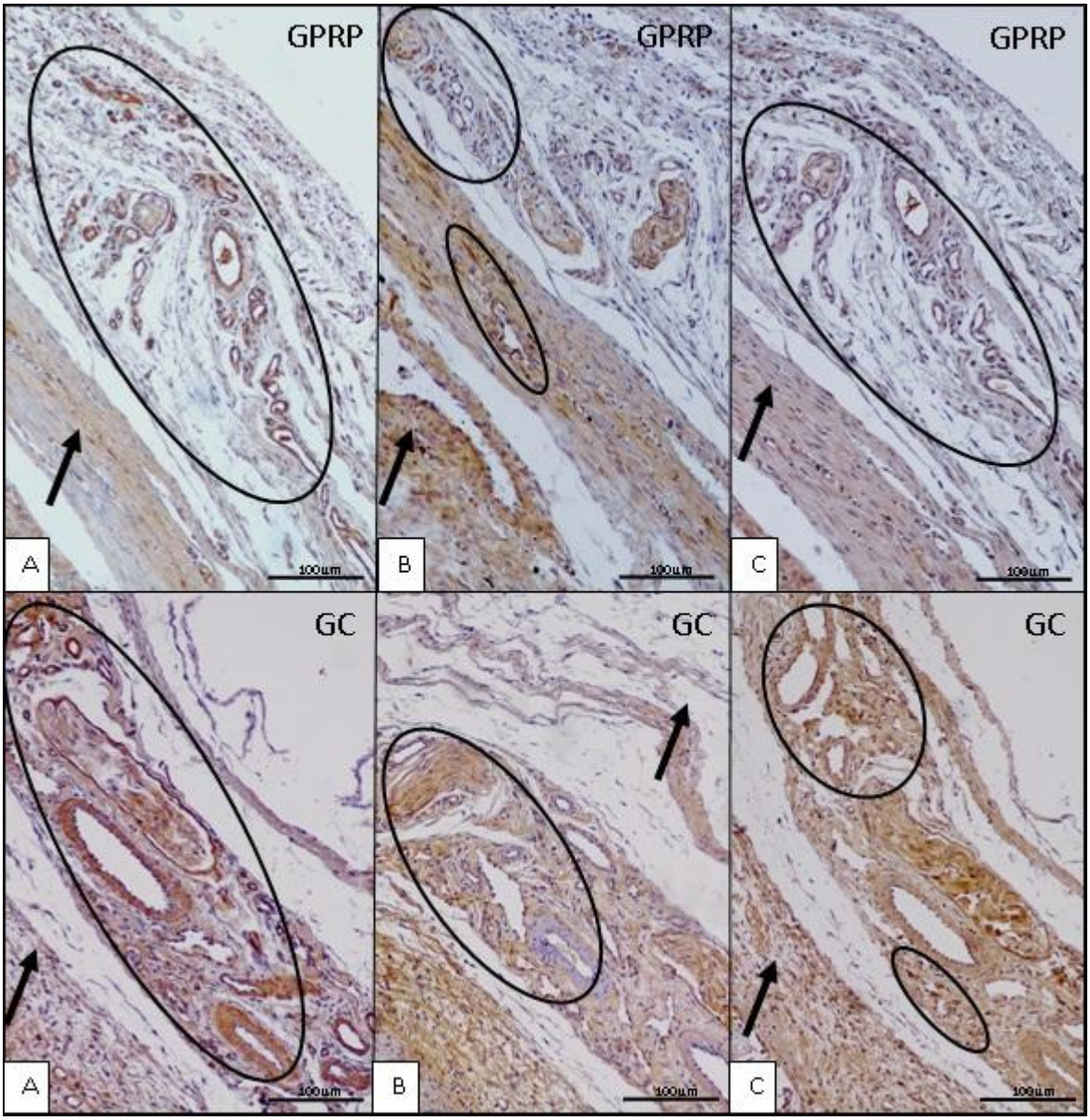

Fig.2. Histologic aspect of microvessel count (MVC) in rabbits (Oryctolagus cuniculus). Photomicrography optical dermal animals submitted to the reconstructive surgery procedure at the Veterinary Hospital of the Faculty of Agricultural and Veterinary Sciences (FCAV) of Unesp, Jaboticabal Campus, 2015. (**A**) Presence accentuated neovascularization in circumscribed area in GPRP, noting the presence of background (arrow). (**B**) Discreet presence of neovascularization in circumscribed area in Gc, noting the presence of background (arrow). (**C**) Discreet presence of neovascularization in circumscribed area in Gc, noting the presence of background (arrow). 100X. Marker Caveolin - 1, CD31, CD34, respectively. Polymer Detection Systems.

According to Abbas et al. (2013), Caveolin - 1 is an antibody used for identifying cytoplasm membrane and endothelium,; it's not specific for angiogenesis. The results of this test were contrary to that as described in the literature (Abbas et al. 2013.) because of Caveolin - 1 showingintense immunolabeling of neovascularization, proving it to be an excellent marker of angiogenesis in the skin of rabbits.

Besides other specific markers being used to evaluate the angiogenic index as VEGF, CD 31, CD 34, CD105 and Factor VIII (Bancroft et al., 2012), in rabbits there is a restriction of some of these markers due to polyclonal antibodies being obtained from lab animals, especially rabbits and mice (Hay 2000, Ball et al. 1990).

The specific markers of vascular endothelial (VEGF, CD 31, CD 34 and Factor VIII) obtained from rabbits are more susceptible to submit changes, such as cross reactions and false negatives, which can compromise the result. Changes often result in intense staining of various structures, intense presence of background, or no marking (Bancroft et al. 2012). The results of this study are in agreement with the literature, since when using specific markers for angiogenesis (Bancroft et al. 2012) CD34 and CD31 the presence of background in some samples was observed, and in individual cases occurred lighter markup of the vessel. Although it has not presented significant difference between the assessment of markers, the microvascular count of CD 31 and CD 34 required greater attention in order to avoid failure due to the fund's presence and the discrete markings. Although Caveolin-1 is not highly specific for vascular endothelium, the labeling in endothelial rabbit tissue was satisfactory when compared with other antibodies employed in this work, making it suitable for microvessel count in rabbits. These results are consistent with Serafim (2016).

CONCLUSIONS

The results of this study demonstrated the histochemistry methods performed with Hematoxylin & Eosin as well as with Masson's Trichrome staining being useful for semi-quantitative assessment of angiogenesis, although there was not specific demand greater attention from the pathologist at the time of the analysis in order to avoid failures in counting; however we recommend using Masson's trichrome for histochemical evaluation of angiogenesis as it shows the vessels.

The immunohistochemical comparison of Caveolin-1, CD31, and CD34 as markers of angiogenesis in rabbits showed that both antibodies could immunolabel newly formed vessels, but the Caveolin - 1 showed better immunolabeling of small and medium sized vessels and lower presence of background, being considered as immunohistochemical marker of vascular endothelium in rabbits.

Acknowledgements. The authors are grateful to the Coordination of Improvement of Higher Education Personnel (CAPES) for the scholarship provided to Josiane Morais Pazzini. Faculty of Agricultural and Veterinary Sciences of Jaboticabal (FCAV), Universidade Estadual Paulista (Unesp) the structure and laboratory support; Capes to the scholarship accorded in Brazil and Portugal (PDSE); the laboratory team at the University of Porto for supporting activities conducted.

.

REFERENCES

Abbas A.K., Kumar V., Fausto N. & Aster J.C. 2013. Robbins & Cotran Patologia - Bases Patológicas das Doenças. Inflamação e reparo. 9 ed. Rio de Janeiro, Elsevier, 2:29-74.

Bancroft's J.D., Layton C., Suvarna S.K. 2012. Theory and practice of histological tchniques. 7ed. Churchill Livingstone, Elsevier, 381- 423.

Reis N.P. 2015. Epitelização de enxertos cutâneos em feridas recentes de coelhos tratados com membrana amniótica canina e/ou laserterapia. Master Dissertation – Universidade Estadual Paulista Júlio de Mesquita Filho, Jaboticabal, São Paulo, 48f.

Garros I.C., Campos A.C.L., Tâmbara E.M., Tenório S.B., Torres O.J.M., Agulham M.A., Araújo A.C.F., Santis-isolan P.M.B., Oliveira R.M. & Arruda E.C.M. 2006. Extrato de *Passiflora edulis* na cicatrização de feridas cutâneas abertas em ratos: estudo morfológico e histológico. Acta Cir Bras, 21(3):55-65.

Hay F.C., Westwood O.M.R., Nelson P.N. & Hudson L. 2002. Practical immunology. Malden, MA, Blackwell Science.

Hedlund C.S. 2008. Cirurgia de pequenos animais. 3 ed. São Paulo, Elsevier, 1390.

Maeda k., Chung Y.S., Takatsuka S., Ogawa Y., Onoda N., Sawada T., Kato Y., Nitta A., Arimoto Y., Kondo Y. et al. 1995. Tumor angiogenesis and tumour cell proliferation as prognostic indicador in gastric carcinoma. Br J Cancer, 72(2):319-323.

Pazzini J.M & Moraes P.C. 2015. Princípios e Técnicas de Cirurgias Reconstrutivas da Pele de Cães e Gatos (Atlas Colorido). 1ed. Medvep, Curitiba, 95-102.

Pazzini J.M., De Nardi A.B., Huppes R.R., Gering A.P., Ferreira M.G.P.A., Silveira C.B.P., Luzzi M.C & SANTOS, R. 2016. Method to obtain platelet rich plasma from rabbits (*Oryctolagus cuniculus*). Pesq Vet Bras, 36(1):39-44.
Serafim E.L. 2016. Fechamento de defeitos em padrão de figura geométrica associado ao emprego de anestesia por tumescência com lidocaína em coelhos (*Oryctolagus cuniculus*). Master Dissertation – Universidade Estadual Paulista Júlio de Mesquita Filho, Jaboticabal, São Paulo, 68f.
Vendramin F.S., Franco D., Nogueira C.M., Pereira M.S & Franco T.R. 2006. Plasma rico em plaquetas e fatores de crescimento: técnica de preparo e utilização em cirurgia plástica. Rev Col Bras Cir, .33:24-28.
Weidner N., Semple J.P., Welch W.R., Folkman J. 1991. Tumor angiogenesis and metastasis – correlation in invasive breast carcinoma. New Engl J Med, 324:1-8.

CAPÍTULO 6 – Emprego de plasma rico em plaquetas associado à esponja cirúrgica em enxertos cutâneos em coelhos (Oryctolagus cuniculus)*

Rich Plasma platelets employed with surgical sponge in skin grafts in rabbits (*Oryctolagus cuniculus*).

Josiane Morais Pazzini[9+], Eduardo Luis Serafim[10], Ricardo Ramirez Andrez Uscategui[1], Vivian Tavares de Almeida[1], Carlos Alfredo Calpaa Oliva[11], Fátima Gärtner[12], Maria de Fátima Faria de Carvalho[13], Nazilton De Paula Reis[1], Marília Gabriele Prado Albuquerque Ferreira[3], Paola Castro Moraes[14], João Ademir de Oliveira[15]Andrigo Barboza De Nardi[6]

ABSTRACT.- Pazzini J.M., Serafim E.L., Uscategui R.R.A., De Almeida V.T., Oliva C.A.C., Gartner F., Carvalho M.F.F., Reis N.P., Ferreira G.P.A., Moraes P.C., Oliveira J.A., Nardi A.B. 2016. **Rich Plasma platelets employed with surgical sponge in skin grafts in rabbits (*Oryctolagus cuniculus*).** *Revista Brasileira de Medicina Veterinária, 00(0):00-00.* Programa de Pós Graduação em Cirurgia Veterinária, Faculdade de Ciências Agrárias e Veterinárias, Universidade Estadual Paulista, Campus Jaboticabal, Via de Acesso Paulo Donatto Castellane s/n, Jaboticabal, SP 14884.900, Brazil. E-mail: josipazzini@hotmail.com

This work had the purpose of evaluate the effectiveness of PRP gel use associated with surgical sponges to improve integration of skin graft to receptor site. Was conducted a study of 16 rabbits, New Zealand white, female, 60 days old, divided into two groups with eight animals, all of which was undergoing reconstructive surgery technique for making mesh graft. The groups were constituted in Gprpme received PRP gel and Gcme who received 0.9% saline solution

---

* Resultados submetidos e aceitos NA Revista Brasileira de Medicina Veterinária (Anexo IV).

[9] Médica Veterinária, Doutoranda, Programa de Pós Graduação em Cirurgia Veterinária, Faculdade de Ciências Agrárias e Veterinárias de Jaboticabal (FCAV), Universidade Estadual Paulista (Unesp), Via de Acesso Professor Paulo Donato Castellane s/n, Jaboticabal, SP 14884-900, Brasil. Pesquisa de doutorado com apoio da Capes e do PDSE – Programa de Doutorado Sanduíche no exterior. E-mail: josipazzini@hotmail.com; ramirezuscategui@hotmail.com; vitalmeida21@hotmail.com; nazilton@hotmail.com. +Autora para correspondência: josipazzini@hotmail.com

[10] Médico Veterinário, Mestrando, Programa de Pós Graduação em Cirurgia Veterinária, Faculdade de Ciências Agrárias e Veterinárias de Jaboticabal (FCAV), Universidade Estadual Paulista (Unesp), Via de Acesso Professor Paulo Donato Castellane s/n, Jaboticabal, SP 14884-900, Brasil. E-mail: eduardoluis.serafim@gmail.com

[11] Médico (a) Veterinária (a), Doutoranda (o), Programa de Pós Graduação em Medicina Veterinária, Faculdade de Ciências Agrárias e Veterinárias de Jaboticabal (FCAV), Universidade Estadual Paulista (Unesp), Via de Acesso Professor Paulo Donato Castellane s/n, Jaboticabal, SP 14884-900, Brasil. E-mail: calpaa@yahoo.es; mary_pops1@hotmail.com

[12] Médica Veterinária, PhD, Departamento de Patologia Veterinária da Universidade do Porto/ICBAS-Instituto de Ciências Biomédicas Abel Salazar (UP-ICSBAS), Rua Jorge Viterbo Ferreira, 228, Porto, 4050-313, Portugal. E-mail: fgartner@ipatimup.pt

[13] Técnica de Anatomiapatológica, Departamento de Patologia Veterinária da Universidade do Porto/ICBAS- Instituto de Ciências Biomédicas Abel Salazar (UP-ICSBAS), Rua Jorge Viterbo Ferreira, 228, Porto, 4050-313, Portugal. E-mail: fatimafaria10@yahoo.com.br

[14] Médico Veterinário, PhD, Departamento de Clínica e Cirurgia Veterinária, Faculdade de Ciências Agrárias e Veterinárias (FCAV), Universidade Estadual Paulista (Unesp), Via de Acesso Professor Paulo Donato Castellane s/n, Jaboticabal, SP 14884-900, Brazil. E-mail: pcastromoraes@yahoo.com.br; andrigobarboza@yahoo.com.br

[15] Estatístico, PhD, Departamento de Estatística, Faculdade de Ciências Agrárias e Veterinárias (FCAV), Universidade Estadual Paulista (Unesp), Via de Acesso Professor Paulo Donato Castellane s/n, Jaboticabal, SP 14884-900, Brazil. E-mail: jaoliv@fcav.unesp.br

combining both surgical sponge as a way of curative. Blood samples Gprpme group that was done PRP, the mean platelet count after centrifugation was 1.430.375 platelets / uL. Results obtained in the PRP final sample when compared to the inicial were significantly greater. Thus, double centrifugation protocol for obtaining PRP which was performed in this trial was appropriate, because the platelet concentration after double centrifugation increased three times as compared with initial count of the blood sample, and it was possible to achieve good therapeutic results. In macroscopic evaluation of the 3rd day, exudate showed significant differences in Gprpme compared to Gcme. In evaluations of the 7th and 14th day edema, color, exudate and cosmetic appearance were not significant between groups. Qualitative histological evaluations using the staining HE and Trichromes of Massom, it was observed that intensity of polymorphonuclear cells, fibroblast proliferation, collagen deposition and epithelialization no significant difference. However, vascular proliferation was significantly higher in the Gprpme when comparison with the Gcme. Therefore, the use of platelet rich plasma in the form of gel using in mesh skin grafts are able to stimulate angiogenesis in wound, favoring integration of the graft to site receptor, without the presence of granulation tissue. And association of surgical sponge as a pressure dressing promotes healing of the graft, reducing complications such as presence of edema, and graft movement, therefore is feasible and advisable his use.

KEY WORDS. Graft, wounds, neovascularization, PRP, compressive curative.

RESUMO. Objetivou-se com este estudo avaliar a eficácia do uso do gel de PRP associado as esponjas cirúrgicas favorecerem a integração do enxerto em malha ao leito receptor. Foi realizado, um estudo com 16 coelhos, Nova Zelândia branco, fêmeas, com 60 dias de idade, separados em dois grupos, com oito animais, que foram todos submetidos à técnica de cirurgia reconstrutiva para confecção de enxerto em malha. Os grupos foram compreendidos em Gprpme receberam gel de PRP e Gcme que receberam solução fisiológica 0,9% ambos associando esponja cirúrgica como forma de curativo. As amostras de sangue do grupo Gprpme no qual se realizou o PRP, a contagem média de plaquetas após a centrifugação foi de 1.430.375 plaquetas/µL, sendo os resultados obtidos na amostra final de PRP quando comparada com a inicial foram significativamente maior. Assim, o protocolo de centrifugação dupla para obtenção do PRP que foi realizado neste ensaio foi adequado, visto que a concentração de plaquetas após centrifugação dupla aumentou três vezes quando comparado com a contagem inicial da amostra de sangue, e foi possível alcançar bons resultados terapêuticos. Nas avaliações macroscópicas do 3º dia, edema, rubor, coloração e aspecto cosmético não foram significativas entre os grupos. Porém, exsudato apresentou diferenças significativas no Gprpme quando comparado com Gcme. Nas avaliações do 7º e do 14º dia edema, coloração, exsudato e aspecto cosmético não foram significativas entre os grupos. As avaliações histológicas qualitativas utilizando as colorações HE e Tricromio de Massom observou-se que a intensidade de polimorfonucleares, proliferação fibroblástica, reepitelização e colagenização não houve diferença significativa. Entretanto, a proliferação vascular foi significativamente maior no Gprpme quando

comparado com o Gcme. Já presença de células mononucleares e Hemorragiaforam significativamente maior no Gcme quando comparado com Gprpme. Portanto, a utilização do plasma rico em plaquetas na forma de gel em enxertos cutâneos em malha é capaz de estimular a angiogênese na ferida favorecendo a integração do enxerto ao leito receptor, sem presença prévia de tecido de granulação. E associação da esponja cirúrgica como curativo compressivo favorece a cicatrização do enxerto por reduzir complicações como seu deslocamento no leito receptor e presença de edema, sendo viável e aconselhável seu emprego.

PALAVRAS-CHAVE. Enxerto, feridas, angiogênese, PRP, curativo compressivo.

INTRODUÇÃO

A cirurgia reconstrutiva consiste de uma especialidade das cirurgias de pequenos animais, a qual vem sendo empregada com freqüência a fim de reparar defeitos com grande perda de continuidade do tegumento, ou falta de elasticidade cutânea, que comprometam a cicatrização (Castro et al., 2015; Pavletic 2010). As técnicas cirúrgicas reconstrutivas podem ser divididas em duas modalidades: retalhos e enxertos (Fossum 2007). Os retalhos consistem de uma porção de tecido que é removido parcialmente do seu local de origem e transferido para outro (leito receptor) onde irá cobrir o defeito, e é acompanhado pela vascularização local (Hedlund 2005). O enxerto cutâneo é uma das modalidades da cirurgia reconstrutiva que é principalmente empregado em defeitos em extremidades de membros, bem como locais com lesões menores, porém pouco utilizado (Pazzini et al. 2015). Esse modelo consiste de segmento da epiderme e da derme que é completamente removido da região doadora e transferido para o local receptor, sem a presença de pedículo vascular (Hedlund 2008).

Os enxertos são classificados conforme sua espessura, podendo ser espessura completa ou parcial. Os de espessura completa consistem da epiderme e derme completa, e os de espessura parcial consistem de epiderme e camadas variáveis da derme (Pazzini et al. 2015). Ademais os enxertos podem ser do tipo camada, malha ou semeadura, e são obtidos de tecido da parede torácica lateral, membros, e áreas que contenham pele abundante (Fossum 2007).

Em virtude dos enxertos não apresentarem pedículo vascular, é recomendado curativo compressivo, a fim de otimizar o contato do enxerto com o leito da ferida, e permitir adequada angiogênese. Além do mais, possibilitam menor ocorrência de hematoma e seroma, eventos que habitualmente conduzem à perda de vitalidade e, por consequência, à falência do enxerto (Leffel 1994).

Os curativos compressivos mais utilizados são Tie over, os quais consistem em suturar um aglomerado de gazes sobre o enxerto (Pavletic 2010). Todavia, outros materiais podem ser usados como curativos compressivos como gaze, algodão, discos plásticos, e moldes de cera (Vasconez 1994). No entanto, a idéia do uso de esponja ou espuma surgiu em 1929, (Blair e Brown), segundo os autores dessa descoberta, a melhor pressão sobre os enxertos era proveniente do uso da esponja. Ademais, as principais vantagens do seu emprego são custo reduzido, oferecendo adequada proteção do enxerto, técnica de fácil realização, moldável em diferentes

formas, apresentam pressão uniformemente distribuída, são de retirada fácil e proporcionam redução do desconforto pós-operatório do paciente.

As cirurgias reconstrutivas apresentam muitos benefícios, permitem que o paciente retorne a sua rotina normal com maior rapidez, e com resultados estéticos satisfatórios. No entanto, alguns casos, há complicações, como inadequada vascularização, movimentação do enxerto e infecção, sendo fatores que predispõe a ocorrência de necrose (Amsellem 2011).

Sendo assim, os problemas encontrados relacionados com neovascularização em procedimentos cirúrgicos, são alvo de estudos em diversas áreas médicas, principalmente em ortopedia e odontologia. Para tanto, o plasma rico em plaquetas (PRP) é alvo de vários estudos associados às complicações nessas áreas. Esse produto é resultado do processamento do sangue do paciente em centrífugas que promovem a separação dos seus constituintes e permitem extração do plasma com concentração maior de plaquetas, e é capaz de potencializar o processo de cicatrização tecidual, por meio da liberação de mediadores biológicos e fatores de crescimento, no local da aplicação. Acredita-se que eles sejam capazes de estimular vários processos envolvidos na recuperação tecidual entre eles a mitose, diferenciação celular, quimiotaxia e angiogênese (Floryan et al. 2004, Silva et al., 2011).

Considerando os benefícios do plasma rico em plaquetas e a importância da cirurgia reconstrutiva para corrigir defeitos sem complicações, este trabalho teve o intuito de avaliar a eficácia do emprego do gel de plasma rico em plaquetas (PRP) em enxertos cutâneos de espessura completa do tipo malha em coelhos (Oryctolagus cuniculus), associando no pós-operatório esponjas cirúrgicas como curativo compressivo, a fim de avaliar a possibilidade do PRP junto as esponjas cirúrgicas favorecerem a integração do enxerto ao leito receptor sem a presença prévia de tecido de granulação, bem como avaliar a angiogênese local onde o procedimento foi realizado.

MATERIAL E MÉTODOS

Os procedimentos cirúrgicos deste estudo foram realizados no Hospital Veterinário Governador Laudo Natel, da Faculdade de Ciências Agrárias e Veterinárias (FCAV), Universidade Estadual Paulista (UNESP), Câmpus de Jaboticabal. As lâminas destinadas à análise histológicas foram confeccionadas no Laboratório de Patologia Veterinária da Universidade do Porto, Portugal. O presente trabalho foi aprovado pelo Comitê de Ética no Uso de animais (CEUA) da Universidade Estadual Paulista (UNESP), Câmpus de Jaboticabal[16].

O modelo experimental utilizado para realização das cirurgias reconstrutivas foi o coelho (*Oryctolagus cuniculus)*. Foram utilizados 16 coelhos da raça Nova Zelândia Branco, com a aproximadamente 170 dias de idade, fêmeas e peso médio de 3 Kg, provenientes de produtor especializado na criação da espécie. Os coelhos foram mantidos no biotério do Curso de Pós-graduação em Cirurgia Veterinária, em gaiolas individuais com dimensões de 80 cm x 50 cm x 35 cm, obedecendo-se os princípios éticos em experimentação animal preconizados pelo Conselho Nacional de Controle

[16] Protocolo número:11767/14

de Experimentação Animal (CONCEA). Foi fornecido durante todo o experimento aos animais ração comercial[17] própria para a espécie e água à vontade.

Os animais foram separados em dois grupos de 8 animais cada, compreendendo os grupos Gprpme (gel de plasma rico em plaquetas associado com esponja cirúrgica como forma de curativo no enxerto de malha) e Gcme (solução fisiológica 0,9%[4]associada com esponjas cirúrgicas no enxerto de malha). Em todos os animais foi realizada a mesma técnica de cirurgia reconstrutiva de enxertia do tipo malha, diferindo apenas a aplicação do plasma rico em plaquetas.

Não foi necessário submeter os animais ao jejum alimentar e hídrico. O protocolo anestésico ao qual os animais foram submetidos consistiu de midazolam[18], na dose de 0,5 mg/kg pela via intramuscular (IM) e cloridrato de tramadol[19], na dose de 5 mg/kg pela mesma via. Após sedação, foram coletadas amostras de sangue dos 16 coelhos submetidos ao procedimento cirúrgico. As amostras de sangue do Gcme não foram submetidas ao preparo de PRP, apenas coletadas para não haver diferenças entres os grupos quanto ao volume de sangue corpóreo. Na sequência, realizou-se tricotomia da região cervical para acesso das veias jugulares, e procedeu-se antissepsia com clorexidine[20] e solução de álcool a 70%[21]. Os animais foram posicionados em decúbito esternal com o pescoço em extensão dorsal máxima para permitir a visualização adequada das veias jugulares. Procedeu-se venopunção e coleta de 8mL de sangue, acondicionada em três tubos estéreis, dois com capacidade de 3,6mL contendo citrato de sódio[22] (anticoagulante) destinados à preparação do PRP, e um terceiro tubo com capacidade de 1mL contendo EDTA[23] (anticoagulante) foi preenchido com 0,8ml de sangue o qual foi destinado à contagem de plaquetas. Após determinar em máquina automática[24] a contagem plaquetária dentro dos parâmetros fisiológicos para a espécie, deu-se início a preparação do PRP por outro integrante da equipe, enquanto o procedimento cirúrgico foi realizado.

O frasco com citrato de sódio foi empregado na produção do plasma rico em plaquetas (PRP) pelo protocolo de dupla centrifugação em centrífuga laboratorial comum[25] conforme descrito por Camargo et al. (2002).

Ao término do processo de enriquecimento do plasma, a contagem da concentração de plaquetas foi realizada em máquina automática[9], a partir de uma alíquota de 80µL da amostra do PRP. Após contagem das plaquetas na amostra, com auxílio de seringa de 1mL, o PRP dentro do tubo estéril foi ativado por meio da adição de 0,3 mL de gluconato de cálcio[26], no momento de sua utilização terapêutica, adquirindo assim, propriedades semelhantes a um gel, estando dessa forma, pronto para ser utilizado.

Em seguida, à coleta do sangue, realizou-se ampla tricotomia da face lateral esquerda do tórax e membro torácico ipisilateral. Após o término da tricotomia

---

[17] Nature multivida coelho - Socil - Sgh Ind. e Com, Ltda – Descalvado - São Paulo - Brasil.
[18] Midazolam – Medley Indústria Farmacêutica Ltda – Campinas – São Paulo – Brasil
[19] Tramal – Medley Indústria Farmacêutica Ltda – Campinas – São Paulo – Brasil
[20] Solução de Digliconato de Clorexidina Loção Aquosa 0,2%. Rioquimica Ind. Farmacêutica, São José do Rio Preto, SP, Brasil.
[21] Álcool etílico 70%. Rioquimica Ind. Farmacêutica, São José do Rio Preto, SP, Brasil.
[22] Tubo BD vacutaneir® citrato de sódio – BD – São Paulo – São Paulo – Brasil.
[23] Tubo pediátrico BD vacutaneir® EDTA – BD – São Paulo – São Paulo – Brasil.
[24] Poch – 100iV Diff- médica comércio representações e importações LTDA – Recife – Pernambuco – Brasil.
[25] Modelo 206 I centrifuge/Fanem® - SP.
[26] Gluconato de cálcio 100mg/ml/ Hipolabor – Sabará – Minas Gerais - Brasil.

realizou-se venopunção da veia auricular dos pacientes com cateter 24[27] para fluidoterapia de manutenção com solução de ringer lactato[28], e procedeu-se indução e manutenção anestésica via máscara facial vedada, com Isofluorano[29] na dose de 3% diluído em 100% oxigênio, para produzir um plano anestésico cirúrgico.

O procedimento cirúrgico de reconstrução empregando enxerto foi realizado em um único momento, substituindo o tecido de granulação pelo plasma rico em plaquetas e pela solução fisiológica 0,9%[4].

Para a realização da ferida dermoepidérmica e demarcação do segmento de pele a ser retirado em região de carpo esquerdo, foi utilizada caneta cirúrgica[30] e régua estéril para criar uma lesão de 4 cm de comprimento por 4 cm de largura, no formato de quadrado (Figura 1A). Com o auxílio de lâmina de bisturi nº15[31] foi excisado o fragmento cutâneo de 16 cm², na porção distal do carpo, do membro torácico esquerdo, aproximadamente 3 cm abaixo do olecrano (Figura 1B), sendo semelhante à lesão decorrente de trauma ou ressecção neoplásica extensa. A confecção de fendas no enxerto (Figura 2A) foram realizadas com auxílio de bisturi[17], com aproximadamente 0,2 mm de comprimento, com 0,3mm de distância entre elas (Figura 2B).

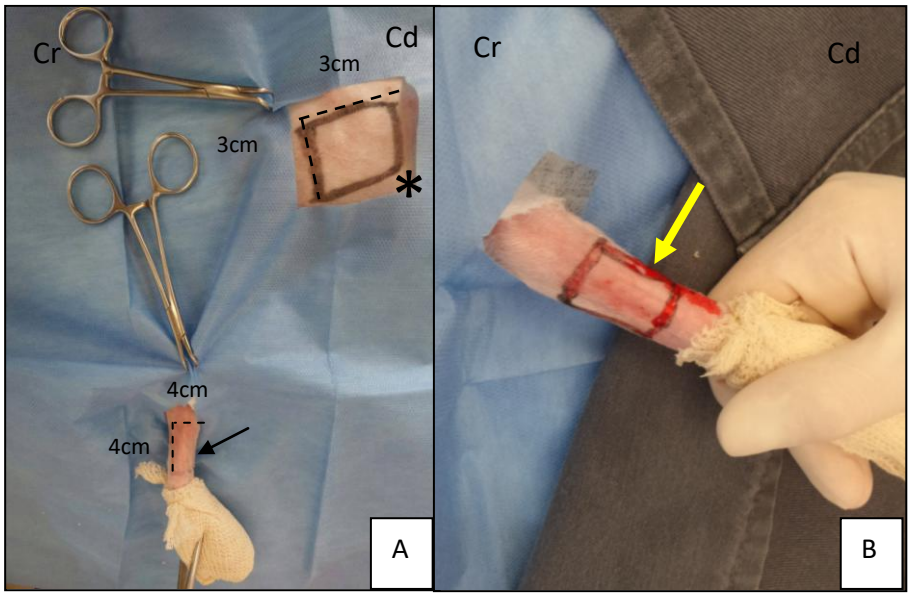

Figura 1 Imagens fotográficas da diérese do procedimento cirúrgico de reconstrução realizado no Hospital Veterinário da Faculdade de Ciências Agrárias e Veterinárias (FCAV) da Unesp, Câmpus de Jaboticabal, 2015. A) Demarcação do segmento de pele a ser retirado no tórax de 9cm², e no membro torácico com 16cm² (seta preta) confeccionado com auxílio de caneta cirúrgica e régua estéril. B) Criação da lesão com no formato de um quadrado, 3 cm abaixo da extremidade do olecrano (seta amarela). Cr. Cranial, Cd. Caudal.

[27] Cateter BD Angiocath 24 – Becton, Dickinson Indústria Cirúrgica Ltda – Juiz de Fora - Minas Gerias – Brasil.
[28] Riger lactato – JP Indústria Farmacêutica S.A – Ribeirão Preto – São Paulo – Brasil.
[29] Isoflurine - Cristália – Itapira - São Paulo Brasil
[30] Skins – T Surgical Skin Marker - Batrik Medical Manufacturing Inc – Quebec – Canadá.
[31] Lâmina de bisturi N15 - Solidor – São Paulo - São Paulo - Brasil.

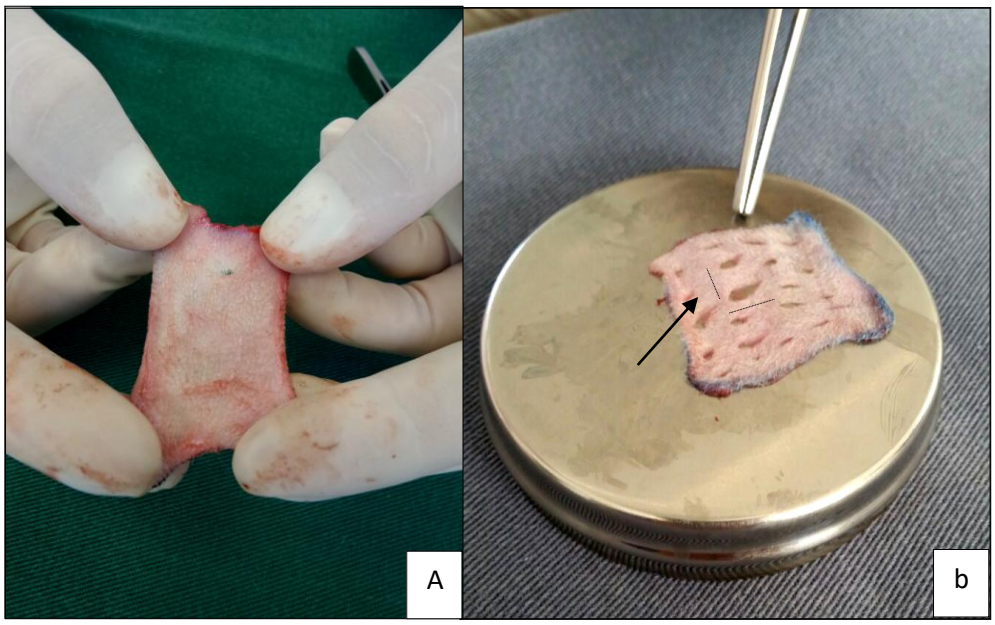

Figura 2 Imagens fotográficas da diérese do procedimento cirúrgico de reconstrução realizado no Hospital Veterinário da Faculdade de Ciências Agrárias e Veterinárias (FCAV) da Unesp, Câmpus de Jaboticabal, 2015. A) Confecção do enxerto. B) Presença das fendas (seta) no enxerto em malha realizadas com auxílio de bisturi[17], com aproximadamente 0,2mm de comprimento (tracejado azul), com 0,3mm de distância entre elas (tracejado preto).

Logo após realização da lesão do carpo, com o paciente em decúbito lateral, e membro torácico em extensão perpendicular ao tronco, confeccionou-se o enxerto cutâneo de 9cm², na região lateral esquerda do tórax, com incisão cutânea em formato de quadrado (Figura 3A), partindo 4 cm no sentido caudal à espinha da escápula, e 3 cm abaixo do processo espinhoso da coluna vertebral, com limites de profundidade determinados de acordo com as referências anatômicas descrita na literatura (Pazzini et al. 2015). Para tal, foi estimada a localização do subcutâneo imediatamente após a incisão de pele A partir deste ponto, prosseguiu-se dissecção cuidadosa do enxerto, e sua retirada do leito doador (Figura 3B), finalizando essa etapa, realizou-se a remoção de resíduos de gordura e subcutâneo do fragmento (Figura 3C), e confeccionaram-se as fendas. Ato contínuo promoveu-se hemostasia dos vasos locais do leito receptor e iniciou-se a implantação do enxerto. As suturas em padrão simples separado, utilizando náilon 4-0[32], foram primeiramente distribuídas nos vértices do quadrado entre o tecido do leito doador com o receptor (Figura 3D), sempre na direção enxerto – pele do leito receptor, a fim de evitar movimentação do enxerto no momento da sutura, e na sequência, procedeu-se a síntese da ferida cirúrgica (Figura 3E).

A ferida do leito doador no tórax foi submetida à dermorrafia em padrão de fechamento em formato de figura geométrica, com náilon 4-0[7], as suturas iniciaram nos vértices do defeito e convergiram em direção ao centro na ferida cirúrgica

[32] Nylon monofilamentar- Point Suture do Brasil IND. de fios cirúrgicos LTDA.-Fortaleza - Ceará - Brasil.

(Figura 3F), ao término apresentando a cicatriz cirúrgica dois triângulos invertidos (Figura 3G).

O gel de plasma rico em plaquetas autólogo (0,7mL de PRP) foi colocado no Gprpme antes da síntese da lesão no carpo, com auxílio do cabo de bisturi[33] e distribuído de maneira homogênea entre o subcutâneo do leito doador e o subcutâneo do leito receptor (Figura 3H), e os animais do Gcme receberam 0,7mL de solução fisiológica[2]. Após aplicação das respectivas soluções procedeu-se a síntese da ferida cirúrgica.

A confecção das esponjas cirúrgicas[34] foi realizada a partir das escovas utilizadas para antissepsia, seguindo descrito na literatura (Zanini et al. 2004). Primeiramente destacou-se a esponja da escova com auxílio de bisturi. Ato contínuo, com lâmina de bisturi, reduziu-se espessura da esponja para 1cm. Sua extensão foi projetada para exceder em torno de 0,5 cm a margem do enxerto. Assim, após implantação do enxerto e aplicação das respectivas soluções, realizou-se o emprego da esponja cirúrgica ao término da dermorrafia (Figura 3I), como curativo compressivo.

Os animais foram recolocados nas suas respectivas gaiolas para observação da recuperação anestésica até completa normalização da frequência respiratória e início da movimentação ativa, e busca por alimentos e água. Além disto, foram identificados com o dia do procedimento cirúrgico e tipo do tratamento que receberam.

Como protocolo de analgesia os animais receberam Cloridrato de Tramadol[35] por via subcutânea na dose de 4 mg/Kg, com intervalos de 12h, durante 7 dias, e receberam antibióticoterapia com Pentabiótico[36] por via subcutânea na dose de 0,06ml/Kg, com intervalo de 48h para nova dose, por 5 dias, e antiinflamatório com Meloxicam[37] durante 3 dias, sendo por via subcutâneo na dose de 0,2 mg/Kg no primeiro dia, e no segundo e terceiro dia 0,1mg/Kg, com intervalos de 24 horas.

Em todos os animais os curativos foram realizados no pós operatório imediato e trocados no 3º, 7º e 15º dias, juntamente foram realizadas as avaliações macroscópicas, até a data da eutanásia. A limpeza e troca dos curativos eram conduzidas da seguinte maneira, Limpeza da ferida com solução fisiológica (NaCl 0,9%[2]), Remoção de exsudato quando necessário; avaliação do aspecto da esponja cirúrgica[18] e do enxerto; cobertura com gaze[38]; fixação da gaze com atadura[39] e esparadrapo[40].

---

[33] Cabo de bisturi n4 – Brasmed Empresa Brasileira de Cirurgia Veterinária LTDA – Paulínia – São Paulo – Brasil.
[34] Escova seca estéril – Rioquímica Indústria Farmacêutica- São José do Rio Preto-SP.
[35] Tramal – Medley Ind. Farmacêutica LTDA – Campinas – São Paulo – Brasil.
[36] Mogipen – Jofadel Indústia Farmacêutica S/A Monte Mor – São Paulo - Brasil.
[37] Maxicam - OuroFino Agronegócios - Cravinhos - São Paulo - Brasil.
[38] Gaze hidrófila estéril – Herika – América Medical LTDA – Curvelo – Minas Gerais – Brasil.
[39] Atadura Cremer - Blumenau – Santa Catarina – Brasil.
[40] Esparadrapo – Cremer – Blumenau – Santa Catarina – Brasil.

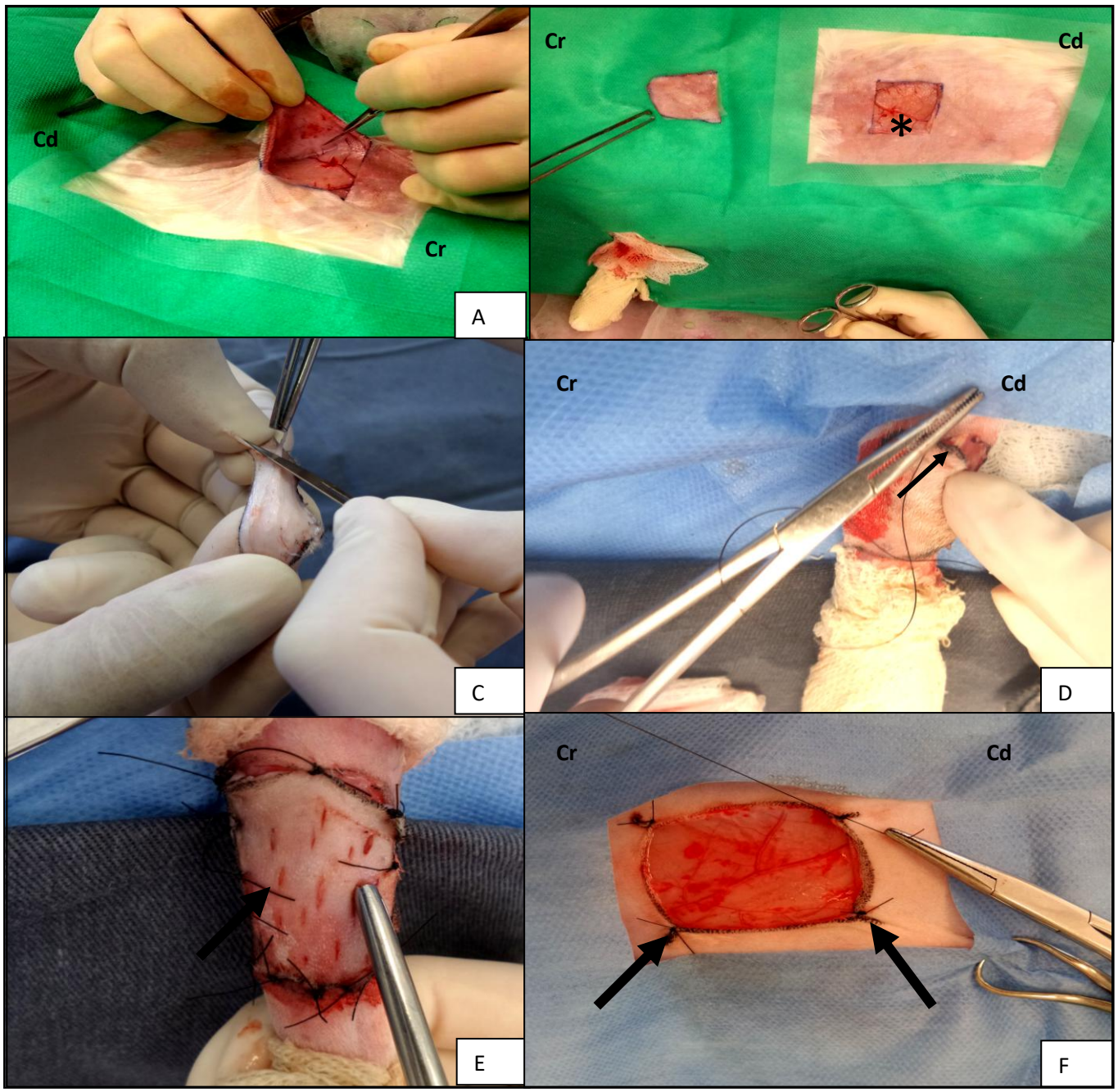

Figura 3 Imagens fotográficas da diérese e síntese do procedimento cirúrgico de reconstrução realizado no Hospital Veterinário da Faculdade de Ciências Agrárias e Veterinárias (FCAV) da Unesp, Câmpus de Jaboticabal, 2015. A) Confecção do enxerto cutâneo de 9cm², na região lateral esquerda do tórax, com incisão cutânea em formato de quadrado e divulsão cautelosa. B) Retirada do enxerto do leito doador. C) Remoção de resíduos de gordura e subcutâneo do fragmento com auxílio de bisturi[17]. D) Sutura do enxerto no leito receptor em padrão simples separado, com náilon 4-0[37], direção da sutura sendo enxerto – pele do leito receptor (seta). E) Síntese do enxerto no leito receptor. F) Fechamento em formato de figura geométrica, com náilon 4-0[7], suturas iniciam nos vértices do defeito e convergem em direção ao centro na ferida cirúrgica (setas). Cr. Cranial, Cd. Caudal.

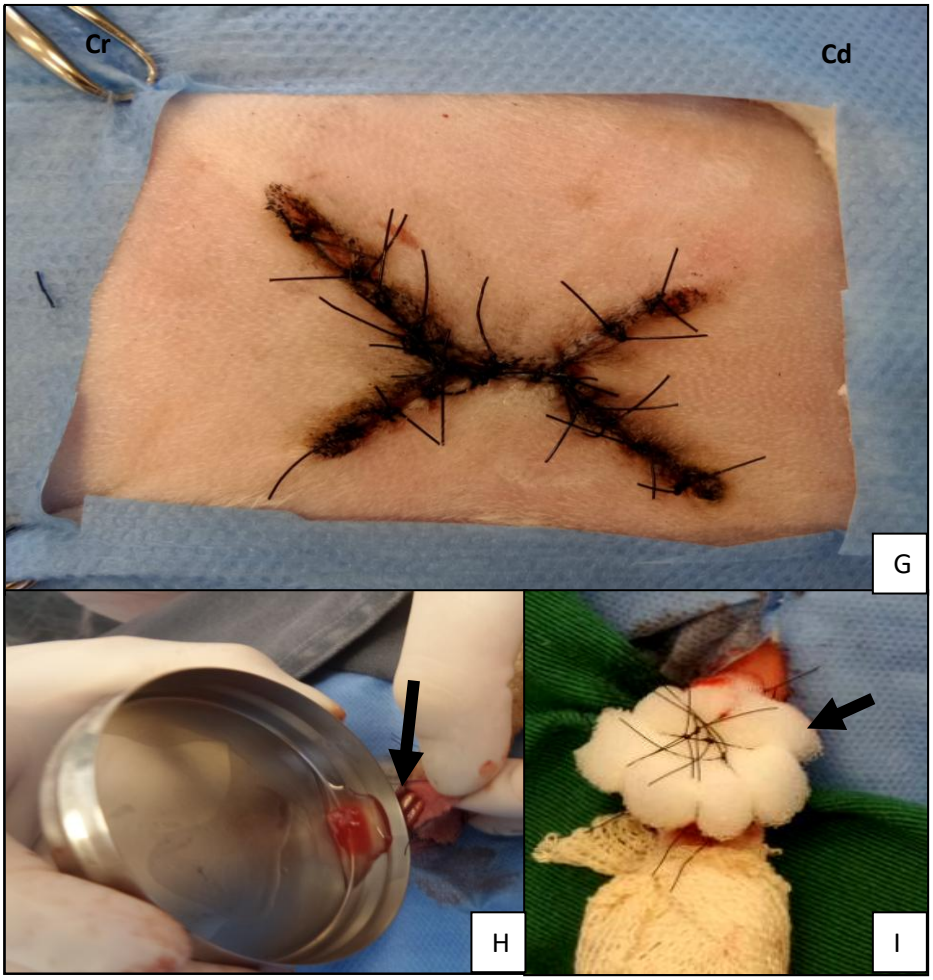

Figura 3 Continuação. Imagens fotográficas da diérese e síntese do procedimento cirúrgico de reconstrução realizado no Hospital Veterinário da Faculdade de Ciências Agrárias e Veterinárias (FCAV) da Unesp, Câmpus de Jaboticabal, 2015. G) Cicatriz cirúrgica formando dois triângulos invertidos. H) Distribuição homogênea do PRP entre o subcutâneo do leito doador e o subcutâneo do leito receptor.I) Emprego da esponja cirúrgica ao término da dermorrafia. Cr. Cranial, Cd. Caudal.

As avaliações macroscópicas da ferida consistiam em avaliar a presença ou ausência de exsudato, coloração, edema, rubor e aspecto cosmético. A presença ou não de exsudato, para avaliar a instalação de provável processo inflamatório na ferida cirúrgica, foi avaliado e posteriormente graduado em: 0 ausência de exsudato, 1 discreta presença, 2 moderada presença e 3 intensa presença. A avaliação da coloração consistia em graduá-la variando de 0 à 3, onde 0 representava pele pálida, 1 rósea, 2 avermelhada, e 3 cianótica. Para avaliação do edema utilizou-se graduação de 0 à 3, sendo 0 ausência de edema, 1 edema discreto, 2 edema moderado e 3 edema intenso. E para avaliação do aspecto cosmético utilizou-se graduação de 0 a 3, sendo 0 excelente, 1 bom, 2 regular e 3 ruim. Os dados foram anotados em ficha própria, individual para cada coelho

No 15º dia de pós-operatório, os coelhos foram eutanasiados para colheita de material da avaliação microscópica. A eutanásia foi realizada com propofol, na dose de 10mg/kg, administrado por via intravenosa, a fim de aprofundar o plano anestésico, ato contínuo realizou-se infusão de cloreto de potássio, obedecendo-se os princípios éticos em experimentação animal preconizados pelo Conselho Nacional de Controle de Experimentação Animal (CONCEA).

Em seguida, as feridas foram excisadas com margem de 1 cm de pele íntegra em torno da lesão de 16 cm^2, e o limite de profundidade foi a fáscia muscular. Cada fragmento foi identificado individualmente, fixado em cartolina e colocado em solução de formalina a 10%[41], e após 48 horas a solução foi substituída por álcool à 70%[42], em seguida, o material foi encaminhado ao para o Laboratório de Patologia Veterinária da Universidade do Porto, Portugal, para confecção das lâminas histológicas.

As amostras foram processadas conforme a rotina convencional de processamento histológico, inclusão em blocos de parafina, e realização dos cortes histológicos. Estes foram cortados em micrótomo[43], com espessura de 4 µm, na sequência, realizou-se desidratação em diluições crescentes de álcoois[44] e diafanização em xilol[45], e procedeu-se as colorações específicas.

A análise dos cortes histológicos foi realizada pelo mesmo patologista sem o conHEcimento prévio da identificação dos grupos. A avaliação histológica das lâminas foi realizada em microscópio óptico[46] no aumento de 400x. As fotomicrografias foram realizadas no programa NIS – Nikon Imaging Software Elements version 4.30. Os dados obtidos foram classificados de acordo com a intensidade em que eram encontrados e transformados em variáveis quantitativas mediante atribuição de índice para o achado histológico, conforme preconizado por Garros et al. (2006) e registrados em fichas individuais para cada animal.

Os cortes foram corados pelo método histoquímico para posterior análise em microscopia óptica. Utilizou-se Hematoxilina e Eosina, para avaliação de epiderme, derme, bem como presença de mononucleados, polimorfonucleados, hemorragia, colagenização e reepitelização; e Tricrômico de Masson para proliferação vascular.

Os dados de PRP (concentração plaquetária) foram analisados pelo teste t emparelhado com grau de significância de 5%. A comparação entre os grupos (Gprpme e Gcme) em relação às variáveis categóricas (exsudato, coloração, edema, aspecto cosmético, proliferação vascular, células mononucleares, células polimorfonucleares, proliferação de fibroblasto, colagenização, reepitelização e hemorragia) foi utilizado o teste de Kruskal-Wallis, com posterior utilização do teste de comparação múltipla de Dunn, para os casos em que houve diferença significativa entre as medianas dos grupos. Para todos os testes, valores de p iguais ou inferiores a 0,05 ($p<0,05$) foram considerados significativos. Para as análises foi utilizado o procedimento npar1way do programa computacional SAS (SAS 9.1, SAS Institute, Cary. NC, USA) e o programa GraphPad Prism, Version 4.00.

---

[41] Formol a 10% tamponado- Indalabor- Dores do Indaiá - Minas Gerais - Brasil.

[42] Alcool 70%- Tupi- Ibaté-São Paulo, Brasil.

[43] Micrótomo rotativo RM2036, Leica Biosystems- Carnaxibe- Portugal.

[44] Etanol absoluto - Merck Millipore Corporation - Darmstadt, Germany.

[45] Xilol – Quimidrol – Joinville – Santa Catarina – Brasil.

[46] Microscópio Nikon eclipse - E200.

RESULTADOS

Analisando as amostras de sangue dos coelhos do grupo Gprpme no qual se realizou o PRP, a contagem inicial de plaquetas apresentou-se dentro dos padrões fisiológicos para a espécie, variando de 290.000 a 678.000 plaquetas/µL. A partir de 7,2 mL de amostra de sangue total, atingiu-se um volume médio de PRP de 0,7mL, e a contagem média de plaquetas após a centrifugação foi de 1.430.375 plaquetas/µL.

Os resultados obtidos na amostra final de PRP quando comparada com a inicial foram significativamente maior ($p=0,001$). Assim, o protocolo de centrifugação dupla para obtenção do PRP que foi realizado neste ensaio foi adequado, visto que a concentração de plaquetas após centrifugação dupla aumentou três vezes quando comparado com a contagem inicial da amostra de sangue, e foi possível alcançar bons resultados terapêuticos.

Nas avaliações macroscópicas do 3º dia, edema, coloração e aspecto cosmético não foram significativas entre os grupos ($p>0,05$). Porém, exsudato apresentou diferenças significativas. A presença de exsudato no Gprpme (Figura 4A) foi significativamente maior quando comparado com Gcme ($p=0,01$) (Figura 4B).

Nas avaliações do 7º e do 14º dia edema, coloração, exsudato e aspecto cosmético não foram significativas entre os grupos ($p>0,05$).

As avaliações histológicas qualitativas utilizando as colorações HE e Tricômio de Massom, observou-se que a intensidade de polimorfonucleares, proliferação fibroblástica, reepitelização e colagenização não houve diferença significativa ($p>0,05$). Entretanto, a proliferação vascular foi significativamente maior no Gprpme (Figura 5A) ($p=0,01$) quando comparado com o Gcme (Figura 5B). Já a presença de células mononucleares e Hemorragia foram significativamente maior no Gcme ($p=0,01$, $p=0,03$, nesta ordem) quando comparado com Gprpme.

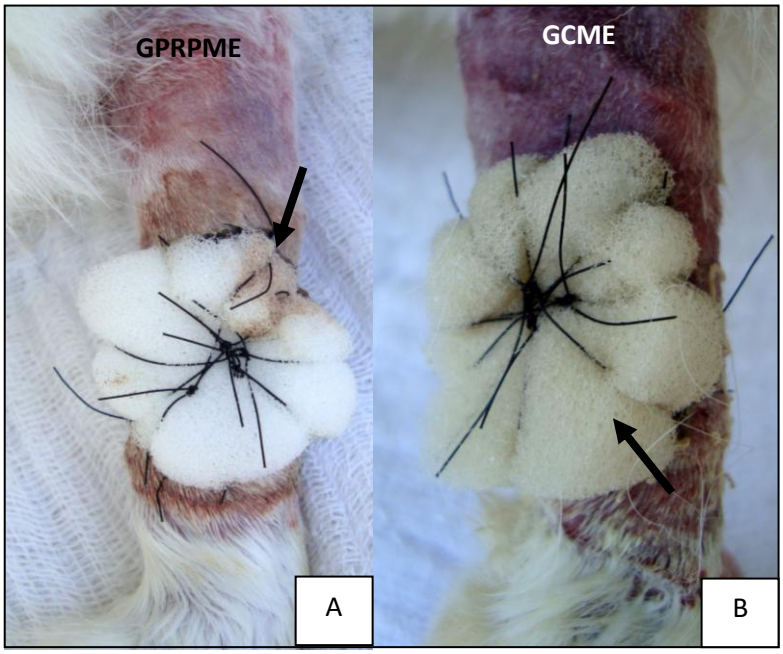

Figura 4. Imagens fotográficas da lesão no membro torácico esquerdo na região do carpo de coelhos (*Oryctolagus cuniculus*) mostrando as variáveis macroscópicas exsudato com 3 dias que foram significativas entre os grupos ($p<0,05$) submetidos ao procedimento de cirurgia reconstrutiva no Hospital Veterinário da Faculdade de Ciências Agrárias e Veterinárias (FCAV) da Unesp, Câmpus de Jaboticabal, 2015. A) Presença de exsudato na esponja cirúrgica (seta) no animal do GPRPME. B) Aspecto da esponja cirúrgica sem presença de exsudato (seta) no animal do GCME.

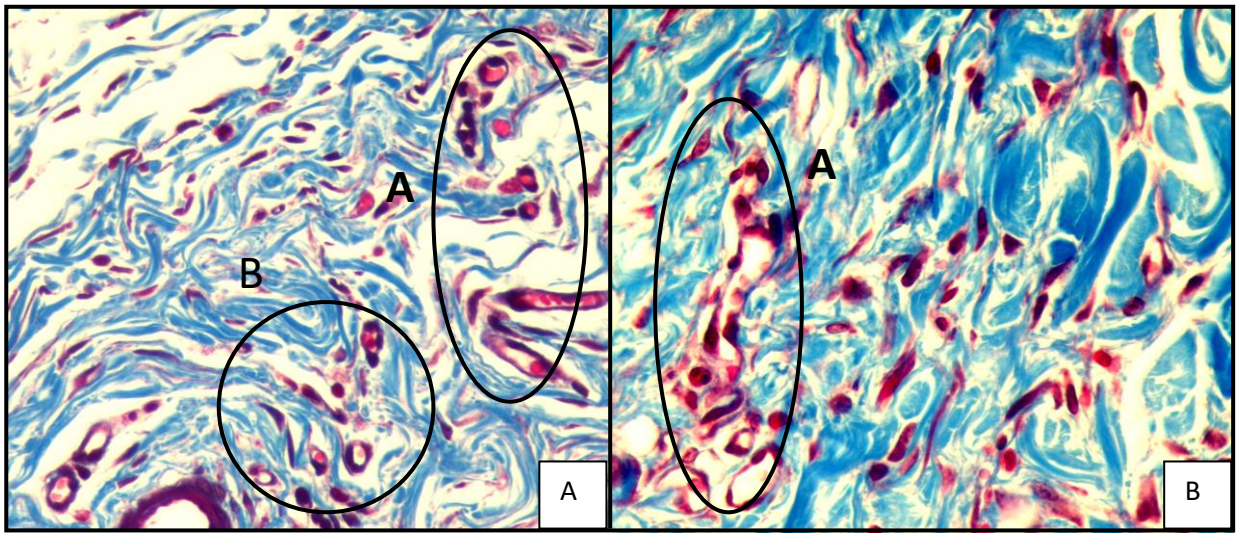

Figura 5. Aspecto histológico da Intensidade de proliferação vascular em coelhos (*Oryctolagus cuniculus*). Fotomicrografia óptica da derme de animais do Gprpme e Gcme submetidos ao procedimento de cirurgia reconstrutiva no Hospital Veterinário da Faculdade de Ciências Agrárias e Veterinárias (FCAV) da Unesp, Câmpus de Jaboticabal, 2015. A) Presença acentuada de neovascularização em A e B no Gprpme, aumento de 400X. B) Presença discreta de neovascularização em A no Gcme. Aumento de 400X. Coloração Tricrômio de Massom.

DISCUSSÃO

O plasma rico em plaquetas é um produto obtido do sangue, de fácil obtenção e com custo reduzidos, e é produzido em centrífugas laboratoriais. Esse produto submetido a tempos e rotações especificas, ao final apresenta contagem plaquetária superior a amostra inicial, sendo capaz de proporcionar efeitos terapêuticos em cicatrização de feridas (Camargo et al. 2002). Posto isso, o presente ensaio vai de encontro com a literatura (Camargo et al. 2002), visto que obteve-se o PRP a partir de centrífugas laboratoriais, como método de fácil execução e baixo custo, assim podendo ampliar sua aplicabilidade por profissionais de diversas modalidades clínicas e cirúrgicas.

Durante o processo de obtenção do PRP, o protocolo empregado sendo de única ou dupla centrifugação faz diferença no resultado final do produto (Maia et al. 2009). O protocolo da dupla centrifugação utilizado neste estudo foi capaz de promover concentração plaquetária 3 vezes maior em relação ao valor inicial da amostra (desvio padrão = 329.265 plaquetas/µL). Os resultados obtidos na amostra final de PRP quando comparada com a inicial foram significativamente maiores ($p=0,001$), assim, o protocolo de centrifugação foi adequado para obtenção de PRP de boa qualidade, semelhante ao descrito por Vendramin et al. (2010), estudo este que utilizou o gel de PRP em enxerto cutâneos em coelhos, obtido pelo método de dupla centrifugação, com tempos e velocidades semelhantes aos utilizados neste ensaio, e proporcionou a obtenção de bons resultados seguindo esse protocolo.

Diante dos resultados obtidos nesta pesquisa quanto as variáveis macroscópicas, edema, rubor, coloração, e aspecto cosmético que não foram significativo entre os grupos estudados, pode-se atribuir tais resultados ao emprego

das esponjas cirúrgicas como modalidade de curativo compressivo. Os resultados obtidos neste ensaio são semelhantes aos de Amâncio et al. (2006), que também utilizaram esponjas cirúrgicas como curativo compressivo em coelhos submetidos ao procedimento de enxertia com estimulação ultrassônica, e não encontraram diferenças significativas quanto à edema, rubor, coloração, bem como aspecto cosmético.

Quanto à presença de exsudato no 3º, que foi significativamente maior no Gprpme quando comparada com o Gcme, os resultados encontrados neste ensaio foram semelhantes ao obtidos por Vendramin et al. (2010), que utilizaram o plasma rico em plaquetas em enxertos cutâneos em coelhos e também obtiveram maior presença de exsudato nos animais tratados quando comparados com o controle. Posto isto, este estudo comprovou maior reação inflamatória com o uso do PRP, o que potencializa a cicatrização, que é um fenômeno fundamentalmente inflamatório.

O emprego do gel de plasma rico em plaquetas no subcutâneo do leito receptor da ferida no Gprpme proporcionou bons resultados, quando comparado com a solução fisiológica no Gcme, indicando que a diferença significativa encontrada quanto à proliferação vascular está relacionada com uso do PRP, sugerindo a capacidade deste composto promover angiogênese no local de aplicação, e favorecer a integração do enxerto no leito receptor sem presença de tecido de granulação. Além disso, a associação da esponja cirúrgica como curativo compressivo favoreceu no processo de cicatrização, evitando presença de edema e movimentação do enxerto. Sendo assim, os resultados deste ensaio quanto ao emprego do plasma rico em plaquetas são semelhantes ao Vendramin et al (2006), que testaram aplicação do produto em enxertos cutâneos, ósseos e na cicatrização de feridas, observando diminuição no tamanho das feridas, bem como o desenvolvimento de um tecido de granulação de melhor qualidade, com uma vascularização mais intensa. O resultado do emprego das esponjas cirúrgicas favorecerem a integração do enxerto no leito receptor são condizentes com Salgado et al. (2007), que realizaram cicatrização conduzida em enxertos de pele no tratamento de feridas e também obtiveram resultados satisfatórios empregando esponjas cirúrgicas no pós operatório das feridas.

Quanto à reação inflamatória da ferida avaliou-se presença das células mononucleares e polimorfonucleares, porém não houve diferenças significativas de células polimorfonucleares entre os grupos experimentais ($p>0,05$). Ademais, a presença de mononucleares ter sido significativamente maior no Gcme ($p=0,01$) quando comparada com o Gprpme indica presença de reação inflamatória, que pode ter sido decorrente do processo de cicatrização da ferida cirúrgica, no entanto, esperava-se que o aumento de células inflamatórias fosse maior no Gprpme devido a reação inflamatória local que é estimulada com emprego do PRP por seus componentes adjuvante na cicatrização, e tal fato não foi observado neste estudo. Os resultados encontrados nessa pesquisa são contrários aos de Vendramin et al. (2010), que utilizaram o PRP em enxertos cutâneos em coelhos e tiveram diferenças significativas entre os grupos tratado e controle quanto a presença de células inflamatórias, associando utilização do produto com aumento da resposta inflamatória, e ainda assim obtiveram bons resultados com o emprego do produto.

Quanto à hemorragia, os achados microscópicos indicaram que a presença de hemorragia foi maior no Gcme quando comparado com o Gprpme, sugere-se que tal resultado ocorreu devido ao enxerto se desprovido de irrigação própria, assim durante o processo de cicatrização ocorre a angiogênese, assim pode-se inferir que devido à formação de novos capilares de pequeno e médio calibre no leito receptor ocorra rompimento de alguns deles e extravasamento de sangue. Os resultados encontrados nesta pesquisa, são contrários ao de Vendramin et al. (2006) e Bauer et al. (2009) que utilizaram PRP em cirurgias reconstrutivas e avaliaram os efeitos do plasma rico em plaquetas no processo de reparação de feridas, e não tiveram presença significativa de Hemorragianos grupos experimentais. E quanto ao uso da esponja cirúrgica que reduz a presença de hemorragia, os resultados encontrados nesta pesquisa são contrários ao obtidos por Zanini et al. (2004), que utilizou esponjas cirúrgicas como curativo compressivo, e não encontrou diferença significativa na presença de hemorragia.

CONCLUSÃO

Conclui-se com este estudo que a utilização do plasma rico em plaquetas na forma de gel em enxertos cutâneos em malha é capaz de estimular a angiogênese na ferida favorecendo a integração do enxerto ao leito receptor, sem presença prévia de tecido de granulação. E associação da esponja cirúrgica como curativo compressivo favorece a cicatrização do enxerto por reduzir complicações como seu deslocamento no leito receptor e presença de edema, sendo viável e aconselhável seu emprego.

Agradecimentos. À Faculdade de Ciências Agrárias e Veterinárias de Jaboticabal (FCAV), Universidade Estadual Paulista (Unesp) pelo apoio estrutural e laboratorial; à Capes pela bolsa de estudos concedida no Brasil e em Portugal (PDSE); à equipe do laboratório da Universidade do Porto pelo apoio às atividades realizadas.

REFERÊNCIAS

Amâncio A.C.G., Barbieri C.H., Mazzer N., Garcia S.B & Thomazini J.A. Estimulação ultra-sônica da integração de enxertos de pele total – Estudo experimental em coelhos. *Acta Ortopédica Brasileira*, 14:5, 2006.

Amsellem P. Complications of Reconstructive Surgery in Companion Animals. *Veterinary Clinical Small Animal*, 41:995-1006, 2011.

Blair V.P & Brown J.B. Use and uses of large split skin grafts of intermediate thickness. *Surgery Gynecology Obstettrics*, 49:82-97, 1929.

Bauer J.A., Correa J., Lima M.F.L., Lima L.A.P.A & Pustiglioni F.E. Efeitos do plasma rico em plaquetas no processo de reparação de feridas dérmicas padronizadas em ratos. *Revista Periodontia*, 19:98-108, 2009.

Camargo P.M., Lekovic V., Weinlaender M., Vasilic N., Madzarevic M & Kenney E.B. Platelet-rich plasma and bovine porous bone mineral combined with guided tissue regeneration in tHE treatment of intrabony defects in humans. *Journal Periodontal Research,* 37: 300-306, 2002.

Castro J.L.C., Huppes R.R., De Nardi, A. B & Pazzini J.M. *Princípios e Técnicas de Cirurgias Reconstrutivas da Pele de Cães e Gatos (Atlas Colorido).* 1ªed. Medvep, Curitiba, 2015. 286p.

Fossum T.W. *Cirurgia de pequenos animais.*3ªed. Roca, São Paulo, 2007. 1390p.

Floryan K.M & Berghoff W.J. Intraoperative use of autologous platelet-rich and platelet-poor plasma for orthopedic surgery patients. *Aorn Journal*, 80: 668-674, 2004.

Garros I.C., Campos A.C.L., Tâmbara E.M., Tenório S.B., Torres O.J.M., Agulham M.A.,

Araújo A.C.F., Santis-Isolan P.M.B., Oliveira R.M & Arruda E.C.M. Extrato de passiflora edulis na cicatrização de feridas cutâneas abertas em ratos: estudo morfológico e histológico. *Acta Cirúrgica Brasileira*, 21:55-65, 2006.

Hedlund C.S. *Cirurgia de pequenos animais.* 3ª ed. São Paulo: Elsevier; 2008. 1390.

Hedlund C.S. *Cirurgia de pequenos animais*. 2ªed. Roca, São Paulo, 2005. 1390.

Leffell D.J. *Atlas of cutaneous surgery***.** W.B Saunders, Philadelphia, 1996. 400p.

Maia L & Souza M.V. Componetes ricos em plaquetas na reparação de afecções tendo-ligamentosas e osteoarticulares em animais. *Ciência Rural*, 39:1267-1274, 2009.

Pavletic M.M. Small Animal Wound Magementand Reconstructive Surgery. 3ªed.: Wiley – Blackwell, Iowa, 2010. 697p.

Pazzini J.M & Moraes P.C. *Princípios e Técnicas de Cirurgias Reconstrutivas da Pele de Cães e Gatos (Atlas Colorido).* 1ªed. Medvep, Curitiba, 2015. 286p.

Salgado M.I., Pretoianu A., Burgarelli G.L., Barbosa A.J.A & Alberti L.R. Cicatrização conduzida e enxerto de pele parcial no tratamento de feridas. *Revista da Associação Médica Brasileira,* 53:80-84, 2007.

Silva R.F., Rezende C.M.F., Paes Lemes F.O & Carmona J.U. Evaluación del método del tubo para concentrar plaquetas caninas: estudio celular. *Archivos de Medicina Veterinária,* 43:95-98, 2011.

Vasconez L.O & Vasconez H.C. *Surgical diagnosis and treatment.* 10ªed. Appleton & Lange Pubs, 1994. 1392p.

Vendramin F.S., Franco D., Nogueira C.M., Pereira M.S & Franco T.R. Plasma rico em plaquetas e fatores de crescimento: técnica de preparo e utilização em cirurgia plástica. *Revista do Colégio Brasileiro de Cirurgia,* 33:24-28, 2006.

Vendramin F.S., Franco D., Schamall R.F & Franco T.R. Utilização do plasma rico em plaquetas (PRP) autólogo em enxertos cutâneos em coelho. *Revista Brasileira de Cirurgia Plástica,* 25:4-10, 2010.

Zanini M., Machado Filho C.A.S & Timoner F. Uso de esponja cirúrgica para curativo compressivo de enxerto cutâneo. *Anais Brasileiro de Dermatologia*, 79: 359-362, 2004.

CAPÍTULO 7 – Considerações finais

Os resuldados encontrados neste estudo evidenciaram:

- O PRP em enxertos cutâneos contribui na sua integração ao leito receptor sem a presença prévia de tecido de granulação.
- Avaliando os modelos de enxertos em malha e camada associados ao emprego ou não de PRP e esponjas cirúrgicas: Enxerto em malha associado com o PRP e esponja cirúrgica apresentam efeitos favoráveis melhores que o enxerto em camada.
- As colorações Hematoxilina & Eosina e Tricrômico de Masson são eficazes para avaliação da angiogênese. Porém não são específicos para angiogênese, sendo assim exigem maior atenção do patologista no momento das análises, evitar falhas na contagem.
- Caveolina-1, CD31 e CD34 como marcadores de angiogênese em coelhos: todos os anticorpos são capazes de imunomarcar os vasos neoformados. Todavia a Caveolina-1 apresentou melhor imunomarcação de vasos de pequeno e médio calibre, com intensa delimitação do endotélio vascular, menor presença de fundo, sendo um marcador imunohistoquímico a considerar na avaliação da angiogênese em coelhos.

ANEXO I

Arquivo Brasileiro de Medicina Veterinária e Zootecnia

Submission Confirmation

Print

Thank you for your submission

Submitted to
Arquivo Brasileiro de Medicina Veterinária e Zootecnia

Manuscript ID
ABMVZ-2016-9560

Title
Surgical sponge associated with platelets rich plasma in skin mesh grafts and layer in rabbits (Oryctolagus cuniculus)

Authors
Pazzini, Josiane
Serafim, Eduardo
Uscategui, Ricardo
Almeida, Vivian
Oliva, Carlos Alfredo
Gartner, Fátima
Amorim, Irina
Faria, Fátima
Rêma, Alexandra
Reis Filho, Nazilton
Ferreira, Marilia
Silva, Ana Carolina
Huppes, Rafael
Castro Moraes, Paola
de Oliveira, João
De Nardi, Andrigo

Date Submitted
31-Oct-2016

Author Dashboard

© Thomson Reuters | © ScholarOne, Inc., 2016. All Rights Reserved.
ScholarOne Manuscripts and ScholarOne are registered trademarks of ScholarOne, Inc.
ScholarOne Manuscripts Patents #7,257,767 and #7,263,655.

@ScholarOneNews | System Requirements | Privacy Statement | Terms of Use

Normas submissão

Reprodução de artigos publicados: A reprodução de qualquer artigo publicado é permitida desde que seja corretamente referenciado. Não é permitido o uso comercial dos resultados. A submissão e tramitação dos artigos é feita exclusivamente on-line, no endereço eletrônico <http://mc04.manuscriptcentral.com/abmvz-scielo>. Não serão fornecidas separatas. Os artigos encontram-se disponíveis no endereço www.scielo.br/abmvz.

Orientações Gerais: Toda a tramitação dos artigos é feita exclusivamente pelo Sistema de publicação online do Scielo – ScholarOne, no endereço http://mc04.manuscriptcentral.com/abmvz-scielo sendo necessário o cadastramento no mesmo.

Leia "PASSO A PASSO – SISTEMA DE SUBMISSÃO DE ARTIGOS POR INTERMÉDIO DO SCHOLARONE"

Toda a comunicação entre os diversos autores do processo de avaliação e de publicação (autores, revisores e editores) será feita apenas de forma eletrônica pelo Sistema, sendo que o autor responsável pelo artigo será informado automaticamente por e-mail sobre qualquer mudança de status do mesmo.

Fotografias, desenhos e gravuras devem ser inseridos no texto e quando solicitados pela equipe de editoração também devem ser enviados, em separado, em arquivo com extensão JPG, em alta qualidade (mínimo 300dpi), zipado, inserido em "Figure or Image" (Step 6).

É de exclusiva responsabilidade de quem submete o artigo certificar-se de que cada um dos autores tenha conhecimento e concorde com a inclusão de seu nome no texto submetido.

O ABMVZ comunicará a cada um dos inscritos, por meio de correspondência eletrônica, a participação no artigo. Caso um dos produtores do texto não concorde em participar como autor, o artigo será considerado como desistência de um dos autores e sua tramitação encerrada.

Comitê de Ética: É indispensável anexar cópia, em arquivo PDF, do Certificado de Aprovação do Projeto da pesquisa que originou o artigo, expedido pelo CEUA (Comitê de Ética no Uso de Animais) de sua Instituição, em atendimento à Lei 11794/2008. O documento deve ser anexado em "Ethics Conmitee" (Step 6). Esclarecemos que o número do Certificado de Aprovação do Projeto deve ser mencionado no campo Material e Métodos.

Tipos de artigos aceitos para publicação: Artigo científico - É o relato completo de um trabalho experimental. Baseia-se na premissa de que os resultados são posteriores ao planejamento da pesquisa.

Seções do texto: Título (português e inglês), Autores e Afiliação (somente na "Title Page" – Step 6), Resumo, Abstract, Introdução, Material e Métodos, Resultados, Discussão (ou Resultados e Discussão), Conclusões, Agradecimentos (quando houver) e Referências. O número de páginas não deve exceder a 15, incluindo tabelas, figuras e Referências. O número de Referências não deve exceder a 30.

Preparação dos textos para publicação: Os artigos devem ser redigidos em português ou inglês, na forma impessoal.

Formatação do texto: O texto NÃO deve conter subitens em nenhuma das seções do artigo, deve ser apresentado em arquivo Microsoft Word e anexado como "Main Document" (Step 6), no formato A4, com margem de 3cm (superior, inferior, direita e esquerda), na fonte Times New Roman, no tamanho 12 e no espaçamento de entrelinhas 1,5, em todas as páginas e seções do artigo (do título às referências), com linhas numeradas.

Não usar rodapé. Referências a empresas e produtos, por exemplo, devem vir, obrigatoriamente, entre parêntesis no corpo do texto na seguinte ordem: nome do produto, substância, empresa e país.

Seções de um artigo: Título: Em português e em inglês. Deve contemplar a essência do artigo e não ultrapassar 50 palavras.

Autores e Filiação: Os nomes dos autores são colocados abaixo do título, com identificação da instituição a qual pertencem. O autor e o seu e-mail para correspondência devem ser indicados com asterisco somente no "Title Page" (Step 6), em arquivo Word.

Resumo e Abstract: Deve ser o mesmo apresentado no cadastro contendo até 200 palavras em um só parágrafo. Não repetir o título e não acrescentar revisão de literatura. Incluir os principais resultados numéricos, citando-os sem explicá-los, quando for o caso. Cada frase deve conter uma informação completa. Palavras-chave e Keywords: No máximo cinco e no mínimo duas*.

* na submissão usar somente o Keyword (Step 2) e no corpo do artigo constar tanto keyword (inglês) quanto palavra-chave (português), independente do idioma em que o artigo for submetido.

Introdução:Explanação concisa na qual os problemas serão estabelecidos , bem como a pertinência, a relevância e os objetivos do trabalho. Deve conter poucas referências, o suficiente para balizá-la.

Material e Métodos: Citar o desenho experimental, o material envolvido, a descrição dos métodos usados ou referenciar corretamente os métodos já publicados. Nos trabalhos que envolvam animais e/ou organismos geneticamente modificados deverão constar obrigatoriamente o número do Certificado de Aprovação do CEUA. (verificar o Item Comitê de Ética).
Resultados: Apresentar clara e objetivamente os resultados encontrados.
Tabela. Conjunto de dados alfanuméricos ordenados em linhas e colunas. Usar linhas horizontais na separação dos cabeçalhos e no final da tabela. O título da tabela recebe inicialmente a palavra Tabela, seguida pelo número de ordem em algarismo arábico e ponto (ex.: Tabela 1.). No texto, a tabela deve ser referida como Tab seguida de ponto e do número de ordem (ex.: Tab. 1), mesmo quando referir-se a várias tabelas (ex.: Tab. 1, 2 e 3). Pode ser apresentada em espaçamento simples e fonte de tamanho menor que 12 (o menor tamanho aceito é oito). A legenda da Tabela deve conter apenas o indispensável para o seu entendimento. As tabelas devem ser obrigatoriamente inseridas no corpo do texto de preferência após a sua primeira citação.
Figura. Compreende qualquer ilustração que apresente linhas e pontos: desenho, fotografia, gráfico, fluxograma, esquema etc. A legenda recebe inicialmente a palavra Figura, seguida do número de ordem em algarismo arábico e ponto (ex.: Figura 1.) e é citada no texto como Fig seguida de ponto e do número de ordem (ex.: Fig.1), mesmo se citar mais de uma figura (ex.: Fig. 1, 2 e 3). Além de inseridas no corpo do texto, fotografias e desenhos devem também ser enviados no formato JPG com alta qualidade, em um arquivo zipado, anexado no campo próprio de submissão, na tela de registro do artigo. As figuras devem ser obrigatoriamente inseridas no corpo do texto de preferência após a sua primeira citação.
Nota: Toda tabela e/ou figura que já tenha sido publicada deve conter, abaixo da legenda, informação sobre a fonte (autor, autorização de uso, data) e a correspondente referência deve figurar nas Referências.
Discussão: Discutir somente os resultados obtidos no trabalho. (Obs.: As seções Resultados e Discussão poderão ser apresentadas em conjunto a juízo do autor, sem prejudicar qualquer uma das partes).
Conclusões: As conclusões devem apoiar-se nos resultados da pesquisa executada e serem apresentadas de forma objetiva, SEM revisão de literatura, discussão, repetição de resultados e especulações.
Agradecimentos: Não obrigatório. Devem ser concisamente expressados.
Referências: As referências devem ser relacionadas em ordem alfabética, dando-se preferência a artigos publicados em revistas nacionais e internacionais, indexadas. Livros e teses devem ser referenciados o mínimo possível, portanto, somente quando indispensáveis. São adotadas as normas gerais da ABNT, adaptadas para o ABMVZ.
Taxas de submissão e de publicação: Taxa de submissão: A taxa de submissão de R$50,00 deverá ser paga por meio de boleto bancário emitido pelo sistema eletrônico do Conveniar http://conveniar.fepmvz.com.br/eventos/#servicos (necessário preencher cadastro). Somente artigos com taxa paga de submissão serão avaliados.
Caso a taxa não seja quitada em até 30 dias será considerado como desistência do autor.
Taxa de publicação:. A taxa de publicação de R$150,00 por página, por ocasião da prova final do artigo. A taxa de publicação deverá ser paga por meio de depósito bancário, cujos dados serão fornecidos na aprovação do artigo.
OBS.: Quando os dados para a nota fiscal forem diferentes dos dados do autor de contato deve ser enviado um e-mail para abmvz.artigo@abmvz.org.br comunicando tal necessidade.

ANEXO II

BMC
Veterinary Research

Editorial Manager

HOME • LOGOUT • HELP • REGISTER • UPDATE MY INFORMATION • JOURNAL OVERVIEW
MAIN MENU • CONTACT US • SUBMIT A MANUSCRIPT • INSTRUCTIONS FOR AUTHORS

Role: Author Username: josipazzini

Submissions Being Processed for Author Josiane Morais Pazzini

Page: 1 of 1 (1 total submissions) Display 10 results per page.

Action	Manuscript Number	Title	Initial Date Submitted	Status Date	Current Status
View Submission View Reference Checking Results Correspondence View Publication Charges Send E-mail	BVET-D-16-00669	USING LAYER GRAFTS AND MESH GRAFTS TO CORRECT SIGNIFICANT DEFECTS INDUCED IN THE CARPALS OF RABBITS (ORYCTOLAGUS CUNICULUS) BY ASSOCIATING PLATELET-RICH PLASMA	24 Nov 2016	02 Jan 2017	Reviews Received

Page: 1 of 1 (1 total submissions) Display 10 results per page.

Normas submissão

Preparing your manuscript: The information below details the section headings that you should include in your manuscript and what information should be within each section. Please note that your manuscript must include a 'Declarations' section including all of the subheadings (please see below for more information).

Title Page: The title page should:present a title that includes, if appropriate, the study design e.g.:

"A versus B in the treatment of C: a randomized controlled trial", "X is a risk factor for Y: a case control study", "What is the impact of factor X on subject Y: A systematic review" or for non-clinical or non-research studies: a description of what the article reports list the full names, institutional addresses and email addresses for all authors if a collaboration group should be listed as an author, please list the Group name as an author. If you would like the names of the individual members of the Group to be searchable through their individual PubMed records, please include this information in the "Acknowledgements" section in accordance with the instructions below indicate the corresponding author.

Abstract: The Abstract should not exceed 350 words and should be structured with a background, main body of the abstract and short conclusion. Please minimize the use of abbreviations and do not cite references in the abstract. Keywords: Three to ten keywords representing the main content of the article. Background: The Background section should explain the background to and perceived need for the database, mentioning forerunners and competitors, and stating its potential value.

Construction and content: The database schema and implementation should be described in this section, together with information on data sources, the informatics of data generation and quality control.

Utility and discussion: These may be broken into subsections with short, informative headings. The user interface should be described and a discussion of the intended uses of the database, and the benefits that are envisioned, should be included, together with data on how its performance and functionality compare with and improve on functionality of similar existing databases. A case study of the use of the database may be presented. The planned future development of new features, if any, should be mentioned.

Conclusions

This should state clearly the main conclusions and include an explanation of their relevance or importance to the field.

List of abbreviations: If abbreviations are used in the text they should be defined in the text at first use, and a list of abbreviations can be provided.

Declarations: All manuscripts must contain the following sections under the heading 'Declarations':

Ethics approval and consent to participate, Consent for publication. Availability of data and material, Competing interests, Funding, Authors' contributions, Acknowledgements, Authors' information (optional)

All references, including URLs, must be numbered consecutively, in square brackets, in the order in which they are cited in the text, followed by any in tables or legends. The reference numbers must be finalized and the reference list fully formatted before submission.

Examples of the BioMed Central reference style are shown below. Please ensure that the reference style is followed precisely. See our editorial policies for author guidance on good citation practice. Web links and URLs: All web links and URLs, including links to the authors' own websites, should be given a reference number and included in the reference list rather than within the text of the manuscript. They should be provided in full, including both the title of the site and the URL, as well as the date the site was accessed, in the following format: The Mouse Tumor Biology Database. http://tumor.informatics.jax.org/mtbwi/index.do. Accessed 20 May 2013. If an author or group of authors can clearly be associated with a web link (e.g. for blogs) they should be included in the reference.

ANEXO III

Decision Letter (PVB-5109)

From: ambrosio-pvb@uol.com.br

To: josipazzini@hotmail.com

CC:

Subject: Pesquisa Veterinária Brasileira - Decision on Manuscript ID PVB-5109

Body: 11-Jan-2017

Dear Ms. Pazzini:

Manuscript ID PVB-5109 entitled "Immunohistochemistry and histochemistry to evaluation of angiogenesis in rabbits submitted to the use of skin grafts associated with platelet-rich plasma" which you submitted to the Pesquisa Veterinária Brasileira, has been reviewed. The comments of the reviewer(s) are included at the bottom of this letter.

The reviewer(s) have recommended publication, but also suggest some minor revisions to your manuscript. Therefore, I invite you to respond to the reviewer(s)' comments and revise your manuscript.

To revise your manuscript, log into https://mc04.manuscriptcentral.com/pvb-scielo and enter your Author Center, where you will find your manuscript title listed under "Manuscripts with Decisions." Under "Actions," click on "Create a Revision." Your manuscript number has been appended to denote a revision.

You may also click the below link to start the revision process (or continue the process if you have already started your revision) for your manuscript. If you use the below link you will not be required to login to ScholarOne Manuscripts.

*** PLEASE NOTE: This is a two-step process. After clicking on the link, you will be directed to a webpage to confirm. ***

https://mc04.manuscriptcentral.com/pvb-scielo?URL_MASK=0f3a7bb8962240c08a9cdef7aad3dabc

You will be unable to make your revisions on the originally submitted version of the manuscript. Instead, revise your manuscript using a word processing program and save it on your computer. Please also highlight the changes to your manuscript within the document by using the track changes mode in MS Word or by using bold or colored text.

Once the revised manuscript is prepared, you can upload it and submit it through your Author Center.

When submitting your revised manuscript, you will be able to respond to the comments made by the reviewer(s) in the space provided. You can use this space to document any changes you make to the original manuscript. In order to expedite the processing of the revised manuscript, please be as specific as possible in your response to the reviewer(s).

IMPORTANT: Your original files are available to you when you upload your revised manuscript. Please delete any redundant files before completing the submission.

Because we are trying to facilitate timely publication of manuscripts submitted to the Pesquisa Veterinária Brasileira, your revised manuscript should be submitted by 11-Feb-2017. If it is not possible for you to submit your revision by this date, we may have to consider your paper as a new submission.

Once again, thank you for submitting your manuscript to the Pesquisa Veterinária Brasileira and I look forward to receiving your revision.

Sincerely,
Dr. Carlos Eduardo Ambrósio
Associate Editor, Pesquisa Veterinária Brasileira
ambrosio-pvb@uol.com.br, ceambrosio@usp.br

ANEXO IV

rBMv
REVISTA BRASILEIRA DE MEDICINA VETERINÁRIA
Avenida Presidente Vargas, 446/1004, Edifício Delamare
www.rbmv.com.br submissao@rbmv.com.br Rio de Janeiro, RJ - 20017-907, Tel.: 21 2516-0706

Rio de Janeiro, em 25 de janeiro de 2016

Prezado(a) Autor(a), Dr(a). Josiane Morais Pazzini

Recebemos em 16.1.2016 a submissão do artigo "**Emprego de plasma rico em plaquetas associado à esponja cirúrgica em enxertos cutâneos em coelhos (Oryctolagus cuniculus)**", de sua autoria, Eduardo Luis Serafim, Ricardo Ramirez Andrez Uscategui, Vivian Tavares de Almeida, Carlos Alfredo Calpaa Oliva, Fátima Gärtner, Maria de Fátima Faria de Carvalho, Nazilton De Paula Reis, Marília Gabriele Prado Albuquerque Ferreira, Paola Castro Moraes, João Ademir de Oliveira e Andrigo Barboza De Nardi, com vistas à publicação na Revista Brasileira de Medicina Veterinária. O artigo foi registrado como RBMV 0262, e este número de registro é a referência que o(a) senhor(a) deverá usar para obter qualquer informação durante a tramitação do mesmo.

Agradecemos por preferir a Revista Brasileira de Medicina Veterinária e ficamos à disposição.

Atenciosamente,

Carlos Wilson Gomes Lopes
Editor