



Case Report

Bilateral Dorsal Subluxation of the Proximal Interphalangeal Joint of the Hind Limb in a Mare: Case Report

Dietrich Pizzigatti DVM, MSc^a, Carlos Alberto Hussni DVM, PhD^a,
 Celso Antonio Rodrigues DVM, PhD^a, Marcos Jun Watanabe DVM, PhD^a,
 Juliana de Moura Alonso DVM^a, Luiz Carlos Vulcano DVM, PhD^b,
 Luis Emiliano Cisneros Álvarez DVM, MSc^b

^a Department of Veterinary Surgery and Anesthesiology, School of Veterinary Medicine and Animal Science (FMVZ), São Paulo State University (UNESP), Rubião Júnior District, Botucatu, São Paulo State, Brazil

^b Department of Veterinary Diagnostic Imaging, FMVZ/UNESP, Rubião Júnior District, Botucatu, São Paulo State, Brazil

ARTICLE INFO

Article history:

Received 28 September 2011

Received in revised form

22 March 2012

Accepted 9 November 2012

Available online 14 March 2013

Keywords:

Subluxation

Proximal interphalangeal joint

Pastern

Tenectomy

Medial digital flexor

ABSTRACT

Subluxation of the proximal interphalangeal joint is a rare and little studied condition in horses. We describe the case of a 12-year-old mare with bilateral dorsal subluxation of the proximal interphalangeal joint of the hind feet. Tenectomy of the medial digital flexor was performed in both limbs, and the patient showed signs of recovery within 14 days. Goniometry of the proximal interphalangeal joints 10 months after surgery showed diminution of 5° for the proximal interphalangeal axis of the left hind limb. However, no change was found for the joint angle of the right limb. Even so, the patient's gait and radiographic results were normal, and clinical abnormalities such as joint clicking and swelling were no longer observed.

© 2013 Elsevier Inc. All rights reserved.

1. Introduction

Subluxation of the proximal interphalangeal joint (PIJ) is defined as the palmar/plantar or dorsal displacement of the distal end of the proximal phalanx affecting either forelimb or hind limb [1-5]. This uncommon condition occurs mainly in young horses secondary to injuries of the proximal interphalangeal collateral ligaments or the suspensory ligament and its extensor branches or flexor deformities caused by contracture of the distal sesamoid ligament and deep digital flexor tendon (DDFT) [4,6-9].

In cases of dorsal subluxation of the PIJ (DS-PIJ), clinical signs include swelling of the dorsal surface of the PIJ,

audible articular clicking, and elevation of the dorsal angle of the PIJ [2,4,9]. The diagnosis of DS-PIJ is based on physical examination and goniometric measurement of the distal limb [2,4,5,9-12].

Anti-inflammatory drugs associated with physiotherapy or external cast coaptation have been described as safety clinical options for therapy [2,4,9]. However, long-term convalescence (up to 6 months) and excessive care are necessary in order to avoid instability of the PIJ in these cases [3]. Direct surgical techniques, such as arthrodesis [6,12-14], screw fixation, and dynamic compression plates associated with chemical or physical ankylosis also have been successfully used to correct the PIJ angle of the hind limb in cases of subluxation [2,12,14-17].

On the other hand, tenectomy of the medial digital flexor muscle (m. flexor digitorum medialis) (Fig. 1) is an indirect surgical technique that allows elongation of the DDFT leading to correction of the DS-PIJ [2,11,18]. This procedure was first reported with success by Shiroma et al.

Corresponding author at: Dietrich Pizzigatti, DVM, MSc, School of Veterinary Medicine and Animal Science, Department of Veterinary Surgery and Anesthesiology, Rubião Júnior District, 18618-000 Botucatu, São Paulo State, Brazil.

E-mail address: vet_pizzigatti@yahoo.com.br (D. Pizzigatti).

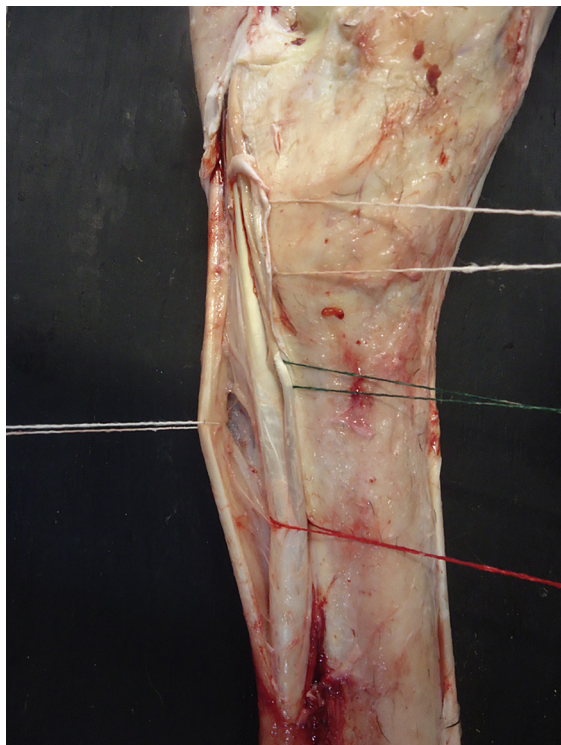


Fig. 1. Medial surface of the left hind limb. DDFT (red thread), medial digital flexor (green thread), superficial digital flexor tendon (left white thread), and tarsal fascia (right white thread) are shown.

[11] in three cases of bilateral DS-PIJ. Satisfactory results were also obtained by Nicoletti et al. [18]. This report describes the positive results of using tenectomy of the medial digital flexor for the treatment of bilateral DS-PIJ of the hind limb in an adult mare.

2. Case

We assessed a 12-year-old mare with bilateral swelling at the pastern and an audible joint “popping” sound at gait. Clinical examination showed bilateral swelling at the PIJ along with a noisy clicking of the left hind limb (LHL) at landing. The patient did not present lameness at walk and trot. However, mild lameness of the LHL was observed after flexion test of the proximal and distal interphalangeal joints. Neither distress nor discomfort was present at manipulation of the joints. Nevertheless, pain was evident on pastern palpation, particularly after pressure on the proximal interphalangeal joint of both hind limbs.

Lateromedial radiographs from the distal diaphysis of the metatarsus to the distal end of the third phalanx were performed in quadrupedal position with the patient mounted on a wood platform 8 cm high. Radiographs of the limbs were obtained with a portable conventional radiographic device (FNX-90 Jockey-Electra, São Paulo, Brazil) set at 65 peak kilovolts (kVp), 5 milliamperere seconds (mAs), a film-focus distance of 70 cm, on 30 × 40 film (Kodak-Medical X-ray Film General Purpose Green-MXG, São Paulo, Brazil) that was processed in an automatic x-ray film processor. Radiographs showed no signs of degenerative joint disease or fracture; however, joint misalignment of

the PIJ of both hind limbs was confirmed on lateral images. Thus, lateral radiographs were properly mounted on a lightbox and digitized with a digital photographic camera for goniometry, which was performed using an angular dimension tool software (Corel Draw 12, Corel Corporation, Ottawa, Canada). The dorsal angle of the PIJ was calculated by, first, establishing the diaphyseal axes of the proximal and middle phalanxes, drawing straight lines through the centers of rotation associated with the fetlock and pastern joints and with the pastern and coffin joints, respectively, as described by Craig et al. [19]. Then, we set a start point for the angular dimension tool at the intersection of these two lines, measuring the dorsal angle formed between them. Goniometric assessment disclosed dorsal left and right proximal interphalangeal angles of 196° and 190°, respectively (Fig. 2A-D).

Based on clinical and radiographic findings, the patient's condition was diagnosed as bilateral subluxation of the proximal interphalangeal joint, and tenectomy of the medial digital flexor was decided upon. Prior to surgery, the patient was held off food and water for 24 and 12 hours, respectively. Then, xylazine (1 mg/kg, intravenous [IV]; Sedazine 10%; Fort Dodge Animal Health Ltd, Campinas, São Paulo, Brazil) was used as a premedication, followed by an association of diazepam (0.05 mg/kg) and ketamine (2 mg/kg; Ketaset; Fort Dodge Animal Health, Fort Dodge, IA) in guaifenesin (10% solution) (100 mg/kg, IV; Guaifenject; Butler, Dublin, OH) for anesthetic induction. The animal was restrained in dorsal recumbency for tracheal intubation and anesthetized with isoflurane and oxygen. An incision was made proximodistally along the medial surface of the proximal end of the third metatarsal bone, between the DDFT and the suspensory ligament, as described by Nicoletti et al. [18]. Then, 3 cm of the medial digital flexor tendon were removed. The fascia was closed with a running suture using 2-0 polyglactin 910 suture (Vycril; Ethicon, Somerville, NJ), and the skin was closed with an interrupted pattern of 4-0 nylon. Postsurgical medication included three prophylactic doses of a mixture of benzathine penicillin (20,000 IU/kg), procaine penicillin (10,000 IU/kg), potassium penicillin G (10,000 IU/kg), and streptomycin/dihydrostreptomycin (16 mg/kg, intramuscular [IM], once every 72 hours) (Pentabiótico Reforçado; Fort Dodge, Campinas, Brazil), and five doses of phenylbutazone (4 mg/kg, IV, once a day; Fenilbutazona; VetNil, Campinas, Brazil). Daily wound care with chlorhexidine solution and dressing change was also performed.

2.1. Outcome

Joint clicking ceased immediately after surgery. On visual inspection, swelling at the dorsal aspect of the PIJ became imperceptible after 4 days in both hind limbs, and angular deviation of the affected joints was not longer observed. The patient was kept 14 days in a pen until skin sutures were removed and was then discharged. Goniometric reassessment 10 months later revealed an apparent reduction of 5° of the PIJ angle of the left hind limb (i.e., from 196° to 191°). However, the angle of the right PIJ remained the same as that at the first evaluation (i.e., 190°) (Figs. 3A and B). Neither swelling nor clicking of the proximal interphalangeal joint was observed in any of the limbs.

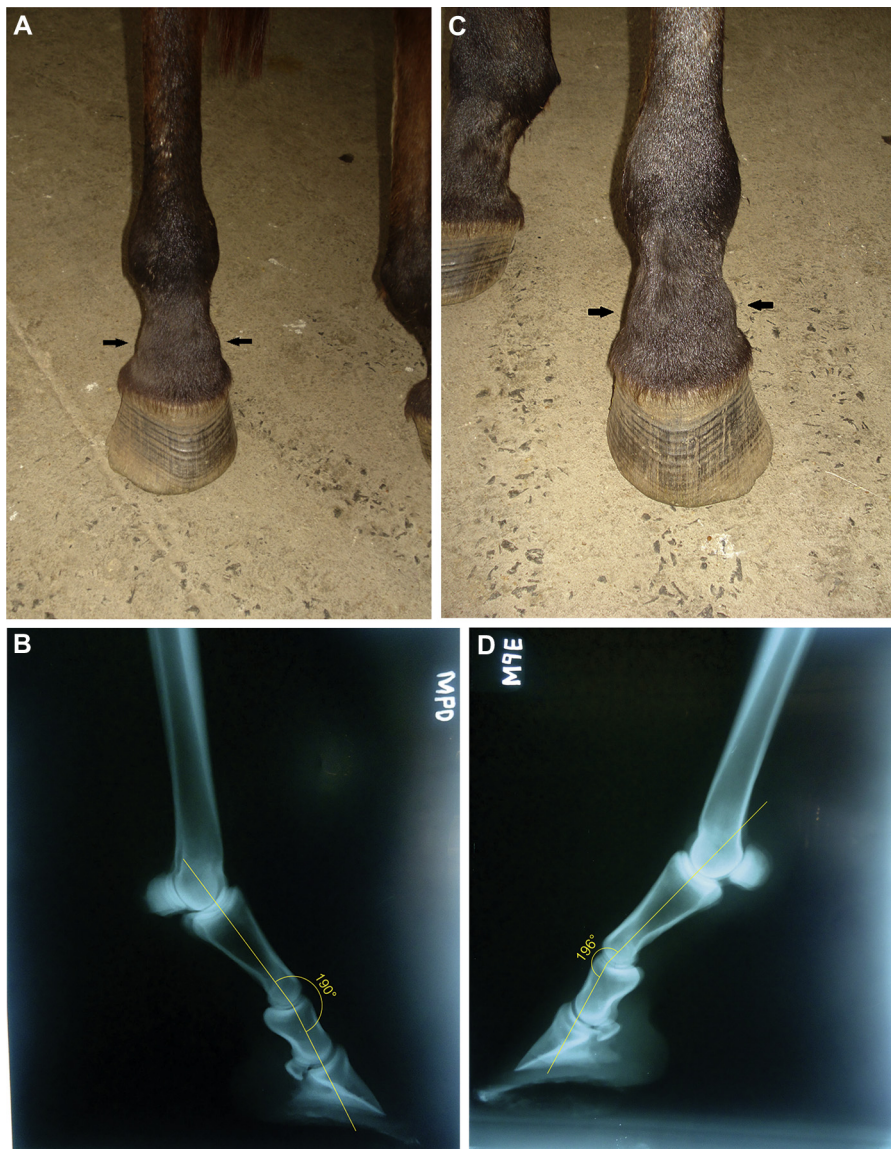


Fig. 2. Volume increase at the dorsal aspect of the proximal interphalangeal joint of the right (A) and left (C) hind limbs. Goniometric assessment of the proximal interphalangeal joints of the right (B, 190°) and left (D, 196°) hind limbs.

3. Discussion and Conclusions

Findings in this case were similar to those of previous studies [1,2,9,11,18], including swelling at the dorsal surface of the pastern, audible joint clicking caused by the dorsal displacement of the PIJ during walking, and absence of lameness suggesting an intermittent subluxation.

Our patient presented neither clinical signs nor lameness from the fourth day after surgery until discharge. Remission of clinical signs after tenectomy of the medial digital flexor was previously described in the short-term follow-up after 30 days [11,18]. Similar results were observed in one animal up to 10 months after surgery [2].

The use of anti-inflammatory drugs, physiotherapy [1,2,15], or cast coaptation [3] has been mentioned in cases of unilateral subluxation of the PIJ. When using cast immobilization, it is thought the weight is supported by the

contralateral (healthy) limb, allowing stability with minimal load on the affected digit. However, the goal of surgery in our case (i.e., bilateral subluxation) was to achieve a more equal load distribution among hind limbs and to institute early normal motion. Other reliable techniques for the treatment of DS-PIJ include arthrodesis [5,6,13,14], screw fixation, and dynamic compression plates associated with ankylosis of the PIJ [1,12,16,17]. However, surgical procedures should be chosen by the practitioner on a case-by-case basis. For instance, arthrodesis and ankylosis have been used when other pathological conditions coexist with the subluxation (e.g., joint infection, intra-articular epiphyseal fracture, or fractures affecting the axis of the phalanxes and so of the PIJ) [6,13,14,17]. In our experience treating joint infection or intra-articular fractures alone (i.e., without subluxation), arthrodesis, screw fixation, dynamic plates, and ankylosis are indicated, provided that

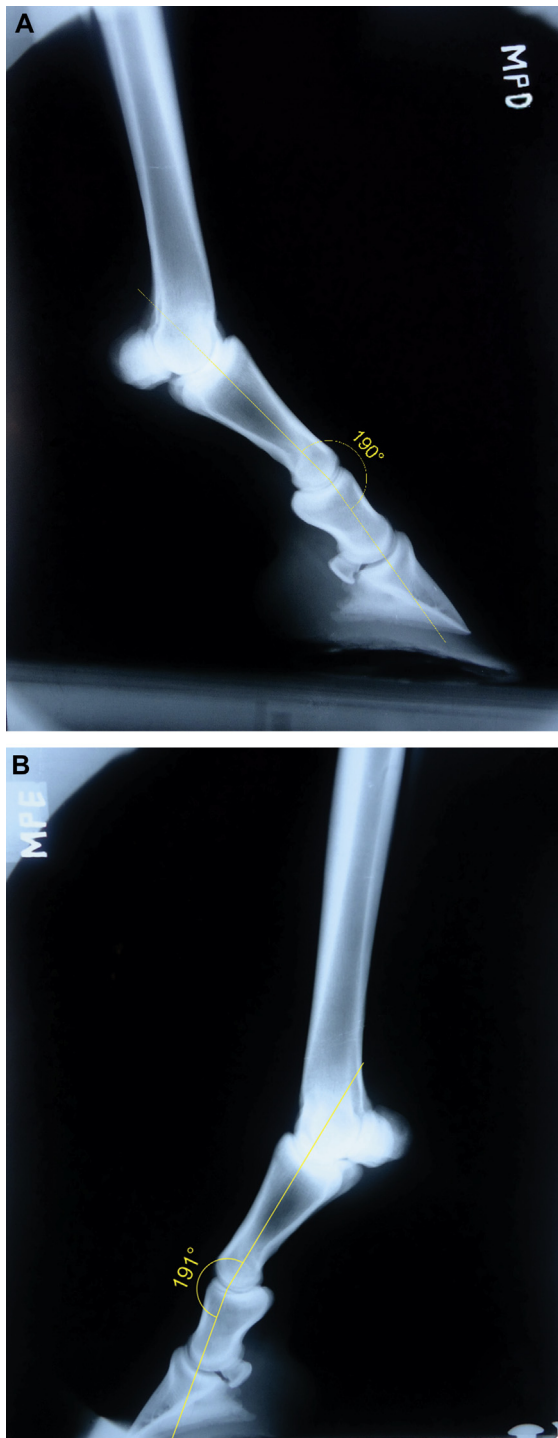


Fig. 3. Goniometric assessment of the proximal interphalangeal joints of the right (**A**, 190°) and left (**B**, 191°) hind limbs 10 months after tenectomy of the medial head of the deep digital flexor tendon.

all other less aggressive treatments have failed, as these techniques cause permanent loss of joint function.

In order to evaluate the long-term effects of surgery clinical, radiographic, and goniometric reassessments were performed 10 months after surgery. We consider the absence of radiographic findings of degenerative joint

disease, lameness, clicking, and swelling as a favorable outcome. Goniometry revealed a slight reduction of 5° (to 191°) of the PIJ of the left hind limb. However, no change of angle of the PIJ of the right hind limb was found (190°). Apparent goniometric improvement in the PIJ was observed in only one of the hind limbs. We infer that despite performing surgery to better distribute the load between the hind feet, there is a tendency for the patient to defend the most affected limb (left, in our case) and so overload the less affected one (right).

Reliability of the visual goniometric technique for the equine distal joints (i.e., coffin, pastern, and fetlock) was previously established by Bushe et al. [20] and confirmed by other authors [21-23]. We used the technique by Craig et al. [19] partially in order to determine the diaphyseal axes of the proximal and middle phalanges, assuming so that the angle formed by the intersection of these two straight lines shares the same confidence interval and likewise the same deviation (i.e., 95% confidence interval of 0.68° for the pastern [difference of $\pm 2^\circ$]). However, once the axes of the phalanges were established, we used the visual technique described by Bushe et al. [24] to graphically relate the measured angle with the joint evaluated (i.e., proximal interphalangeal joint). We set a start point for the angular dimension tool of Corel Draw at the proximal interphalangeal space by drawing a line parallel (dorsally) to the previously established axis of the middle phalanx. Thus, the angle formed by the intersection of this parallel line and the axis of the proximal phalanx is the same as that formed by the intersection of the diaphyseal axes of the proximal and middle phalanges. Finally, although these techniques can be easily performed using triangles, compass, and a protractor or a standard goniometer, the use of software makes the procedure much easier and more practical.

Reference values for the proximal interphalangeal angle of the forelimb (166°-173.5°) were previously obtained using similar goniometric techniques [18,20,21,25]. However, to our knowledge, no specific data regarding metatarsophalangeal, proximal interphalangeal, and distal interphalangeal joint angles of the hind limb have been published to date. Data available for the angle of the hind limb digit make reference only to the coffin and pastern [26]. Thus, studies of the normal angle of the joints of the hind limb digit should be further addressed. Above all, correction of lameness and other clinical signs while maintaining the function of the PIJ justifies the use of this technique.

References

- [1] Auer JA. Disease of pastern region. In: Colahan PT, Mayhew IG, Merritt AM, Moore JM, editors. Equine medicine and surgery. St. Louis, MO: Mosby; 1999. p. 1548-50.
- [2] Stashak TS. Luxação e subluxação da articulação interfalângica proximal (quartela). In: Stashak TS, editor. Claudicação em Equinos Segundo Adams. 5th ed. Brasil: Editora Roca; 2006. p. 1093.
- [3] Nikahval B, Naeiniand AT, Parizi AM. Cast immobilization for treatment of dorsally subluxated proximal interphalangeal joint in a Thoroughbred mare. Iranian Journal of Veterinary Research 2009; 10:294-7.
- [4] Nixon AJ. Phalanges, metacarpophalangeal and metatarsophalangeal joints. In: Auer JA, Stick JA, editors. Equine surgery. 3rd ed. Philadelphia: WB Saunders (Elsevier); 2006. p. 1222-3.

- [5] Watts AE, Fortier LA, Caldwell FJ. Proximal interphalangeal joint arthrodesis in a one-month-old foal for superficial digital flexor tendon and straight sesamoidean ligament disruption. *Equine Vet Educ* 2007;19:407-12.
- [6] Knox PM, Watkins JP. Proximal interphalangeal joint arthrodesis using a combination plate-screw technique in 53 horses (1994–2003). *Equine Vet J* 2006;38:538-42.
- [7] Lose MP. Correction of hindleg pastern subluxation. *Mod Vet Pract* 1981;62:156.
- [8] Parks A. Form and function of the equine digit. *Vet Clin North Am Equine Pract* 2003;19:285-307.
- [9] Ruggles AJ. The proximal and middle phalanges and proximal interphalangeal joint. In: Ross MW, Dyson SJ, editors. *Diagnosis and management of lameness in the horse*. 2nd ed. St. Louis, MO: WB Saunders (Elsevier); 2003. p. 342-7.
- [10] Redden RF. Radiographic imaging of the equine foot. *Vet Clin North Am Equine Pract* 2003;19:379-92.
- [11] Shiroma JT, Engel HN, Wagner PC, Watrous BJ. Dorsal subluxation of the proximal interphalangeal joint in the pelvic limb of 3 horses. *J Am Vet Med Assoc* 1989;195:777-80.
- [12] Watts AE, Fortier LA, Nixon AJ, Ducharme NG. A technique for laser-facilitated equine pastern arthrodesis using parallel screws inserted in lag fashion. *Vet Surg* 2010;39:244-53.
- [13] Carol JP, Fretz PB, Bailey JV, Barber SM. Proximal interphalangeal arthrodesis in the horse. A retrospective study and a modified screw technique. *Vet Surg* 1990;19:196-202.
- [14] Zubrod CJ, Schneider RK. Arthrodesis techniques in horses. *Vet Clin North Am Equine Pract* 2005;21:691-711.
- [15] Adams P, Honnas CM, Ford TS, Watkins JP. Arthrodesis of a subluxated proximal interphalangeal joint in a horse. *Equine Pract* 1995;17:26-31.
- [16] Angeli AL, Nicoletti JLM. Comparação entre dois métodos de artrodese interfalangeana proximal em equinos. *Arch Vet Sci* 2008;13:31-9.
- [17] Jones P, Delco M, Beard W, Lillich JD, Desormaux A. A limited surgical approach for pastern arthrodesis in horses with severe osteoarthritis. *Vet Comp Orthop Traumatol* 2009;22:303-8.
- [18] Nicoletti JLM, Alves ALG, Hussni CA, Thomassian A. Tenectomia da cabeça medial do flexor digital profundo em equinos. *Veterinária e Zootecnia* 2006;13:169-72.
- [19] Craig JJ, Craig MF, Weltner TN. Quantifying conformation of the equine digit from lateromedial radiographs. *Proceedings of the 21st Annual Convention of Association for Equine Sports Medicine Meeting*. Sacramento, CA: Association for Equine Sports Medicine; 2001. p. 1–9.
- [20] Bushe T, Turnert A, Poulos PW, Harwell NM. The effect of hoof angle on coffin, pastern and fetlock joint angles. *Proceedings of 33rd Annual Convention of American Association of Equine Practitioners*. New Orleans, LA: American Association of Equine Practitioners; 1987. p. 729–38.
- [21] Hussni CA. Efeitos da tenotomia do tendão flexor digital superficial e da desmotomia do acessório sobre os ângulos articulares e sobre os cascos dos equinos. Botucatu: Universidade Estadual Paulista Júlio de Mesquita Filho; 2002.
- [22] Hussni CA. Tenotomia do músculo flexor digital profundo proximal à inserção do ligamento acessório: Proposta de uma nova técnica cirúrgica em equinos e seus efeitos sobre os ângulos das articulações metacarpofalangeana e interfalangeana. [Dissertação]. Botucatu: Universidade Estadual Paulista; 1991.
- [23] Hussni CA, Nicoletti JLM, Thomassian A, Gandolfi W, Luna SPL, Vulcano LC, et al. Variações dos ângulos das articulações metacarpofalangeanas e interfalângicas frente a duas técnicas de tenotomia do flexor digital profundo em equinos. *Veterinária e Zootecnia* 1996;8:27-34.
- [24] Bushe T, Turner TA, Poulos PW, Harwell NM. The effect of hoof angle on coffin, pastern and fetlock joint angles. In: XXXX, editor. *Proceedings of 33rd Annual Convention of American Association of Equine Practitioners*. New Orleans, LA: American Association of Equine Practitioners; 1987. p. 729-38.
- [25] Alexander GR, Gibson KT, Day RE, Robertson ID. Effects of superior check desmotomy on flexor tendon and suspensory ligament strain in equine cadaver limbs. *Vet Surg* 2001;30:522-7.
- [26] Kolb B. *Fisiologia Veterinária*. Rio de Janeiro: Guanabara Koogan; 1984.