

## Spermatogenic Cycle Length and Spermatogenic Efficiency in the Gerbil (*Meriones unguiculatus*)

TÂNIA M. SEGATELLI,\* LUIZ R. FRANÇA,† PATRICIA F. F. PINHEIRO,‡ CAMILA C. D. ALMEIDA,‡ MARCELO MARTINEZ,§ AND FRANCISCO E. MARTINEZ‡

From the \*Department of Morphofysiological Science, DCM-Bloco H-79, University of State of Paraná (UEM), Paraná, Brazil; †Laboratory of Cellular Biology, Department of Morphology, Institute of Biological Science, Federal University of Minas Gerais, Belo Horizonte, MG, Brazil; ‡Department of Anatomy, Institute of Bioscience, State University of São Paulo, Botucatu, SP, Brazil; §Department of Morphology and Pathology, Laboratory of Anatomy, UFSCAR, São Carlos, SP, Brazil.

**ABSTRACT:** The gerbil (*Meriones unguiculatus*) is a rodent native of the arid regions of Mongolia and China. Because the gerbil can be easily bred in laboratory conditions, this species has been largely used as an experimental model in biomedical research. However, there is still little information concerning the testis structure and function in the gerbil. In this regard, we performed a detailed morphofunctional analysis of the gerbil testis and estimated the spermatogenic cycle length utilizing  $^3\text{H}$ -thymidine as a marker for germ cell progression during their evolution through the spermatogenic process. The stage frequencies of the XII stages characterized according to the acrosome formation and development were (I–XII) 13.8, 10.1, 8.1, 7.8, 4.0, 11.2, 7.5, 7.1, 5.9, 7.6, 8.1, and 8.9. The mean duration of each seminiferous epithelium cycle was determined to be  $10.6 \pm 1.0$  days and the total duration of spermatogenesis, based on 4.5 cycles, was approximately 47.5 days. The volume density of tubular and interstitial compartments was approximately 92% and 8%, respectively. Based on the volume occupied by seminiferous tubules in the testis and the tubular diameter, about 9 and 18 m of

seminiferous tubules were found per testis and per gram of testis, respectively. Twelve primary spermatocytes were formed from each type A1 spermatogonia. The meiotic index was 2.8, indicating that 30% of cell loss occurs during meiosis. The number of Leydig and Sertoli cells per gram of the testis was 28 million and each Sertoli cell was able to support approximately 13 spermatids. The daily sperm production per gram of testis (spermatogenic efficiency) was 33 million. Taken together, these data indicate that, mainly due to the high seminiferous tubule volume density and Sertoli cell support capacity for germ cells, the gerbil presents high spermatogenic efficiency compared with other mammalian species already investigated. The data obtained in the present study might provide the basis for future research involving the reproductive biology in this species.

Key words: Testis, spermatogenesis, morphometry, sperm production.

J Androl 2004;25:872–880

The spermatogenic process during the breeding season in sexually mature mammals is a cyclic, highly organized and coordinated event in which spermatogonia differentiate into mature spermatozoa (Russell et al, 1990a). The complexity of this process necessitates a tight and well-balanced regulatory mechanism evidenced by the precise duration of spermatogenesis and the presence of defined germ cell associations. These germ cell associations are referred to as stages of spermatogenesis, and they vary in number and duration in a species-specific manner (Weinbauer et al, 2001). The sequence of events that occurs from the disappearance of a given cellular association to its reappearance in a given area of the sem-

iniferous epithelium constitutes the seminiferous epithelium cycle (Leblond and Clermont, 1952). The time interval required for 1 complete series of cellular associations to appear at one point within the tubule is called duration of the seminiferous epithelium cycle. The total duration of spermatogenesis, which takes approximately 4.5 cycles, lasts from 30 to 75 days in mammals (Russell et al, 1990a; França and Russell, 1998). Although strain or breed differences can be found in the literature among members of the same species (Russell et al, 1990a), the duration of the spermatogenic cycle has been generally considered to be constant for a given species. A recent study utilizing xenogenic spermatogonial transplantation has demonstrated that the spermatogenic cycle duration is under the control of the germ cell genotype (França et al, 1998).

Estimates for the duration of the seminiferous epithelium cycle have been obtained utilizing several methods (Roosen-Runge, 1951; Clermont and Perey, 1957; Clermont and Antar, 1973; Rosiepen et al, 1994; Dolbeare,

Supported by FAPESP (grants 99/11839-2).

Correspondence to: Tânia Mara Segatelli, Department of Morphofysiological Science, DCM-Bloco H-79, University of State of Paraná (UEM), Av Colombo, 5790, Maringá, Paraná, Brazil (e-mail: tmsegatelli@uem.br).

Received for publication May 13, 2004; accepted for publication June 20, 2004.

1995; Smithwick et al, 1996a,b; Rosiepen et al, 1997; Weinbauer et al, 1998; França et al, 1999). However, tritiated thymidine, a very specific precursor for DNA, is classically utilized as a germ cell marker in order to determine the duration of spermatogenesis (Swierstra and Foote, 1965; Swierstra, 1968; Barr, 1973; Neves et al, 2002; França and Godinho, 2003).

Accurate morphometric information can provide answers to important questions about the spermatogenic process and also is valuable for correlations with physiological and biochemical findings (Wing and Christensen, 1982; Gaytan et al, 1986; França and Russell, 1998). There are numerous quantitative studies in the literature related to germ, Sertoli, and Leydig cells in mammals, and most quantitative investigations of spermatogenesis require identification of the stages of the seminiferous epithelium cycle and the knowledge of its duration (Berndtson, 1977; França and Russell, 1998; França and Godinho, 2003). Also, because each Sertoli cell is able to support only a limited number of germ cells, in a species-specific manner, the number of Sertoli cells that are established before puberty in mammals and Sertoli cell efficiency are the best indicators of spermatogenic efficiency (daily sperm production per gram of testis) (Hess et al, 1993; Johnson, 1995; França and Russell, 1998).

The gerbil (*Meriones unguiculatus*) is a native rodent in the arid regions of Mongolia and China and represents an interesting experimental model in biomedical research, being easily bred in laboratory conditions. Although there are some reports in the literature regarding the descriptions of the testicular postnatal development and benign testicular hyperplasia (Ninomiya and Nakamura, 1987a,b) and ultrastructural investigation of acrosome formation and development during spermatogenesis (Segatelli et al, 2000, 2002), little is known about the reproductive biology in male gerbils (Schwentker, 1963; Rich, 1968; Williams, 1974). The objectives of the present study were to perform a detailed quantitative investigation of the testis and to determine the duration of spermatogenesis and the spermatogenic efficiency in the gerbil.

## Materials and Methods

### Animals

Sixteen adult male gerbils (*M. unguiculatus*), aged 3 months and weighing 65–80 g were used. These animals were divided into 2 groups utilized to estimate the duration of the seminiferous epithelium cycle ( $n = 8$ ) and to perform the morphometric analysis of the testis ( $n = 8$ ). The animals were kept under controlled temperature (23°C) and controlled lighting conditions (12:12 hours light:dark photoperiod). The experimental protocol followed the ethical principles in animal research adopted by the Brazilian College of Animal Experimentation.

### Thymidine Injections and Tissue Preparation

To estimate the duration of spermatogenesis, the animals received intraperitoneal injections of tritiated thymidine (thymidine [methyl- $^3\text{H}$ ], specific activity 82.0 Ci/mmol; Amersham, Life Science, England). The injections of 100  $\mu\text{Ci}$  of  $^3\text{H}$ -thymidine were performed using a hypodermic needle. Two animals were utilized for each time interval considered (approximately 1 hour, 7, 14, and 21 days) after thymidine injections. Before sacrifice, the animals were anesthetized with ether and perfused-fixed with Karnovsky fluid (Sprando, 1990). Histoiresin-embedded testis fragments were sectioned at 3- $\mu\text{m}$  thickness and placed on glass slides. To perform autoradiographic analysis, the histological slides were dipped in autoradiography emulsion (Kodak NTB-2, Eastman Kodak Company, NY) at 45°C. After drying for approximately 1 hour at 25°C, sections were placed in sealed black boxes containing silica gel as a drying agent and stored in a refrigerator at 4°C for approximately 30 days. Subsequently, testis sections were developed in Kodak D-19 solution at 15°C according to Bundy (1995) and stained with toluidine blue. Analyses of these sections were performed by light microscopy. Cells were considered labeled when 4–5 or more grains were present over the nucleus in the presence of low-to-moderate background (Neves et al, 2002; França and Godinho, 2003).

### Stages Characterization and Relative Frequency

Stages of seminiferous epithelium cycle were characterized based on the development of the acrosomic system and morphology of the developing spermatid nucleus. This method provides 12 stages of the seminiferous epithelium cycle and both stage characterization and relative frequencies were described previously for the gerbil by Segatelli et al (2000; 2002). The relative stage frequencies were determined according to Hess et al (1990), utilizing the analysis of 200 seminiferous tubule cross-sections in 12 animals, at 400 $\times$  magnification. The duration of the seminiferous epithelium cycle was estimated based on the stage frequencies and considering the most advanced germ cell type labeled at each time period investigated after thymidine injection.

### Morphometric Analysis of the Testis

The 8 animals utilized in this part of the study were also anesthetized with ether and perfused-fixed with Karnovsky fluid (Sprando, 1990). After this procedure, testes were trimmed out from the epididymis and weighed, and the percentage occupied by the tunica albuginea was determined. Because the testis mediastinum in the gerbil is very small, its percentage was not determined in the present study. Testis samples were embedded in Histoiresin<sup>®</sup>, sectioned at 4- $\mu\text{m}$  thickness, placed on glass slides, and stained with toluidine blue and Schiff-hematoxylin periodic acid. The tubular diameter of the seminiferous tubule and the height of the seminiferous epithelium were measured at 100 $\times$  magnification using an ocular micrometer calibrated with a stage micrometer. Thirty tubular profiles that were round or nearly round were chosen randomly and measured for each animal. The epithelium height was obtained in the same tubule sections utilized to determine tubular diameter. The volume densities of various testicular components were determined by light

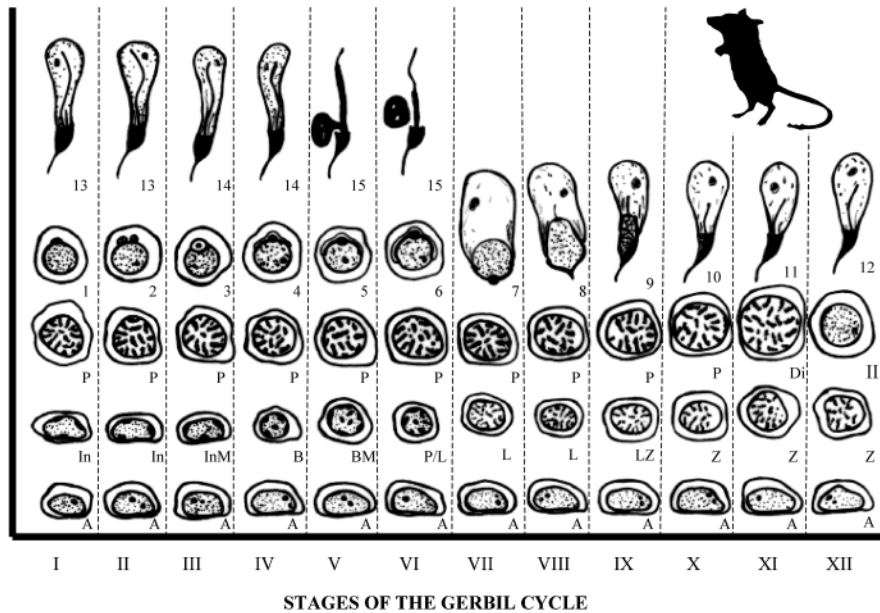


Figure 1. This diagrammatic figure illustrates the XII different stages of the seminiferous epithelium cycle characterized in the gerbil. The vertical columns, designated by roman numerals, depict the cell associations. The developmental progression of a cell is followed horizontally until the right-hand border of the diagram is reached. The cell progression continues at the left of the diagram 1 row up. The cycle diagram ends with the completion of spermiation. The symbols used designate specific germ cell types: Type A (A), intermediate (In), and Type B (B) spermatogonia, mitotic divisions (InM and BM); preleptotene (Pl), leptotene (L), zygotene (Z), pachytene (P), and diplotene (Di) primary spermatocyte, and secondary spermatocyte (II). The Arabic numbers designate the steps of the spermiogenic phase (Segatelli et al, 2000).

microscopy using a 441-intersection grid placed in the ocular of the light microscope. Twenty fields chosen randomly (8820 points) were scored for each animal at 400 $\times$  magnification. Points were classified as one of the following: seminiferous tubule (comprising tunica propria, epithelium, and lumen), Leydig cell, blood and lymphatic vessels, connective tissue, and others (including fibers and cells of connective tissue). The volume of each component of the testis was determined as the product of the volume density and testis volume. To obtain a more precise measure of the testis parenchyma volume, 3.15% of testicular capsule was excluded from testis weight. The total length of seminiferous tubule per testis and per gram of testis, expressed in meters, was obtained by dividing the seminiferous tubule volume by the squared radius of the tubule times the pi value ( $\pi R^2$ ) (Johnson and Neaves, 1981; Frana and Godinho, 2003)

### Cell Counts and Cell Numbers

All germ cell nuclei and Sertoli cell nucleoli present at stage VII of the seminiferous epithelium cycle (SEC) were counted in 10 round or nearly-round seminiferous tubule cross-sections, chosen at random, for each animal. These counts were corrected for section thickness and nucleus or nucleolus diameter according to Abercrombie (1946), modified by Amann (1962). The following germ cells were counted: type A1 spermatogonia, leptotene primary spermatocytes, pachytene primary spermatocytes, and round spermatids. The following ratios were obtained from the corrected counts:

- pachytene spermatocytes/type A1 spermatogonia, to estimate the coefficient of efficiency of spermatogonial mitosis;
- round spermatids/type A1 spermatogonia, to obtain the overall rate of spermatogenesis;

- round spermatids/pachytene spermatocytes, to obtain the rate of germ cell loss during meiosis (meiotic index);
- round spermatids/Sertoli cell nucleoli, to estimate the Sertoli cell efficiency;
- total number of germ cells/Sertoli cell nucleoli, to obtain the total support capacity of each Sertoli cell.

The total number of Sertoli cells was determined from the corrected counts of Sertoli cell nucleoli per seminiferous tubule cross-section and the total length of seminiferous tubules according to the method described by Hochereau-de Riviers and Lincoln (1978). The daily sperm production (DSP) per testis and per gram of testis were obtained according to the following formula developed by Frana (1992): DSP = (total number of Sertoli cells per testis)  $\times$  (the ratio of round spermatids to Sertoli cells at stage VII)  $\times$  (stage VII relative frequency [%])/(stage VII duration [days]).

The individual volume of Leydig cell was obtained from the nucleus volume and the proportion between nucleus and cytoplasm. Thirty spherical Leydig cell nuclei showing evident nucleolus were measured for each animal. Leydig cell nuclear volume obtained by the formula  $(4/3)\pi R^3$  ( $R$  = nuclear diameter/2) was expressed in  $\mu\text{m}^3$ . To calculate the proportion between nucleus and cytoplasm, a 441-point square lattice was placed over the sectioned material at 400 $\times$  magnification. One thousand points over Leydig cells were counted for each animal. The number of Leydig cells per testis and per gram of testis were estimated from the Leydig cell individual volume and the volume occupied by Leydig cells in the testis parenchyma.

### Statistical Analysis

All data are presented as the mean  $\pm$  SEM, and these data were analyzed by descriptive statistic.

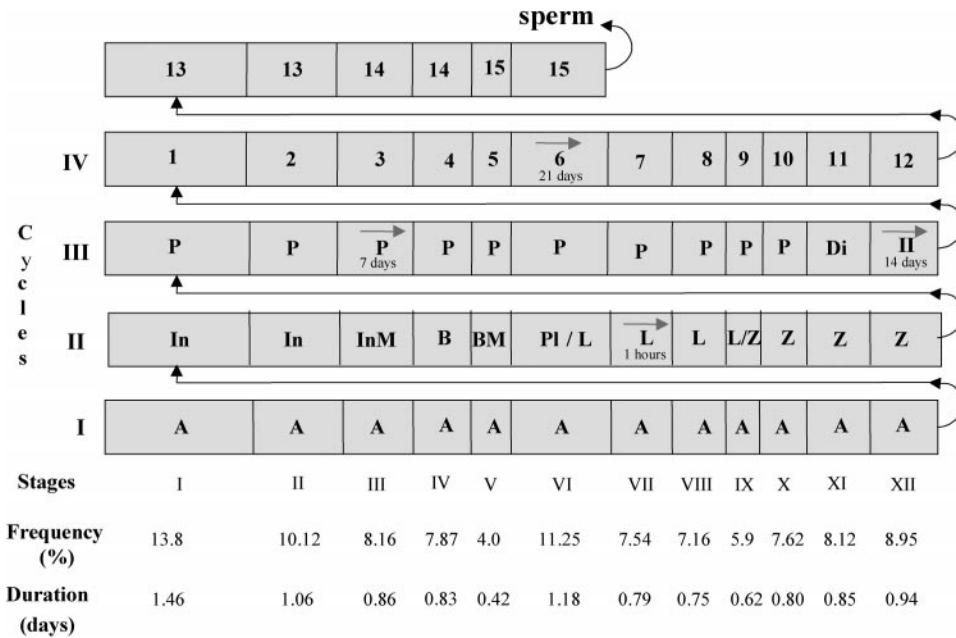


Figure 2. Diagram showing the germ cell composition, the frequencies (%), and the duration in days for each stage of the seminiferous epithelium cycle. Also depicted is the most advanced germ cell type labeled at the 12 stages of the cycle at different time periods (approximately 1 hour, 7, 14, and 21 days) following <sup>3</sup>H-thymidine injections (arrows). The roman vertical numbers indicate the spermatogenic cycles and the horizontal roman numbers the stages of cycle with their relative frequencies (%) and durations (days). The space given to each stage is proportional to its frequency and duration. The letters within each column indicate the germ cell types present at each stage of the cycle. Type A (A), intermediate (In), and Type B (B), spermatogonia, mitotic divisions (InM) and (BM), preleptotene (Pl), leptotene (L), zygotene (Z), pachytene (P), and diplotene (Di) spermatocytes; secondary spermatocytes (II); round (1–6) and elongating/elongated (7–15) spermatids.

**Results**

*Stages of the Seminiferous Epithelium Cycle and Relative Stage Frequencies*

The composition of the XII stages characterized in the gerbil (Segatelli et al, 2000, 2002) and the relative frequency of these stages are shown in Figures 1 and 2. Stage I (13.8%) and stage V (4%) showed the highest and lowest frequencies, respectively, whereas the frequency of meiotic stage (XII) was almost 9%. The frequencies of premeiotic (stages VII–XI) and postmeiotic (I–VI) stages were 55.2% and 36.3%, respectively.

*Duration of Spermatogenesis*

The most advanced labeled germ cell type present at several times after the <sup>3</sup>H-thymidine injections (approximate-

ly 1 hour, 7, 14, and 21 days) are shown in Table 1 and Figure 2. Approximately 1 hour after injection, the most advanced labeled germ cell type observed was leptotene primary spermatocytes present at stage VII (Figure 3a). However, it should be stated that all XII stages characterized presented labeled germ cell nuclei near the basal lamina; these nuclei had the morphological characteristics of type A, intermediate, and type B spermatogonia. The most advanced labeled cells found 7 days after injection were pachytene spermatocytes, observed at stage III (Figure 3b). Meiotic figures from the first meiotic divisions and located at the middle of stage XII were observed as the most advanced labeled germ cell 14 days after injection (Figure 3c), whereas 21 days after injection, round spermatids present at stage VI were the most advanced cell labeled (Figure 3d). Based on these labeling patterns

Table 1. The length (days) of seminiferous epithelium cycle ( $\bar{x} \pm SEM$ )

Time After Injection	Most Advanced Germ Cell Type Labeled	Stage of the Cycle	Number of Cycles Traversed	Cycle Length Based on Labeling in Leptotene	Cycle Length Based on Intermediate Labeling Point
89 min	Leptotene	VII	...	...	...
6.96 d*	Pachytene	III	0.77	9.00	10.96
13.98 d*	Meiotic figures	XII	1.41	9.89	11.33
20.98 d*	Round spermatid	VI	2.01	10.43	11.72
Mean†				9.77	11.33

\* Total time after thymidine injection minus 89 minutes.

† Mean duration of the cycle based on labeling in leptotene and on intermediated labeling points.  $\bar{x} = 10.55 \pm 1.0$  d.



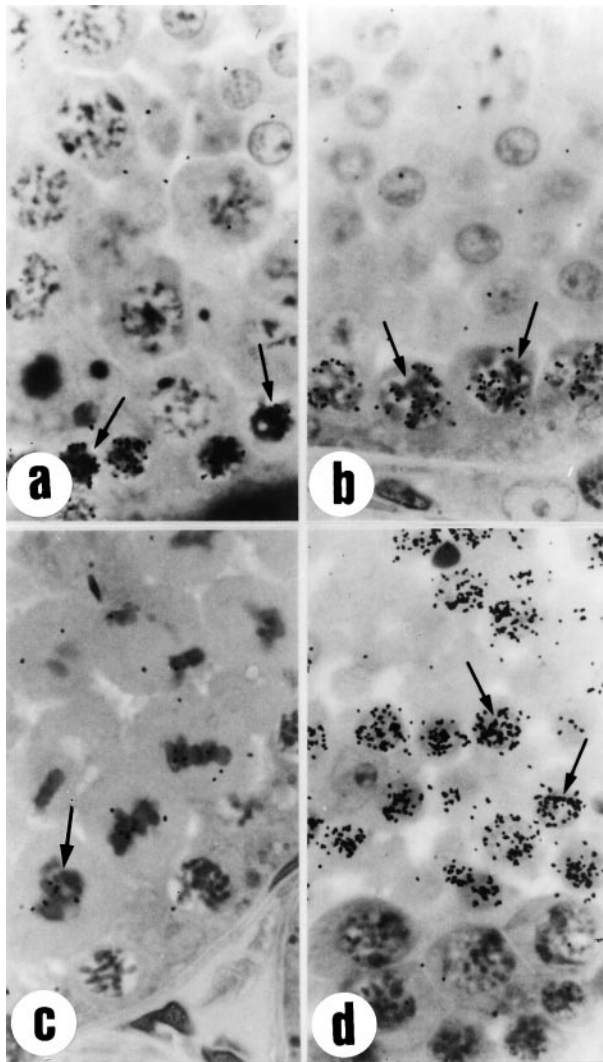


Figure 3. Most advanced labeled germ cell type observed after different time periods following  $^3\text{H}$ -thymidine injections. (a) Approximately 1 hour after injection, leptotene primary spermatocytes (arrows) at stage VII. (b) Seven days after injection, pachytene spermatocytes (arrows), observed at stage III. (c) Fourteen days after injection, meiotic figures from the first meiotic divisions present at the middle of stage XII (arrow). (d) Twenty-one days after injection, round spermatids (arrows), at stage VI. 1000 $\times$  magnification, toluidine blue.

and the stage frequencies, the mean duration of the seminiferous epithelium cycle was estimated to be  $10.55 \pm 1.0$  days. As can be observed in Table 1 and Figure 2, this value was obtained based on labeling of leptotene spermatocytes and intermediate labeling points for the various time intervals considered. The duration of each stage of the seminiferous epithelium cycle was determined taking into account the cycle duration and the percentage of occurrence of each stage (Figure 2). Thus, stage I was the longest stage (1.46 days), whereas the shortest was stage V (0.42 days). Considering that approximately 4.5 cycles are necessary for the spermatogenesis process to be completed, the total duration of

Table 2. Morphometric data ( $\bar{x} \pm \text{SEM}$ ) in gerbil

Parameters	$\bar{x} \pm \text{SEM}$
Body weight (g)	$77 \pm 3$
Testicular weight (g)	$0.54 \pm 0.03$
Right testis	$0.54 \pm 0.03$
Left testis	$0.53 \pm 0.03$
Gonadosomatic index (%)	$0.72 \pm 0.04$
Testis parenchyma volume density (%)	
Seminiferous tubule	$92.2 \pm 2.3$
Tunica propria	$1.5 \pm 0.5$
Seminiferous epithelium	$85 \pm 2.2$
Lumen	$5.6 \pm 0.8$
Interstitial compartment	$7.8 \pm 2.3$
Leydig cell	$3.0 \pm 0.9$
Macrophages	$0.3 \pm 0.1$
Blood vessels	$2.5 \pm 0.3$
Lymphatic vessels	$1.6 \pm 1.3$
Others	$0.3 \pm 0.2$
Tubular diameter ( $\mu\text{m}$ )	$253 \pm 8$
Seminiferous epithelium height ( $\mu\text{m}$ )	$100 \pm 1$
Total tubular length per testis (m)	$10 \pm 0.9$
Tubular length per gram of testis (m)	$18 \pm 1.3$

spermatogenesis in the gerbil was estimated as being 47.47 days.

#### Morphometry of the Testis

The mean testis weight found for the gerbil was approximately 0.54 g, providing a gonadosomatic index (testes mass divided by body weight) of approximately 0.72% (Table 2). The volume density of tubular and interstitial compartments was approximately 92% and 8%, respectively, and Leydig cells occupied 3% of the testis parenchyma or almost 40% of the interstitial space (Table 2). The mean tubular diameter and epithelium height were 253 and 100  $\mu\text{m}$ , respectively. Based on the volume of the testis parenchyma (testis weight minus tunica albuginea weight) and the volume occupied by the seminiferous tubules in the testis and the tubular diameter, approximately 10 and 18 m of seminiferous tubules were found, respectively, per testis and per testis gram (Table 2). Table 3 shows the corrected number of germ cells and Sertoli cell nucleoli found per seminiferous tubule cross-section at stage VII of the seminiferous epithelium cycle, whereas the cell ratios obtained from these corrected counts are shown in Table 4. Approximately 12 pachytene primary spermatocytes and 34 round spermatids were found per each type A1 spermatogonia. The meiotic index, measured as the number of round spermatids produced per pachytene spermatocytes, was 2.8, indicating that 30% of cell loss occurs during meiosis. The Sertoli cell efficiency at stage VII, estimated from the total number of germ cells and the number of round spermatids per Sertoli cell was 21 and 12.6, respectively (Table 4). The

Table 3. Corrected numbers of germ cells and Sertoli cells nucleoli per cross-section of seminiferous tubules at stage VII

Cell Types	$\bar{x} \pm \text{SEM}$
Type A spermatogonia	2.4 $\pm$ 0.4
Pachytene primary spermatocytes	27 $\pm$ 3
Round spermatids	78 $\pm$ 8
Total of germ cells	130 $\pm$ 11
Sertoli cells nucleoli	6.3 $\pm$ 0.8

total number of Sertoli cells per testis was 15 million, whereas the daily sperm production per testis and per gram of testis (spermatogenic efficiency) was 18 and 33 million, respectively (Table 5). Leydig cell and nuclear volumes were approximately 328 and 1148  $\mu\text{m}^3$ , respectively. Coincidentally, the values found for the number of Leydig cell per testis and per gram of testis was strikingly similar to those found for Sertoli cells (Table 6).

## Discussion

The present study is the first to estimate the duration of spermatogenesis and to perform a detailed morphometric evaluation of the testis structure in the gerbil. The literature suggests that stage frequencies grouped in premeiotic and postmeiotic phases of spermatogenesis might be phylogenetically determined among members of the same mammalian family (França and Russell, 1998; França et al, 1999; Neves et al, 2002). In this aspect, 2 patterns are readily observed for rodents: species in which the premeiotic stage frequencies are situated from approximately 20% to approximately 35% of the entire cycle and species that present a relative equilibrium between pre- and postmeiotic-stage frequencies (Paula et al, 1999). The data found for the gerbil indicates that this species belongs to the first pattern.

In mammals, the duration of spermatogenesis is considered to be species specific and, although strain or breed differences can be found among members of the same species (Russell et al, 1990a), apparently the spermatogenic cycle length cannot be altered by any natural factor or experimental manipulation (Clermont, 1972; Berndtson and Desjardins, 1974; Amann and Schanbacher, 1983). In approximately half of the mammalian species already in-

Table 4. Cell ratios from the corrected counts obtained at stage VII

Cell Types	Ratios
Pachytene spermatocytes:type A spermatogonia	12 $\pm$ 2:1
Round spermatids:type A spermatogonia	34 $\pm$ 6:1
Round spermatids:pachytene spermatocytes	2.8 $\pm$ 0.1:1
Round spermatids:Sertoli cell nucleoli	12.6 $\pm$ 1.7:1
Total number of germ cells:Sertoli cell nucleoli	21 $\pm$ 2.8:1

Table 5. Sertoli cell number and daily sperm production (DSP) per testis and per gram of testis (million)

Parameters	$\bar{x} \pm \text{SEM}$
Sertoli cell number per gram of testis	28 $\pm$ 4
Sertoli cell number per testis	15 $\pm$ 2
DSP per gram of testis	33 $\pm$ 5
DSP per testis	18 $\pm$ 3

vestigated, the duration of each spermatogenic cycle is situated in an interval of 9–12 days. In this way, the cycle length found for the gerbil is situated exactly in the middle of this predominant range. The same trend is observed when the gerbil is compared with other rodent species investigated. In these species, the duration of each spermatogenic cycle varies from 6.7 days for bank vole (Grocock and Clarke, 1976) to 17 days for the Chinese hamster (Oud and de Rooij, 1977). Although the duration of spermatogenesis is not necessarily the same for species closely related (Russell et al, 1990a; França and Russell, 1998; Paula et al, 1999), it is considered that the cycle duration is not phylogenetically determined in mammals (Neves et al, 2002). However, recent work has shown that this very important aspect of spermatogenesis is controlled by the germ cell genotype (França et al, 1998).

Compared with most mammalian species already investigated (Kenagy and Trombulak, 1986), the gonadosomatic index in the gerbil is high and similar to other laboratory rodent species investigated, such as rats and mice. Also, considering the values found for the seminiferous tubule compartment in most mammalian species (~70% to ~90%) (Russell et al, 1990b; França and Russell, 1998), the volume density observed for this parameter is very high in the gerbil. However, the opposite is observed for Leydig cells (França and Russell, 1998; França and Godinho, 2003), the percentage of which is similar to that found for rats (Russell and França, 1995; Rocha et al, 1999). The length of seminiferous tubules per gram of testis is related to the tubular diameter and the seminiferous tubule volume. In general, there are 10–15 m of tubules per gram of testis in mammals (Wing and Christensen, 1982; Neaves and Johnson, 1985; Sinha-Hikim et al, 1988; França and Russell, 1998; França and Godinho, 2003). Due to the high seminiferous tubule occupancy and the fact that mean value found for the tubular

Table 6. Leydig cell morphometry

Parameter	$\bar{x} \pm \text{SEM}$
Nuclear diameter ( $\mu\text{m}$ )	8.5 $\pm$ 0.6
Leydig cell volume ( $\mu\text{m}^3$ )	1148 $\pm$ 266
Nuclear volume ( $\mu\text{m}^3$ )	328 $\pm$ 67
Cytoplasm volume ( $\mu\text{m}^3$ )	820 $\pm$ 202
Leydig cell number per gram of testis ( $\times 10^6$ )	28 $\pm$ 8
Leydig cell number per testis ( $\times 10^6$ )	15 $\pm$ 4

diameter in the gerbil is situated around the mean range observed for mammals (Roosen-Runge, 1977; Setchell et al, 1994; França and Russell, 1998), approximately 18 m of tubules per gram of testis parenchyma was found in this species.

Germ cell loss (apoptosis) plays an important role in the seminiferous epithelium homeostasis by limiting the number of sperm produced. This occurs mainly during meiosis, through the elimination of germ cells that are defective or carry DNA mutations, and during the spermatogonial phase in a process named cell-density regulation (Roosen-Runge, 1973; Huckins, 1978; Sinha-Hikim et al, 1985; de Rooij and Lok, 1987; França and Russell, 1998; de Rooij and Russell, 2000; Young and Nelson, 2001; Weinbauer et al, 2001). Overall, germ cell apoptosis results in the loss of up to 75% of the potential number of mature spermatozoa that can be produced by one differentiated type A1 spermatogonia (de Rooij and Lok, 1987; Bartke, 1995; Johnson, 1995; França and Russell, 1998; Lee et al, 1997, 1999; Sinha-Hikim and Swerdloff, 1999; de Rooij and Russell, 2000).

Germ cell loss can be estimated comparing the ratios between germ cells counted during specific steps of spermatogenesis (Johnson, 1991). We did not perform an investigation specifically related to the kinetics of spermatogonia in the gerbil. However, the results found for the ratio of primary spermatocytes to type A spermatogonia, investigated at stage VII, suggest that at least 5 generations of differentiated spermatogonia are present in this species. The ratio of spermatids to primary spermatocytes show that 30% of germ cell loss occurred in the gerbil during meiosis. This value is similar to that observed for most mammalian species investigated (Roosen-Runge, 1973; França and Russell, 1998). Also, assuming that 5 generations of differentiated spermatogonia are present in the gerbil, the ratio of round spermatids to type A1 spermatogonia observed in this species indicate that 75% of germ cell loss took place during spermatogenesis.

The Sertoli cell number established during the prepubertal period in mammals determines the final testicular size and the number of sperm produced in sexually mature animals (Orth et al, 1988; Hess et al, 1993). This occurs because each Sertoli cell can support only a limited number of germ cells, with this support capacity being both variable and species-specific (Berndtson and Desjardins, 1974; Russell and Peterson, 1984; França and Russell, 1998). Approximately 28 million Sertoli cells were found per testis gram in the gerbil. This value is situated in the range (20–40 million) observed for most mammalian species studied up to date (Russell et al, 1990b; França and Russell, 1998). Because the number of Sertoli cells is stable in the adult animal and throughout the different stages of the cycle, these cells are used

as a reference point to quantify and functionally evaluate the spermatogenic process (França and Russell, 1998; França and Godinho, 2003). The noticeable flexibility among species in the number of spermatids supported by a single Sertoli cell shows that, in general, species in which the ratio of spermatids to Sertoli cells is higher also have higher spermatogenic efficiency (daily sperm production per gram of testis) (Russell and Peterson, 1984; Sharpe, 1994; França and Russell, 1998). According to Russell and Peterson (1984), the ability to accommodate more germ cells may be dependent on the size of the Sertoli cells and also to a certain degree on the size and/or shape of the elongated spermatids. In the gerbil, almost 13 spermatids were found for each Sertoli cell. Compared with other mammalian species and even to other rodent species, this ratio is relatively high (Wing and Christensen, 1982; Russell and Peterson, 1984; Sharpe, 1994; França and Russell, 1998; Rocha et al, 1999).

Very little is known about the mechanisms responsible for the regulation of the Leydig cell size and the number of Leydig cells per testis and a dramatic variation in these parameters, and for the organization of these cells in the interstitial compartment, is found in the literature for different mammalian species (Fawcett et al, 1973; Russell, 1996; França and Russell, 1998; França et al, 2000). However, it is already established that Leydig cell volume and Leydig cell capacity to secrete testosterone is positively correlated with the quantity of smooth endoplasmic reticulum (Ewing et al, 1979; Zirkin et al, 1980). A cross-talk between the seminiferous epithelium and the Leydig cells is strongly suggested in the literature (Habert et al, 2001; Russell et al, 2001; Neves et al, 2002). As found for some species investigated during sexual maturity (Neves et al, 2002; França and Godinho, 2003) and around the pubertal period (França et al, 2000), perhaps it might be more than a coincidence that the number of Leydig and Sertoli cells per testis are strikingly similar in the gerbils investigated in the present study.

Several parameters, such as the number of germ cells supported by each Sertoli cell, the volume density of seminiferous tubules, the number of spermatogonial generations, the number of Sertoli cells per gram of testis, are positively correlated with the spermatogenic efficiency (Russell and Peterson, 1984; França and Russell, 1998; Johnson et al, 2000). On the other hand, this parameter shows a negative correlation with the volume density of Sertoli cells in the seminiferous epithelium and the length of spermatogenic cycle. It means that species showing long cycle length and, paradoxically, bigger Sertoli cells are those with lower spermatogenic efficiency (Russell et al, 1990b). Therefore, probably because the volume density of the seminiferous epithelium and the support capacity (efficiency) of Sertoli cells are very high in the gerbil, this species presents high spermatogenic efficiency



compared with other mammalian species, including rodents, already investigated (Russell and Peterson, 1984; Russell et al, 1990b; França and Russell, 1998; Johnson et al, 2000).

In summary, in the present investigation, we obtained several fundamental basic data regarding the testis structure and function in the gerbil. These data might provide the basis for future research involving the reproductive biology in this species that is an important experimental model in biomedical research.

## References

- Abercrombie M. Estimation of nuclear population from microtome sections. *Anat Rec*. 1946;94:238–248.
- Amann RP. Reproductive capacity of dairy bulls. III. The effect of ejaculation frequency, unilateral vasectomy, and age on spermatogenesis. *Am J Anat*. 1962;110:49–67.
- Amann RP, Schanbacher BD. Physiology of male reproduction. *J Anim Sci*. 1983;57:380–403.
- Barr AB. Timing of spermatogenesis in four nonhuman primate species. *Fertil Steril*. 1973;24:381–389.
- Bartke A. Apoptosis of male germ cells, a generalized or a cell type-specific phenomenon? *Endocrinology*. 1995;136:3–4.
- Berndtson WE. Methods for quantifying mammalian spermatogenesis: a review. *J Anim Sci*. 1977;44:818–833.
- Berndtson WE, Desjardins C. The cycle of the seminiferous epithelium and spermatogenesis in the bovine testis. *Am J Anat*. 1974;140:167–179.
- Bundy DC. Photographic emulsions and processing. In: Stumpf WE, Solomon HF, eds. *Autoradiography and Correlative Imaging*. San Diego: Academic Press; 1995:49–57.
- Clermont Y. Kinetics of spermatogenesis in mammals seminiferous epithelium cycle and spermatogonial renewal. *Physiol Rev*. 1972;52:198–236.
- Clermont Y, Antar M. Duration of the cycle of the seminiferous epithelium and the spermatogonial renewal in the monkey *Macaca arctoides*. *Am J Anat*. 1973;136:153–166.
- Clermont Y, Pery B. The stages of the cycle of the seminiferous epithelium of the rat: practical definitions in PAS-hematoxylin and hematoxylin-eosin stained sections. *Rev Can Biol*. 1957;16:451–462.
- de Rooij DG, Lok D. Regulation of the density of spermatogonia in the seminiferous epithelium of the Chinese hamster: II. Differentiating spermatogonia. *Anat Rec*. 1987;217:131–136.
- de Rooij DG, Russell LD. All you wanted to know about spermatogonia but were afraid to ask. *J Androl*. 2000;21:776–798.
- Dolbeare F. Bromodeoxyuridine: a diagnostic tool in biology and medicine, Part I: historical perspectives, histochemical methods and cell kinetics. *Histochem J*. 1995;27:339–369.
- Ewing LL, Zirkin BR, Cochran RC, Kromann N, Peters C, Ruiz-Bravo N. Testosterone secretion by rat, rabbit, guinea pig, dog, and hamster testes perfused in vitro: correlation with Leydig cell mass. *Endocrinology*. 1979;105:1135–1142.
- Fawcett DW, Neaves WB, Flores MN. Comparative observations on intertubular lymphatic and the organization of the interstitial tissue of the mammalian testis. *Biol Reprod*. 1973;9:500–532.
- França LR. Daily sperm production in piau boar estimated from Sertoli population and Sertoli cell index. In: *Proceedings of the 12th International Congress on Animal Reproduction (ICAR)*, Vol 4—Free Communications. The Hague, The Netherlands. 1992:1716–1718.
- França LR, Becker-Silva SC, Chiarini-Garcia H. The length of the cycle of seminiferous epithelium in goats (*Capra hircus*). *Tissue Cell*. 1999;31:274–280.
- França LR, Godinho CL. Testis morphometry, seminiferous epithelium cycle length, and daily sperm production in domestic cats (*Felis catus*). *Biol Reprod*. 2003;68:1554–1561.
- França LR, Ogawa T, Avarbock MR, Brinster RL, Russell LD. Germ cell genotype controls cell cycle during spermatogenesis in the rat. *Biol Reprod*. 1998;59:1371–1377.
- França LR, Russell LD. The testis of domestic mammals. In: Martínez-García F, Regadera J, eds. *Male Reproduction*. Spain: Churchill Communications Europe España; 1998:197–219.
- França LR, Silva VA Jr, Chiarini-Garcia H, Garcia SK, Debejuk L. Cell proliferation and hormonal changes during postnatal development of the testis in the pig. *Biol Reprod*. 2000;63:1629–1636.
- Gaytan F, Lucena MC, Muñoz E, Paniagua R. Morphometric aspects of rat testis development. *J Anat*. 1986;145:155–159.
- Grocock CA, Clarke JR. Duration of spermatogenesis in the vole (*Microtus agrestis*). *J Reprod Fertil*. 1976;47:133–135.
- Habert R, Lejeune H, Saez JM. Origin, differentiation and regulation of fetal and adult Leydig cells. *Mol Cell Endocrinol*. 2001;179:47–74.
- Hess RA, Cooke PS, Bunick D, Kirby JD. Adult testicular enlargement induced by neonatal hypothyroidism is accompanied by increased Sertoli cell and germ cell number. *Endocrinology*. 1993;132:2607–2613.
- Hess RA, Schaeffer DJ, Eroschenko VP, Keen JE. Frequency of the stages in the cycle of the seminiferous epithelium in the rat. *Biol Reprod*. 1990;43:517–24.
- Hochereau-de-Riviers MT, Lincoln GA. Seasonal variation in the histology of the testis of the red deer, *Cervus elaphus*. *J Reprod Fertil*. 1978;54:209–213.
- Huckins C. The morphology and kinetics of spermatogonial degeneration in normal adult rats: an analysis using a simplified classification of the germinal epithelium. *Anat Rec*. 1978;190:905–926.
- Johnson L. Seasonal differences in equine spermatocytogenesis. *Biol Reprod*. 1991;44:284–291.
- Johnson L. Efficiency of spermatogenesis. *Microsc Res Tech*. 1995;32:385–422.
- Johnson L, Neaves WB. Age-related changes in the Leydig cell population, seminiferous tubules and sperm production in stallions. *Biol Reprod*. 1981;24:703–712.
- Johnson L, Varner DD, Robert ME, Smith TL, Keillor GE, Scrutchfield WL. Efficiency of spermatogenesis: a comparative approach. *Anim Reprod Sci*. 2000;60–61:471–480.
- Kenagy CJ, Trombulak SC. Size and function of mammalian testes in relation to body size. *J Mammol*. 1986;67:1–22.
- Leblond CP, Clermont Y. Definition of the stages of the cycle of the seminiferous epithelium in the rat. *Ann N Y Acad Sci*. 1952;55:548–573.
- Lee J, Richburg JH, Shipp EB, Meistrich ML, Boekelheide K. The Fas System, a regulator of testicular germ cell apoptosis, is differentially up-regulated in Sertoli cell versus germ cell injury of the testis. *Endocrinology*. 1999;140:852–858.
- Lee J, Richburg JH, Younkin SC, Boekelheide K. The Fas system is a key regulator of germ cell apoptosis in the testis. *Endocrinology*. 1997;138:2081–2088.
- Neaves WB, Johnson L. Seminiferous tubules and daily sperm production (DSP) in older adult men with varied numbers of Leydig cells. *Biol Reprod*. 1985;32:86.
- Neves ES, Chiarini-Garcia H, França LR. Comparative testis morphometry and seminiferous epithelium cycle length in donkeys and mules. *Biol Reprod*. 2002;67:247–255.
- Ninomiya H, Nakamura T. Postnatal development of the testis in the Mongolian gerbil, *Meriones unguiculatus*. *Exp Anim*. 1987a;36:65–72.



- Ninomiya H, Nakamura T. Benign testicular hyperplasia in the Mongolian gerbil, *Meriones unguiculatus*. *Exp Anim*. 1987b;36:191–194.
- Orth JM, Gunsalus GL, Lamperti AA. Evidence from Sertoli cell-depleted rats indicates that spermatids number in adults depends on numbers of Sertoli cells produced during perinatal development. *Endocrinology*. 1988;122:787–794.
- Oud JL, de Rooij DG. Spermatogenesis in the Chinese hamster. *Anat Rec*. 1977;187:113–124.
- Paula TAR, Chiarini-Garcia H, França LR. Seminiferous epithelium cycle and its duration in capybaras (*Hydrochoerus hydrochaeris*). *Tissue Cell*. 1999;31:327–334.
- Rich ST. The Mongolian gerbil (*Meriones unguiculatus*) in research. *Lab Anim Care*. 1968;18:235–242.
- Rocha DCM, Debeljuk L, França LR. Exposure to constant light during testis development increases daily sperm production in adult Wistar rats. *Tissue Cell*. 1999;31:372–379.
- Roosen-Runge EC. Quantitative studies on spermatogenesis in the albino rat. II. The duration of spermatogenesis and some effects of colchicine. *Am J Anat*. 1951;88:163–176.
- Roosen-Runge EC. Germinal-cell loss in normal metazoan spermatogenesis. *J Reprod Fertil*. 1973;35:339–348.
- Roosen-Runge EC. *The Process of Spermatogenesis in Animals*. Cambridge: University Press; 1977.
- Rosiepen G, Aslan M, Clemen G, Nieschlag E, Weinbauer GF. Estimation of the duration of the cycle of the seminiferous epithelium in the non-human primate *Macaca mulatta* using the 5-bromodeoxyuridine technique. *Cell Tissue Res*. 1997;288:365–369.
- Rosiepen G, Weinbauer GF, Schlatt S, Behre HM, Nieschlag E. Duration of the cycle of the seminiferous epithelium, estimated by the 5-bromodeoxyuridine technique, in laboratory and feral rats. *J Reprod Fertil*. 1994;100:299–306.
- Russell LD. Mammalian Leydig cell structure. In: Payne AH, Hardy MP, Russell LD, eds. *The Leydig Cell*. Vienna, Ill: Cache River Press; 1996:43–96.
- Russell LD, França LR. Building a testis. *Tissue Cell*. 1995;27:129–147.
- Russell LD, Peterson RN. Determination of the elongate spermatid-Sertoli cell ratio in various mammals. *J Reprod Fertil*. 1984;70:635–641.
- Russell LD, Ren HP, Sinha-Hikim I, Schulze W, Sinha-Hikim AP. A comparative study in twelve mammalian species of volume densities, volumes, and numerical densities of selected testis components, emphasizing those related to the Sertoli cell. *Am J Anat*. 1990b;188:21–30.
- Russell LD, Sinha-Hikim AP, Ettl RA, Clegg ED. *Evaluation of the testis: Histological and Histopathological*. 1a ed. Cache River Press; 1990a.
- Russell LD, Warren J, Debeljuk L, et al. Spermatogenesis in bclw-deficient mice. *Biol Reprod*. 2001;65:318–332.
- Schwentker V. The gerbil. A new laboratory animal. *III Vet*. 1963;6:5.
- Segatelli TM, Almeida CCD, Pinheiro PFF, Martinez M, Padovani CR, Martinez FE. Kinetics of spermatogenesis in the Mongolian gerbil (*Meriones unguiculatus*). *Tissue Cell*. 2002;34:7–13.
- Segatelli, TM, Pinheiro PFF, Almeida CCD, Martinez M, Padovani CR, Martinez FE. Ultrastructural study of acrosome formation in mongolian gerbil (*Meriones unguiculatus*). *Tissue Cell*. 2000;32:1–10.
- Setchell BP, Maddocks S, Brooks DE. Anatomy, vasculature, innervation, and fluids of the male reproductive tract. In: Knobil E, Neill JD, eds. *The Physiology of Reproduction*. 2nd ed. New York: Raven Press; 1994:1063–1175.
- Sharpe RM. Regulation of spermatogenesis. In: Knobil E, Neill JD, eds. *The Physiology of Reproduction*. New York: Raven Press; 1994:1363–1434.
- Sinha-Hikim AP, Bartke A, Russell LD. Morphometric studies on hamster testes in gonadally active and inactive states: light microscope findings. *Biol Reprod*. 1988;39:1225–1237.
- Sinha-Hikim AP, Chakraborty J, Jhunjhunwala JS. Germ cell quantification in human testicular biopsy. *Urol Res*. 1985;13:111–115.
- Sinha-Hikim AP, Swerdloff RS. Hormonal and genetic control of germ cell apoptosis in the testis. *Rev Reprod*. 1999;4:38–47.
- Smithwick EB, Young LG, Gould KG. Duration of spermatogenesis and relative frequency of each stage in the seminiferous epithelial cycle of the chimpanzee. *Tissue Cell*. 1996a;28:357–366.
- Smithwick EB, Gould KG, Young LG. Estimate of epididymal transit time in the chimpanzee. *Tissue Cell*. 1996b;28:485–493.
- Sprando RL. Perfusion of the rat testis through the heart using heparin. In: Russell LD, Ettl RA, Sinha-Hikim AP, Clegg ED, eds. *Histological and Histopathological Evaluation of the Testis*. Clearwater, Fla: Cache River Press; 1990:277–280.
- Swierstra EE. Cytology and duration of the cycle of the seminiferous epithelium of the boar; duration of spermatozoan transit through the epididymis. *Anat Rec*. 1968;161:171–186.
- Swierstra EE, Foote RH. Duration of spermatogenesis and spermatozoan transport in the rabbit based on cytological changes, DNA synthesis and labeling with tritiated thymidine. *Am J Anat*. 1965;116:401–412.
- Weinbauer GF, Aslan H, Krishnamurthy H, Brinkworth MH, Einspanier A, Hodges IK. Quantitative analysis of spermatogenesis and apoptosis in the common marmoset (*Callithrix jacchus*) reveals high rates of spermatogonial turnover and high spermatogenic efficiency. *Biol Reprod*. 2001;64:120–126.
- Weinbauer GF, Schubert J, Yeung CH, Rosiepen G, Nieschlag E. Gonadotrophin-releasing hormone antagonist arrests premeiotic germ cell proliferation but does not inhibit meiosis in the male monkey: a quantitative analysis using 5-bromodeoxyuridine and dual parameter flow cytometry. *J Endocrinol*. 1998;156:23–34.
- Williams WM. *The Anatomy of the Mongolian gerbil (Meriones unguiculatus)*. West Brookfield, Mass: Tumblebrook Farm, Inc; 1974.
- Wing TY, Christensen K. Morphometric studies on rat seminiferous tubules. *Am J Anat*. 1982;165:13–25.
- Young KA, Nelson RJ. Mediation of seasonal testicular regression by apoptosis. *Reproduction*. 2001;122:677–685.
- Zirkin BR, Ewing LL, Kromann N, Cochran RC. Testosterone secretion by rat, rabbit, guinea pig, dog, and hamster testes perfused in vitro: correlation with Leydig cell ultrastructure. *Endocrinology*. 1980;107:1867–1874.