



Mario Rietjens

**Segurança oncológica no uso de
células tronco de origem adiposa e
lipofilling na reconstrução
mamária após câncer**

**Orientador
Marilza Vieira Cunha Rudge**

**Co-orientador
Jose Ricardo P. Rodrigues
Jean Yves Petit**

Doutorado

**FACULDADE DE MEDICINA DE BOTUCATU
Universidade Estadual Paulista "Júlio de Mesquita Filho"
UNESP
2012**



Mario Rietjens

Segurança oncológica no uso de células tronco de origem adiposa e lipofilling na reconstrução mamária após câncer

Tese apresentada ao Programa de Pós Graduação em Ginecologia, Obstetrícia e Mastologia da Faculdade de Medicina de Botucatu – UNESP, área de concentração em Tocoginecologia, para obtenção do título de Doutor.

Orientador
Marilza VIEIRA CUNHA RUDGE

Co-Orientador
Jose Ricardo P. RODRIGUES
Jean Yves PETIT

FACULDADE DE MEDICINA DE BOTUCATU
Universidade Estadual Paulista “Julio de Mesquita Filho”
UNESP
2012

Rietjens, Mario

Segurança oncológica no uso de células tronco de origem adiposa e lipofilling na reconstrução mamária após câncer./ Mario Rietjens. – Botucatu – 2011.

Tese (Doutorado) – Faculdade de Medicina de Botucatu, Universidade Estadual Paulista, 2011.

Orientador: Prof. Dr. Marilza Vieira Cunha Rudge

Co-orientadores: Prof. Dr. Jose Ricardo P. Rodrigues

Prof. Dr. Jean Yves Petit

Mamas – Câncer – Cirurgia. 2. Enxerto adiposo – células tronco. 3. Câncer – tratamento – resultado estético. 4. Oncologia

Palavras chave: Câncer de mama; Cirurgia da mama; reconstrução da mama; células tronco; enxerto; adipócitos.



Dedicatória

A minha esposa Yara, pelo amor, companheirismo e paciência a mim dedicados durante todos estes anos.

Aos meus filhos Daniel e Bruna, pelo estímulo cotidiano de luta e sacrifício para encontrar um lugar ao sol em um momento de crise europeia.

Aos meus pais Jacs e Floripes, pelo amor e orientação que guiou-me durante toda a minha vida.

A minha irmã Elisa, com carinho e admiração pela sua capacidade de lutar.

A minha sogra Maria Rita, por permitir a minha inclusão nesta bela família botucatuense.

Aos meus amigos Marco, Linda, Lino e Alessandra por compartilharem a alegria da vida em Milão.

Aos meus colaboradores do Departamento de Cirurgia Plástica do IEO, pela grande ajuda e amizade durante as intermináveis jornadas de trabalho no hospital.

Aos meus pupilos e amigos: Cicero Urban, Angelo Gustavo Zucca Matthes, Fabrício Brenelli, Maurício Resende, Eluis Barbosa e Regis Paulinelli por continuarem os ensinamentos da Oncoplástica em todo o Brasil.



Agradecimientos

À Doutora Marilza Vieira Cunha Rudge, por aceitar ser a orientadora desta tese e por sua grande ajuda para que ela fosse finalizada.

Ao Doutor José Ricardo P. Rodrigues, pela brilhante idéia de propor-me a realização deste projeto.

Ao Doutor Mario Schorr, pela enorme disponibilidade e ajuda para as intermináveis revisões da tese.

Ao meu ex-chefe e amigo Prof. Jean Yves Petit, pela ajuda e oportunidade para realizar a minha carreira de médico na Europa.



Epigrafe

*“Querem que vos ensine o modo de chegar a ciência verdadeira?
Aquilo que se sabe, saber que se sabe; aquilo que não se sabe,
saber que não se sabe; na verdade é este o saber.”*

Confúcio



Resuma

Introdução: Lipofilling ou enxerto de gordura é uma técnica muito utilizada para corrigir defeitos em qualquer região do corpo humano. **Objetivo:** O objetivo deste estudo foi analisar a segurança desta técnica para corrigir defeitos de reconstruções mamárias após câncer de mama. **Material e métodos:** Foram analisados 158 pacientes que receberam 194 procedimentos de enxerto de gordura, segundo a técnica de Coleman e realizados por um único cirurgião (MR). 98% das pacientes desta série tinham cirurgia oncológica mamária precedente: conservadora ou mastectomia com reconstrução. **Resultados:** A única complicação pós-operatória encontrada nesta série foi a liponecrose associada à mastite em sete casos (3.6%), todos tratados com terapia antibiótica e curativos diários. Nos pacientes com precedente de cirurgia conservadora e tratados com enxerto de gordura, somente quatro (5.9%) apresentaram pequenas alterações na mamografia, simulando alterações benignas. **Conclusão:** O enxerto gorduroso pode ser uma boa solução para reparar defeitos após reconstrução em pacientes tratados de câncer de mama e pode reduzir indicações de cirurgias maiores, como reconstruções com retalhos miocutâneos. A incidência de complicações pós-operatórias é muito baixa e não ocorrem alterações significativas nas mamografias de seguimento oncológico. Dois pontos ainda não estão elucidados: qual o percentual de gordura que é reabsorvida após o lipofilling e se existe a possibilidade das células-tronco de origem adiposa estimular células neoplásicas a induzirem recidiva local.

Palavras-chave: Mama; Injeção de gordura autóloga; Técnica de Coleman; Cirurgia reconstrutora da mama; Tratamento Conservador; Complicações cirúrgicas.



Abstract

Background: Fat grafting is largely used to correct soft-tissue defects in any region of the human body. This study analysed its safety when the technique is used to correct defects after breast cancer reconstruction. **Methods:** A total of 158 patients who underwent 194 breast fat grafting procedures were analysed. Almost all patients (98%) had a personal history of breast cancer treated with conservative surgery or mastectomy followed by breast reconstruction. In all cases, fat grafting was performed according to the Coleman's technique by a single surgeon. **Results:** Immediate complications included liponecrosis and infection in seven cases (3.6%) that required only daily dressings and oral antibiotics administration. In cases of fat grafting after conservative surgery, only four patients (5,9%) showed minor alterations in the postoperative mammograms, consisting of the appearance of benign images. **Conclusion:** Breast fat grafting can be a good solution to repair defects after breast-cancer treatment and reconstruction, and can reduce the indication for more extensive surgeries such as myocutaneous flaps. Postoperative complication rates are very low and there is little alteration in the follow-up mammograms. Two points remain unclear – What is the percentual of the fat is absorbed after grafting and the potential risk of local “domant” tumour cells being stimulated to induce a local recurrence.

Keywords: Breast; Autologous fat injection; Coleman technique; Breast reconstructive surgery; Conservative treatment; Surgical complications.



Sumário

Lista de Ilustrações.....	16
Lista de Abreviaturas	19
1 Introdução.....	21
2 Revisão da Literatura	24
2.1 Conceitos básicos sobre Lipoenxertia.....	25
2.2 Células-tronco derivadas de células diposas, pré-adipócitos e engenharia de tecidos.....	25
2.3 A biologia do tecido gorduroso e medicina regenerativa: um futuro promissor.....	26
3 Princípios técnicos para lipoenxertia.....	28
3.1 Revisão da técnica.....	29
3.2 Protocolos pré e pós-operatório e técnica cirúrgica utilizada no IEO.....	31
3.2.1 Avaliação pré-operatória.....	31
3.2.2 Técnica Cirúrgica.....	32
3.2.3 Cuidados pós-operatórios e seguimento.....	36
4 Reconstrução secundária da mama com lipoenxertia pós câncer de mama.	37
4.1 Cirurgias conservadoras.....	38
4.1.1 Reparações secundárias.....	38
4.1.2 Reparações imediatas.....	38
4.2 Mastectomias.....	39
4.2.1 Reparações secundárias após reconstruções com próteses.....	39

4.2.2	Reparações secundárias após reconstruções com retalhos autólogos do grande dorsal ou reto abdominal.....	39
4.2.3	Reparações imediatas após mastectomias.....	40
5	Questionamentos e pontos controversos.....	41
5.1	A técnica realmente funciona.....	43
5.2	Incidência de complicações ligadas à lipoenxertia.....	45
5.3	Lipoenxertia e alterações nos exames de imagem.....	45
5.4	Lipoenxertia e estimulação tumoral.....	46
6.	Resultados.....	48
7	Considerações finais.....	51
8	Fotos de casos incluídos no estudo.....	53
9	Referências Bibliográficas	61
10	Artigos científicos publicados.....	71
10.1	Artigo 1.....	76
10.2	Artigo 2.....	83
10.3	Artigo 3.....	90
10.4	Artigo 4.....	97
11	Anexos.....	99
11.1	Documento de aprovação do Comitê de Ética.....	100
11.2	Termo de consentimento livre e esclarecido pós-informado.....	113



Lista de Ilustrações

Figura 1	Infiltração da solução de Coleman na região abdominal previamente à lipoaspiração.....	32
Figura 2	A gordura é aspirada delicadamente após a vasoconstrição estar estabelecida através de pequena incisão no mesmo ponto da infiltração.....	33
Figura 3	Tecido adiposo aspirado colocado na centrífuga e após centrifugação resultando em solução de 3 fases: superficial: fração oleosa; intermediária: adipócitos purificados que serão enxertados; profunda: resíduo de sangue, solução salina e anestésica.....	34
Figura 4	Enxerto de pequenas porções de gordura purificada em finas camadas e em múltiplos túneis no espaço subcutâneo na área do defeito.....	35

CASOS CLÍNICOS

Figura 1	Foto de celulite pós-operatória.....	54
Figura 2	Foto de defeito após cirurgia conservadora da mama esquerda.....	54
Figura 3	Foto de resultado após mastopexia periareolar direita e lipofilling de 130 gramas de tecido adiposo na mama esquerda em anestesia geral.....	55
Figura 4	Foto de defeito no quadrante súpero-interno após reconstrução mamária imediata com prótese definitiva.....	56
Figura 5	Foto do caso anterior em visão oblíqua.....	56

Figura 6	Foto do resultado após lipofilling de 50 gramas de tecido adiposo e reconstrução do complexoaréola e mamilo com anestesia local.....	57
Figura 7	Foto do caso anterior com visão oblíqua.....	57
Figura 8	Foto pré-operatória de paciente com recidiva mamária à esquerda após quadrantectomia e radioterapia intra-operatória.....	58
Figura 9	Foto do resultado após mastectomia esquerda com conservação do CAM e radioterapia intra-operatória no CAM, mastectomia profilática direita e reconstrução mamária bilateral com prótese definitiva. Paciente estava insatisfeita com as ondulações nos quadrantes súpero-interno (Rippling).....	58
Figura 10	Foto do resultado após lipofilling de 30 gramas em cada mama, com anestesia local.....	59
Figura 11	Foto de paciente com contratura periprotésica após mastectomia, reconstrução mamária imediata com prótese definitiva e radioterapia externa convencional.....	59
Figura 12	Foto de resultado após 4 sessões de lipofilling com anestesia local, com grande melhora da contratura periprotésica.....	60



Lista de Abreviaturas

BFG -	Breast fat grafting
MMG –	Mamografia
RM -	Ressonância magnética
IEO -	Instituto Europeu de Oncologia
MR –	Mario rietjens
TRAM –	Transverse rectus abdominis musculocutaneous flap / Retalho músculo-cutâneo do músculo retoabdominal transverso
RT –	Radioterapia
CAM –	Complexo aréolo-mamilar
ADSCs –	Adipose-derived stem cells
ml –	Mililitros
mg –	Miligrama
RPM –	Rotações por minuto



1. Introdução

Após a primeira revolução na abordagem cirúrgica do câncer de mama, a cirurgia conservadora tornou-se o tratamento de escolha para a maioria das pacientes (1,2). O aprofundamento e o refinamento técnico seguiu esse novo paradigma, que envolve preservação, reparação e reconstrução mamária associando técnicas da cirurgia plástica ao tratamento oncológico. É uma nova forma de encarar esse grave problema que atinge a feminilidade, no seu órgão simbólico mais significativo. Esse movimento passou a encontrar aceitação entre a comunidade científica médica e nos diversos estratos da sociedade. Na tomada de decisão sobre a abordagem terapêutica do câncer de mama, passaram a fazer parte do processo noções de que se deve tratar a pessoa e não a mama com câncer, que não se pode estigmatizar a mulher com a amputação de sua mama sem reconstrução imediata e, principalmente, que não se deve adoecer a paciente com a mutilação para só depois curá-la.

O último e revolucionário avanço para o melhoramento cosmético pós-tratamento cirúrgico mamário é a lipoenxertia, do inglês, breast fat grafting (BFG), que corresponde ao preenchimento de defeitos de superfície corpórea com a injeção de tecido adiposo autólogo. (3) Czerny, em 1895,(4) descreveu o primeiro caso de lipofilling, que consistiu no enxerto de um lipoma da região lombar em um defeito mamário. Do início do século 20 até 1980, inúmeras publicações demonstraram a factibilidade e a eficácia do método na correção de defeitos de face e mãos. (5-9) Posteriormente, o enxerto de gordura também passou a ser utilizado para corrigir defeitos estéticos mamários (10,11) (12, 13) e para a correção das sequelas estéticas decorrentes dos tratamentos oncológicos da mama. Tanto após a cirurgia conservadora associada à radioterapia (RT) local quanto após a mastectomia seguida de reconstrução, o enxerto de gordura dá bons resultados e permite corrigir pequenos a

moderados defeitos. (1-3, 7-9, 11, 14-21) Coleman (5-7, 9, 10, 14) e Rigotti (15, 16, 22-24) demonstraram que o transplante autólogo de gordura é mais do que uma simples técnica de preenchimento pois melhora a qualidade da pele sobre a gordura transplantada, especialmente em zonas irradiadas, graças à atividade das células-tronco adiposas.(16, 25) O método é simples, facilmente reproduzível, podendo ser realizado sob anestesia local, sem necessidade de grandes incisões.(26)

Existe grande entusiasmo em relação ao transplante de gordura e o uso dessa técnica está sendo muito estimulado (17, 19, 27-32). Em 2005, a lipoenxertia da mama passou a ser realizada no Instituto Europeu de Oncologia (IEO) para corrigir defeitos secundários à reconstrução mamária por câncer. (33) Ainda não há dados que confirmem a segurança oncológica do procedimento. (21, 34-41) Por esse motivo, no IEO preconiza-se o seguimento clínico e instrumental destas pacientes com mamografia (MMG), ecografia e ou ressonância magnética (RM) periódicos (42). Existem ainda questões que precisam ser respondidas antes da introdução em definitivo da técnica na prática cirúrgica. Essas dúvidas levaram a idealizar este estudo que teve como objetivo primário: 1 – identificar os fatores que aumentam o risco de complicações pós-operatórias após lipoenxertia da mama. E como objetivos secundários: 1 - avaliar a factibilidade de realizar a lipoenxertia da mama sob anestesia local; 2 - Avaliar se a lipoenxertia da mama após cirurgia conservadora da mama produz novas microcalcificações, interferindo no acompanhamento oncológico por alterações nos resultados da mamografia; 3 - Avaliar se a lipoenxertia da mama após o tratamento do câncer de mama aumento o índice de recidiva local.

2. Revisão da Literatura

2.1 CONCEITOS BÁSICOS SOBRE LIPOENXERTIA

Desde os primeiros resultados bem-sucedidos e com a padronização da técnica descrita por Coleman (14), a lipoenxertia ultrapassou suas fronteiras originais da cirurgia cosmética e é nos dias de hoje aplicada na mama com aparente eficácia. (10, 21, 30, 33, 43, 44) O enxerto de gordura permite a correção de pequenos e médios defeitos após a reconstrução mamária, parcial ou total. O método é simples e reprodutível, pode ser realizado com anestésico local e tem o potencial de iniciar o reparo e regeneração tecidual. (26) Como demonstrado pelo próprio Coleman (14, 45), o tecido gorduroso enxertado não apenas restaura o volume, mas também melhora a qualidade da pele que recobre a gordura transplantada, em especial em regiões irradiadas, graças à atividade das células-tronco derivadas de adipócitos (ADSCs, em inglês).

2.2 CÉLULAS-TRONCO DERIVADAS DE CÉLULAS ADIPOSAS, PRÉ-ADIPÓCITOS E ENGENHARIA DE TECIDOS

Nos últimos anos, estudos sobre a natureza da matriz extracelular mostraram que, além dos adipócitos, o tecido gorduroso contém muitos outros tipos celulares, tais como pré-adipócitos, células endoteliais, células de músculo liso, fibroblastos e células-tronco derivadas de adipócitos. (9)

Os pré-adipócitos representam uma população de células que podem rapidamente diferenciar-se em adipócitos. (46-48) As ADSCs, presentes na fração estromal do lipoaspirado, são capazes de se diferenciar em muitos

outros tipos celulares, tais como adipócitos, osteoblastos, condrócitos, cardiomiócitos, células endoteliais, entre outras. (49-53). Portanto, são capazes de formar diferentes tecidos como osso, músculo, cartilagem, nervos e vasos sanguíneos. (49, 54-57)

A habilidade de formar outros tecidos permite à gordura transplantada produzir mais capilares ou vasos sanguíneos e criar um novo suprimento sanguíneo ou até mesmo substituir células ausentes ou danificadas. (16, 58, 59)

Além disso, as células derivadas do tecido gorduroso humano têm muitas propriedades, tais como, imunocompatibilidade, multipotência, capacidade de auto-renovação, disponibilidade e fácil acesso. Essas características tornam o tecido adiposo acessível à engenharia genética e fazem dele uma fonte de células autólogas ideal para aplicações na engenharia tecidual e na medicina regenerativa. (49-53, 60, 61) (62, 63)

2.3 A BIOLOGIA DO TECIDO GORDUROSO E MEDICINA REGENERATIVA: UM FUTURO PROMISSOR

Além do conceito tradicional de que a gordura é um reservatório de “high-energy” envolvida na homeostase pela sua habilidade de reter grandes quantidades de fluidos, e com propriedades isolantes envolvidas na manutenção da termorregulação, há uma nova caracterização de que a gordura é também um órgão com capacidade reparadora. (9, 39, 40, 63, 64)

Quando a gordura é transplantada para outra parte do corpo, essa propriedade reparadora parece ser ainda mais pronunciada.(45)

Um mecanismo provável que justifique essa propriedade regenerativa da gordura enxertada no tecido danificado deve-se à ação de células primitivas (células-tronco mesenquimais e pré-adipócitos) presentes no tecido gorduroso normal. (11) A manipulação das ADSCs mostra-se promissora em diferentes campos da medicina, possibilitando multiplicidade de novos tratamentos, que farão parte de um movimento em direção à chamada medicina regenerativa.(39, 40, 45, 65)

3. Princípios Técnicos para Lipoenxertia

Os princípios básicos da técnica “Structural Fat Grafting” publicados originalmente por Coleman em 1998 (66) permanecem inalterados e continuam norteando o procedimento de lipoenxertia mamária. A lipoenxertia consiste na lipossucção atraumática com subsequente injeção de adipócitos purificados na área defeituosa no mesmo procedimento.

3.1 REVISÃO DA TÉCNICA(45)

A coleta do tecido gorduroso se faz através de lipoaspiração com cânula romba e seringa de 10 ml, realizando a sucção com baixa pressão negativa. Recentes publicações não demonstraram maior viabilidade de nenhum local doador específico. (67, 68) As zonas doadoras devem ser acessadas por incisões colocadas, sempre que possível, em dobras corporais, cicatrizes prévias, estrias ou áreas de pilificação. Infiltra-se a solução de lidocaína e epinefrina (se procedimento é feito com anestesia local) delicadamente, com agulha romba, em locais com tecido gorduroso mais saliente.

O refinamento do material coletado é feito com centrifugação que remove os componentes inertes. A velocidade recomendada é de 3.000 (três mil) rotações por minuto por três minutos. A centrífuga separa os componentes por densidade, criando três diferentes camadas. A mais superficial é a de menor densidade e é constituída basicamente de óleo. A porção intermediária consiste primariamente de tecido gorduroso. A camada mais profunda e densa contém sangue, água e elementos aquosos como a lidocaína e ringer lactato. A

seguir o óleo é decantado, para após ser então descartada a camada mais densa de líquidos. Pequenas tiras de material absorvente podem ser colocados na seringa após esse processo, em geral por 4 minutos, para retirar o óleo remanescente. A gordura refinada é então transferida para seringas de 1 ou 3 ml. A percentagem de gordura viável após a centrifugação varia de 10 a 90% do material lipoaspirado.

A injeção do tecido gorduroso refinado no local receptor é a parte mais desafiadora do processo de lipoenxertia. Porções de gordura devem ser posicionadas de forma a assegurar a sobrevivência uniforme, estabilidade e integração do material ao tecido receptor circundante. O passo fundamental para a adequada infiltração do tecido gorduroso é maximizar a superfície de contato entre a gordura enxertada com o tecido receptor, colocando pequenas quantidades de gordura separadas entre si, entremeadas pelo tecido receptor. Com esta técnica, múltiplas camadas simples de adipócitos são dispostas de tal forma a permitir uma boa vascularização do tecido enxertado, diminuindo a chance de fibrose e liponecrose. A injeção de uma massa de gordura em locais inadequados pode resultar em áreas de gordura que fiquem muito longe dos tecidos vascularizados que são a fonte de nutrição e respiração. Neste caso, grande parte do enxerto morrerá ou será reabsorvido e isto pode resultar também em irregularidades na região lipoenxertada. Dessa forma, diminuem-se os danos ao frágil tecido gorduroso pela agressão mecânica, barométrica ou química. A aderência a esses princípios promove a longevidade, estabilidade e integração efetiva do tecido gorduroso aos tecidos receptores, criando uma mudança estrutural que é minimamente detectável. (45)

3.2 PROTOCOLOS PRÉ E PÓS-OPERATÓRIO E TÉCNICA CIRÚRGICA UTILIZADA NO IEO

3.2.1 Avaliação pré-operatória

Todas as pacientes foram submetidas a avaliações clínica e radiológica das mamas. Mamografia bilateral e ultrassonografia mamária foram solicitadas para todas as pacientes, excluindo-se mamografias para mamas reconstruídas.

Após fornecer informações detalhadas sobre o procedimento, cada paciente entregou um consentimento informado concordando em se submeter à cirurgia e que os dados fossem usados para pesquisa. As pacientes foram examinadas em posição ortostática, quando foram realizadas as fotos e os desenhos para demarcar a zona doadora e a área receptora do enxerto. Os defeitos foram medidos por caliper ou régua nos seus maiores diâmetros e a sua profundidade por uma medida empírica aproximada. Para estimar o volume do defeito a ser corrigido usou-se a seguinte fórmula:

$$[\text{Altura defeito (cm)} \times \text{Largura defeito (cm)} \times \text{Profundidade (cm)}] / 2 \quad (26)$$

Em casos com múltiplos defeitos, eles foram medidos e nomeados como defeito 1, 2, 3, e assim por diante. (26)

O procedimento foi realizado sob anestesia geral ou local, dependendo das condições clínicas, riscos ou realização de procedimentos concomitantes. A preferência foi pela anestesia local sendo a anestesia geral reservada para os casos de lipoaspiração de grande quantidade de tecido gorduroso ou quando solicitado pela paciente.

3.2.2 Técnica cirúrgica

Os procedimentos de lipoaspiração e lipofilling foram realizados de acordo com a técnica de Coleman (45), com mínimas modificações, como descritos a seguir:

Infiltração: Sob anestesia geral, a zona doadora foi infiltrada com 500 ml de solução Ringer Lactato + 1 mg de epinefrina utilizando uma cânula romba de 1 mm de diâmetro. Nos casos sob anestesia local a solução foi modificada, acrescentando-se 50 ml de anestésico local (mepivacaína) e infiltrando-se com agulha de anestesia epidural. O volume máximo injetado no abdome foi de 300 ml e, na área do quadril, coxa e joelho foi de 240 ml. Na periferia do defeito mamário, foi infiltrado anestésico local com adrenalina (Mepivacaína com 1:400.000 de epinefrina). A quantidade de solução injetada foi o dobro do volume estimado da gordura necessária. (ver figura 1)

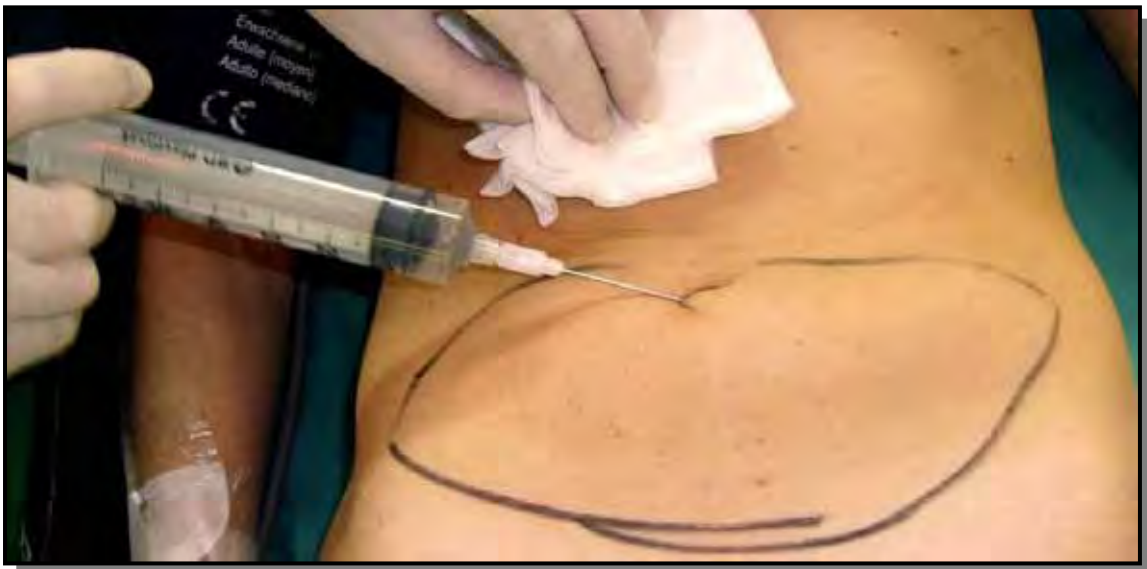

Figura 1: infiltração da solução de Coleman na região abdominal previamente à lipoaspiração.

Aspiração: Através de pequena incisão, realizada no mesmo ponto da infiltração, a gordura foi aspirada delicadamente após a vasoconstricção estar estabelecida (no abdome, a incisão é infra-umbilical). As cânulas de lipoaspiração mediam 3 mm de diâmetro, com comprimentos que variaram de 15 a 23 cm e com a ponta romba para diminuir a chance de lesão vascular. Estas cânulas foram conectadas a uma seringa luer-lock (“dual function luer-lock plug”), que aspira com mínima pressão negativa, diminuindo o trauma sobre os adipócitos para preservar sua integridade. A gordura geralmente foi obtida da região abdominal. Outras zonas doadoras foram a porção lateral da coxa, quadril e área interna dos joelhos. A gordura foi lipoaspirada até alcançar o volume pré-estimado do defeito mamário. (ver figura 2)

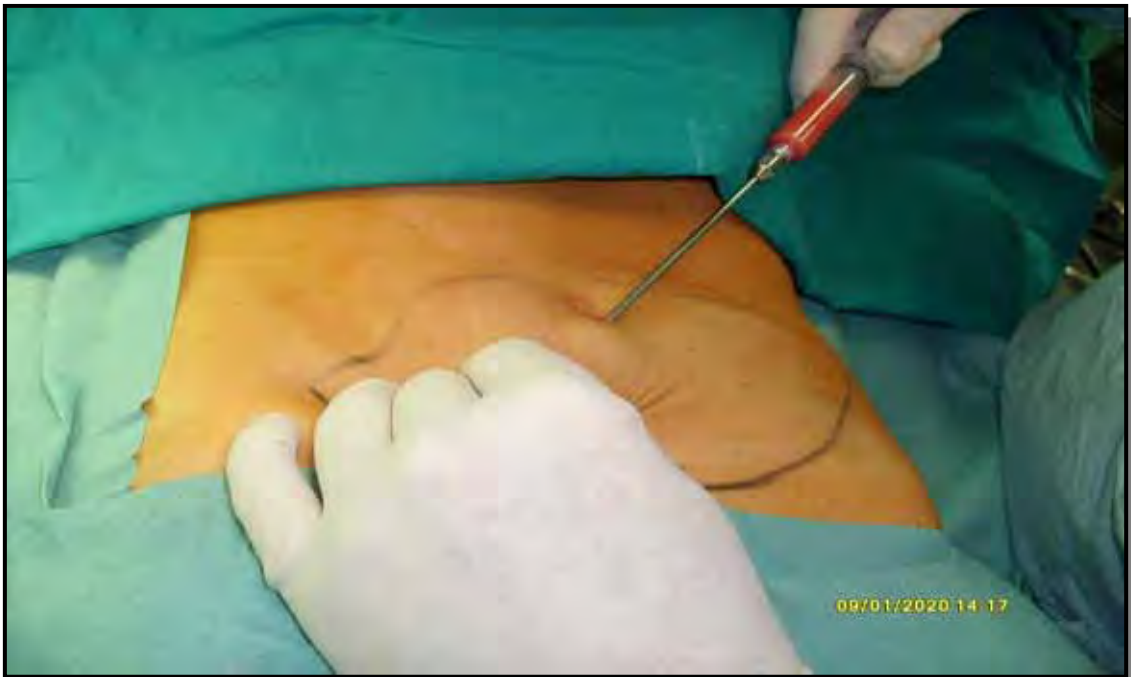

Figura 2: a gordura foi aspirada delicadamente após a vasoconstricção estar estabelecida através de pequena incisão no mesmo ponto da infiltração.

Centrifugação: O tecido adiposo foi centrifugado a 3.000 RPM por 3 minutos até separar o soro e o componente oleoso do tecido adiposo. (figura 3)

Assim, obteve-se uma solução de 3 fases:

- a) superficial: resultado da lise celular durante aspiração – fração oleosa.
- b) intermediária: adipócitos purificados – porção enxertada.
- c) profunda: resíduo sanguinolento – sangue, solução salina e anestésica.




Figura 3: tecido adiposo aspirado colocado na centrífuga e após centrifugação resultando em solução de 3 fases: superficial: fração oleosa; intermediária: adipócitos purificados que foram enxertados; profunda: resíduo de sangue, solução salina e anestésica.

Enxerto: Os adipócitos purificados foram imediatamente transferidos diretamente para seringas luer-lock de 1ml que eram conectadas às cânulas de Coleman de 7-9 cm de comprimento, estando preparadas para injeção. Pequenas porções de gordura foram então injetadas, em finas camadas com a técnica de múltiplos túneis, no espaço subcutâneo da área do defeito pela passagem retrógrada da cânula de Coleman.(45) Não infiltrou-se no tecido mamário ou no músculo peitoral. Todos os defeitos foram super corrigidos devido à previsível reabsorção de gordura que ocorre nos primeiros três meses de pós-operatório. (figura 4)

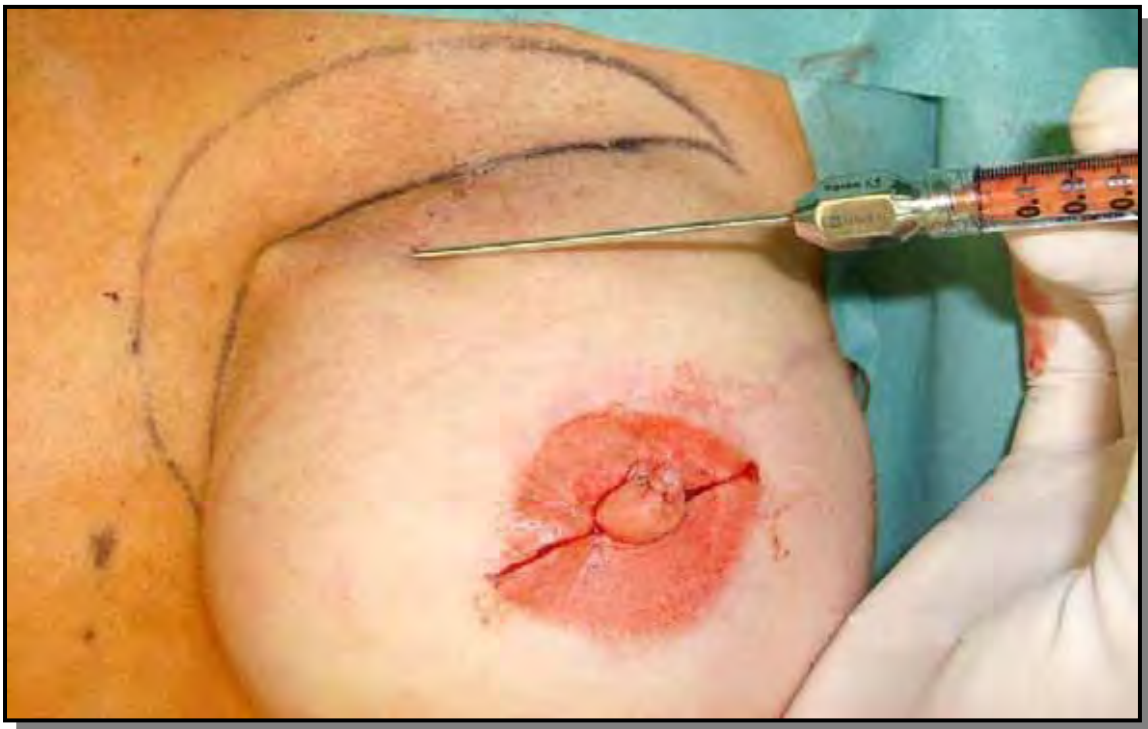

Figura 4: Enxerto de pequenas porções de gordura purificada em finas camadas e em múltiplos túneis no espaço subcutâneo na área do defeito.

3.2.3 Cuidados pós-operatórios e seguimento

Utilizaram-se curativos simples delimitando a área enxertada na região mamária e curativos compressivos na zona doadora. Foram removidos no terceiro pós-operatório. Antibióticos e antiinflamatórios não foram prescritos de rotina, bem como massagens ou drenagem linfática local.

O controle clínico e radiológico foi realizado em todas as pacientes, de acordo com os protocolos oncológicos, além da consulta clínica semestral para avaliação do resultado estético final, da qualidade do enxerto e da necessidade ou não de um segundo procedimento. Além disso, foi realizado o exame instrumental de imagem da mama com mamografia e/ou ecografia anuais.

*4. Reconstrução secundária
da mama com lipoenxertia
pós câncer de mama*

A lipoenxertia é uma grande aliada para a melhora do resultado cosmético da reconstrução mamária após câncer de mama. Pode ser indicada nos casos de cirurgia conservadora, nos casos de reconstrução após mastectomia total e também em algumas situações especiais. (26) Abaixo estão relacionadas as principais indicações da técnica.

4.1 CIRURGIAS CONSERVADORAS

4.1.1 Reparações secundárias

As reparações secundárias de defeitos após o tratamento conservador foram as principais indicações iniciais da técnica. (26) Os defeitos resultantes da quadrantectomia com radioterapia externa são muito difíceis de serem resolvidos, devido à falta de elasticidade e de vascularização dos tecidos irradiados, apresentando maior risco de mau resultado estético e elevado índice de complicações. O lipofilling vem demonstrando baixo risco de complicações pós-operatórias, pois, com a implantação das células-tronco, ocorre melhora da vascularização local e recuperação da elasticidade cutânea, além da reparação dos defeitos estéticos.(26)

4.1.2 Reparações imediatas

A utilização do lipofilling para reparação imediata após quadrantectomia está nos seus passos iniciais. Até o momento não houve necessidade de desenvolvê-la para esta indicação devido às inúmeras técnicas já existentes no arsenal da cirurgia oncoplástica. Uma possível indicação seria nos casos de

reparação de defeitos dos quadrantes superiores, onde a pequena espessura da glândula pode favorecer a adaptação da técnica. Após a sutura do leito tumoral, o lipofilling é feito no espaço subcutâneo em torno da quadrantectomia para recuperar a forma harmoniosa da mama.(26)

4.2 MASTECTOMIAS

4.2.1 Reparações secundárias após reconstruções com próteses

É uma técnica muito útil para incrementar o resultado final da reconstrução. Pode melhorar as retrações dos quadrantes superiores, que são frequentes quando se usa a prótese anatômica com altura baixa, além de poder melhorar a projeção do pólo inferior da mama, simulando uma ptose. É a única técnica eficaz para tratar as ondulações (rippling em inglês) muito frequentes nos quadrantes superiores, devido a menor espessura dos tecidos que recobrem a prótese, mesmo incluindo o músculo peitoral.(26)

4.2.2 Reparações secundárias após reconstruções com retalhos autólogos do grande dorsal ou reto abdominal

O Lipofilling é muito útil, sobretudo quando ocorre complicação vascular acompanhada de perda do volume mamário inicial. É usado para corrigir defeitos e aumentar o volume.(26)

4.2.3 Reparações imediatas após mastectomias

Nestas situações há um problema técnico que dificulta o uso do lipofilling porque, após a mastectomia, não existe espaço para injetar a gordura que tenha contato com os tecidos locais para que possa ter suprimento sanguíneo e funcionar como enxerto. Pode ser indicado em casos especiais de mamas pequenas e com importante lipodistrofia de coxas, podendo inserir-se um expansor e após a sua distensão completa, realizar-se diversas sessões de lipofilling associado à redução do volume do expansor. O volume de tecido adiposo enxertado deve corresponder ao dobro do volume do expansor reduzido. Na sessão final, o expansor é removido e é então realizada a reconstrução do complexo aréolo-papilar, concluindo a reconstrução somente com o tecido adiposo, sem necessidade de inclusão de prótese definitiva. (26)



5. *Questionamentos e pontos
controversos*

A lipoenxertia é um procedimento simples, reprodutível, com baixo índice de complicações. (10, 30, 33, 41) Pode ser útil na correção de defeitos mamários após cirurgia conservadora para câncer de mama e na melhora dos resultados cosméticos após reconstrução mamária com prótese ou retalhos autólogos.(26, 35)

Entretanto, ainda existem questionamentos sobre a eficácia e segurança da técnica e há questões que permanecem sem respostas definitivas. A primeira é se a lipoenxertia realmente funciona, pois o grau variável de reabsorção do tecido enxertado é um inconveniente imprevisível, além disso, apesar de ser considerado baixo, o índice de complicações ainda deve ser melhor equacionado.

Outra questão importante é sobre o receio de que o lipofilling mamário possa interferir na detecção do câncer de mama ou sua recorrência por alterações nos exames de imagem. Mas, o ponto central de incertezas e discussões é se a técnica pode estimular o surgimento de novos tumores ou a sua recorrência.

A seguir serão abordadas essas questões e as evidências disponíveis até o momento:

5.1 A TÉCNICA REALMENTE FUNCIONA

Foi comprovado por Coleman que a técnica funcionava bem para defeitos da face (6, 8) e do dorso das mãos(5), porém, nestes casos, a quantidade de tecido adiposo injetado era pequena e o tecido receptor não apresentava alterações de vascularização, como nos casos após radioterapia. Nos casos iniciais de reparação mamária com a técnica de Coleman, observou-se grande diversidade nos resultados, pois a lipoenxertia mamária mostrou alto e variável índice de absorção (27). No IEO encontrou-se absorção de 10 a 60% do enxerto em seis meses de acompanhamento, (26) ou até 70% do volume, conforme estudo clássico de Billings.(69) É impossível saber qual a proporção de cada tipo celular que será injetado, principalmente das células ADRC, devido à manipulação empírica do tecido(9).

A explicação mais aceitável para a reabsorção tem sido baseada na teoria de sobrevivência celular de Peer, na qual o número de adipócitos viáveis durante o transplante pode correlacionar-se com o volume final do tecido gorduroso enxertado que sobreviverá. (70) Para obter-se longa sobrevivência do tecido gorduroso autólogo transplantado, a gordura lipoaspirada é processada e precisa permanecer viável antes da implantação. A manipulação traumática durante a aspiração e injeção do tecido, pode prejudicar a viabilidade do adipócito transplantado. (26) Uma solução proposta é fazer sessões repetidas, com menor quantidade de gordura transfundida, apresentando menor risco de destruição mecânica e isquêmica do adipócito.(10, 26, 43)

Alguns aparelhos estão sendo introduzidos comercialmente, como por exemplo, o LIPOKIT(71), que permite a separação e eliminação dos adipócitos adultos, aumentando a concentração dos ADRC (basicamente 2% a 5% das células do tecido gorduroso), além dos outros tipos celulares multipotenciais, reduzindo a reabsorção pós-operatória do enxerto. Trata-se de tecnologia nova e ainda não há estudos que comprovem sua eficácia.

Também foi lançado no mercado, pela americana Citory Therapeutics(72-74), um equipamento que permite a separação das células ADRC. Este processo é feito através da ligação de enzimas específicas a anticorpos monoclonais que são adicionados ao tecido adiposo que será enxertado na porcentagem desejada (de 10, 20 ou até 50%). Ainda não está demonstrada a superioridade deste método em relação à técnica de Coleman e, por isso, até o momento não é utilizado no IEO, devido ao alto custo do kit de tubos e enzimas e do longo tempo necessário para o processamento do tecido adiposo e separação das células (entre 2 e 3 horas).

Atualmente, para compensar a reabsorção, tentamos se possível, enxertar um volume um pouco maior que o necessário, fazendo uma hipercorreção. Entretanto, as pacientes são avisadas da possibilidade de fazer uma nova sessão para terminar a correção do defeito. (26, 30) A hipercorreção tem-se revelado uma tática eficaz e apesar de representar alguma imprevisibilidade, tem proporcionado bons resultados.(33)

5.2 INCIDÊNCIA DE COMPLICAÇÕES LIGADAS À LIPOENXERTIA

A técnica é muito simples e na maioria das vezes pode ser feita sob anestesia local assistida em regime de “day hospital”.(26, 33) A grande preocupação era saber se a gordura injetada teria boa capacidade de revascularização e se não existiria grande risco de liponecrose. Neste estudo preliminar (33) foram analisadas as complicações específicas do lipofilling, tanto na zona doadora quanto na receptora e, também, as complicações gerais inerentes a todos os procedimentos cirúrgicos, como infecções, hematomas, embolias, etc, e a incidência de complicações encontradas foi muito baixa. De um total de 158 pacientes, submetidos a 194 procedimentos, houve sete casos (3,6%) de complicações imediatas incluindo liponecrose e infecção local. Em relação às alterações mamográficas após a lipoenxertia em cirurgias conservadoras, apenas 4 pacientes (5,9%) mostraram pequenas alterações no exame com características de benignidade. Esses achados concordam com outros estudos publicados. (30, 41, 44, 75)

5.3 LIPOENXERTIA E ALTERAÇÕES NOS EXAMES DE IMAGEM

O seguimento radiológico das pacientes tratadas com cirurgia conservadora da mama e posteriormente submetidas à lipoenxertia é fonte de incertezas e questionamentos, devido à hipótese da possibilidade de surgimento de novas microcalcificações mamárias, o que poderia dificultar o diagnóstico de recidiva tumoral. (76-79) Entretanto, diferentes procedimentos

mamários como biópsias, mamoplastias, radioterapia, reconstrução e liposucção estética, tem risco de causar mudanças clínicas e radiológicas, e nem por isso deixam de ser realizados.(80-83)

Alguns autores demonstraram que é possível diferenciar as calcificações de origem liponecrótica das calcificações relacionadas com carcinoma mamário. (76, 78, 79, 81-88) Apesar dos achados tranquilizadores da maioria dos trabalhos, ainda existe receio quanto ao acompanhamento por imagem pós lipoenxertia, com intensos debates e posições discordantes como a de Wang. (77) Não há contra-indicações ao procedimento devido ao acompanhamento radiográfico posterior, mas ainda aguardam-se estudos com maior número de pacientes para confirmar essa expectativa.(76, 79, 84, 87, 88)

5.4 LIPOENXERTIA E ESTIMULAÇÃO TUMORAL

Talvez o ponto de maior discussão sobre o lipofilling e câncer de mama seja o risco de que as células tronco adiposas pudessem estimular células neoplásicas quiescentes. (35, 36) Isto se aplica principalmente nos casos em que a lipoenxertia é feita após a cirurgia conservadora.

Numerosos trabalhos que sugerem haver potencial estimulador de células neoplásicas mamárias pelos adipócitos, proadipócitos, células progenitoras e adipocinas foram publicados nos últimos anos. (89-99) Apesar de estudos clínicos recentes não terem evidenciado maior incidência de

recorrência local,(30, 33, 41) esta é uma questão que permanece em aberto, pois há aparente discordância entre os estudos laboratoriais e clínicos.(38)

Diante desse quadro de incerteza, aguardam-se novos trabalhos que possam esclarecer se existe um real potencial carcinogênico das células-tronco do tecido adiposo que são enxertadas e os possíveis grupos de pacientes que seriam expostas a um maior risco.

6. Resultados

Os resultados decorreram da análise de 158 casos de lipofilling foram publicados no artigo:

“Safety of fat grafting in secondary breast reconstruction after cancer”. *J Plast Reconstr Aesthet Surg.* 2011 Apr;64(4):477-83. Rietjens M, De Lorenzi F, Rossetto F, Brenelli F, Manconi A, Martella S, Intra M, Venturino M, Lohsiriwat V, Ahmed Y, Petit JY.

Os resultados encontrados são promissores e sugerem que a lipoenxertia de mama é uma excelente técnica para correção de defeitos mamários após cirurgias oncológicas. É um procedimento seguro, com um baixo índice de complicações pós-operatórias. A radioterapia foi um fator que aumentou as complicações pós-operatórias da lipoenxertia de mama neste trabalho.

Também foi demonstrado que é possível realizar a lipoenxertia da mama sob anestesia local e o procedimento, nesta série, não produziu novas microcalcificações nem atrapalhou o acompanhamento oncológico por interferência nos resultados mamográficos. Os resultados preliminares não mostraram aumento do risco de recidiva local e de metástases. As poucas questões que ainda permanecem são a imprevisibilidade da quantidade de gordura enxertada que será reabsorvida e o resultados oncológicos a longo prazo.

Outros três artigos publicados pelo autor relacionados à segurança oncológica e avaliação de complicações cirúrgicas da lipoenxertia também estão anexados, vide item 10. A seguir os títulos:

Petit JY, Lohsiriwat V, Clough KB, Sarfati I, Ihrai T, Rietjens M, Veronesi P, Rossetto F, Scevola A, Delay E. The oncologic outcome and immediate surgical complications of lipofilling in breast cancer patients: a multicenter study--Milan-Paris-Lyon experience of 646 lipofilling procedures. *Plast Reconstr Surg.* 2011 Aug;128(2):341-6.

Lohsiriwat V, Curigliano G, Rietjens M, Goldhirsch A, Petit JY. Autologous fat transplantation in patients with breast cancer: "silencing" or "fueling" cancer recurrence? *Breast.* 2011 Aug;20(4):351-7.

Petit JY, Clough K, Sarfati I, Lohsiriwat V, de Lorenzi F, Rietjens M. Lipofilling in breast cancer patients: from surgical technique to oncologic point of view. *Plast Reconstr Surg.* 2010 Nov;126(5):262e-263e.

7. Considerações Finais

A lipoenxertia é uma técnica simples, útil e eficaz para melhorar o resultado cosmético na cirurgia oncoplástica da mama, preenchendo pequenos a moderados defeitos e, possivelmente, no futuro, a reconstrução completa da mama possa ser possível através do transplante de tecido adiposo. Entretanto, pensamos que incluir as pacientes candidatas à lipoenxertia após o tratamento do câncer de mama em protocolos de pesquisa, com seguimento continuado, seja prudente e possa responder a alguns dos questionamentos apresentados.

O lipofilling é uma excelente técnica para corrigir alguns tipos de defeitos mamários. É útil não apenas no preenchimento de depressões e retrações mamárias decorrentes de cirurgia conservadora ou reconstrução, mas também apresenta potencial efeito de regeneração e reparo tecidual no tecido irradiado, através da ação das células tronco adiposas.

8. *Fotos de casos incluídos
no estudo*

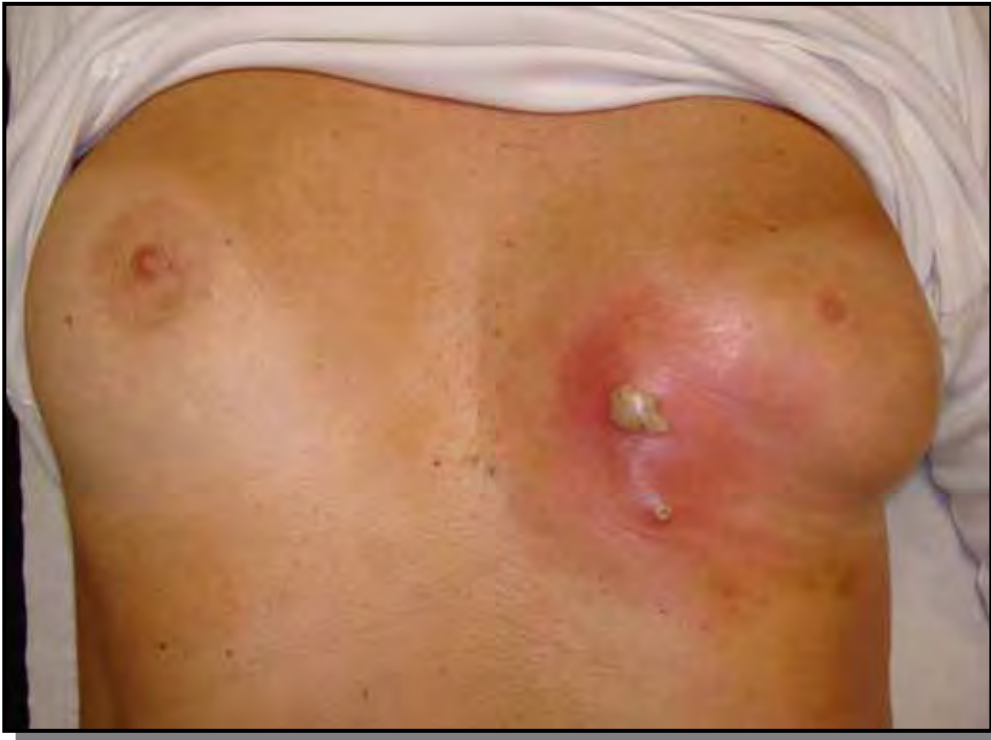

Figura 1: Foto de celulite pós-operatória.

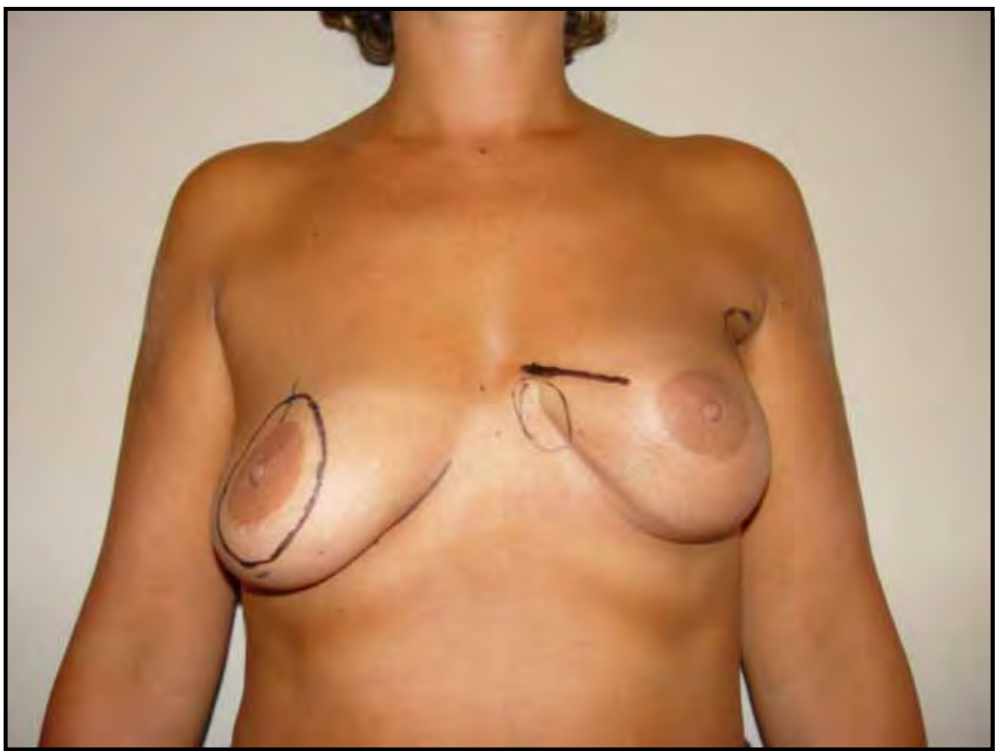


Figura 2: Foto de defeito após cirurgia conservadora da mama esquerda.

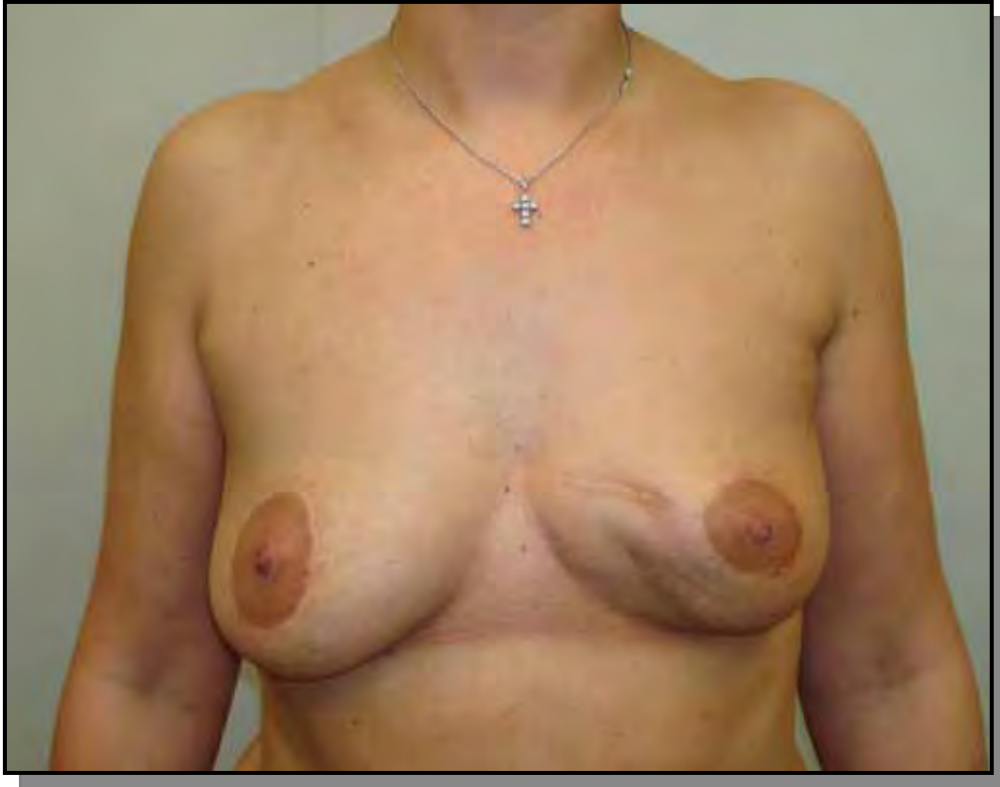

Figura 3: Foto de resultado após mastopexia periareolar direita e lipofilling de 130 gramas de tecido adiposo na mama esquerda sob anestesia geral.

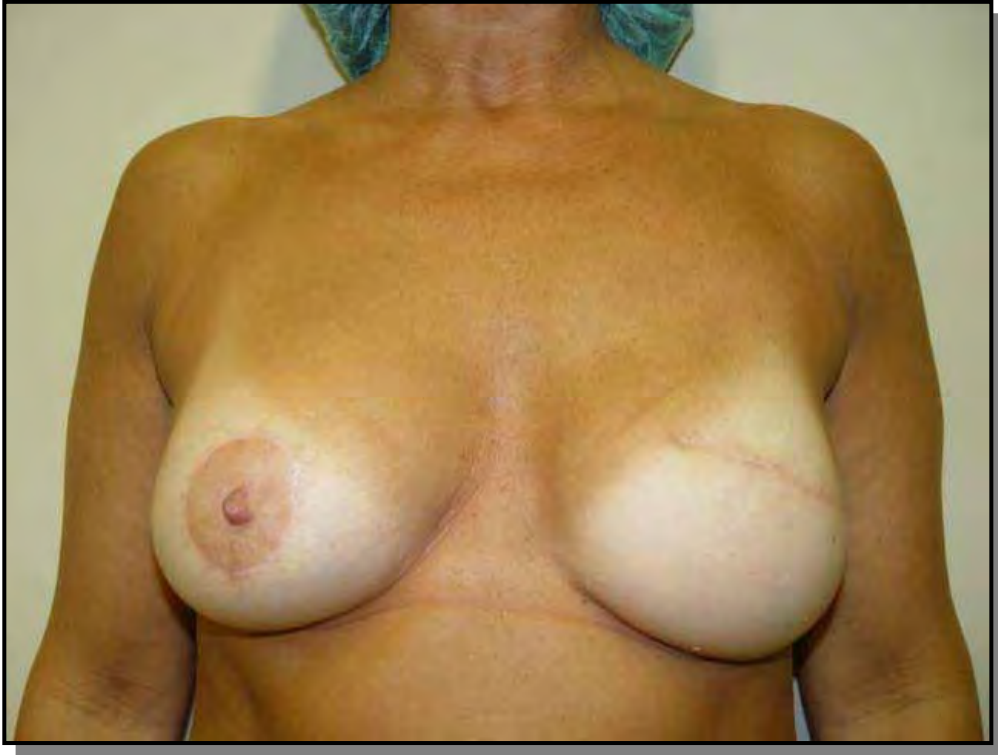

Figura 4: Foto de defeito no quadrante súpero-interno após reconstrução mamária imediata com prótese definitiva.

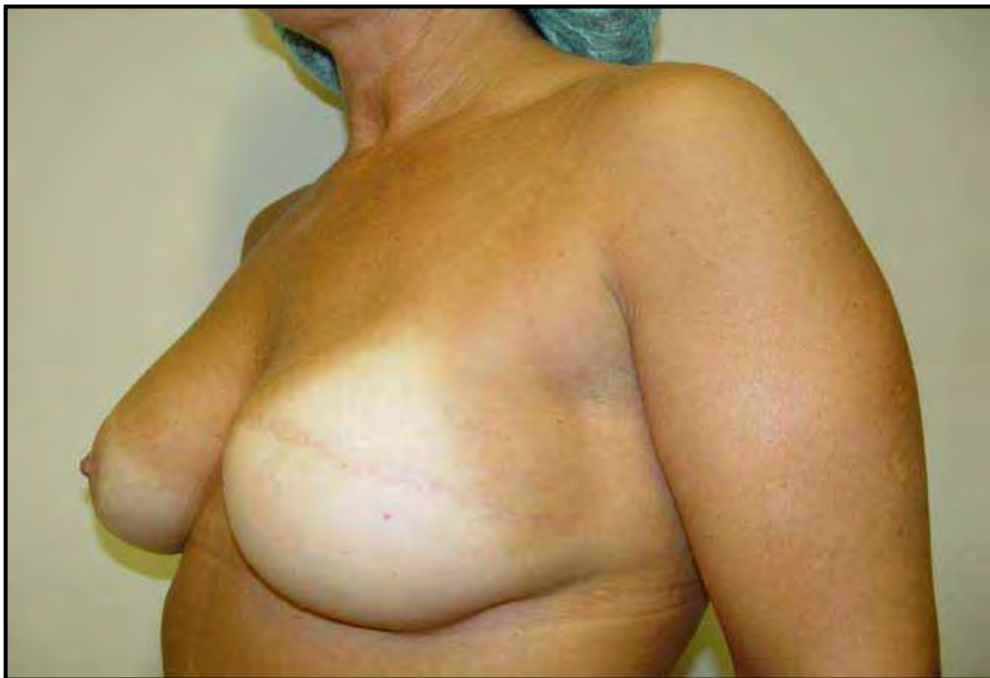

Figura 5: Foto do caso anterior em visão oblíqua.

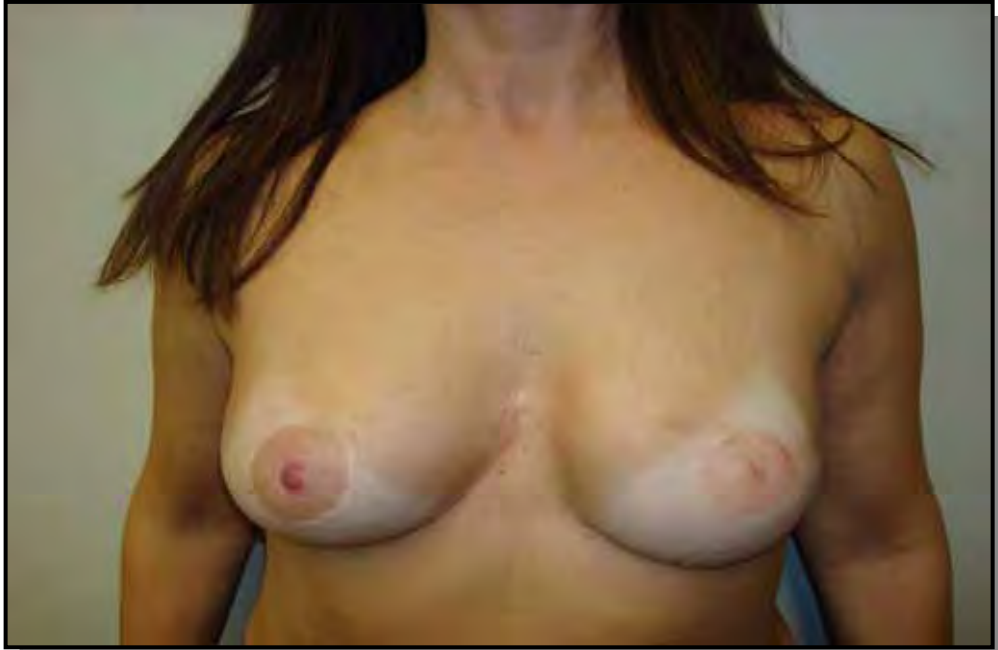

Figura 6: Foto do resultado após lipofilling de 50 gramas de tecido adiposo e reconstrução do complexo aréola e mamilo com anestesia local.

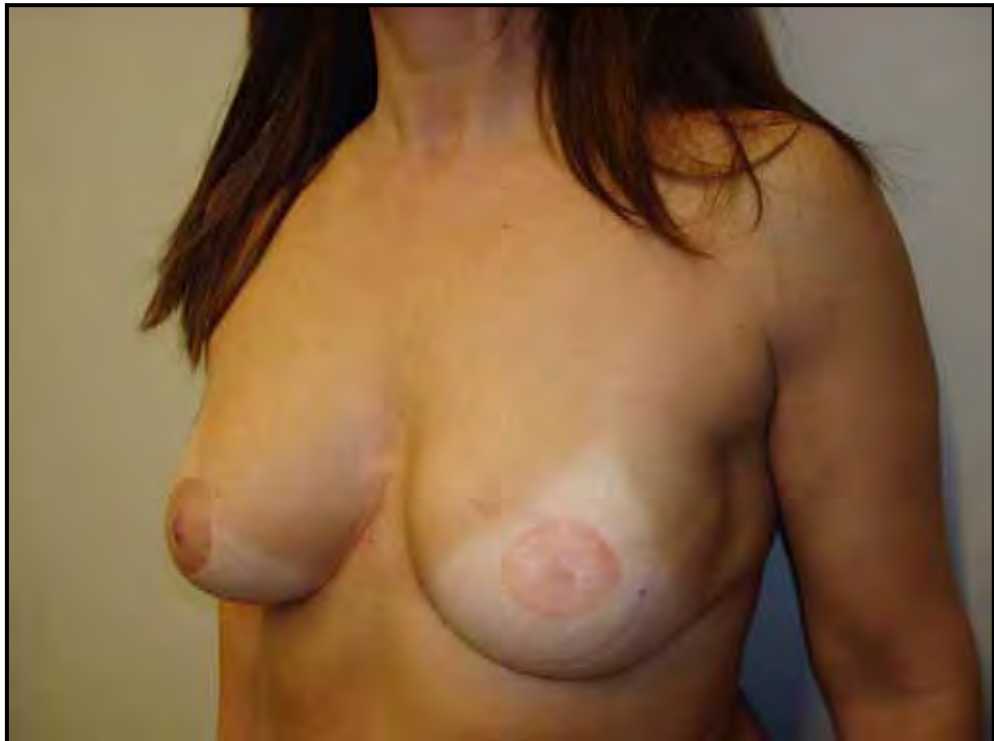

Figura 7: Foto do caso anterior com visão oblíqua.

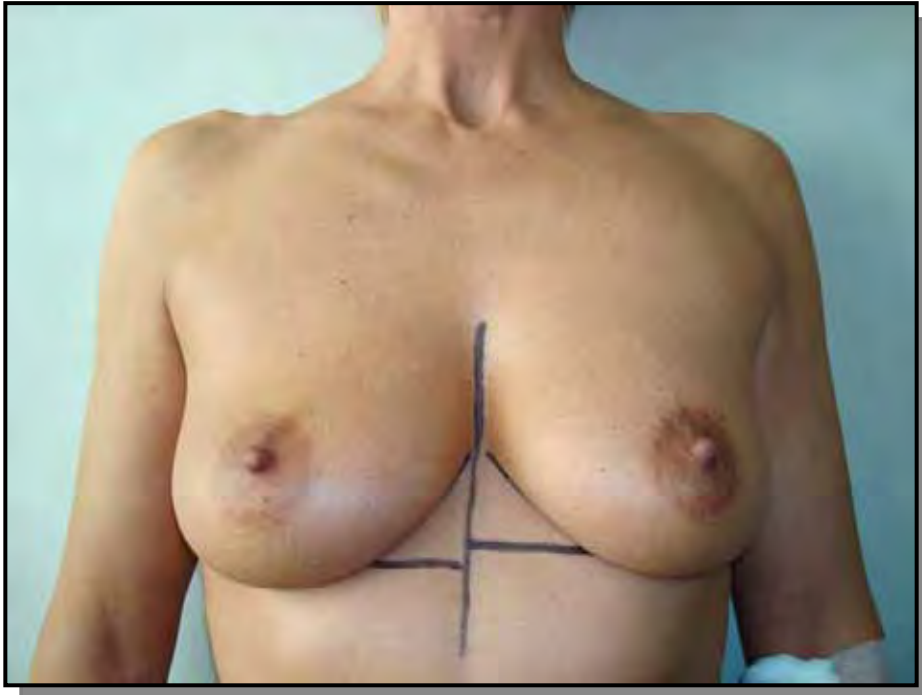

Figura 8: Foto pré-operatória de paciente com recidiva mamária à esquerda após quadrantectomia e radioterapia intra-operatória.

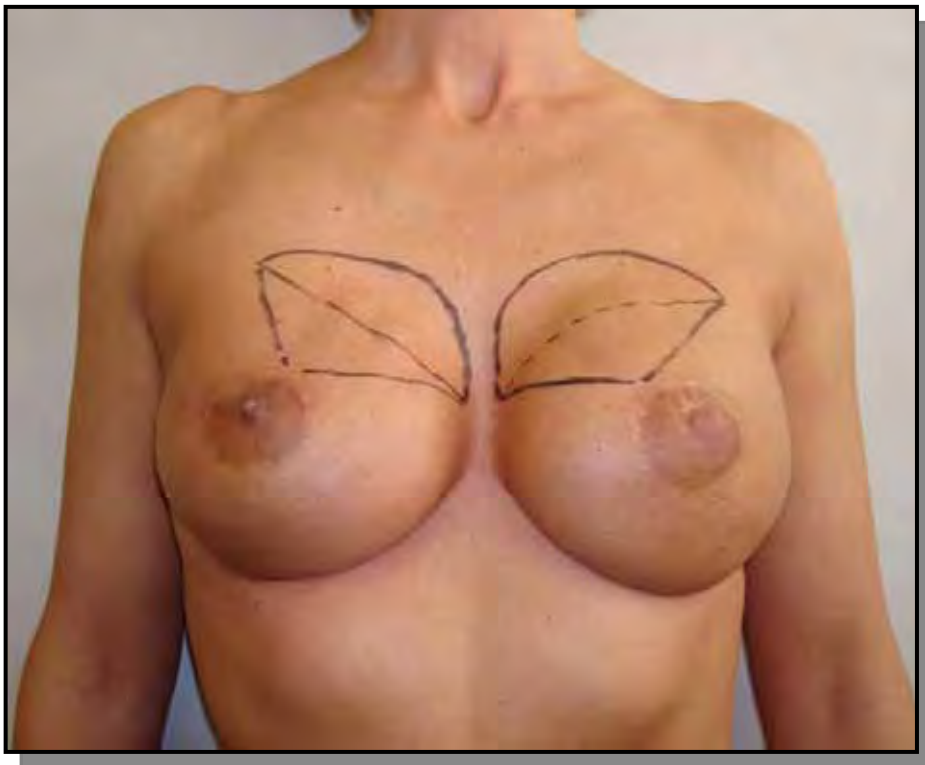


Figura 9: Foto do resultado após mastectomia esquerda com conservação do CAM e radioterapia intra-operatória no CAM, mastectomia profilática direita e reconstrução mamária bilateral com prótese definitiva. Paciente estava insatisfeita com as ondulações nos quadrantes súpero-interno (Rippling).

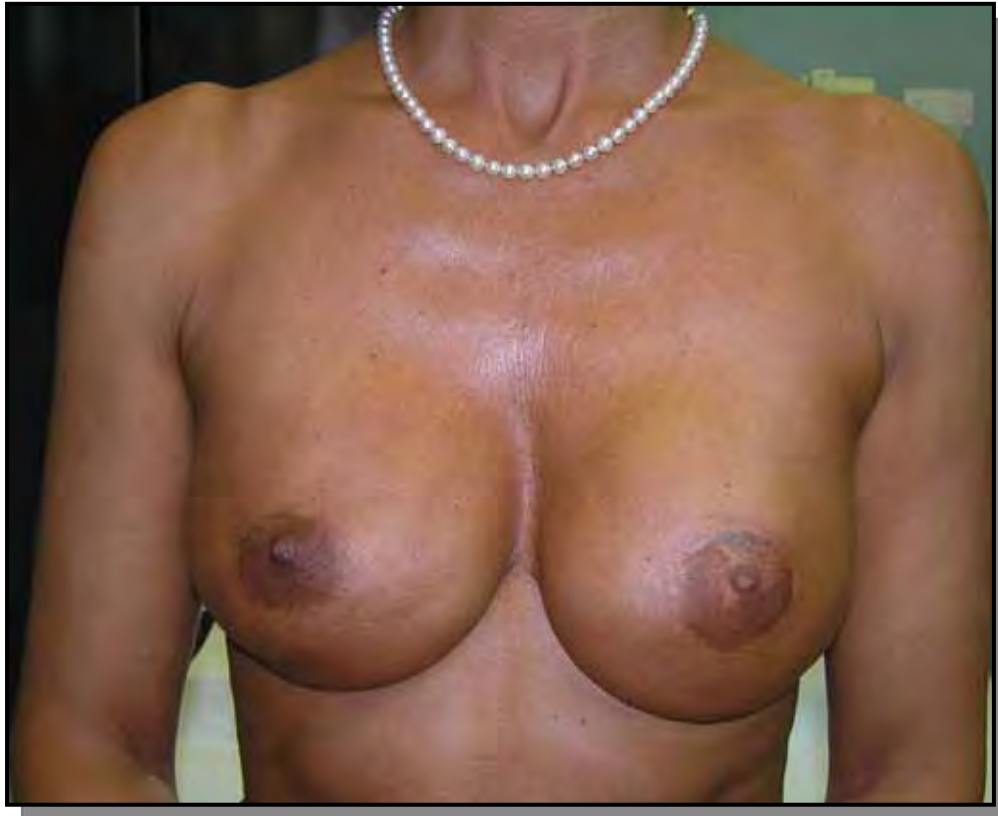

Figura 10: Foto do resultado após lipofilling de 30 gramas em cada mama, com anestesia local.

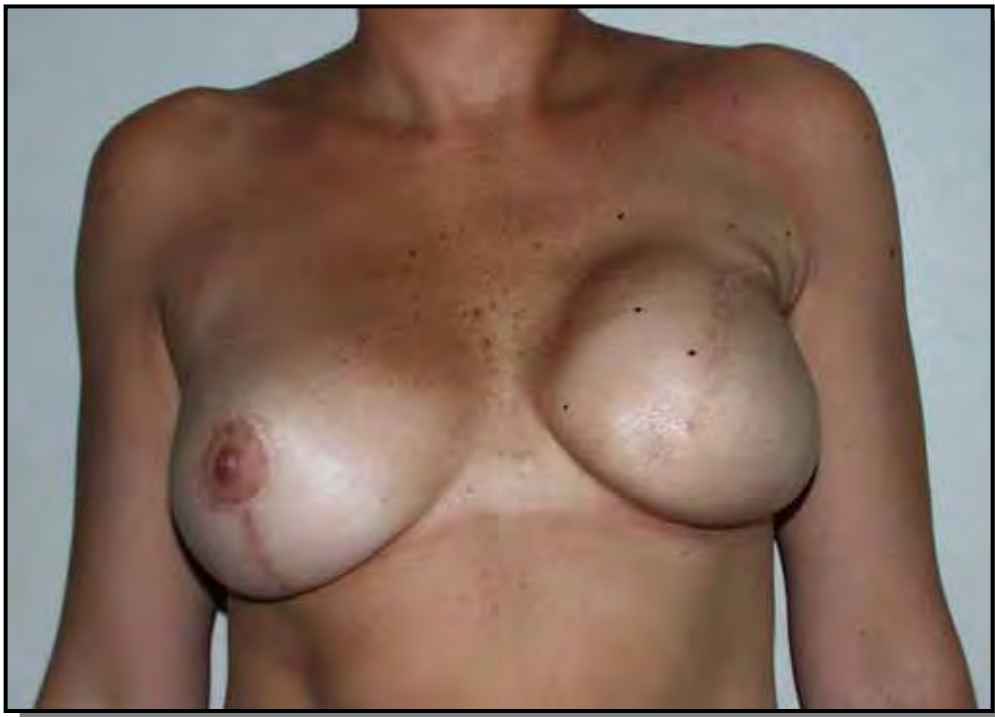

Figura 11: Foto de paciente com contratura periprotésica após mastectomia, reconstrução mamária imediata com prótese definitiva e radioterapia externa convencional.

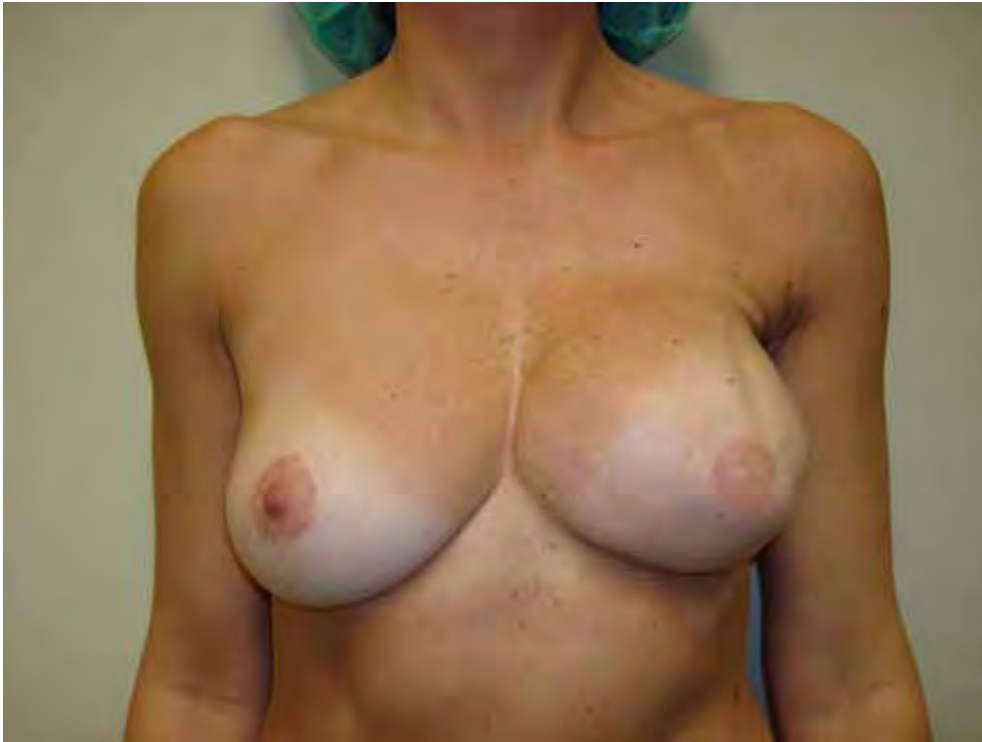

Figura 12: Foto de resultado após 4 sessões de lipofilling com anestesia local, com grande melhora da contratatura periprotésica.

9. Referências Bibliográficas

1. Veronesi U, Saccozzi R, Del Vecchio M, Banfi A, Clemente C, De Lena M, et al. Comparing radical mastectomy with quadrantectomy, axillary dissection, and radiotherapy in patients with small cancers of the breast. *The New England journal of medicine*. 1981;305(1):6-11. Epub 1981/07/02.
 2. Fisher B, Anderson S. Conservative surgery for the management of invasive and noninvasive carcinoma of the breast: NSABP trials. National Surgical Adjuvant Breast and Bowel Project. *World journal of surgery*. 1994;18(1):63-9. Epub 1994/01/01.
 3. Mojallal A, Foyatier JL. [Historical review of the use of adipose tissue transfer in plastic and reconstructive surgery]. *Annales de chirurgie plastique et esthetique*. 2004;49(5):419-25. Epub 2004/11/03. Historique de l'utilisation du tissu adipeux comme produit de comblement en chirurgie plastique.
 4. V. C. Plastischer Ersatz Der Brustdruse durch ein Lipom. *Zentralbl Chir*. 1895;27:72.
 5. Coleman SR. Hand rejuvenation with structural fat grafting. *Plastic and reconstructive surgery*. 2002;110(7):1731-44; discussion 45-7. Epub 2002/11/26.
 6. Coleman SR. Facial augmentation with structural fat grafting. *Clinics in plastic surgery*. 2006;33(4):567-77. Epub 2006/11/07.
 7. Coleman SR. Long-term survival of fat transplants: controlled demonstrations. *Aesthetic plastic surgery*. 1995;19(5):421-5. Epub 1995/09/01.
 8. Coleman SR. Facial recontouring with lipostructure. *Clinics in plastic surgery*. 1997;24(2):347-67. Epub 1997/04/01.
-

9. Coleman SR. Structural fat grafting: more than a permanent filler. *Plastic and reconstructive surgery*. 2006;118(3 Suppl):108S-20S. Epub 2006/08/29.
 10. Coleman SR, Saboeiro AP. Fat grafting to the breast revisited: safety and efficacy. *Plastic and reconstructive surgery*. 2007;119(3):775-85; discussion 86-7. Epub 2007/02/22.
 11. Spear SL, Wilson HB, Lockwood MD. Fat injection to correct contour deformities in the reconstructed breast. *Plastic and reconstructive surgery*. 2005;116(5):1300-5. Epub 2005/10/12.
 12. Pinsolle V, Chichery A, Grolleau JL, Chavoïn JP. Autologous fat injection in Poland's syndrome. *Journal of plastic, reconstructive & aesthetic surgery : JPRAS*. 2008;61(7):784-91. Epub 2008/01/08.
 13. Serra-Renom JM, Munoz-Olmo J, Serra-Mestre JM. Treatment of grade 3 tuberous breasts with Puckett's technique (modified) and fat grafting to correct the constricting ring. *Aesthetic plastic surgery*. 2011;35(5):773-81. Epub 2011/03/19.
 14. Coleman SR. Structural fat grafts: the ideal filler? *Clinics in plastic surgery*. 2001;28(1):111-9. Epub 2001/03/16.
 15. Rigotti G, Marchi A, Sbarbati A. Adipose-derived mesenchymal stem cells: past, present, and future. *Aesthetic plastic surgery*. 2009;33(3):271-3. Epub 2009/04/22.
 16. Rigotti G, Marchi A, Galie M, Baroni G, Benati D, Krampera M, et al. Clinical treatment of radiotherapy tissue damage by lipoaspirate transplant: a healing process mediated by adipose-derived adult stem cells. *Plastic and reconstructive surgery*. 2007;119(5):1409-22; discussion 23-4. Epub 2007/04/07.
-

17. Delay E, Delpierre J, Sinna R, Chekaroua K. [How to improve breast implant reconstructions?]. *Annales de chirurgie plastique et esthetique*. 2005;50(5):582-94. Epub 2005/09/20. Comment ameliorer les reconstructions mammaires par protheses?
 18. Amar O, Bruant-Rodier C, Lehmann S, Bollecker V, Wilk A. [Fat tissue transplant: restoration of the mammary volume after conservative treatment of breast cancers, clinical and radiological considerations]. *Annales de chirurgie plastique et esthetique*. 2008;53(2):169-77. Epub 2007/10/26. Greffe de tissu adipeux: restauration du volume mammaire apres traitement conservateur des cancers du sein, aspect clinique et radiologique.
 19. Delay E, Gosset J, Toussoun G, Delaporte T, Delbaere M. [Efficacy of lipomodelling for the management of sequelae of breast cancer conservative treatment]. *Annales de chirurgie plastique et esthetique*. 2008;53(2):153-68. Epub 2007/12/08. Efficacite du lipomodelage pour la correction des sequelles du traitement conservateur du cancer du sein.
 20. Chan CW, McCulley SJ, Macmillan RD. Autologous fat transfer--a review of the literature with a focus on breast cancer surgery. *Journal of plastic, reconstructive & aesthetic surgery : JPRAS*. 2008;61(12):1438-48. Epub 2008/10/14.
 21. Petit JY, Lohsiriwat V, Clough KB, Sarfati I, Ihrai T, Rietjens M, et al. The oncologic outcome and immediate surgical complications of lipofilling in breast cancer patients: a multicenter study--Milan-Paris-Lyon experience of 646 lipofilling procedures. *Plastic and reconstructive surgery*. 2011;128(2):341-6. Epub 2011/04/20.
 22. Rigotti G, Marchi A, Stringhini P, Baroni G, Galie M, Molino AM, et al. Determining the oncological risk of autologous lipoaspirate grafting for post-mastectomy breast reconstruction. *Aesthetic plastic surgery*. 2010;34(4):475-80. Epub 2010/03/25.
-

23. Rigotti G, Marchi A, Micciolo R, Baroni G. Autologous fat grafting in breast cancer patients. *Breast*. 2012. Epub 2012/07/04.
 24. Rigotti G, Marchi A, Micciolo PR, Baroni PG. On the safety of autologous fat grafting for breast reconstruction. *Plastic and reconstructive surgery*. 2012;130(1):206e-7e; author reply 8e. Epub 2012/06/30.
 25. Sarfati I, Ihrai T, Kaufman G, Nos C, Clough KB. Adipose-tissue grafting to the post-mastectomy irradiated chest wall: preparing the ground for implant reconstruction. *Journal of plastic, reconstructive & aesthetic surgery : JPRAS*. 2011;64(9):1161-6. Epub 2011/04/26.
 26. I. Coleman SIM, Riccardo F. *Fat injection: from filling to regeneration*. St. Louis, Missouri: Quality Medical Publishing. Inc.; 2009. 621-37 p.
 27. Delay E, Sinna R, Delaporte T, Flageul G, Tourasse C, Tousson G. Patient information before aesthetic lipomodeling (lipoaugmentation): a French plastic surgeon's perspective. *Aesthetic surgery journal / the American Society for Aesthetic Plastic surgery*. 2009;29(5):386-95. Epub 2009/10/15.
 28. Delay E, Sinna R, Chekaroua K, Delaporte T, Garson S, Toussoun G. Lipomodeling of Poland's syndrome: a new treatment of the thoracic deformity. *Aesthetic plastic surgery*. 2010;34(2):218-25. Epub 2009/11/11.
 29. Delay E, Gosset J, Toussoun G, Delaporte T, Delbaere M. [Post-treatment sequelae after breast cancer conservative surgery]. *Annales de chirurgie plastique et esthetique*. 2008;53(2):135-52. Epub 2007/12/14. *Sequelles therapeutiques du sein apres traitement conservateur du cancer du sein*.
 30. Delay E, Garson S, Tousson G, Sinna R. Fat injection to the breast: technique, results, and indications based on 880 procedures over 10 years. *Aesthetic surgery journal / the American Society for Aesthetic Plastic surgery*. 2009;29(5):360-76. Epub 2009/10/15.
-

31. Delay E, Delaporte T, Sinna R. [Breast implant alternatives]. *Annales de chirurgie plastique et esthetique*. 2005;50(5):652-72. Epub 2005/09/20. Alternatives aux protheses mammaires.
 32. Missana MC, Laurent I, Barreau L, Balleyguier C. Autologous fat transfer in reconstructive breast surgery: indications, technique and results. *European journal of surgical oncology : the journal of the European Society of Surgical Oncology and the British Association of Surgical Oncology*. 2007;33(6):685-90. Epub 2007/01/24.
 33. Rietjens M, De Lorenzi F, Rossetto F, Brenelli F, Manconi A, Martella S, et al. Safety of fat grafting in secondary breast reconstruction after cancer. *Journal of plastic, reconstructive & aesthetic surgery : JPRAS*. 2011;64(4):477-83. Epub 2010/08/10.
 34. Petit JY, Botteri E, Lohsiriwat V, Rietjens M, De Lorenzi F, Garusi C, et al. Locoregional recurrence risk after lipofilling in breast cancer patients. *Annals of oncology : official journal of the European Society for Medical Oncology / ESMO*. 2012;23(3):582-8. Epub 2011/05/26.
 35. Lohsiriwat V, Curigliano G, Rietjens M, Goldhirsch A, Petit JY. Autologous fat transplantation in patients with breast cancer: "silencing" or "fueling" cancer recurrence? *Breast*. 2011;20(4):351-7. Epub 2011/02/08.
 36. Petit JY, Clough K, Sarfati I, Lohsiriwat V, de Lorenzi F, Rietjens M. Lipofilling in breast cancer patients: from surgical technique to oncologic point of view. *Plastic and reconstructive surgery*. 2010;126(5):262e-3e. Epub 2010/11/03.
 37. Cordeiro PG. Discussion: The oncologic outcome and immediate surgical complications of lipofilling in breast cancer patients: a multicenter study--Milan-Paris-Lyon experience of 646 lipofilling procedures. *Plastic and reconstructive surgery*. 2011;128(2):347-8. Epub 2011/07/27.
-

38. Fraser JK, Hedrick MH, Cohen SR. Oncologic risks of autologous fat grafting to the breast. *Aesthetic surgery journal / the American Society for Aesthetic Plastic surgery*. 2011;31(1):68-75. Epub 2011/01/18.
 39. Donnenberg VS, Zimmerlin L, Rubin JP, Donnenberg AD. Regenerative therapy after cancer: what are the risks? *Tissue engineering Part B, Reviews*. 2010;16(6):567-75. Epub 2010/08/24.
 40. Zimmerlin L, Donnenberg AD, Rubin JP, Basse P, Landreneau RJ, Donnenberg VS. Regenerative therapy and cancer: in vitro and in vivo studies of the interaction between adipose-derived stem cells and breast cancer cells from clinical isolates. *Tissue engineering Part A*. 2011;17(1-2):93-106. Epub 2010/08/03.
 41. Seth AK, Hirsch EM, Kim JY, Fine NA. Long-term outcomes following fat grafting in prosthetic breast reconstruction: a comparative analysis. *Plastic and reconstructive surgery*. 2012. Epub 2012/07/11.
 42. Hyakusoku H, Ogawa R, Ono S, Ishii N, Hirakawa K. Complications after autologous fat injection to the breast. *Plastic and reconstructive surgery*. 2009;123(1):360-70; discussion 71-2. Epub 2009/01/01.
 43. Illouz YG, Sterodimas A. Autologous fat transplantation to the breast: a personal technique with 25 years of experience. *Aesthetic plastic surgery*. 2009;33(5):706-15. Epub 2009/06/06.
 44. de Blacam C, Momoh AO, Colakoglu S, Tobias AM, Lee BT. Evaluation of clinical outcomes and aesthetic results after autologous fat grafting for contour deformities of the reconstructed breast. *Plastic and reconstructive surgery*. 2011;128(5):411e-8e. Epub 2011/10/28.
 45. Coleman SR MR. *Fat injection: from filling to regeneration*. St. Louis, Missouri: Quality Medical Publishing, Inc.; 2009.
-

46. Tholpady SS, Aojanepong C, Llull R, Jeong JH, Mason AC, Futrell JW, et al. The cellular plasticity of human adipocytes. *Annals of plastic surgery*. 2005;54(6):651-6. Epub 2005/05/19.
 47. Kirkland JL, Hollenberg CH, Gillon WS. Age, anatomic site, and the replication and differentiation of adipocyte precursors. *The American journal of physiology*. 1990;258(2 Pt 1):C206-10. Epub 1990/02/01.
 48. Tchkonina T, Giorgadze N, Pirtskhalava T, Tchoukalova Y, Karagiannides I, Forse RA, et al. Fat depot origin affects adipogenesis in primary cultured and cloned human preadipocytes. *American journal of physiology Regulatory, integrative and comparative physiology*. 2002;282(5):R1286-96. Epub 2002/04/18.
 49. Zuk PA, Zhu M, Ashjian P, De Ugarte DA, Huang JI, Mizuno H, et al. Human adipose tissue is a source of multipotent stem cells. *Molecular biology of the cell*. 2002;13(12):4279-95. Epub 2002/12/12.
 50. Dragoo JL, Choi JY, Lieberman JR, Huang J, Zuk PA, Zhang J, et al. Bone induction by BMP-2 transduced stem cells derived from human fat. *Journal of orthopaedic research : official publication of the Orthopaedic Research Society*. 2003;21(4):622-9. Epub 2003/06/12.
 51. Nathan S, Das De S, Thambyah A, Fen C, Goh J, Lee EH. Cell-based therapy in the repair of osteochondral defects: a novel use for adipose tissue. *Tissue engineering*. 2003;9(4):733-44. Epub 2003/09/19.
 52. Planat-Benard V, Menard C, Andre M, Puceat M, Perez A, Garcia-Verdugo JM, et al. Spontaneous cardiomyocyte differentiation from adipose tissue stroma cells. *Circulation research*. 2004;94(2):223-9. Epub 2003/12/06.
 53. Planat-Benard V, Silvestre JS, Cousin B, Andre M, Nibbelink M, Tamarat R, et al. Plasticity of human adipose lineage cells toward endothelial cells: physiological and therapeutic perspectives. *Circulation*. 2004;109(5):656-63. Epub 2004/01/22.
-

54. Zuk PA, Zhu M, Mizuno H, Huang J, Futrell JW, Katz AJ, et al. Multilineage cells from human adipose tissue: implications for cell-based therapies. *Tissue engineering*. 2001;7(2):211-28. Epub 2001/04/17.
 55. Mizuno H, Zuk PA, Zhu M, Lorenz HP, Benhaim P, Hedrick MH. Myogenic differentiation by human processed lipoaspirate cells. *Plastic and reconstructive surgery*. 2002;109(1):199-209; discussion 10-1. Epub 2002/01/12.
 56. Huang JI, Zuk PA, Jones NF, Zhu M, Lorenz HP, Hedrick MH, et al. Chondrogenic potential of multipotential cells from human adipose tissue. *Plastic and reconstructive surgery*. 2004;113(2):585-94. Epub 2004/02/06.
 57. Tholpady SS, Llull R, Ogle RC, Rubin JP, Futrell JW, Katz AJ. Adipose tissue: stem cells and beyond. *Clinics in plastic surgery*. 2006;33(1):55-62, vi. Epub 2006/01/24.
 58. Rehman J, Traktuev D, Li J, Merfeld-Clauss S, Temm-Grove CJ, Bovenkerk JE, et al. Secretion of angiogenic and antiapoptotic factors by human adipose stromal cells. *Circulation*. 2004;109(10):1292-8. Epub 2004/03/03.
 59. Hausman GJ, Richardson RL. Adipose tissue angiogenesis. *Journal of animal science*. 2004;82(3):925-34. Epub 2004/03/23.
 60. Gimble JM. Adipose tissue-derived therapeutics. *Expert opinion on biological therapy*. 2003;3(5):705-13. Epub 2003/07/26.
 61. Awad HA, Halvorsen YD, Gimble JM, Guilak F. Effects of transforming growth factor beta1 and dexamethasone on the growth and chondrogenic differentiation of adipose-derived stromal cells. *Tissue engineering*. 2003;9(6):1301-12. Epub 2003/12/13.
 62. Hsu VM, Stransky CA, Bucky LP, Percec I. Fat Grafting's Past, Present, and Future: Why Adipose Tissue Is Emerging as a Critical Link to the Advancement of Regenerative Medicine. *Aesthetic surgery journal / the American Society for Aesthetic Plastic surgery*. 2012;32(7):892-9. Epub 2012/09/04.
-

63. Perez-Cano R, Vranckx JJ, Lasso JM, Calabrese C, Merck B, Milstein AM, et al. Prospective trial of adipose-derived regenerative cell (ADRC)-enriched fat grafting for partial mastectomy defects: the RESTORE-2 trial. *European journal of surgical oncology : the journal of the European Society of Surgical Oncology and the British Association of Surgical Oncology*. 2012;38(5):382-9. Epub 2012/03/20.
 64. Prantl L, Heine N. [Options for regenerative therapy in the field of breast surgery]. *Handchirurgie, Mikrochirurgie, plastische Chirurgie : Organ der Deutschsprachigen Arbeitsgemeinschaft fur Handchirurgie : Organ der Deutschsprachigen Arbeitsgemeinschaft fur Mikrochirurgie der Peripheren Nerven und Gefasse* 2012;44(2):103-11. Epub 2012/04/13. *Regenerative Therapieansätze im Bereich der Mammachirurgie*.
 65. Moseley TA, Zhu M, Hedrick MH. Adipose-derived stem and progenitor cells as fillers in plastic and reconstructive surgery. *Plastic and reconstructive surgery*. 2006;118(3 Suppl):121S-8S. Epub 2006/08/29.
 66. Coleman SR. Structural fat grafting. *Aesthetic surgery journal / the American Society for Aesthetic Plastic surgery*. 1998;18(5):386, 8. Epub 1998/09/01.
 67. Ullmann Y, Shoshani O, Fodor A, Ramon Y, Carmi N, Eldor L, et al. Searching for the favorable donor site for fat injection: in vivo study using the nude mice model. *Dermatologic surgery : official publication for American Society for Dermatologic Surgery [et al]*. 2005;31(10):1304-7. Epub 2005/09/29.
 68. Rohrich RJ, Sorokin ES, Brown SA. In search of improved fat transfer viability: a quantitative analysis of the role of centrifugation and harvest site. *Plastic and reconstructive surgery*. 2004;113(1):391-5; discussion 6-7. Epub 2004/01/07.
 69. Billings E, Jr., May JW, Jr. Historical review and present status of free fat graft autotransplantation in plastic and reconstructive surgery. *Plastic and reconstructive surgery*. 1989;83(2):368-81. Epub 1989/02/01.
-

70. Peer LA. Cell survival theory versus replacement theory. *Plast Reconstr Surg* (1946). 1955;16(3):161-8. Epub 1955/09/01.
 71. Wang L, Lu Y, Luo X, Fu MG, Hu X, Dong H, et al. [Cell-assisted lipotransfer for breast augmentation: a report of 18 patients]. *Zhonghua zheng xing wai ke za zhi = Zhonghua zhengxing waike zazhi = Chinese journal of plastic surgery*. 2012;28(1):1-6. Epub 2012/04/14.
 72. Daniels E. Cytori Therapeutics, Inc. *Regenerative medicine*. 2007;2(3):317-20. Epub 2007/05/22.
 73. Hicok KC, Hedrick MH. Automated isolation and processing of adipose-derived stem and regenerative cells. *Methods Mol Biol*. 2011;702:87-105. Epub 2010/11/18.
 74. Lin K, Matsubara Y, Masuda Y, Togashi K, Ohno T, Tamura T, et al. Characterization of adipose tissue-derived cells isolated with the Celution system. *Cytotherapy*. 2008;10(4):417-26. Epub 2008/06/25.
 75. Serra-Renom JM, Munoz-Olmo JL, Serra-Mestre JM. Fat grafting in postmastectomy breast reconstruction with expanders and prostheses in patients who have received radiotherapy: formation of new subcutaneous tissue. *Plastic and reconstructive surgery*. 2010;125(1):12-8. Epub 2010/01/06.
 76. Gosset J, Guerin N, Toussoun G, Delaporte T, Delay E. [Radiological evaluation after lipomodelling for correction of breast conservative treatment sequelae]. *Annales de chirurgie plastique et esthetique*. 2008;53(2):178-89. Epub 2007/12/07. Aspects radiologiques des seins traités par lipomodélage après séquelles du traitement conservateur du cancer du sein.
 77. Wang CF, Zhou Z, Yan YJ, Zhao DM, Chen F, Qiao Q. Clinical analyses of clustered microcalcifications after autologous fat injection for breast augmentation. *Plastic and reconstructive surgery*. 2011;127(4):1669-73. Epub 2010/12/29.
-

78. Veber M, Tourasse C, Toussoun G, Moutran M, Mojallal A, Delay E. Radiographic findings after breast augmentation by autologous fat transfer. *Plastic and reconstructive surgery*. 2011;127(3):1289-99. Epub 2011/03/03.
 79. Del Vecchio DA. Discussion: Clinical analyses of clustered microcalcifications after autologous fat injection for breast augmentation. *Plastic and reconstructive surgery*. 2011;127(4):1674-6. Epub 2011/04/05.
 80. Hogge JP, Robinson RE, Magnant CM, Zuurbier RA. The mammographic spectrum of fat necrosis of the breast. *Radiographics : a review publication of the Radiological Society of North America, Inc*. 1995;15(6):1347-56. Epub 1995/11/01.
 81. Abboud M, Vadoud-Seyedi J, De Mey A, Cukierfajn M, Lejour M. Incidence of calcifications in the breast after surgical reduction and liposuction. *Plastic and reconstructive surgery*. 1995;96(3):620-6. Epub 1995/09/01.
 82. Danikas D, Theodorou SJ, Kokkalis G, Vasiou K, Kyriakopoulou K. Mammographic findings following reduction mammoplasty. *Aesthetic plastic surgery*. 2001;25(4):283-5. Epub 2001/09/25.
 83. Leibman AJ, Styblo TM, Bostwick J, 3rd. Mammography of the postreconstruction breast. *Plastic and reconstructive surgery*. 1997;99(3):698-704. Epub 1997/03/01.
 84. Pierrefeu-Lagrange AC, Delay E, Guerin N, Chekaroua K, Delaporte T. [Radiological evaluation of breasts reconstructed with lipomodelling]. *Annales de chirurgie plastique et esthétique*. 2006;51(1):18-28. Epub 2005/12/13. Evaluation radiologique des seins reconstruits ayant bénéficié d'un lipomodélage.
 85. Mendelson EB. Evaluation of the postoperative breast. *Radiologic clinics of North America*. 1992;30(1):107-38. Epub 1992/01/01.
-

86. Kneeshaw PJ, Lowry M, Manton D, Hubbard A, Drew PJ, Turnbull LW. Differentiation of benign from malignant breast disease associated with screening detected microcalcifications using dynamic contrast enhanced magnetic resonance imaging. *Breast*. 2006;15(1):29-38. Epub 2005/07/09.
 87. Veber M, Tourasse C, Moutran M, Mojallal A. Clinical analyses of clustered microcalcifications after autologous fat injection for breast augmentation. *Plastic and reconstructive surgery*. 2012;129(1):168e-9e; author reply 9e-70e. Epub 2011/12/22.
 88. Bircoll M. Clinical analyses of clustered microcalcifications after autologous fat injection for breast augmentation. *Plastic and reconstructive surgery*. 2011;128(6):779e; author reply e-80e. Epub 2011/11/19.
 89. Andarawewa KL, Motrescu ER, Chenard MP, Gansmuller A, Stoll I, Tomasetto C, et al. Stromelysin-3 is a potent negative regulator of adipogenesis participating to cancer cell-adipocyte interaction/crosstalk at the tumor invasive front. *Cancer research*. 2005;65(23):10862-71. Epub 2005/12/03.
 90. Celis JE, Moreira JM, Cabezon T, Gromov P, Friis E, Rank F, et al. Identification of extracellular and intracellular signaling components of the mammary adipose tissue and its interstitial fluid in high risk breast cancer patients: toward dissecting the molecular circuitry of epithelial-adipocyte stromal cell interactions. *Molecular & cellular proteomics : MCP*. 2005;4(4):492-522. Epub 2005/02/08.
 91. Elliott BE, Tam SP, Dexter D, Chen ZQ. Capacity of adipose tissue to promote growth and metastasis of a murine mammary carcinoma: effect of estrogen and progesterone. *International journal of cancer Journal international du cancer*. 1992;51(3):416-24. Epub 1992/05/28.
 92. Iyengar P, Combs TP, Shah SJ, Gouon-Evans V, Pollard JW, Albanese C, et al. Adipocyte-secreted factors synergistically promote mammary tumorigenesis through induction of anti-apoptotic transcriptional programs and proto-oncogene stabilization. *Oncogene*. 2003;22(41):6408-23. Epub 2003/09/26.
-

93. Kilroy GE, Foster SJ, Wu X, Ruiz J, Sherwood S, Heifetz A, et al. Cytokine profile of human adipose-derived stem cells: expression of angiogenic, hematopoietic, and pro-inflammatory factors. *Journal of cellular physiology*. 2007;212(3):702-9. Epub 2007/05/05.
 94. Manabe Y, Toda S, Miyazaki K, Sugihara H. Mature adipocytes, but not preadipocytes, promote the growth of breast carcinoma cells in collagen gel matrix culture through cancer-stromal cell interactions. *The Journal of pathology*. 2003;201(2):221-8. Epub 2003/10/01.
 95. Nkhata KJ, Ray A, Schuster TF, Grossmann ME, Cleary MP. Effects of adiponectin and leptin co-treatment on human breast cancer cell growth. *Oncology reports*. 2009;21(6):1611-9. Epub 2009/05/09.
 96. Perera CN, Spalding HS, Mohammed SI, Camarillo IG. Identification of proteins secreted from leptin stimulated MCF-7 breast cancer cells: a dual proteomic approach. *Exp Biol Med (Maywood)*. 2008;233(6):708-20. Epub 2008/04/15.
 97. Rahimi N, Tremblay E, McAdam L, Roberts A, Elliott B. Autocrine secretion of TGF-beta 1 and TGF-beta 2 by pre-adipocytes and adipocytes: a potent negative regulator of adipocyte differentiation and proliferation of mammary carcinoma cells. *In vitro cellular & developmental biology Animal*. 1998;34(5):412-20. Epub 1998/06/25.
 98. Schaffler A, Scholmerich J, Buechler C. Mechanisms of disease: adipokines and breast cancer - endocrine and paracrine mechanisms that connect adiposity and breast cancer. *Nature clinical practice Endocrinology & metabolism*. 2007;3(4):345-54. Epub 2007/03/23.
 99. Wiseman BS, Werb Z. Stromal effects on mammary gland development and breast cancer. *Science*. 2002;296(5570):1046-9. Epub 2002/05/11.
-

10. Artigos científicos publicados

10.1 ARTIGO 1

“Safety of fat grafting in secondary breast reconstruction after cancer”. *J Plast Reconstr Aesthet Surg*. 2011 Apr;64(4):477-83. Rietjens M, De Lorenzi F, Rossetto F, Brenelli F, Manconi A, Martella S, Intra M, Venturino M, Lohsiriwat V, Ahmed Y, Petit JY.

Journal of Plastic, Reconstructive & Aesthetic Surgery (2011) 64, 477–484



Safety of fat grafting in secondary breast reconstruction after cancer

M. Rietjens^{a,*}, F. De Lorenzi^a, F. Rossetto^a, F. Brenelli^a,
A. Manconi^a, S. Martella^a, M. Intra^b, M. Venturino^c, V. Lohsiriwat^{a,d},
Y. Ahmed^a, J.Y. Petit^a

^a Department of Plastic and Reconstructive Surgery, European Institute of Oncology (EIO), Via Ripamonti, 435, 20141 Milan, Italy

^b Department of Breast Surgery, European Institute of Oncology (EIO), Via Ripamonti, 435, 20141 Milan, Italy

^c Department of Anaesthesiology and Intensive Care Unit, European Institute of Oncology (EIO), Via Ripamonti, 435, 20141 Milan, Italy

^d Department of Surgery, Siriraj hospital, Mahidol University, Bangkok, Thailand

Received 3 March 2010; accepted 28 June 2010

KEYWORDS

Breast;
Autologous fat
injection;
Coleman technique;
Breast reconstructive
surgery;
Conservative treat-
ment;
surgical complications

Summary *Background:* Fat grafting is largely used to correct soft-tissue defects in any region of the human body. This study analysed its safety when the technique is used to correct defects after breast-cancer reconstruction.

Methods: A total of 158 patients who underwent 194 breast fat grafting procedures were analysed. Almost all patients (98%) had a personal history of breast cancer: conservative surgery or mastectomy with breast reconstruction. In all cases, fat grafting was performed according to the Coleman's technique by a single surgeon.

Results: Immediate complications included liponecrosis and infection in seven cases (3.6%) that required only daily dressings and oral antibiotics administration. In cases of fat grafting after conservative surgery, only four patients (5.9%) showed minor alterations in the postoperative mammograms, consisting of the appearance of benign images.

Conclusion: Breast fat grafting can be a good solution to repair defects after breast-cancer treatment and reconstruction, and can reduce the indication for more extensive surgeries such as myocutaneous flaps. Postoperative complication rates are very low and there is little alteration in follow-up mammograms. Two points remain unclear – How much of the fat is absorbed after grafting and the potential risk of local 'dormant' tumour cells being stimulated to induce a local recurrence.

© 2010 British Association of Plastic, Reconstructive and Aesthetic Surgeons. Published by Elsevier Ltd. All rights reserved.

* Corresponding author.

E-mail address: mario.rietjens@ieo.it (M. Rietjens).

Breast-cancer treatment is now currently evaluated on cure-rate figures and quality of life. Quality of life is measured by psychological studies based on questionnaires and by cosmetic results after reconstructive surgery aiming at decreasing the disabling effects of the ablative surgery. Oncoplasty techniques, autologous flaps and implants are commonly used plastic surgery techniques in patients undergoing breast reconstruction. Lipofilling is a currently used technique to correct soft-tissue defects.¹⁻⁶ The lipofilling technique is also indicated in many types of breast surgeries. For cosmetic purposes, some surgeons use this technique for breast augmentation for the sole treatment or for correction of the capsular deformity.⁷⁻⁹ For reconstruction, some authors favour this procedure to correct secondary defects after breast-cancer reconstruction,¹⁰⁻¹⁴ or to treat tissue damages and deformities after radiotherapy.¹⁵

In 2005, we started the use of breast fat grafting (BFG) at our Institute to correct secondary defects after breast-cancer reconstruction. We carefully followed up all the patients to answer the following questions. (1) What factors increase the risk of postoperative complications after BFG? (2) Is it feasible to perform BFG under local anaesthesia? (3) Will BFG after breast-conservative surgery (BCS) produce new microcalcification, disturbing the oncological follow-up using mammograms? (4) Will BFG after breast-cancer treatment increase local recurrence (LR) rate?

Materials and methods

Patient selection

From October 2005 to July 2008, we prospectively evaluated 158 patients who underwent 194 BFG procedures. All patients had been submitted to a previous breast surgical procedure at our Institute either for oncological (155 patients) or functional reasons (three patients), which led to an unaesthetic breast defect (Diagram 1). All of the post-oncological treatment defects included in our series were quadrantectomies. All patients were visited and operated by a single surgeon. Only patients who were free of local breast disease were considered eligible for the procedure after an appropriate clinical and radiological breast evaluation. The presence of bone-stable distant metastasis was not an exclusion criterion. All patients who previously received loco-regional radiotherapy and those who did not receive loco-regional radiotherapy were included in this study.

Preoperative evaluation

All patients were evaluated preoperatively with clinical and radiological breast examinations. Bilateral mammography and breast ultrasonography (US) were requested for all patients, excluding mammography to the reconstructed breasts.

After detailed information about the procedure was explained, each patient gave written informed consent and agreed to undergo the surgery. Preoperative photographs were taken in all cases and all the breast defects were

measured by a calliper or ruler on its two major axis, and, finally, on its depth by an approximate and empirical measurement (Figures 1 and 2). In cases of multiple defects, they were measured and named as defect 1, 2, 3 and so on.

Surgical technique

The procedure was performed under local or general anaesthesia, depending on the patient's clinical conditions and risks. Local anaesthesia was our preference, while general anaesthesia was recommended in cases of harvesting a large amount of fat tissue. We also selected general anaesthesia when the patient preferred it. The selected donor site was infiltrated with Klein's solution. It consists of 1 cc of epinephrine diluted in 500 cc of 0.001% lactate ringer solution (LRS). The 50 cc of Mepivacaine is added in the solution if surgeon performed under local anaesthesia. The amount of solution injected was double the volume of pre-estimated fat tissue requirement.

The whole procedure of fat harvesting and 'lipofilling' was performed according to the Coleman's technique¹ with minimal modifications, as described in the following text. After the injection of the diluted solution, two-hole, 3-mm diameter Coleman's cannula with a blunt tip attached to a 10-cc Luer-Lock syringe was inserted through the small incision. A combination of slight negative pressure and the curetting action of the cannula through the tissues allows fat harvesting. The fat was harvested until we reached the pre-estimated defect volume. Then we took the fat to centrifuge at 3000 rpm for 3 min until the serum and oily components were separated from the adipose tissue. The cellular component was immediately transferred to a 1-cc Luer-Lock syringe and prepared for injection. Prepared cellular component was then injected into the defect area through a blunt Coleman's cannula. Retrograde injection with thin-layer and multiple-tunnel technique was performed. We avoided putting fat as an excessive depot, which may result in liponecrosis and graft loss.

We judged the amount of fat needed to be grafted in each individual case, based on the tissue quality, shape and size of the defect. We preferred more than one procedure

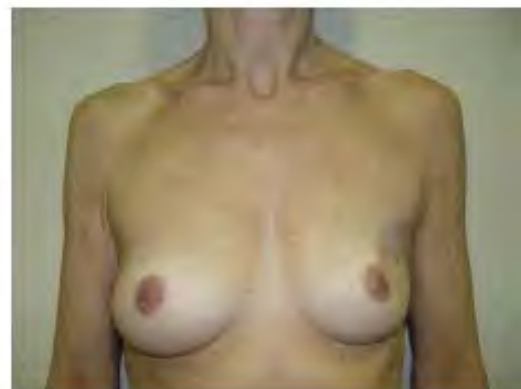

Figure 1 Defect in the upper outer quadrant after conservative surgery for breast cancer and postoperative radiotherapy.

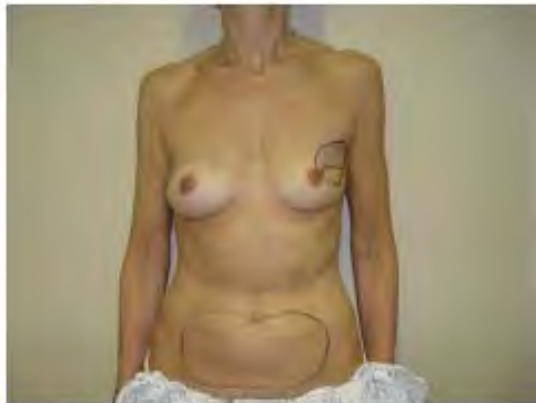

Figure 2 Preoperative drawings show the breast defects area that will receive the fat grafting and the periumbilical (abdominal) donor site.

in irradiated breasts, small or deep defects in which there was a limited space for grafting.

Local factors can influence our technique approach for individual cases, especially in scarred and irradiated tissues. We broke the fibrotic scar with a sharp cannula to create the space for grafting. However, this group is more likely to have a second procedure and the second procedure in this group is usually easier as the tissue quality is improved by the first lipofilling procedure.

We usually perform lipofilling after completion of oncologic and/or reconstructive intervention, radiation and chemotherapy. The average interval between oncologic interventions to lipofilling interventions is 35.2 months. In case of radiation, we wait until at least 6 months after completion of radiotherapy.

Results

Mean age of the patients at the time of fat grafting was 48 (range 22–70 years) years and mean follow-up time was 18.3 (range 6–49) months. Three out of 158 patients (2%) included in this series had no history of breast cancer: one case of Poland's syndrome, one case after surgery for gynaecomastia and one case after aesthetic breast augmentation. BFG was performed under local anaesthesia for 158 procedures and under general anaesthesia in 36 cases.

BFG was performed after conservative surgery in 77 cases (62 patients) and after mastectomy and reconstruction in 114 cases (93 patients). The tumour staging and type of breast reconstruction prior to the lipofilling procedure are demonstrated in Tables 1 and 2, respectively.

Most of the patients required only one procedure. Only 26 of them (16.8%) underwent more than one procedure, and one of them underwent five procedures. Among 158 patients, there were 96 patients who previously received loco-regional radiotherapy and 62 patients who did not.

Most of the cases required just one donor site, although some patients needed multiple sites. The preferred donor area was the abdomen (143 times), thighs (24), hips (18), inner part of the knee (six) and combined sites abdomen

Table 1 Tumor Staging

Stage	Quadrantectomy	Mastectomy
0	11	23
I	28	26
IIA	16	21
IIB	3	12
IIIA	2	12
IIIB	0	6
IV ^a	2	1
Total	77	114

^a Note : Three bone metastasis.

and hips (one). In one patient, who had no oncological background, fat was harvested from the lateral mammary tissue. Concerning the technique, the mean volume of Klein's solution injected into the abdomen was 360 cc and 240 cc in the thighs, hips and knees.

The mean estimated volume of the main defect was 19.7 cc and the mean volume of fatty tissue injected was 48 cc, varying from 6 to a maximum of 183 cc. The mean volume of the second and the third defects was 5.7 cc and 1.7 cc, respectively, whilst the mean injected volume was 23 cc and 12.5 cc, respectively.

There were no complications in any of the donor sites. Of the seven immediate complications (3.6%), there were five liponecrosis, one cellulitis and one abscess (Table 3). All cases were conservatively managed with no further complications. Liponecrosis was drained in the outpatient clinics and the two cases of cellulitis were treated with systemic oral antibiotic therapy, with no need of hospitalisation (Figure 3). Among seven immediate complications, there were six patients who previously received loco-regional radiotherapy and one patient who did not receive it. The only one who did not receive loco-regional radiotherapy had liponecrosis.

A minimum of at least one follow-up visit occurred 6 months after the procedure (Figure 4). We focused on safety in terms of early complication and oncological

Table 2 Operative and reconstructive procedures

Type of oncologic resection	Type of reconstruction	Total
Mastectomy (114 cases)	Prosthesis	105
	LD flap	5
	Pedicled TRAM flap	3
	Pedicled TRAM flap with prosthesis	2
Quadrantectomy (77 cases)	Oncoplasty/Parenchymal relocation	60
	Prosthesis	10
	Alone	5
	LD flap	1
		191

LD flap – Lattissimus dorsi flap.

TRAM flap – Transverse rectus abdominis musculocutaneous flap.

Table 3 Complications

Complication	Quadrantectomy		Mastectomy		Total
	77		114		
	With RT ^a	Without RT ^a	With RT ^a	Without RT ^a	
No	67	7	50	60	184
Yes	3		4		7
liponecrosis	1	—	3	1	5
cellulitis	1	—	—	—	1
abscess	1	—	—	—	1
Total	70	7	53	61	191

^a Note: RT - radiotherapy.

aspect. The oncological follow-up was based on clinical examination and mammographic finding. We particularly assessed if the lipofilling produced a mammographic change. Every case has been examined by mammogram pre- and post-lipofilling procedure.

Particular attention was paid to those patients who have had a BCS. Although this procedure is previously reported to increase the number of breast calcifications or oily cysts, and, therefore, may cause some problems to the radiologist or breast surgeon in the management of those patients, we observed only few cases of breast-image alteration after BFG in this subgroup of patients. In only four cases (5.2%) out of 77 having mammograms were abnormalities present after grafting, compared with the preoperative examination. They were classified as benign images not requiring further investigations. For eight cases (10.4%), we do not have postoperative information. These patients underwent BFG only 6 months earlier and had not done the postoperative mammography yet. In 54 cases (72.7%), mammograms were normal before and after the procedure. In four cases (5.2%), preoperative mammograms were abnormal but of benign appearance and these images were not present anymore in postoperative mammograms. In the remaining 6.5% of the control mammograms, benign microcalcifications were present before and after the procedure.

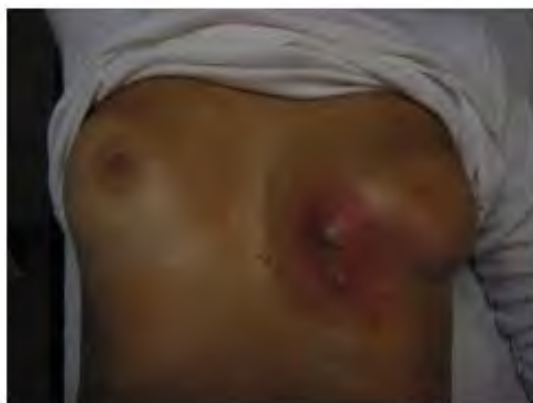

Figure 3 Postoperative view of a case of abscess cellulites, the main complication of this technique.



Figure 4 A 6 months postoperative follow-up after 70gr. fat grafting under local anaesthesia.

One local relapse (LR) was observed at follow-up, probably misdiagnosed at the time of the fat grafting procedure. Diagnosis was made about 2 weeks after BFG in a young patient who already had a LR after breast-conserving treatment. The early LR after grafting in the high-risk patient is unlikely to have been caused by the procedure. Three patients had bone metastasis before the procedure. The lesions were static during the follow-up. The mean interval between the oncologic surgery and the fat grafting was of 50.5 (range 5.5–170 months) months in the BCS group. In general, nine patients failed to attend the last 6-month follow-up and could not be reached, although the previous records showed that they were in disease-free stages.

Discussion

BFG is a promising technique to improve aesthetic results after BCS and breast reconstructions after mastectomy with prostheses or autologous tissues.^{1–6,8,30,33,36} It is a simple procedure that can avoid more extensive surgery such as myocutaneous flaps, and it is often used to correct small defects after breast-cancer reconstruction.

Although this technique is not new, its use to correct breast defects has only recently been introduced. We report one of the largest series of BFG after breast-cancer treatment. We have used BGF in treating one or more

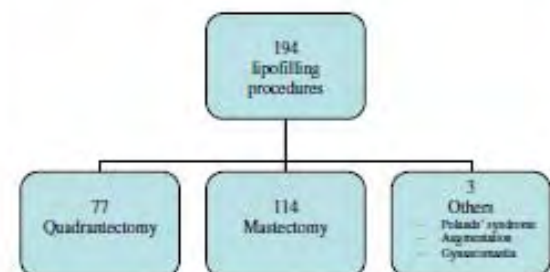


Diagram 1 Patients flow diagram.

breast defects in a single surgical setting. Moreover, it is very simple and very reproducible, and, in most of the cases, can be performed under local anaesthesia, as demonstrated in this present study. It is less invasive than any other surgical technique and we only had minor complications, which were very simple to manage. In our opinion, this complication rate can be reduced, because it was probably due to a 'learning curve' with this technique. In our early cases, we feel that excess anaesthetic fluid injected around the defect could have caused fat 'dilution' and consequent problems to get normal fat graft takes. Other authors also^{13,16} showed complications rates from zero to 5%.

The other significant factor to cause complications is the presence of loco-regional radiotherapy. We had a total of seven immediate complications, six of whom had radiotherapy. This finding suggests we should be cautious about the patients who have previously received loco-regional radiotherapy and warn them about the higher risk of complications.

The surgical result depends on two major factors; first is the surgical technique and the second is the tissue quality. The density and the layer of the grafted fat are important factors, which can contribute to the complications because overgrafting and/or overcondensing will result in insufficient vascularisation and liponecrosis.

We avoid creating a lake of fat by injecting the fat graft in retrograde fashion in a separate column of fat in the best-available healthy tissue. Our data showed a higher complication rate in the irradiated group compared with the non-irradiated group (6.9% and 1.6%, respectively). However, the percentage of the total complication is as low as 3.6%. (See Table 3.)

We avoid performing BFG in patients receiving chemotherapy because they tend to have low immunological defence and, therefore, complication rate can be increased. Lipofilling is delayed until after completion of chemotherapy treatment.

We did not perform lipofilling as a 'sole treatment' for the BCS and/or mastectomy group. In fact, our patients have been reconstructed with prosthetic, autologous tissue or other oncoplastic techniques (e.g., reduction mammoplasty and parenchymal relocation) as shown in 'Operative procedure table'. As a result, the size of the defects is not huge, and we mainly perform lipofilling as a 'secondary reconstruction' to correct the unsatisfactory aesthetic result from primary reconstruction.

In our series, more than 80% of the cases were performed under local anaesthesia in day hospital, because the treated defects were not too large and required approximate 50 cc of purified fat injected. The procedure lasts about 1 h and the patient can be discharged 2 h after the end of surgery. This technique is technically easy and simple with cost benefits.

Radiological findings after BFG and consequent abnormalities are topics of debate, especially in patients with previous BCS. Although some authors showed that it is possible to differentiate calcifications resulting due to fat necrosis from calcifications related to breast cancer,¹⁷⁻²⁷ this is a critical topic that we were willing to evaluate. Actually, we found no significant increase in abnormal breast images after BFG. In the group of BCS, only 5.2% of

the patients who had a prior normal mammogram developed an abnormal one after the procedure. None of them were considered to have pathologically worrying images. They were scheduled for a radiological control every 6 months without requiring further investigation. In the majority of cases, mammograms were normal before and after grafting. The elimination of the oily component in the lipoaspirate content may reduce calcifications if compared with others' techniques of fat grafting.²⁸⁻³¹ In 5.2% of the cases, there were some benign images (calcifications) that disappeared after the procedure. In our opinion, this finding had no correlation with the procedure, and it could be just a misdiagnosis.

We need to be aware of the potential oncological risk of breast-cancer recurrence as, in BFG, we graft more cellular components. A wealth of evidence has been provided which shows that adipocytes and pre-adipocytes are involved in tumour-stromal interaction through autocrine, paracrine and exocrine/endocrine secretions.³²⁻³⁷ Such interactions may play a significant role in oncogenesis, tumour progression, tumour differentiation and development of LR or metastasis.³⁸⁻⁴² For example, leptin, adiponectin, resistin, matrix metalloproteinase 11, adipocyte-derived collagen VI and some other factors have positive effects in particular stages of tumour development.⁴³⁻⁴⁹ Conversely, transforming growth factor (TGF)-beta 1 and TGF-beta 2 have negative effects on mammary carcinoma cell differentiation and proliferation.⁵⁰ Therefore, based on these considerations, a highly relevant clinical question is whether BFG is a safe procedure, because it carries the possibility of fat transfer into a previous breast-cancer area and it might even have detrimental effects such as stimulation of a local recurrence. Although some studies advocate a hypothetical increased risk of LR, we did not observe it. This does not mean that LR will not occur, but after a mean time of more than 18 months we detected only one LR probably already present at time of grafting and misdiagnosed. Further investigation is needed, and series from other centres need to be compared with our results.

We provided our preliminary data on the oncological follow-up. The main form of reference in our study was a radiological examination. The examination can show that lipofilling does not significantly alter the result. However, a longer follow-up period and an increased number of patients are needed to reassure us about oncological safety.

Finally, it is still very difficult to predict the percentage of the fat-graft survival. In our experience, only in 16.8% of the cases was a further BFG performed. We presume that those numbers are underestimated, as there are patients who have already scheduled for a new procedure or others with remaining breast defects not requesting further procedures.

We conclude that BFG is an excellent technique to correct breast defects after oncological procedures. It is safe, with a small rate of postoperative complications, in our series. BFG produces promising results. Radiotherapy is the factor that may increase postoperative complication after BFG. It is feasible to perform BFG under local anaesthesia. It does not produce new microcalcification or disturb the oncological follow-up with mammograms. The preliminary results show neither increase risk of LR nor

metastasis. The few questions that still remain are the unpredictable amount of fat that will be grafted successfully, and the long-term follow-up of oncologic outcome.

Conflict of interest

None.

Funding

None.

References

- Coleman SR. Long-term survival of fat transplants: controlled demonstrations. *Aesthetic Plast Surg* 1995;19:421–5.
- Coleman SR. Facial recontouring with liposuction. *Clin Plast Surg* 1997;24:347–67.
- Coleman SR. Structural fat grafts: the ideal filler? *Clin Plast Surg* 2001;28:111–9.
- Coleman SR. Hand rejuvenation with structural fat grafting. *Plast Reconstr Surg* 2002;110:1731–45.
- Coleman SR. *Structural fat grafting*. St Louis, Mo: Quality Medical; 2004.
- Coleman SR. Structural fat grafting: more than a permanent filler. *Plast Reconstr Surg* 2006;118:1085–205.
- Bircoll M. Cosmetic breast augmentation utilizing autologous fat and liposuction techniques. *Plast Reconstr Surg* 1987;79:267.
- Coleman SR, Saboeiro AP. Fat grafting to the breast revisited: safety and efficacy. *Plast Reconstr Surg* 2007;119:775–85.
- Spear SL, Newman MK. Fat grafting to the breast revisited: safety and efficacy. *Plast Reconstr Surg* 2007;119:786–7.
- Delay E, Delpiere J, Sinna R, et al. How to improve breast implant reconstruction? *Ann Chir Plastique Esthet* 2005;50:582–94.
- Spear SL, Henry BW, Lockwood MD. Fat injection to correct contour deformities in the reconstructed breast. *Plast Reconstr Surg* 2005;116:1300–5.
- Amar O, Bruant-Rodier C, Lehmann S, et al. Fat tissue transplant: restoration of the mammary volume after conservative treatment of breast cancers, clinical and radiological considerations. *Ann Chir Plastique Esthet* 2008;53:169–77.
- Delay E, Gasset J, Toussoun G, et al. Efficacy of lipomodelling for the management of sequelae of breast cancer conservative treatment. *Ann Chir Plastique Esthet* 2008;53:153–68.
- Chan CW, McCulley SJ, Mcmillan RD. Autologous fat transfer - a review of the literature with a focus on breast cancer surgery. *J Plast Reconstr Aesthet Surg* 2008;61:1438–48.
- Rigotti G, Marchi A, Galè M, et al. Clinical treatment of radiotherapy tissue damage by lipoaspirate transplant: a healing process mediated by adipose-derived adult stem cells. *Plast Reconstr Surg* 2007;119:1409–22.
- Missana MC, Laurent I, Barreau L, et al. Autologous fat transfer in reconstructive breast surgery: indications, technique and results. *EJSO* 2007;33:685–90.
- Abboud M, Vadoud-Seyedi J, De Mey A, et al. Incidence of calcifications in the breast after surgical reduction and liposuction. *Plast Reconstr Surg* 1995;96:620.
- Chala LF, De Barros N, De Camargo Moraes P, et al. Fat necrosis of the breast: mammographic, sonographic, computed tomography and magnetic resonance imaging findings. *Curr Probl Diagn Radiol* 2004;33.
- Danikas D, Theodorou SJ, Kokkalis G, et al. Mammographic findings following reduction mammoplasty. *Plast Reconstr Surg* 2001;25:283.
- Fischer U, Baum F, Obenaus S, et al. Comparative study in patients with microcalcifications: full-field digital mammography vs screen-film mammography. *Eur Radiol* 2002;12:2679.
- Hogge JP, Robinson RE, Magnant CM, et al. The mammographic spectrum of fat necrosis of the breast. *Radiographics* 1995;15:1347.
- Jiang Y, Metz CE, Nishikawa RM, et al. Comparison of independent double readings and computer-aided diagnosis (CAD) for the diagnosis of breast calcifications. *Acad Radiol* 2006;13:84.
- Kim SM, Park JM. Mammographic and ultrasonographic features after autogenous myocutaneous flap reconstruction. *J Ultrasound Med* 2004;23:275.
- Kneeshaw PJ, Lowry M, Manton D, et al. Differentiation of benign from malignant breast disease associated with screening detected microcalcifications using dynamic contrast enhanced magnetic resonance imaging. *Breast* 2006;15:29.
- Leibman AJ, Styblo TM, Boswick III J. Mammography of the postreconstruction breast. *Plast Reconstr Surg* 1997;99:698.
- Mendelson EB. Evaluation of the postoperative breast. *Radiol Clin North Am* 1992;30:107.
- Yunus M, Ahmed N, Masroor I, et al. Mammographic criteria for determining the diagnostic value of microcalcifications in the detection of early breast cancer. *J Pak Med Assoc* 2004;54:24.
- Castello JR, Barros J, Vasquez R. Giant liponecrotic pseudocyst after breast augmentation by fat injection. *Plast Reconstr Surg* 1999;103:209.
- Kwak JY, Lee SH, Park HL, et al. Sonographic findings in complications of cosmetic breast augmentation with autologous fat obtained by liposuction. *J Clin Ultrasound* 2004;32:299.
- Maillard GF. Liponecrotic cysts after augmentation mammoplasty with fat injections. *Aesthetic Plast Surg* 1994;18:405.
- Montana Vizzano J, Baena Montilla P, Benito Ruiz J. Complications of autografting fat obtained by liposuction. *Plast Reconstr Surg* 1990;85:683.
- Ahima RS, Flier JS. Adipose tissue as an endocrine organ. *Trend Endocrinol Metab* 2000;11:327–32.
- Bradley RL, Cleveland KA, Cheatham B. The adipocyte as a secretory organ: mechanisms of vesicle transport and secretory pathways. *Recent Prog Horm Res* 2001;56:329–58.
- Kim S, Moustaid-Moussa N. Secretory, endocrine and autocrine/paracrine function of the adipocyte. *J Nutri* 2000;130:110s–5s.
- Mohamed-Ali V, Pinkney JH, Coppack SW. Adipose tissue as an endocrine and paracrine organ. *Inter J Obes* 1998;22:1145–58.
- Trayhurn P, Wood IS. Adipokines: inflammation and the pleiotropic role of white adipose tissue. *Brit J Nutri* 2004;92:347–55.
- Trujillo ME, Scherer PE. Adipose tissue-derived factors: impact on health and disease. *Endoc Rev* 2006;27:762–78.
- Imagawa W, Pedchenko VK, Helber J, et al. Hormone/growth factor interactions mediating epithelial/stromal communication in mammary gland development and carcinogenesis. *J Ster Biochem Molec Biol* 2002;80:213–30.
- Iyengar P, Combs TP, Shah SJ, et al. Adipocyte-secreted factors synergistically promote mammary tumorigenesis through induction of anti-apoptotic transcriptional programs and proto-oncogene stabilization. *Oncogene* 2003;22:6408–23.
- Kilroy GE, Foster SJ, Wu X, et al. Cytokine profile of human adipose-derived stem cells: expression of angiogenic, hematopoietic, and pro-inflammatory factors. *J Cell Physiol* 2007;212:702–9.
- Manabe Y, Toda S, Miyazaki K, et al. Mature adipocytes, but not preadipocytes, promote the growth of breast carcinoma cells

- in collagen gel matrix culture through cancer-stromal cell interactions. *J Pathol* 2003;201:221–8.
42. Schaffler A, Scholmerich J, Buechler C. Mechanisms of disease: adipokines and breast cancer - endocrine and paracrine mechanisms that connect adiposity and breast cancer. *Nature Clin Pract Endocrinol Metab* 2007;3:345–54.
 43. Iyengar P, Espina V, Williams TW, et al. Adipocyte-derived collagen VI affects early mammary tumour progression in vivo, demonstrating a critical interaction in the tumor/stroma microenvironment. *J Clin Invest* 2005;115:1163–76.
 44. Koerner A, Kratzsch J, Kiess W. Adipocytokines: leptin - the classical, resistin - the controversial, adiponectin - the promising, and more to come. *Best Pract Res Clin Endocrinol Metab* 2005;19:525–46.
 45. Motrescu ER, Blaise S, Etique N, et al. Matrix metalloproteinase-11/stromelysin-3 exhibits collagenolytic function against collagen VI under normal and malignant conditions. *Oncogene* 2008;27:6347–55.
 46. Motrescu ER, Rio MC. Cancer cells, adipocytes and matrix metalloproteinase 11: a vicious tumor progression cycle. *Biol Chem* 2008;389:1037–41.
 47. Perera CN, Spalding HS, Mohammed SI, et al. Identification of proteins secreted from leptin stimulated MCF-7 breast cancer cells: A dual proteomic approach. *Exp Biol Med* 2008;233:708–20.
 48. Rahimi N, Sautnier R, Nakamura T, et al. Role of hepatocyte growth-factor in breast-cancer - A novel mitogenic factor secreted by adipocytes. *DNA Cell Biol* 1994;13:1189–97.
 49. Vona-Davis L, Rose DP. Adipokines as endocrine, paracrine, and autocrine factors in breast cancer risk and progression. *Endocr Relat Cancer* 2007;14:189–206.
 50. Rahimi N, Tremblay E, McAdam L, et al. Autocrine secretion of TGF-beta 1 and TGF-beta 2 by pre-adipocytes and adipocytes: A potent negative regulator of adipocyte differentiation and proliferation of mammary carcinoma cells. *In Vitro Cell Dev Biol Anim* 1998;34:412–20.

Invited commentary

M. Felix Freshwater^{a,*}, David M. Freshwater^b

^aUniversity of Miami School of Medicine, 9100 S Dadeland Blvd Ste 502, Miami, FL 33156-7815, United States

^bVassar College, 124 Raymond Avenue, Poughkeepsie, NY 12604-0002, United States

Received 12 August 2010; accepted 18 August 2010

The authors have injected a rare prospective study into the body of fat grafting knowledge. Hopefully, we can reap some answers from them because their results and discussion produced further questions.

1. The phrase 'control mammograms' first appears in the discussion, but it is undefined. What does it mean – control versus treated, control versus malignant, or something else?
2. Were the mammographers blinded; did they know which mammograms were pre- and which were post grafting?
3. The authors' mammography results were described as percentages, but do not add up to 77 cases. (Table) (The correct numbers are in parentheses.) Was this an arithmetic error, a typographical error, or something else?

Cases	Percent	Comments
4	5.2	Abnormal pre-, not post
8	10.4	Less than 6 months post
54	72.7 (70.1)	Normal pre- and post
4	5.2	Abnormal pre-, normal post
5 (7)	6.5	Benign pre-, benign post
77	100	Total

4. In their discussion, the authors stated: 'The other significant factor to cause complications is the presence of loco-regional radiotherapy.' There is an important distinction between the meaning of the word 'significant' and the phrase 'clinical importance'. As Lang and Secic have written: 'In medical writing 'significant' is reserved for its statistical meaning'.³ Using both Barnard's and Fisher's exact tests with a 95% confidence interval on all 191 breasts, the 77 quadrantectomies and the 114 mastectomies, we found no statistically significant difference in complications between the radiated and non-radiated breasts. Many more patients and possibly even in multi-center trials will be needed to know if radiotherapy is a statistically significant cause of complications. Did the authors mean 'significant' or did they mean, 'The other clinically important factor that may cause complications is the presence of loco-regional radiotherapy'?
5. Finally, the 'usual suspects' that impact the microcirculation such as smoking and diabetes may be implicated here too. Have the authors looked at these confounders? Perhaps they are 'significant'?

Conflict of interest

None.

10.2 ARTIGO 2

Petit JY, Lohsiriwat V, Clough KB, Sarfati I, Ihrai T, Rietjens M, Veronesi P, Rossetto F, Scevola A, Delay E. The oncologic outcome and immediate surgical complications of lipofilling in breast cancer patients: a multicenter study--Milan-Paris-Lyon experience of 646 lipofilling procedures. *Plast Reconstr Surg.* 2011 Aug;128(2):341-6.

BREAST

The Oncologic Outcome and Immediate Surgical Complications of Lipofilling in Breast Cancer Patients: A Multicenter Study—Milan-Paris-Lyon Experience of 646 Lipofilling Procedures

Jean Yves Petit, M.D.
 Visnu Lohsiriwat, M.D.
 Krishna B. Clough, M.D.
 Isabelle Sarfati, M.D.
 Tarik Ibrai, M.D.
 Mario Rietjens, M.D.
 Paolo Veronesi, M.D.
 Fabio Rossetto, B.S.
 Anna Scevola, M.D.
 Emmanuel Delay, M.D.

Milan, Italy; Paris and Lyon, France;
 and Bangkok, Thailand



Background: Lipofilling is now performed to improve the breast contour, after both breast-conserving surgery and breast reconstruction. However, injection of fat into a previous tumor site may create a new environment for cancer and adjacent cells. There is also no international agreement regarding lipofilling after breast cancer treatment.

Methods: The authors included three institutions specializing in both breast cancer treatment and breast reconstruction (European Institute of Oncology, Milan, Italy; Paris Breast Center, Paris, France; and Leon Berard Centre, Lyon, France) for a multicenter study. A collective chart review of all lipofilling procedures after breast cancer treatment was performed.

Results: From 2000 to 2010, the authors reviewed 646 lipofilling procedures from 513 patients. There were 370 mastectomy patients and 143 breast-conserving surgery patients. There were 405 patients (78.9 percent) with invasive carcinoma and 108 (21.1 percent) with carcinoma in situ. The average interval between oncologic surgical interventions and lipofilling was 39.7 months. Average follow-up after lipofilling was 19.2 months. The authors observed a complication rate of 2.8 percent (liponecrosis, 2.0 percent). Twelve radiologic images appeared after lipofilling in 119 breast-conserving surgery cases (10.1 percent). The overall oncologic event rate was 5.6 percent (3.6 percent per year). The locoregional event rate was 2.4 percent (1.5 percent per year).

Conclusions: Lipofilling after breast cancer treatment leads to a low complication rate and does not affect radiologic follow-up after breast-conserving surgery. A prospective clinical registry including high-volume multicenter data with a long follow-up is warranted to demonstrate the oncologic safety. Until then, lipofilling should be performed in experienced hands, and a cautious oncologic follow-up protocol is advised. (*Plast. Reconstr. Surg.* 128: 341, 2011.)

CLINICAL QUESTION/LEVEL OF EVIDENCE: Therapeutic, II.

Breast reconstruction is included in the treatment plans for each individual breast cancer patient to improve quality of life.¹⁻⁴ To obtain satisfactory results, surgeons focus on cosmetic issues and, even more importantly, on oncologic safety.⁵ Despite various techniques of reconstruction with autologous tissues or pros-

theses, adipocyte tissue has been used more frequently in the recent era.⁵⁻⁹ The indications for lipofilling include micromastia, tuberous breasts, Poland syndrome, postlumpectomy deformity, postmastectomy deformity, sequelae of postradiotherapy, secondary reconstruction after flap or prosthesis reconstruction, and nipple reconstruction.¹⁰⁻¹³

Recently, a number of new techniques of fat preparation have been described, with the ultimate goal of improving adipocyte purification and

From the Division of Plastic and Reconstructive Surgery, European Institute of Oncology; the Paris Breast Center; the Leon Berard Center; and the Department of Surgery, Siriraj Hospital, Mahidol University.

Received for publication October 21, 2010; accepted January 14, 2011.

Copyright ©2011 by the American Society of Plastic Surgeons

DOI: 10.1097/PRS.0b013e31821e713c

Disclosure: The authors have no conflict of interest to report. No outside funding was received.

stem cell selection.¹⁴⁻¹⁶ However, many fundamental studies have suggested that adipocytes and preadipocytes and their products are involved in the tumor cell cycle through autocrine, paracrine, and exocrine/endocrine secretions.^{17,18} Such secretions delivered on tumor sites may play a role in tumorigenesis, tumor progression, and tumor recurrence or metastasis. In contrast, some of them could have an inhibitory effect on some particular stages of the tumor cycle. Breast cancer cells might still be present in the residual mammary parenchyma after conservative treatment or in the subcutaneous tissue after mastectomy. Therefore, based on these contradictory studies, a highly relevant clinical question is whether the lipofilling technique is a safe procedure after breast cancer treatment, especially in breast-conserving protocols.¹⁹⁻²⁴

The review article by Lohsiriwat et al.²⁵ on experimental studies found that adipocyte, preadipocyte, and progenitor cell secretions can stimulate angiogenesis and cell growth. They also emphasized that the "tumor-stroma interaction" can potentially induce cancer reappearance by "fueling" dormant breast cancer cells in the tumor bed. However, there is a lack of translational research that proves this concern clinically. No study on the effects of lipotransfer on human cancer breast cells *in vivo* is available. The direct and indirect effects of lipotransfer in breast cancer patients, highlighting pro and con-related issues, remain unclear. Today, no informed consent can be given to our patients stating that lipofilling does not stimulate fueling of dormant cancer cells or eventually induce new cancer cells.²⁵

There is no international agreement for lipofilling after breast cancer treatment. Depending on country, the safety of lipofilling is still a controversial issue. In 2007, the French Society of Plastic Reconstructive and Aesthetic Surgery (Société Française de Chirurgie Plastique Reconstructrice et Esthétique) addressed the question of cancer safety for lipofilling technique in breast cancer patients.²⁷ The Society sent a "recommendation to the French plastic surgeons to postpone the lipofilling in the breast with or without breast cancer history unless it is performed under prospective controlled protocol." In 2009, the American Society of Plastic Surgeons Fat Graft Task Force concluded that no reliable studies can confirm definitely the oncologic safety of lipofilling in breast cancer patients.¹⁴ The Italian Society of Plastic Surgery in 2010 advised surgeons to perform lipofilling with caution and with a precise consent form but did not impose any restrictions regarding

lipotransfer indications. Our purpose was to design a multicenter observational study on lipofilling after breast cancer with a significant number of cases to check the complication rate of the technique, the risk of modification of mammography and ultrasound, and the occurrence of a suspicious image, and to record oncologic follow-up.

PATIENTS AND METHODS

We set up a multicenter study gathering information from three institutions with a large experience of breast cancer treatment and reconstruction (European Institute of Oncology, Milan, Italy; Paris Breast Center, Paris, France, and Leon Berard Centre, Lyon, France). A collective chart review of lipofilling procedures was performed for the registration of the cases.

We included all breast cancer patients with lipofilling after treatment of breast cancer. Patients could have undergone breast-conserving surgery or mastectomy, regardless of preoperative and postoperative treatment (i.e., radiotherapy, chemotherapy, or hormonal treatment). Both carcinoma *in situ* and invasive carcinoma were included. The exclusion criteria were lack of histology or lack of complete operative data, follow-up less than 6 months, and treatment for local or distant recurrence between the primary cancer treatment and the lipofilling procedure.

The patients' data from each institution were collected and registered systematically on the same case record form. All patients' preoperative clinical and radiologic data were registered. The techniques of lipofilling procedures were recorded. The missing data were completed by telephone call and/or appointment. Patient age, date and indication for oncologic surgery, radiotherapy, tumor histopathology and staging, indication for lipofilling, type of anesthesia, donor sites of fat harvesting, volume of preparation and injection, complications, and clinical and radiologic follow-up data before and after lipofilling were registered.

Surgical Technique

All three institutes performed lipofilling using the same technique. The procedure was performed under local or general anesthesia, depending on quantities of fat required and the patient's clinical conditions. The selected donor site was infiltrated with Klein's solution, which consists of 1 cc of epinephrine diluted in 500 cc of 0.001% lactated Ringer's solution; 50 cc of mepivacaine is added to the solution if the surgeon is operating using local anesthesia. For harvesting,

Volume 128, Number 2 • Lipofilling in Breast Cancer Patients

we use a Coleman blunt-tip cannula attached to a 10-cc Luer-Lok syringe or a controlled pressure vacuum machine. A combination of slight negative pressure and the curetting action of the cannula through the tissues allows the fat harvesting. Then, we centrifuge the fat at 3000 rpm for 3 minutes until the serum and oily components are separated from the adipose tissue. The cellular component is transferred immediately to a 1-cc Luer-Lok syringe and prepared for injection.

RESULTS

From December of 2000 to March of 2010, we reviewed 646 lipofilling procedures from 513 patients. There were 370 mastectomy patients (476 lipofilling procedures) and 143 breast-conserving surgery patients (170 lipofilling procedures). The average amount of lipofilling performed per session was 107.3 cc (range, 5 to 400 cc). The average number of sessions required was 1.25 (range, one to six sessions). Three patients had lipofilling immediately at the time of total reconstruction with prostheses. Thirty-seven underwent lipofilling within 6 months, and the rest underwent lipofilling more than 6 months after primary oncologic surgery.

There were 240 T1 tumors, 131 T2 tumors, 31 T3 tumors, and three T4 tumors.²⁸ There were 405 invasive carcinomas (78.9 percent) and 108 carcinomas in situ (21.1 percent) (ductal carcinoma in situ, $n = 101$; lobular carcinoma in situ, $n = 7$).

The average age of the patients was 52.1 years (range, 27.7 to 86.3 years). The average time between oncologic surgical interventions and lipofilling was 39.7 months (range, 0 to 216 months). The average follow-up time from the last lipofilling procedure to the last visit was 19.2 months (range, 1 to 107 months). The average time between oncologic surgical interventions and the last visit was 57.6 months (range, 6 to 260 months). Types of oncologic and reconstructive surgical intervention are listed in Table 1 and types of radiation therapy are listed in Table 2.

Table 1. Type of Surgery

Type of Surgery	No.
Mastectomy ($n = 370$)	
Mastectomy plus prosthesis	236
Mastectomy plus flap	125
Mastectomy plus flap plus prosthesis	9
Breast-conserving surgery ($n = 143$)	
Breast-conserving surgery alone	131
Breast-conserving surgery plus flap	10
Breast-conserving surgery plus prosthesis	2
Total	513

Table 2. Type of Radiation Therapy

Radiation Therapy	No.
With radiation therapy ($n = 395$)	
IORT	129
ERT	231
IORT plus ERT	35
Without radiation therapy	118
Total	513

IORT, intraoperative radiation therapy; ERT, external radiation therapy.

First events were classified into local, regional, distant, and death events. Recurrence in breast tissue, skin around previous tumor sites, previous scar, and nipple-areola complex were categorized as local recurrence. Axillary, infraclavicular, and internal mammary nodal recurrences were categorized as regional recurrence. Locoregional recurrence refers to the cumulative number of local recurrence and regional recurrence. The overall event rate was 5.6 percent (3.6 percent per year). The locoregional event rate was 2.4 percent (1.5 percent per year). The distant metastasis rate was 3.1 percent (1.9 percent per year). A summary of all events is provided in Table 3.

We observed 18 complications from 646 procedures (2.8 percent). The most common complication was liponecrosis, which accounted for 2.0 percent. Other complications were three local infections (0.5 percent), one seroma (0.2 percent), and one pneumothorax (0.2 percent). Liponecrosis detection was based on physical examination. Regarding the liponecrosis rate in patients who underwent irradiation, we had 13 cases of liponecrosis (seven patients received external radiation therapy, one patient received intraoperative radiation therapy, and two patients received both radiation therapies). We did not study the absorption rate. The details of complications are listed in Table 4.

We follow up all breast-conserving surgery cases with systematic yearly mammograms. We have prelipofilling and postlipofilling radiologic imaging from 119 of 143 breast-conserving surgery cases: 12 radiologic images appeared after lipofilling. Seven images showed benign calcifications, two showed benign opacity masses, and three showed suspicious lesions. Seven of them were processed for tissue diagnosis; however, five of them were not submitted to any further investigation because of typical benign characteristic images. From seven histopathologic reports, there were five benign lesions (liponecrosis, $n = 2$; scarring, $n = 2$; and fibrocystic lesion, $n = 1$), and two of them were proven to be local breast relapses.

Table 3. Summary of All Events

	Cases (%)	LR (%)	RR (%)	Distant Metastasis (%)	Total (%)
Histology					
Invasive	405 (78.9)	3 (0.7)	6 (1.5)	16 (3.9)	25 (6.1)
In situ	108 (21.0)	4 (3.7)	0 (0.0)	0 (0.0)	4 (3.7)
Type of surgery					
BCS	143 (27.8)	2 (1.3)	3 (2.0)	6 (4.1)	11 (7.6)
Mastectomy	370 (72.1)	5 (1.3)	3 (0.8)	10 (2.7)	18 (4.8)
Subgroup					
BCS plus in situ	25 (4.8)	1 (4.0)	0 (0.0)	0 (0.0)	1 (4.0)
BCS plus invasive	118 (23.0)	1 (0.8)	3 (2.5)	6 (5.0)	10 (8.4)
Mastectomy plus in situ	83 (16.1)	3 (3.6)	0 (0.0)	0 (0.0)	3 (3.6)
Mastectomy plus invasive	322 (62.7)	2 (0.6)	3 (0.9)	10 (3.1)	15 (4.7)
All patients	513 (100.0)	7 (1.3)	6 (1.1)	16 (3.1)	29 (5.6)

LR, local recurrence; RR, regional recurrence; BCS, breast-conserving surgery.

Table 4. Complications

Complication	No. of Procedures (%)
Liponecrosis	13 (2.0)
Infection	3 (0.5)
Seroma	1 (0.2)
Pneumothorax	1 (0.2)
All	18 (2.8)

DISCUSSION

Fat transfer following breast cancer treatment is a growing indication of oncoplastic surgery to improve the morphologic results after total or partial breast reconstruction. It is a simple technique that usually provides a low complication rate and good cosmetic results, even after radiotherapy. In our series, 18.1 percent of patients required more than one lipofilling procedure. We cannot provide the definite reabsorption rate in our series. The patients who need only one lipofilling procedure can also have a partial lipofilling, with an acceptable aesthetic result. In the literature, the fat reabsorption rate after lipofilling is approximately 10 to 30 percent.

We observed 18 complications from 646 procedures (2.8 percent), mostly liponecrosis (2.0 percent), which is inferior to the results published by the American Society of Plastic Surgeons of 12.7 percent (infections, 1.1 percent; calcifications, 4.9 percent; fat necroses, 5.7 percent; and unspecified superficial lumps, 1.1 percent).¹³

Lipofilling can modify the radiologic follow-up of breast-conserving surgery patients. In our series, there were 12 modified radiologic images from 119 breast-conserving surgery cases. Two of them were breast relapses. The interference with radiographic examination caused by lipofilling has been well studied in the literature. Usually, the images resulting from fat injection are easily distinguished from the neoplastic images.^{29,30} Compared with

previous studies, there is no evidence that fat grafting to the breast interferes with breast cancer detection; however, the authors emphasize the need for biopsy in cases of doubt. The American Society of Plastic Surgeons also concluded that fat grafting to the breast could potentially interfere with breast cancer detection; however, no evidence was found that strongly suggests this interference. Radiologic studies suggest that imaging technologies (i.e., ultrasound, mammography, and magnetic resonance imaging) can identify the grafted fat tissue, microcalcifications, and suspicious lesions; biopsies may be performed if needed for additional clarification.¹³

Recently, Rietjens et al. reported a series of lipofilling procedures in breast cancer treatment and reconstruction. They followed 158 patients and found that postoperative complication rates are very low (3.6 percent) and that there is little alteration in follow-up mammograms (5.9 percent).³¹ Another series of 880 lipofilling procedures by Delay et al. demonstrated a low complication rate (3 percent fat necrosis) and positive results. They also suggested that preoperative and postoperative examination by a radiologist specializing in breast imaging is necessary to limit the risk that a cancer may occur coincidentally with lipofilling.⁹

However, injection of fat into a previous tumor site may create a new environment for cancer cells and adjacent cells because of cell purification or by adding stimulus factors. The "tumor stromal interaction" or paracrine action of the injected fat may affect locoregional recurrence rates, especially in breast-conserving surgery. To evaluate the oncologic events in our series of patients, we compared our results with two articles published recently from the European Institute of Oncology, the first organization dedicated to breast-conservative treatment and the second one dedicated to

Volume 128, Number 2 • Lipofilling in Breast Cancer Patients

the results of total mastectomy with or without breast reconstruction. We focused on locoregional recurrence, which is the sum of regional recurrence and local recurrence. In our series, locoregional recurrence rates were higher in the breast-conserving surgery group than in the mastectomy group (2.07 percent versus 1.38 percent per year), and *in situ* carcinoma tends to have a higher chance of locoregional recurrence than invasive carcinoma (2.33 percent versus 1.44 percent per year). The incidence of locoregional recurrence in a series of 2784 breast-conserving surgery patients from the European Institute of Oncology is 0.4 percent per year as compared with 2.07 percent in our series of lipofilling.³² The locoregional recurrence rate after mastectomy with lipofilling is consistent with the results of the study published by Petit et al.: 1.38 percent versus 1.1 percent.³³

The distant metastasis rate in our series was 1.95 percent per year, and all of the distant events occurred in the invasive carcinoma group. We found 2.78 percent and 1.75 percent rates of distant metastasis in the breast-conserving surgery group and the mastectomy group, respectively. Compared with data from our institute, there are 1.52 percent and 2.38 percent distant metastasis rates in the breast-conserving surgery group and the mastectomy group, respectively.^{32,33} Such comparison with the two series of the European Institute of Oncology shows a small increase of locoregional recurrence in the breast-conserving surgery group after lipofilling and no difference for the mastectomy group. No definitive conclusion can be drawn from such comparison between retrospective studies. Our purpose was, first, to eliminate the risk of finding a consistent increase of the local or distant events in the follow-up of patients after lipofilling. To report at the level of drawing conclusions, our next program will compare our cases with a control group of patients undergoing breast reconstruction without lipofilling, matched according to the usual cancer criteria: staging, histology, biological markers, hormonal receptors, and the same period of time without adverse oncologic events between the primary cancer surgery and the date of lipofilling. A longer period of follow-up is also required to focus on oncologic results.

Few articles have focused on the oncologic safety of lipotransfer. Illouz and Sterodimas concluded that the locoregional recurrence in cancer patients in their series was comparable to that in the aesthetic group.³⁴ However, these results are retrospective, with no information on the quality of the cancer follow-up. No cancer staging has been provided by the authors.

Another study based on cancer evolution by Rigotti et al. compared the number of locoregional recurrences of the same group of patients in the prelipofilling and postlipofilling periods.³⁵ Such methodology could be criticized, because the risk of locoregional recurrence decreases with time and cannot be considered as equivalent in the prelipofilling and postlipofilling periods. Moreover, we cannot understand why the authors did not use the 104 conservative treatments of their series, which could be the patients most at risk for locoregional recurrence.³⁶

Because of the purpose of our study, we cannot provide definitive proof regarding the safety of lipofilling in terms of cancer recurrence or distant metastasis. We only provided the preliminary results of oncologic follow-up and early complications of surgical and radiologic follow-up. We have not reported the efficacy of the lipofilling procedure in terms of aesthetic follow-up or fat reabsorption.

CONCLUSIONS

This multicenter study from three institutions confirms that lipofilling following breast cancer treatment leads to a very low rate of complications and does not affect the radiologic follow-up after breast-conserving surgery. We cannot provide the definitive proof of the safety of lipofilling in terms of cancer recurrence or distant metastasis. Further studies are required with a longer follow-up, a larger group of patients, and a control group matched according to the cancer status of the lipofilling group. Until then, lipofilling should be performed in experienced hands, and a cautious oncologic follow-up protocol is advised.

Jean Yves Petit, M.D.
Division of Plastic Surgery
European Institute of Oncology
Via Ripamonti, 435
20141 Milano, Italy
jean.petit@ieo.it

REFERENCES

1. Brédart A, Petit JY. Partial mastectomy: A balance between oncology and aesthetics? *Lancet Oncol*. 2005;6:130.
2. Cordeiro PG. Breast reconstruction after surgery for breast cancer. *N Engl J Med*. 2008;359:1590-1601.
3. Petit JY, Rietjens M, Garusi C. Breast reconstructive techniques in cancer patients: Which ones, when to apply, which immediate and long term risks? *Crit Rev Oncol Hematol*. 2001; 38:231-239.
4. Petit JY, De Lorenzi F, Rietjens M, et al. Technical tricks to improve the cosmetic results of breast-conserving treatment. *Breast* 2007;16:15-16.
5. Rietjens M, Urban CA, Rey PC, et al. Long-term oncological results of breast conservative treatment with oncoplastic surgery. *Breast* 2007;16:387-395.

Plastic and Reconstructive Surgery • August 2011

6. Missara MC, Laurent I, Barreau L, Balleyguier C. Autologous fat transfer in reconstructive breast surgery: Indications, technique and results. *Eur J Surg Oncol.* 2007;33:685-690.
7. Rigotti G, Marchi A, Caliè M, et al. Clinical treatment of radiotherapy tissue damage by lipospiate transplant: A healing process mediated by adipose-derived adult stem cells. *Plast Reconstr Surg.* 2007;119:1409-1422; discussion 1423-1424.
8. Chan CW, McCulley SJ, Macmillan RD. Autologous fat transfer: A review of the literature with a focus on breast cancer surgery. *J Plast Reconstr Aesthet Surg.* 2008;61:1438-1448.
9. Delay E, Garson S, Tousson G, Sinna R. Fat injection to the breast: Technique, results, and indications based on 880 procedures over 10 years. *Aesthet Surg J.* 2009;29:360-376.
10. Coleman SR, Saboero AP. Fat grafting to the breast revisited: Safety and efficacy. *Plast Reconstr Surg.* 2007;119:775-785.
11. Spear SL, Newman MK. Fat grafting to the breast revisited: Safety and efficacy (Discussion). *Plast Reconstr Surg.* 2007;119:786-787.
12. Spear SL, Wilson HB, Lockwood MD. Fat injection to correct contour deformities in the reconstructed breast. *Plast Reconstr Surg.* 2005;116:1300-1305.
13. Gutowski KA; ASPS Fat Graft Task Force. Current applications and safety of autologous fat grafts: A report of the ASPS Fat Graft Task Force. *Plast Reconstr Surg.* 2009;124:272-280.
14. Shiffman MA, Mirrafati S. Fat transfer techniques: The effect of harvest and transfer methods on adipocyte viability and review of the literature. *Dermatol Surg.* 2001;27:819-826.
15. Katz AJ, Ljull R, Hedrick MH, Futrell JW. Emerging approaches to the tissue engineering of fat. *Clin Plast Surg.* 1999;26:587-603.
16. Patrick CW Jr. Adipose tissue engineering: The future of breast and soft tissue reconstruction following tumor resection. *Semin Surg Oncol.* 2000;19:302-311.
17. Vona-Davis L, Rose DP. Adipokines as endocrine, paracrine, and autocrine factors in breast cancer risk and progression. *Endocr Relat Cancer.* 2007;14:189-206.
18. Lamszus K, Jin L, Fuchs A, et al. Scatter factor stimulates tumor growth and tumor angiogenesis in human breast cancers in the mammary fat pads of nude mice. *Lab Invest.* 1997;76:339-353.
19. Manabe Y, Toda S, Miyazaki K, Sugihara H. Mature adipocytes, but not preadipocytes, promote the growth of breast carcinoma cells in collagen gel matrix culture through cancer-stromal cell interactions. *J Pathol.* 2003;201:221-228.
20. Schäffler A, Schölmerich J, Bueschler C. Mechanisms of disease: Adipokines and breast cancer. Endocrine and paracrine mechanisms that connect adiposity and breast cancer. *Nat Clin Pract Endocrinol Metab.* 2007;3:345-354.
21. Iyengar P, Espina V, Williams TW, et al. Adipocyte-derived collagen VI affects early mammary tumor progression in vivo, demonstrating a critical interaction in the tumor/stroma microenvironment. *J Clin Invest.* 2005;115:1163-1176.
22. Motrescu ER, Rio MC. Cancer cells, adipocytes and matrix metalloproteinase 11: A vicious tumor progression cycle. *Biol Chem.* 2008;389:1037-1041.
23. Rahimi N, Tremblay E, McAdam L, Roberts A, Elliott B. Autocrine secretion of TGF-beta 1 and TGF-beta 2 by pre-adipocytes and adipocytes: A potent negative regulator of adipocyte differentiation and proliferation of mammary carcinoma cells. *In Vitro Cell Dev Biol Anim.* 1998;34:412-420.
24. Garofalo C, Surmacz E. Leptin and cancer. *J Cell Physiol.* 2006;207:12-22.
25. Lohsiriwat V, Curigliano G, Rietjens M, Goldhirsch A, Petit JY. Autologous fat transplantation in patients with breast cancer: "Silencing" or "fueling" cancer recurrence? *Breast.* Published ahead of print February 4, 2011.
26. Petit JY, Clough K, Sarfati I, Lohsiriwat V, de Lorenzi F, Rietjens M. Lipofilling in breast cancer patients: From surgical technique to oncologic point of view. *Plast Reconstr Surg.* 2010;126:262e-263e.
27. French Society of Plastic Reconstructive and Aesthetic Surgery (Société Française de Chirurgie Plastique Reconstructrice et Esthétique). Portail de la de Chirurgie Plastique, Reconstructrice et Esthétique. Available at: <http://www.plasticiens.org/>. Accessed November 28, 2009.
28. American Joint Committee on Cancer. TNM staging: The common language of cancer. Available at: <http://www.cancerstaging.org/>. Accessed November 28, 2009.
29. Pulagam SR, Poulton T, Mamounas EP. Long-term clinical and radiologic results with autologous fat transplantation for breast augmentation: Case reports and review of the literature. *Breast J.* 2006;12:63-65.
30. Kwak JY, Lee SH, Park HI, Kim JY, Kim SE, Kim EK. Sonographic findings in complications of cosmetic breast augmentation with autologous fat obtained by liposuction. *J Clin Ultrasound.* 2004;32:299-301.
31. Rietjens M, De Lorenzi F, Rossetto F, et al. Safety of fat grafting in secondary breast reconstruction after cancer. *J Plast Reconstr Aesthet Surg.* 2011;64:477-483.
32. Botteri E, Bagnardi V, Rotmensz N, et al. Analysis of local and regional recurrences in breast cancer after conservative surgery. *Ann Oncol.* 2010;21:723-728.
33. Petit JY, Gentilini O, Rotmensz N, et al. Oncological results of immediate breast reconstruction: Long term follow-up of a large series at a single institution. *Breast Cancer Res Treat.* 2008;112:545-549.
34. Illouz YG, Sterodimas A. Autologous fat transplantation to the breast: A personal technique with 25 years of experience. *Aesthetic Plast Surg.* 2009;33:706-715.
35. Rigotti G, Marchi A, Stringhini P, et al. Determining the oncological risk of autologous lipospiate grafting for post-mastectomy breast reconstruction. *Aesthetic Plast Surg.* 2010;34:475-480.
36. De Lorenzi F, Lohsiriwat V, Petit JY. In response to: Rigotti G, Marchi A, Stringhini P, et al. "Determining the oncological risk of autologous lipospiate grafting for post-mastectomy breast reconstruction." *Aesth Plast Surg.* 2010;34:475. *Aesthetic Plast Surg.* 2011;35:132-133.

10.3 ARTIGO 3

Lohsiriwat V, Curigliano G, Rietjens M, Goldhirsch A, Petit JY. Autologous fat transplantation in patients with breast cancer: "silencing" or "fueling" cancer recurrence? *Breast*. 2011 Aug;20(4):351-7.

The Breast 20 (2011) 351–357



Contents lists available at ScienceDirect

The Breast

journal homepage: www.elsevier.com/brst

Original article

Autologous fat transplantation in patients with breast cancer: "silencing" or "fueling" cancer recurrence?

Visnu Lohsiriwat^{a,c,*}, Giuseppe Curigliano^b, Mario Rietjens^a, Aron Goldhirsch^b, Jean Yves Petit^a^a Division of Reconstructive Surgery, European Institute of Oncology, Milan, Italy^b Department of Medicine, Division of Medical Oncology, European Institute of Oncology, Milan, Italy^c Division of Head Neck and Breast, Department of Surgery, Faculty of Medicine Siriraj Hospital, Mahidol University, Bangkok, Thailand

ARTICLE INFO

Article history:
Received 2 July 2010
Received in revised form
15 September 2010
Accepted 6 January 2011

Keywords:
Breast cancer
Lipofilling
Adipokines
Plastic surgery
Adipocyte
Breast reconstruction

ABSTRACT

Lipotransfer can be considered a technical revolution in plastic surgery and widely performed for esthetic surgery. Recently the lipofilling has been indicated in breast reconstruction and deformity correction after breast conservative treatment. However, there is lack of understanding concerning the interactions between the potential tumor beds and the lipoaspirates grafts. Current literature underlines the efficacy of the technique as well as its safety. Nevertheless, many experimental studies provide data on the endocrine, paracrine, and autocrine activities of the transplanted fat tissues. Adipocyte, pre-adipocyte and progenitor cell secretions can stimulate angiogenesis and cell growth. The "tumor–stroma interaction" can potentially induce cancer reappearance by "fueling" dormant breast cancer cells in tumor bed. There is lack of translational research that proves this concern in clinical aspect. No study on the effects of lipotransfer on human cancer breast cells *in vivo* is available.

We provide direct and indirect effects of lipotransfer in breast cancer patients, highlighting pro and con related issues. To confirm the safety of lipotransfer in breast cancer patients we need clinical studies with control group based on long term follow up.

© 2011 Elsevier Ltd. All rights reserved.

Introduction

The lipofilling technique has been used since many years and becomes rapidly popular especially in esthetic surgery. Breast reconstruction is also widely proposed to reduce the disabling effects of the mutilation.^{1–3} Lipofilling can be associated to the usual techniques of breast reconstruction to improve the symmetry and the final cosmetic result. Fat grafting can also be performed to improve the cosmetic results of the conservative treatment, particularly in case of defect resulting from the tumorectomy followed by the radiotherapy^{4–12} (Fig. 1). For several teams, lipofilling becomes part of the armamentarium of the oncoplastic surgery.^{6–23} The indications of lipofilling include micromastia, tuberous breasts, Poland's Syndrome, post-lumpectomy deformity, post-mastectomy deformity, post radiotherapy sequelae, secondary reconstruction after flap or prosthesis reconstruction and nipple reconstruction.^{7,11,24} However, the indication and case selection for lipotransfer should be standardized base on large series studies and long term

follow up results, particularly in term of immediate surgical complications, fat necrosis/realorption and esthetic improvement.

Most studies published in the literature focus on technique, complications, fat graft survival and cosmetic results. Several studies are focused on breast cancer patient safety. They are mainly dealing with the risk of microcalcifications observed on the mammogram in the follow up. No data are available on the risk of recurrence due to the endocrine, paracrine and autocrine fat activity. In 2007, the French Society of Plastic Surgery addressed the question of cancer safety for the lipofilling technique in breast cancer patients. The Society sent a recommendation to the French plastic surgeons to postpone the lipofilling in the breast with or without breast cancer history unless it is performed under prospective controlled protocol. One year later, the American Society of Plastic Surgeons (ASPS) gathered 8 important American plastic surgeons in "The ASPS Fat Graft Task Force" to assess the indications, the safety and efficacy of autologous fat grafting.²⁴ Five major endpoints were identified: 1. What are the current and potential applications of fat grafting? 2. What risks and complications are associated with fat grafting? 3. How does technique affect outcomes of fat grafting? 4. What risk factors need to be considered for patient selection? 5. What advancements in bench research/molecular biology should potentially impact current or future methods of fat grafting?

* Corresponding author: Division of Plastic Surgery, European Institute of Oncology, via Giuseppe Ripamonti 435, Milan M120141, Italy. Tel.: +39 0257489723, +39 3930546055 (mobile); fax: +39 029479203.

E-mail address: lohswat@gnail.com (V. Lohsiriwat).

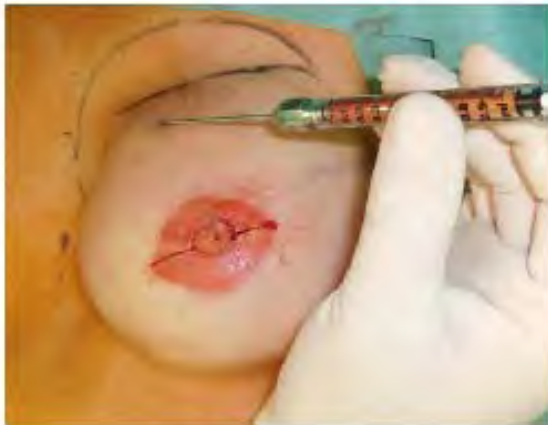

Fig. 1. Lipofilling procedure.

In the ASPS task force project, only 6 out of 111 cited literature references mentioned the potential impact of fat transfer on breast cancer detection.^{11,16,17,25–27} There are reports concerning the radiological sequelae following autologous fat transfer, such as the finding of microcalcifications. Some data emphasized that not only mammography but also ultrasonography and MRI may be more accurate to distinguish between the changes associated with benign necrosis of breast tissue and changes associated with cancer.^{25–27,80} Moreover, the task force also stated that “based on a limited number of studies with few cases ... no interference with breast cancer detection has been observed; however, more studies are needed...”. Despite the fact that post-lumpectomy and post-mastectomy are clearly included in the indications of fat graft, the task force did not discuss the issues of adipocyte–stroma interaction, and the risk of development of local recurrences.

Search strategy and selection criteria

Information for this Personal View were obtained by a search of PubMed using the following search term: “lipofilling”, “fat grafting”, “breast cancer”, “breast conservative surgery”, “oncoplasty”, “adipocyte”, “adipokine”, “adiponectin”, “leptin” and “adipocytokine”. Only papers published in English were cited [The references no. 19 and 25 were published in French with English abstract available]. No limitation in date range was introduced. Publications and citations were selected within the issue of this review. The articles are selected according to each subheading purpose in the review.

What is fat grafting surgical procedure?

The first description of the use of adipose tissue as a filler was made in 1893 by Neuber. The results were ephemeral because of the resorption of the fat grafted. During the twentieth century, the surgical techniques were improved allowing more durable results with a low resorption rate.¹⁹ At present, the technique used by the majority of surgeons was published in 1995 by Coleman²⁰; adipose tissue is taken, centrifuged and injected in the area where a filling is necessary. Coleman’s technique gives good and stable cosmetic results in many anatomic areas.^{14,21,22} Lipofilling technique consists in a localized injection of fat into the area of breast previously subjected to excisional surgery for the removal of a breast cancer lesion.^{6–15} Briefly, the fat is removed by liposuction from the

subcutaneous tissue, usually from the abdomen or from the thighs according to the morphology of the patient. The specimen obtained is subjected to soft centrifugation to remove blood cell contaminants and obtain an adipocyte-enriched preparation. Recently, a number of new techniques have been described, mostly based on enzymatic treatments, with the ultimate goal to improve adipocyte purification. After harvesting and processing, the purified fat is finally injected into the area of the breast, which should be refilled to improve the shape. The revitalization of the injected fat acts as a graft. In approximately 30% of cases, reabsorption of the fat is observed. This represents a major hurdle to successful outcome of the lipofilling technique. This kind of complication can be circumvented with high density embryologic adipocyte preparations.^{31–39}

Fat injection into the breast could result in fat necrosis, cyst formation, and indurations that could be mistaken as cancerous calcifications. Moreover the degree of reabsorption of the injected adipose tissue is unpredictable. Breast cancer surgeons use fat grafting to improve the results of breast reconstructions and to correct conservative treatments’ sequelae. One of the oncological concerns of the lipofilling in patients with breast cancer patient is related to the difficulty of radiological surveillance due to microcalcification occurrence after lipofilling procedure. Rigotti et al.³⁰ demonstrated that lipofilling is more than just a filler; it also enhances skin trophicity (which is interesting after radiotherapy).

The aim of our manuscript is to critically review literature data questioning the safety of fat grafting in reconstructive surgery of patients with breast cancer.

Adipocytes and breast cancer

Experimental studies have shown that adipocytes can stimulate breast cancer cells. Adipokines are factors that can stimulate breast cancerous cells through endocrine, paracrine and autocrine pathways.^{28,29} Lamszus et al. have proved that Hepatocyte Growth Factors stimulates tumor growth and neoangiogenesis in mice’s mammary fat pads.³⁰ Numerous observations of the adipocyte proadipocyte, progenitor cells, adipokines, and adipokine–stroma interaction as potential actors in breast cancer tumorigenesis have been dispersedly reported in various reports during the last two decades.^{40–74}

In 1992, an early experiment from Elliot et al.⁵⁷ showed that the subcutaneously or peritoneally co-transplantation of murine mammary carcinoma cell into adipose tissue rich environment regions led to tumor growth and metastasis. Later on, Manabe Y et al.⁴⁸ co-cultured mature adipocytes or preadipocytes with multiple models of breast carcinoma cell lines. The result also showed growth-promoting effects of mature adipocyte to estrogen positive tumor cells.

In 2002, Wiseman BS and Werb Z.⁵⁸ reviewed pathways involving soluble factors secreted from cells that surround tumors, the extracellular-matrix components, and interactions between stromal cells and tumor cells which create a specific and local peritumoral microenvironment. In the review, the role of adipocyte, which is the most abundant stromal cell, is emphasized either in promotion and protection against breast cancer.

The specific adipocyte products have been studied by microarray analysis, luciferase reporter assays,⁴⁶ serum analysis and interstitial fluid analysis.⁵⁹ Iyengar P et al.⁴⁵ also carried out an *in vivo* model to measure quantitatively the ability of adipocytes to facilitate growth potential of breast ductal epithelial cells faster than those fibroblast co-culture cells. Celis JE et al. registered a total of 359 unique proteins. Apart from providing a comprehensive overview of the mammary fat proteome and its interstitial fluid, their results offer some insight as to the role of adipocytes in the

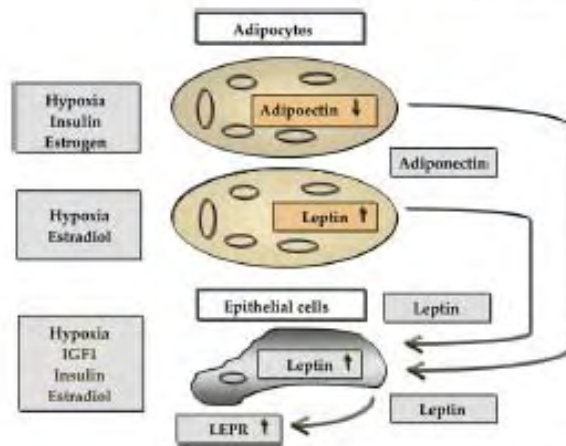


Diagram 1. Cross-talk of the adipokines leptin and adiponectin in breast cancer tumorigenesis (Adapted from Schaffler A et al.)

breast tumor microenvironment and their molecular cellular circuitry.⁵⁰

Adipose organ can have influence to distant tumor site via endocrine function⁴⁴ and soluble factors secreted from peritumoral cells/extracellular-matrix components.⁴⁰ Trujillo ME and Scherer PE⁴⁴ reviewed endocrine function of the adipose organ which secretes adiponectin, resistin and other adipokines. The same description by Schaffler A et al.⁴⁰ stated that adipocytes have a role in breast-cancer tumorigenesis as they can promote tumorigenesis through soluble factors secreted from peritumoral cells, extracellular-matrix components. These soluble factors facilitate interactions between stromal cells and tumor cells and create a specific and local peritumoral microenvironment. Moreover, they reviewed the specific role of peritumoral adipose tissue which secretes adipokines [such as adiponectin and leptin] exerting endocrine and paracrine effects in breast cancer behavior. Meanwhile, the cellular and molecular basis of the peritumoral 'desmoplastic' tissue reaction is involved via tumor necrosis factor (TNF), interleukin 11 and matrix metalloproteinase 11. All these factors play role in breast cancer cell progression and adipocyte differentiation inhibition. Interactions between adipokines and breast cancer tumorigenesis are reported as shown in Diagram 1.

Adiponectin and breast cancer

Adiponectin is an adipocyte-secreted protein which has been implicated in the pathogenesis of insulin-resistant states, such as obesity and type 2 diabetes mellitus. Adiponectin levels are also associated with the development of endometrial carcinoma and breast cancer. The correlation of adiponectin level and breast cancer may especially link between breast cancer and obesity/insulin resistance via paracrine and endocrine pathway. The potential mechanisms of this relationship are not yet clarified even if the autocrine, paracrine or endocrine function may all be an explanation.^{60–65}

Mantzoros C et al.⁶⁰ designed a case-control study in order to identify potential surrogate biomarkers of breast cancer tumorigenesis. They demonstrated an inverse correlation between serum adiponectin levels and breast cancer risk among postmenopausal women. This relationship was independent of possible effects of the IGF pathways, leptin, body mass index, sociodemographic variables, and other known risk factors for breast cancer. Körner A

et al.⁶¹ also observed that women with the higher adiponectin levels had a 65% reduced risk of breast cancer. This study was performed on 74 patients with breast cancer compared to 76 control patients. Their study demonstrated that the exposure of specific breast cancer cell lines to adiponectin can significantly inhibit the percentage of viable cells and cell proliferation with no effect on apoptosis. These studies suggested that adiponectin may relate to carcinogenesis and may constitute a molecular link between obesity and breast cancer.

Similar findings were described by Tworoger SS et al.⁶² in 2007. The authors observed that adiponectin may be inversely associated with breast cancer risk in postmenopausal, particularly in a low-estrogen environment. Though the explanation of endocrine action seems to fit the hypothesis, the actions of autocrine and paracrine are still debatable. The specific effective role of adiponectin was demonstrated by Kang JH et al.⁶³ in 2005. They proved that adiponectin level within the range of physiological concentration could significantly suppress the proliferation of ER negative cancer cell line (MDA-MB-231) and also caused cell growth arrest and even apoptosis. Nevertheless, four out of five tested cell lines especially those with ER positive cancer cell line were unsuccessful to produce the same result.

In 2007, Barb D et al.⁶⁴ underlined that the circulating adiponectin concentrations are lower in patients with breast, endometrial, prostate, and colon cancer. Adiponectin may influence cancer risk not only through its well-recognized effects on insulin resistance, but it also acts on tumor cells directly. In 2008, an experimental study by Nakayama S et al.⁶⁵ showed that adiponectin treatment resulted in a significant dose-dependent growth inhibition of human breast cancer cell lines. The adiponectin can decrease breast cancer cell proliferation by inhibiting the entry into S-phase without inducing apoptosis, and this inhibitory effect is mediated through adiponectin receptor 1.

Leptin and breast cancer

Leptin is a cytokine-like protein secreted from adipose tissues. It is also recognized as a serum growth factor positively associated with body weight and/or body fat. The circulating leptin increases as body weight and fat mass increase. Leptin has been identified in regulation of cell proliferation and neovascularization⁶⁶ in malignant and normal cells of diverse origins, including lung, gastric, colonic, kidney, leukemic, hematopoietic and epithelial cells.⁶⁶ The expression of leptin has been described in normal human mammary tissues and in human breast tumor cell lines and breast cancer cell. Whether leptin is involved in the regulation of normal mammary gland development has not been clearly investigated.

In 2006, Miyoshi Y et al.⁶⁷ found the association between high serum leptin or high intratumoral leptin mRNA levels and poor prognosis. This seems to suggest that the leptin and Lep-R(L)/Lep-R(S) pathways are implicated in the growth stimulation of breast tumors. The process of this occurrence may be affected by autocrine, paracrine or circulating leptin.

In another report, Garofalo C et al.⁶⁸ claimed that leptin might also contribute to mammary tumorigenesis. They also discussed the biological functions of leptin and its signaling pathways, together with the effects of leptin on different cancer types in experimental cellular and animal models. They analyzed the epidemiological data on the relationship between obesity and the presence of cancer or cancer risk. The majority of data on relationship of leptin and cancer are based on epidemiological data and particularly related to its endocrine function as circulating leptin.

There are two case-control studies which used multiple logistic regression with adjustment by Mantzoros CS et al.⁶⁹ and Wu MH et al.⁷⁰ try to demonstrate the relation between serum leptin and

Table 1
Studies on adiponectin and leptin with evidences of relationship to breast cancer risk.

Reference	Year	Design	No of patients	Results	Notes
Mantzoros C, et al. ⁶⁷	2004	Case-control study	174	Inverse correlation between serum adiponectin levels and breast cancer risk among postmenopausal women	Odds ratio, 0.82; 95% confidence interval, 0.67–1.00; No significant association in pre-menopausal women
Körner A, et al. ⁶¹	2007	Case-control and experimental study	74	Women with the higher adiponectin levels had a 65% reduced risk of breast cancer	Adiponectin significantly inhibit proliferation of tumor cells
Twooger SS, et al. ⁶²	2007	Prospective case-control study	1477	Adiponectin inversely associated with breast cancer risk in postmenopausal women	Strongly inverse association in women who never used hormone replacement therapy
Kang JH, et al. ⁶³	2005	Experimental study <i>in vitro</i>	–	Cell growth arrest and induction of apoptosis by adiponectin in ER negative breast cancer cell lines	No evidence of anti-tumor activity in ER positive cancer cell lines
Nakayama S, et al. ⁶⁴	2008	Experimental study <i>in vitro</i>	–	Adiponectin decreases breast cancer cell proliferation by inhibiting the entry into S-phase without inducing apoptosis.	This inhibitory effect is mediated through adiponectin receptor 1
Miyoshi Y, et al. ⁶⁷	2006	Experimental study on tissue samples	91	Leptin and Lep-R(L)/Lep-R(S) pathways are implicated in the breast cancer tumorigenesis	Association of obesity and poor prognosis in patient with breast cancer may be explained by leptin levels
Mantzoros CS, et al. ⁶⁹	1999	Case-control study	83	Leptin does not appear to increase the risk of cancer in pre-menopausal patients	/
Wu MH, et al. ⁷⁰	2009	Case-control study	297	Higher leptin levels were significantly associated with an increased risk of breast cancer.	The associations of leptin with breast cancer risk remained after adjustment for obesity indices
Nikhata KJ, et al. ⁷¹	2009	Experimental study <i>in vitro</i>	–	Increasing the adiponectin:leptin (A/L) ratio resulted in down-regulation of proliferation of MCF-7 and T47-D breast cancer cell lines.	/

breast cancer. Mantzoros CS et al.⁶⁹ concluded that serum leptin does not appear to increase the risk of cancer in pre-menopausal patients. In contrast, the results of latter study showed that the associations of leptin with breast cancer risk remained after adjustment for obesity indices. These results also suggested that leptin may have an independent role in breast tumorigenesis.

In 2009, an experimental study by Nikhata KJ et al.⁷¹ was conducted on the adipocyte-derived adiponectin and leptin effect on breast cancer cell proliferation *in vitro*. They also examined the effects of varying adiponectin:leptin(A/L) ratios toward different breast cancer cell lines. The results showed that the effects of A/L ratio on mediating proliferation may have some specificity since the cell lines exhibited different responses as A/L ratio resulted in down-regulation of proliferation of only MCF-7 and T47-D breast cancer cell lines (Table 1).

Other adipocytokines and breast cancer

Besides the adiponectin and leptin which are well known adipokines, adipocytes also associated with other secretions such as Stromelysin-3,⁷² matrix metalloproteinase,^{53,72} and collagen VI⁵⁰ which may act through autocrine, paracrine and endocrine pathways. Some of them has been reported and studied dearly in the specific correlation with breast tumor cell development.

Andarawewa KL et al.⁷² showed that adipocytes present at human breast tumor invasive front were induced by cancer cells to express ST3/Stromelysin-3/matrix metalloproteinase 11 (ST3/MMP11). That was associated with tumor invasion and poor prognosis. Thus, adipocytes are involved in initial cancer cell survival in connective tissue, and this effect is ST3 mediated. They also found the importance of a matrix metalloproteinase (MMP) in cancer cell-adipocyte crosstalk during early steps of connective tissue invasion. Motrescu ER et al.⁵³ demonstrated that MMP have collagenolytic activity. This activity is functional in fat tissue oncogenesis as well as during cancer invasive steps. These activities established through an epithelial/mesenchymal heterotypic cell interaction and induce dramatic remodeling of the adjacent connective tissue through desmoplasia, leading to the formation of

the peritumoral stroma. Moreover, Iyengar et al.⁵⁰ in 2005 explored the bi-directional interactions between adipocytes and malignant ductal epithelial cells. They found that the absence of collagen VI delayed the onset of early hyperplasia while Collagen VI-secreting adipocytes were more permissive of breast tumor growth *in vivo* and had a greater impact on the progression of early tumor development. They concluded that adipocytes play a vital role in defining the extracellular matrix (ECM) environment for normal and tumor-derived ductal epithelial cells and contribute significantly to tumor growth at early stages through secretion and processing of collagen VI.

Not only the stimulatory effect but also the inhibitory effect of adipocyte were reported in fewer studies.^{55,56,73,74} In 2001, Meng L et al.⁷³ studied epithelial–stromal interactions and demonstrated that adipocyte differentiation was inhibited by co-culturing fibroblasts with various breast cancer cell lines. On the other hand, inhibitory effect by adipocyte resistin was reported by Van Valkenburgh D et al.⁷⁴ They conducted both *in vitro* and *in vivo* experiments in mouse and revealed that resistin could significantly inhibit tumor growth in both experiments. Nevertheless this result was somehow contradictory to epidemiological studies that link obesity to a higher breast cancer risk, so the underlying mechanisms remain unclear regarding resistin and tumor growth association. Also Rahimi N et al.⁵⁶ have developed both *in vitro* and *in vivo* experiments in a mouse model to demonstrate that activation of TGF- β has a potent negative effect on adipocyte differentiation and murine mammary carcinoma growth. Other report stated that, under physiologic conditions, mature adipocyte would promote tumor growth, whereas pre-adipocyte would suppress tumor growth as well as their own differentiation.⁵⁵

Discussion

Subcutaneously or peritoneally co-transplantation of murine mammary carcinoma cells into adipose tissue rich environment regions can lead to tumor growth and metastasis.⁵⁷ This is the main interesting concept of local effect acting via paracrine, autocrine or “tumor–stromal interaction” pathway that can also happen in

lipofilling procedures to the breast. We have evidence that both stimulatory as well as inhibitory effects can be observed in the experimental researches. Some of the studies tried to validate single type of cell or type of adipokine which may be responsible for some particular stages of breast cancer cell line development. However, the majority of those studies are from fundamental research and *in vitro* study and somehow difficult to link with the clinical model.

Indirect data that support safety of fat transfer are based on reconstruction using an autologous flap technique such as transverse rectus abdominis myocutaneous (TRAM) flap and deep inferior epigastric perforator (DIEP) flap. Despite the large amount of fat tissue transferred with the flap, no increased risk of cancer recurrence has been published in the literature. However both techniques should be distinguished. Autologous flap is made of a complex tissue with its own vascular system; the composition or ratio of the fat tissue in the flap is not altered. Lipotransfer fat composition is altered from original donor site ratio. Moreover new protocols try to select the proadipocytes and adult stem cells with specific enzymatic activities.^{18,36,37,39,75} Several teams also introduced growth factor or biological active substance in the preparation process to increase the survival of the injected adipocytes.^{76–78} After conservative treatment, the fat tissue is injected through the glandular tissue. Such injection of adipocytes are able to produce adipokines and several secretions which can potentially induce cancer reappearance by “fueling” dormant breast cancer cells in tumor bed through the “tumor–stroma interaction”. We cannot conclude that the flap transfer does not have any tumor–stroma interaction. In the literature, few papers have shown the absence of local recurrence risk after TRAM flap reconstruction.⁷⁹ No study provides reliable comparative oncological outcome between flap reconstruction and lipotransfer in breast cancer patients.

The clinical series of oncologic data of lipotransfer in breast cancer patients is still limited. Ilouz et al., reviewed a personal series of 820 patients with lipofilling only 381 patients were cancer patients; other indications were for congenital breast asymmetry and cosmetic augmentation without cancer history.²³ However, they could not make the conclusion in term on oncological safety because almost half of the patients were lack of oncological data and follow up.

Rietjens M et al. reported one of the biggest series focus on lipotransfer in breast-cancer treatment and reconstruction. They followed 158 patients and found that postoperative complication rates are very low and there is little alteration in follow-up mammograms. Although they found only one recurrence in 18 months they concluded that and the potential risk of local ‘dormant’ tumor cells being stimulated to induce a local recurrence is still unclear.⁸⁰

Another study based on cancer evolution by Rigotti G. Compared the number of LRR of the same group of patients in the pre and post lipofilling. Such methodology should be criticized, because the risk of LRR decreases with time and cannot be considered as equivalent in the pre and post lipofilling period. The authors excluded 104 breast conservative treatment patients from the whole study populations which breast conservative treatment patients could be the group at most risk of LRR. Without the translational research, this report concluded that autologous lipoaspirate transplant combines striking regenerative properties with no or marginal effects on the probability of post-mastectomy locoregional recurrence of breast cancer.⁸¹

In 2008 Chan CW et al.⁸² reviewed 8 studies on autologous fat transfer with a focus on breast cancer surgery. In such review, most indications of lipofilling were not for breast cancer patients but for benign purpose. No specific oncologic follow up was mentioned. Chan stated in the conclusion that “...Owing to insufficient data, its (lipotransfer) use as an adjunct in breast reconstruction surgery has been slow to gain acceptance...”.

The same concern of stimulatory effect of lipotransfer method is also found in other type of solid tumor. Recently, Perrot P and colleagues⁸³ reported a case of a late local osteosarcoma recurrence. They investigated the relationship of osteosarcoma tumor growth with fat injections in pre-clinical models and found that fat grafts or progenitor cells promoted osteosarcoma tumor growth.

There is increasing evidence that the stroma is important for driving tumor growth. When performing a fat transfer procedure we should consider the potential adipokines downstream effects on breast cancer tumorigenesis. Adipokines can potentially increase the interaction between tumor and stromal cells rather than conferring self-sufficiency to the tumor. Adipocytes, pre-adipocytes and adipokines can promote or inhibit breast cancer cell tumorigenesis through autocrine and paracrine mechanisms enhancing tumor–stroma interactions. These data question the safety of fat grafting in reconstructive surgery of the breast. Since November 2007, the French Society of Plastic Surgery (SOFCPRE) recommends not to use adipose tissue in breast surgery until its innocuity has been proved. Authors also underline that the autologous fat grafting to the breast is not a simple procedure and should be performed only by well-trained and skilled surgeons. The major complications can be observed when this procedure is performed by untrained and untutored physicians and the role of education in the lipofilling technique is of paramount importance.

Conclusion

We cannot state that lipofilling procedure is dangerous or should not be done in patients with breast cancer, since available data are balanced on suppressive or promoting effects of fat transfer on breast cancer progression. Therefore, we should promote translational research to evaluate the role of fat grafting in the development of breast tumor, to evaluate if fat grafting may induce cancer recurrence (especially after radiotherapy) and to evaluate whether cancer induction or recurrence depends on angiogenesis mediated by cytokines produced by the lipofilling. Clinical studies based on an accurate follow up of patients with breast cancer who underwent lipotransfer are required to definitively address all relevant questions. A prospective clinical registry including high volume multicenter collaborative data is warranted.

Authorship statement

Concept and design - Jean Yves Petit, Visnu Lohsiriwat; Writing manuscript - Giuseppe Curigliano, Visnu Lohsiriwat and Jean Yves Petit. Critically Revising - Mario Rietjens, Aron Goldhirsch.

Conflict of interest statement

The author and co-authors declare no conflict of interest.

References

- Bredan A, Petit JY. Partial mastectomy: a balance between oncology and aesthetics? *Lancet Oncol* 2005; **6**(3): 130.
- Costeiro PC. Breast reconstruction after surgery for breast cancer. *N Engl J Med* 2008; **358**(15):1590–601.
- Petit JY, Rietjens M, Garusi C. Breast reconstructive techniques in cancer patients: which ones, when to apply, which immediate and long term risks? *Curr Rev Oncol Hemat* 2001; **3**(3):231–9.
- Petit JY, De Lorenzi F, Rietjens M, Inra M, Martella S, Garusi C, et al. Technical tricks to improve the cosmetic results of breast-conserving treatment. *Breast* 2007; **16**(1): 13–6.
- Rietjens M, Urban CA, Rey PC, Mazzardi G, Maisonneuve P, Garusi C, et al. Long-term oncological results of breast conservative treatment with oncoplastic surgery. *Breast* 2007; **16**(4):387–95.
- Amar O, Bruant-Rodier C, Lehmann S, Bolleclier V, Wilk A. Fat tissue transplant: restoration of the mammary volume after conservative treatment of breast

- cancers, clinical and radiological considerations. *Ann Chir Plast Esth* 2008;53(2):16D–77.
7. Delay E, Gostet J, Toussoun G, Delaporte T, Delbaere M. Efficacy of lipomodelling for the management of sequelae of breast cancer conservative treatment. *Ann Chir Plast Esth* 2008;53(2):153–66.
 8. Kijima Y, Yoshinaka H, Owaki T, Aikou T. Early experience of immediate reconstruction using autologous free dermal fat graft after breast conservative surgery. *J Plast Reconstr Aest Surg* 2007;60(5):495–502.
 9. Missani MC, Laureit L, Barreau I, Balleguier C. Autologous fat transfer in reconstructive breast surgery: indications, technique and results. *Eur J Surg Oncol* 2007;33(6):685–90.
 10. Rigotti G, Marchi A, Galie M, Baroni G, Bonati D, Krampfer M, et al. Clinical treatment of radiotherapy tissue damage by liposyringe transplant: a healing process mediated by adipose-derived adult stem cells. *Reas Reconstr Surg* 2007;119(5):140B–22.
 11. Coleman SR, Sobolov AP. Fat grafting to the breast revisited: safety and efficacy. *Reas Reconstr Surg* 2007;119(3):775–85.
 12. Spear SL, Newman MK. Fat grafting to the breast revisited: safety and efficacy. *Plast Reconstr Surg* 2007;119(3):786–7.
 13. Bircoll M. Cosmetic breast augmentation utilizing autologous fat and liposuction techniques. *Plast Reconstr Surg* 1987;79(2):267–71.
 14. Coleman SR. Structural fat grafting: more than a permanent filler. *Reas Reconstr Surg* 2006;118(3):1085–205.
 15. Spear SL, Wilson HB, Lockwood MD. Fat injection to correct contour deformities in the reconstructed breast. *Plast Reconstr Surg* 2005;116(5):1300–5.
 16. Hang-Fu L, Marmolva G, Feiglin DH. Liposuction fat-filler implant for breast augmentation and reconstruction. *Aesthetic Plast Surg* 1995;19(5):427–37.
 17. Yoshimura K, Sato K, Aoi N, Kurita M, Hiroki T, Harai K. Cell-assisted lipotransfer for cosmetic breast augmentation: supportive use of adipose-derived stem/stromal cells. *Aesthetic Plast Surg* 2008;32(1):48–55.
 18. Patrick CW. Adipose tissue engineering: the future of breast and soft tissue reconstruction following tumor resection. *Semin Surg Oncol* 2000;19(3):302–11.
 19. Mojallal A, Royzter JL. [Historical review of the use of adipose tissue transfer in plastic and reconstructive surgery]. *Ann Chir Plast Esth* 2004;49(5):419–25.
 20. Coleman SR. Long-term survival of fat transplants: controlled demonstrations. *Aesthetic Plast Surg* 1995;19(5):421–5.
 21. Coleman SR. Structural fat grafts: the ideal filler? *Clin Plast Surg* 2001;28(1):111–9.
 22. Coleman SR. Facial recontouring with liposuction. *Clin Plast Surg* 1997;24(2):347–67.
 23. Housh YC, Strydomas A. Autologous fat transplantation to the breast: a personal technique with 25 years of experience. *Aesthetic Plast Surg*; 2009 Jun 4 [Epub ahead of print].
 24. Gutowski KA, Baker SR, Coleman SR, Khorobehi K, Lorenz HP, Massey ME, et al. Current applications and safety of autologous fat grafts: a report of the ASFS Fat Graft Task Force. *Reas Reconstr Surg* 2009 Mar 23 [Epub ahead of print].
 25. Piorofani-Lagrange AC, Delay E, Guezin N, Chelakroua K, Delaporte T. [Radiological evaluation of breasts reconstructed with lipomodelling]. *Ann Chir Plast Esth* 2005;51(1):18–28.
 26. Pulagam SR, Boulton T, Manouvas EP. Long-term clinical and radiologic results with autologous fat transplantation for breast augmentation: case reports and review of the literature. *Breast J* 2006;12(1):63–5.
 27. Kwak JY, Lee SH, Park HL, Kim JY, Kim SE, Kim EK. Sonographic findings in complications of cosmetic breast augmentation with autologous fat obtained by liposuction. *J Clin Ultrasound* 2004;32(6):299–301.
 28. Vona-Davila L, Rose DP. Adipokines as endocrine, paracrine, and autocrine factors in breast cancer risk and progression. *Endocr Relat Cancer* 2007 Jun;14(2):189–206.
 29. Hou WK, Xu YX, Yu T, Zhang L, Zhang WW, Fu CL, et al. Adipocytokines and breast cancer risk. *Chin Med J* 2007;120(18):1592–6.
 30. Lamszus K, Jin L, Fuchs A, Shi E, Chowdhury S, Yao Y, et al. Scatter factor stimulates tumor growth and tumor angiogenesis in human breast cancers in the mammary fat pads of nude mice. *Lab Invest* 1997;76(3):339–53.
 31. Markov AC, Glogau RG. Autologous fat grafting: comparison of techniques. *Dermatol Surg* 2000;26(12):1135–9.
 32. Fu LQ, Coleman SR, Cal X, Ferguson RBH, Vaconez HC. Autologous fat grafts harvested and refined by the Coleman technique: a comparative study. *Reas Reconstr Surg* 2008;122(3):932–7.
 33. Rieck B, Schiack S. Measurement in vivo of the survival rate in autologous adipocyte transplantation. *Reas Reconstr Surg* 2003;111(7):2315–23.
 34. Shiffman MA, Mirafati S. Fat transfer techniques: the effect of harvest and transfer methods on adipocyte viability and review of the literature. *Dermatol Surg* 2001;27(9):819–26.
 35. Toledo LS, Masad R. Fat injection: a 20-year revision. *Clin Plast Surg* 2006;33(1):47–53.
 36. Katz AJ, Uall R, Hedrick MH, Patten JW. Emerging approaches in the tissue engineering of fat. *Clin Plast Surg* 1999;26(4):587–603.
 37. Lin SD, Wang KH, Kao AP. Engineered adipose tissue of predefined shape and dimensions from human adipose-derived mesenchymal stem cells. *Tissue Eng Part A* 2008;14(5):571–81.
 38. Moseley TA, Zhu M, Hedrick MH. Adipose-derived stem and progenitor cells as fillers in plastic and reconstructive surgery. *Reas Reconstr Surg* 2006;118(3):1215–85.
 39. Patrick CW. Breast tissue engineering. *Annu Rev Biomed Eng* 2004;6:109–30.
 40. Ahima RS, Flier JS. Adipose tissue as an endocrine organ. *Trends Endocrin Met* 2000;11(8):327–32.
 41. Bradley RL, Cleveland RA, Cheatham B. The adipocyte as a secretory organ: mechanisms of vesicle transport and secretory pathways. *Recent Prog Horm Res* 2001;56:329–58.
 42. Kim S, Mouzard-Moussa N. Secretory, endocrine and autocrine/paracrine function of the adipocyte. *J Nutr* 2000;130(12):3110S–55.
 43. Mohamed-Ali V, Pinkney JH, Coppack SW. Adipose tissue as an endocrine and paracrine organ. *Int J Obes* 1998;22(12):1145–58.
 44. Trujillo ME, Scherer PE. Adipose tissue-derived factors: impact on health and disease. *Endocr Rev* 2006;27(7):762–78.
 45. Imagawa W, Fedchenko VK, Helber J, Zhang HZ. Hormone/growth factor interactions mediating epithelial/stromal communication in mammary gland development and carcinogenesis. *J Steroid Biochem Mol Biol* 2002;80(7):213–30.
 46. Iyengar P, Combs TP, Shah SJ, Gouin-Evans V, Follard JW, Albanese C, et al. Adipocyte-secreted factors synergistically promote mammary tumorigenesis through induction of anti-apoptotic transcriptional programs and proto-oncogene stabilization. *Oncogene* 2008;27(41):5408–23.
 47. Killey CE, Foster SJ, Wu X, Ruiz J, Sherwood S, Helletz A, et al. Cytokine profile of human adipose-derived stem cells: expression of angiogenic, hematopoietic, and pro-inflammatory factors. *J Cell Physiol* 2007;212(3):702–9.
 48. Marabe Y, Toda S, Miyazaki K, Sugihara H. Mature adipocytes, but not pre-adipocytes, promote the growth of breast carcinoma cells in collagen gel matrix culture through cancer-stromal cell interaction. *J Pathol* 2008;211(2):221–8.
 49. Schaffer A, Scholmetch J, Buechler C. Mechanisms of disease: adipokines and breast cancer – endocrine and paracrine mechanisms that connect adiposity and breast cancer. *Nat Clin Pract Endocrin* 2007;3(4):345–54.
 50. Iyengar P, Espina V, Williams TW, Lin Y, Berry D, Jellics LA, et al. Adipocyte-derived collagen VI affects early mammary tumor progression in vivo, demonstrating a critical interaction in the tumor/stroma microenvironment. *J Clin Invest* 2005;115(5):1163–76.
 51. Koerner A, Kitzsch J, Kiess W. Adipocytokines: leptin – the classical, resistin – the controversial, adiponectin – the promising, and more to come. *Best Pract Res Clin Endocrinol Metab* 2005;19(4):525–46.
 52. Morrescu ER, Blaise S, Enque N, Mesaddeq N, Chenaud MP, Stoll L, et al. Matrix metalloproteinase-11/stromelysin-3 exhibits collagenolytic function against collagen VI under normal and malignant conditions. *Oncogene* 2008;27(49):6347–55.
 53. Morrescu ER, Rio MC. Cancer cells, adipocytes and matrix metalloproteinase 11: a vicious tumor progression cycle. *Biol Chem* 2008;389(8):1037–41.
 54. Pereira CN, Spalding HS, Mohammed SI, Camarillo JG. Identification of proteins secreted from leptin stimulated MCF-7 breast cancer cells: a dual proteomic approach. *Exp Biol Med* 2008;233(6):708–20.
 55. Rahimi N, Saubrier R, Nakamura T, Park M, Elliott B. Role of hepatocyte growth factor in breast cancer – A novel mitogenic factor secreted by adipocytes. *DNA Cell Biol* 1994;13(12):1189–97.
 56. Rahimi N, Tremblay E, McAdam I, Roberts A, Elliott B. Autocrine secretion of TGF-beta 1 and TGF-beta 2 by pre-adipocytes and adipocytes: a potent negative regulator of adipocyte differentiation and proliferation of mammary carcinoma cells. *In Vitro Cell Dev Biol Anim* 1998;34(5):412–20.
 57. Elliott BE, Tan SP, Dexter D, Chen ZQ. Capacity of adipose tissue to promote growth and metastasis of a murine mammary carcinoma: effect of estrogen and progesterone. *Int J Cancer* 1992;51:416–24.
 58. Winerman BS, Werb Z. Stromal effects on mammary gland development and breast cancer. *Science* 2002;296(1046):9.
 59. Celis JE, Moreira JMA, Cabezon T, Goshov P, Fells E, Rana F, et al. Identification of extracellular and intracellular signaling components of the mammary adipose tissue and its interstitial fluid in high risk breast cancer patients: toward dissecting the molecular circuitry of epithelial-adipocyte stromal cell interactions. *Mol Cell Proteomics* 2005;4(4):402–522.
 60. Mantzoros C, Petridou E, Dessypris N, Chavelas C, Dala-maga M, Anez DM, et al. Adiponectin and breast cancer risk. *J Clin Endocrinol Metab* 2004;89(3):1102–7.
 61. Kömer A, Papatou-Panayiotou K, Kelesidis T, Kelesidis I, Williams CJ, Kaprara A, et al. Total and high-molecular-weight adiponectin in breast cancer: in vitro and in vivo studies. *J Clin Endocrinol Metab* 2007;92(3):1041–8.
 62. Tsvonger SS, Eliason AH, Kelesidis T, Colditz GA, Willett WC, Mantzoros CS, et al. Plasma adiponectin concentrations and risk of incident breast cancer. *J Clin Endocrinol Metab* 2007;92(4):1510–6.
 63. Kang JH, Lee YY, Yu BY, Yang BS, Cho KH, Yoon DK, et al. Adiponectin induces growth arrest and apoptosis of MDA-MB-231 breast cancer cell. *Arch Biochem Res* 2005;28(11):1269–9.
 64. Barb D, Williams CJ, Neuwirth AK, Mantzoros CS. Adiponectin in relation to malignancies: a review of existing basic research and clinical evidence. *Am J Clin Nutr* 2007;86(3):e58–66.
 65. Nakayama S, Miyoshi Y, Ishihara H, Noguchi S. Growth-inhibitory effect of adiponectin via adiponectin receptor 1 on human breast cancer cells through inhibition of S-phase entry without inducing apoptosis. *Breast Cancer Res Treat* 2008;112(3):405–10.
 66. Attoub S, Nee V, Pirota L, Bruyere E, Chastre E, Maree JM, et al. Leptin promotes invasiveness of kidney and colonic epithelial cells via phosphoinositide 3-kinase-, rho-, and mG-dependent signaling pathways. *FASEB J* 2000;14(14):2329–38.
 67. Miyoshi Y, Funahashi T, Tanaka S, Taguchi T, Tamaki Y, Shimomura I, et al. High expression of leptin receptor mRNA in breast cancer tissue predicts poor prognosis for patients with high, but not low, serum leptin levels. *Int J Cancer* 2006;118(6):1414–9.
 68. Gostol C, Surmacz E. Leptin and cancer. *J Cell Physiol* 2006;207:12–22.

69. Mantzoros CS, Balkhe K, Moschos S, Cramer DW. Leptin in relation to carcinoma in situ of the breast: a study of premenopausal cases and controls. *Int J Cancer* 1999; **80**(4):523–6.
70. Wu MH, Chou YC, Chou WY, Hsu GC, Chu CH, Yu CP, et al. Circulating levels of leptin, adiposity and breast cancer risk. *Brit J Cancer* 2009 Feb; **100**(4): 578–82.
71. Nishida KJ, Ray A, Schuster TF, Grossmann ME, Cleary MP. Effects of adiponectin and leptin co-treatment on human breast cancer cell growth. *Oncol Rep* 2009 Jun; **21**(6): 1611–9.
72. Andarawewa KI, Motreanu ER, Chénard MP, Gansmüller A, Stoll L, Tomasello C, et al. Stromelysin-3 is a potent negative regulator of adipogenesis participating to cancer cell–adipocyte interaction/crosstalk at the tumor invasive front. *Cancer Res* 2005; **65**(23):10862–71.
73. Meng L, Zhou J, Sasano H, Suzuki T, Zeitoun KM, Bulun SE. Tumor necrosis factor α and interleukin 11 secreted by malignant breast epithelial cells inhibit adipocyte differentiation by selectively down-regulating CCAAT/enhancer binding protein α and peroxisome proliferator-activated receptor γ : mechanism of desmoplastic reaction. *Cancer Res* 2001; **61**(5):2250–5.
74. Van Valkenburgh D, De Wever O, Hendrix A, Bracke M, Vandembroccke R, Van Belle S, et al. Role of adipocyte-derived resistin in breast cancer. *Breast Cancer Res Treat* 2006; **100**: 5299–5.
75. Piasecki JH, Gutowski KA, Lahlvis GP, Moreno RD. An experimental model for improving fat graft viability and purity. *Plast Reconstr Surg* 2007; **119**(5): 1571–83.
76. Shoshani O, Livne E, Annoni M, Shupak A, Berger J, Ramon Y, et al. The effect of interleukin-8 on the viability of injected adipose tissue in nude mice. *Plast Reconstr Surg* 2005; **115**(3):853–9.
77. Vashi AV, Abberton KM, Thomas GP, Morrison WA, O'Connor AJ, Cooper-White J, et al. Adipose tissue engineering based on the controlled release of fibroblast growth factor-2 in a collagen matrix. *Tissue Eng* 2006; **12**(11):3035–43.
78. Yi CC, Pan Y, Zhen Y, Zhang LX, Zhang XD, Shu MC, et al. Enhancement of viability of fat grafts in nude mice by endothelial progenitor cells. *Dermatol Surg* 2006; **32**(12):1437–43.
79. Howard MA, Poto K, Pusic AL, Costello PG, Hidalgo DA, Mehrara B, et al. Breast cancer local recurrence after mastectomy and TRAM flap reconstruction: incidence and treatment options. *Plast Reconstr Surg* 2006; **117**(5): 1381–6.
80. Rietjens M, De Lorenzi F, Rossetto F, Brenelli F, Manconi A, Martella S, et al. Safety of fat grafting in secondary breast reconstruction after cancer. *J Plast Reconstr Aesthet Surg*. 2010 Aug 5 [Epub ahead of print].
81. Rigotti G, Marchi A, Stanghini P, Baroni C, Galè M, Molino AM, et al. Determining the oncological risk of autologous liposyringe grafting for post-mastectomy breast reconstruction. *Aesth Plast Surg* 2010; **34**:475.
82. Chan CW, McCulley SJ, Macmillan RD. Autologous fat transfer—a review of the literature with a focus on breast cancer surgery. *J Plast Reconstr Aesthet Surg* 2008; **61**(12): 1488–48.
83. Penot F, Rousseau J, Bouffaut AL, Rédini F, Castagnau E, Deschaseaux F, et al. Safety concern between autologous fat graft, mesenchymal stem cell and osteosarcoma recurrence. *PLoS One* 2010 Jun 8; **5**(6):e10999.

10.4 ARTIGO 4

Petit JY, Clough K, Sarfati I, Lohsiriwat V, de Lorenzi F, Rietjens M. Lipofilling in breast cancer patients: from surgical technique to oncologic point of view. *Plast Reconstr Surg*. 2010 Nov;126(5):262e-263e.

Plastic and Reconstructive Surgery • November 2010

Thomas P. Whetzel, M.D.

Lee L. Pu, M.D., Ph.D.

Thomas R. Stevenson
Division of Plastic Surgery
University of California Davis Medical Center
Sacramento, Calif.

Correspondence to Dr. Patel

Division of Plastic Surgery
University of California Davis Medical Center
2221 Stockton Boulevard, Suite 2125
Sacramento, Calif. 95817
kamlesh.patel@ucdmc.ucdavis.edu

DISCLOSURE

The authors have no financial interest to declare in relation to the content of this article.

REFERENCES

1. McCarthy CM, Mehrara BJ, Riedel E, et al. Predicting complications following expander/implant breast reconstruction: An outcomes analysis based on preoperative clinical risk. *Plast Reconstr Surg*. 2008;121:1886-1892.
2. Taub E, Layman ML. Thoracic complications of venriculo-peritoneal shunt: Case report and review of the literature. *Neurosurgery* 1994;34:181-185; discussion 183-184.
3. Iyer HP, Jacob LP, Chaudhry NA. Breast cerebrospinal fluid pseudocyst. *Plast Reconstr Surg*. 2006;118:87e-89e.
4. Spector JA, Culliford AT, Post NI, Weiner H, Levine JP. An unusual case of cerebrospinal fluid pseudocyst in a previously augmented breast. *Ann Plast Surg*. 2005;54:85-87.
5. Torres AN. Late complication of a ventriculoperitoneal shunt in a patient with mammary prosthesis. *J Plast Reconstr Aesthet Surg*. 2008;61:212-214.

Lipofilling in Breast Cancer Patients: From Surgical Technique to Oncologic Point of View

Sir:

An important question should be raised today concerning the safety of lipofilling in breast cancer patients. Indications for lipofilling are broadening extensively in aesthetic and reconstructive surgery. After breast cancer treatment, lipofilling is now used widely to improve the contour of the breast, both after breast conservation and after breast reconstruction. Tentative techniques of total breast reconstruction without prostheses or flaps have been performed and published.¹⁻⁴

In 2008, the French Society of Plastic, Reconstructive and Aesthetic Surgery issued a recommendation to French plastic surgeons to postpone lipofilling in the breast with or without a history of breast cancer, unless it is performed under a prospective controlled protocol.⁵ In 2009, the American Society of Plastic Surgeons set up a fat graft task force to assess the safety and efficacy of autologous fat grafting.¹ The task force conclusions mentioned that no publication studied emphasized an increasing risk of breast cancer recurrence or metastasis related to the lipofilling procedure. However, no study reached a high level of evidence as defined pre-

viously by the task force. Most studies were gathering small series, with short follow-up, poor definition of the cancer status of the patients, and no comparison with a control group.

Moreover, the preparation of the fat to be transferred varies widely. The selection of adult adipocytes by the Coleman technique using centrifugation to discard the other components of the aspirated specimen is the most frequently used. New approaches aiming at enhancing the proportion of adult stem cells are under study.² Addition of growth factors to stimulate the survival of the adipocytes is also proposed by some authors.³ All of these techniques may promote the stimulation of angiogenesis, although cancer treatment research works on fighting against angiogenesis. Moreover, experimental animal studies demonstrate a stimulation of the cancer burden following lipofilling. A number of publications emphasize the endocrine, paracrine, and autocrine activity of the adipocytes. Adipokines can have the "tumor-stromal interaction" with breast parenchymal cell and stromal cells. For example, a high level of adiponectin seems to have an inhibitive effect on breast cancer, whereas leptin tends to stimulate cancer growth. No definitive conclusion can be drawn from "in vitro" studies, as cancer recurrence is concerned with breast cancer patients. However, the question of safety should be solved quickly because of reliable statistical controlled clinical studies. Today, no informed consent can be given to our patients stating that lipofilling does not stimulate fueling of dormant cancer cells or eventually induce new cancer cells. A multicenter study is required that gathers an important number of cases with a precise registration of the cancer status and that follows them prospectively for a sufficient number of years to reach reliable statistical results for comparison of the local recurrence rate with a matched controlled group.
DOI: 10.1097/PRS.0b013e3181e94a8

Jean Yves Petit, M.D.

Division of Plastic Surgery
European Institute of Oncology
Milan, Italy

Krishna Clough, M.D.

Isabelle Sarfati, M.D.

Paris Breast Center
Paris, France

Vismu Lohsiriwat, M.D.

Francesca de Lorenzi, M.D., Ph.D.

Mario Rietjens, M.D.
Division of Plastic Surgery
European Institute of Oncology
Milan, Italy

Correspondence to Dr. Petit
Division of Plastic Surgery
European Institute of Oncology
Via Ripamonti, 435
20141 Milan, Italy
jean.petit@ieo.it

REFERENCES

1. Gusowski KA, Baker SB, Coleman SR, et al. Current applications and safety of autologous fat grafts: A report of the ASPS fat graft task force. *Plast Reconstr Surg*. 2009;124:272–280.
2. Coleman SR, Saboeiro AP. Fat grafting to the breast revisited: Safety and efficacy. *Plast Reconstr Surg*. 2007;119:775–785.
3. Chan CW, McCulley SJ, Macmillan RD. Autologous fat transfer: A review of the literature with a focus on breast cancer surgery. *J Plast Reconstr Aesthet Surg*. 2008;61:1438–1448.
4. Delay F, Casse J, Toussou G, Delaporte T, Delbaere M. Efficacy of lipomodelling for the management of sequelae of breast cancer conservative treatment (in French). *Ann Chir Plast Esthet*. 2008;53:153–168.
5. French Society of Plastic Reconstructive and Aesthetic Surgery [Société Française de Chirurgie Plastique Reconstructrice et Esthétique (SOFICPRE)]. Available at: <http://www.plasticiens.org/>. Accessed November 28, 2009.

Repeated Bilateral Reduction Mammoplasty: A 12-Year Experience

Sir:

Bilateral reduction mammoplasty is an extremely common operation used to decrease the size of large breasts and relieve their many associated symptoms. Repeated bilateral reduction mammoplasty, in contrast, is an infrequently performed procedure. Few studies have investigated postoperative outcomes, and as a result, there are no clearly established guidelines, risk profiles, or recommendations for the preferred operative technique.^{1–3}

From September of 1997 to May of 2009, a total of 890 patients (1780 breasts) underwent bilateral reduction mammoplasty performed by one of four surgeons at the University of Michigan Health System. Of these, eight cases (16 breasts) were repeated procedures (0.9 percent of all bilateral reduction mammoplasties) (Table 1). Mean patient age at the time of the repeated procedure was 48.8 years (range, 24 to 76 years). All surgeons used the same technique for the repeated bilateral reduction mammoplasty that was used for the primary procedure, when known. However, the pri-

mary operation was unknown in four of the eight cases. Operative procedures included inferior pedicle technique ($n = 5$), central/superior pedicle technique ($n = 1$), inferior pedicle technique with a free nipple graft ($n = 1$), and superomedial pedicle technique with a free nipple graft ($n = 1$).

Three of the eight repeated reduction mammoplasties (37.5 percent) resulted in a major complication, which was defined as a complication that required either an operation or hospitalization to treat, as follows: nipple necrosis ($n = 1$), abscess ($n = 1$), and seroma ($n = 1$). All major complications occurred in cases using a pure inferior pedicle technique; all of these patients had also undergone an inferior pedicle technique as the original procedure. As a result, there was a 100 percent complication rate for the repeated reduction cases using an inferior pedicle when the original reduction was known to have been performed by means of an inferior pedicle (patients 3, 5, and 8 in Table 1). There were no major complications in any patient undergoing a repeated reduction using any other technique.

Repeated bilateral reduction mammoplasty procedures are associated with a major complication rate of 37.5 percent, a rate significantly higher than rates reported for primary reduction, which range from 4 to 26 percent.^{4,5} It has been recommended that surgeons could reduce their risk of reoperative complications by performing the same operation for the secondary procedure as was originally performed.³ However, on the basis of our data, if an inferior pedicle technique was known to have been used for the primary procedure, and an inferior pedicle is used for the repeated procedure, there is a 100 percent complication rate. This would suggest that surgeons should exercise caution when selecting the technique to be used for the repeated reduction mammoplasty. Cases using some version of a free nipple graft technique for the revisional procedure did not have any major complications, and this may be the technique of choice for repeated bilateral reduction mammoplasties.

DOI: 10.1097/PRS.0b013e3181ef94bd

Shaun P. Patel, B.S.
David L. Brown, M.D.

Table 1. Repeated Bilateral Reduction Mammoplasty Cases

Patient	Age (yr)	First Operation (yr previously)	First Operation Technique	Repeated Operation Technique	Right Breast Tissue Resected (g)	Left Breast Tissue Resected (g)	Major Complication
1	44	~10 (exact unknown)	Unknown	Inferior pedicle	710	700	None
2	37	20	Unknown pedicle/free nipple graft	Central/superior pedicle	510	600	None
3	41	15	Inferior pedicle	Inferior pedicle	680	1000	Abscess
4	67	35	Unknown	Inferior pedicle	250	430	None
5	55	27	Inferior pedicle	Inferior pedicle	506	524	Nipple necrosis
6	76	~15 (exact unknown)	Inferior pedicle	Inferior/free nipple graft	1011	1042	None
7	24	4	Unknown	Superomedial/free nipple graft	762	547	None
8	46	18	Inferior pedicle	Inferior pedicle	935	920	Seroma



11. Anexos

11. 1 DOCUMENTO DE APROVAÇÃO DO COMITÊ DE ÉTICA



IEO
Istituto Europeo di Oncologia

Istituto di Ricovero e Cura a Carattere Scientifico (DM 18/1/96)
Via Ripamonti 435, 20141 Milano - Italia

Comitato Etico

Tel +39 02 57 489 848 Fax +39 02 57 489 781

E-mail: comitato.etico@ieo.it

Milano, 23 luglio 2008
AN/dt

Dott Mauro Germinario
Chiltern International srl
Via Nizzoli 6
20147 Milano MI

Dott. Mario Rietjens
Div Chirurgia Ricostruttiva IEO

DOMANDA N.: **IEO S392/108**

SPONSOR: Citory Therapeutics Inc

TITOLO DELLO STUDIO: Valutazione Clinica di Cellule Rigenerative Derivate da Cellule Adipose nel Trattamento di Pazienti con Deformità Mammare post-Resezione Mammaria Segmentale (Lumpectomia) con o senza Terapia Radiante. Potenziale Registro Post-Marketing. Trial RESTORE-2

SPERIMENTATORE PRINCIPALE: Dott. Mario Rietjens

In riferimento alla richiesta di parere concernente lo studio in oggetto, si informa che questo Comitato etico, nella seduta del 16 luglio 2008, alla luce degli elementi presentati in seguito alla richiesta di approfondimento esprime **parere favorevole** con richiesta di modifiche all'informativa per il paziente e consenso informato.

La sperimentazione viene registrata con il n. **R399-IEO S392/108** (n. di riferimento da citare sempre nella corrispondenza).

In allegato si trasmettono l'elenco dei membri partecipanti alla seduta e l'elenco dei documenti presentati e la revisione dell'informativa.

Si specifica che la sperimentazione clinica in oggetto deve essere eseguita in conformità alla normativa vigente, alle norme di Buona Pratica Clinica nonché secondo il protocollo di studio presentato ed in accordo con i principi etici fissati nella dichiarazione di Helsinki.

Si ricorda che i costi della sperimentazione dovranno essere sostenuti dallo Sponsor ed autorizzati dall'amministrazione IEO. I suddetti costi non devono gravare sul SSN o sui pazienti.

Si precisa che non devono essere avviate deviazioni dal protocollo o modifiche allo stesso, senza che il Comitato Etico abbia espresso parere favorevole ad ogni specifico emendamento, eccetto quando ciò sia necessario per eliminare i rischi immediati per i soggetti.

Si rammenta che tutte le comunicazioni che lo Sponsor ha l'obbligo di trasmettere al Ministero della Salute vanno trasmesse in copia a questo Comitato Etico. Vanno altresì trasmesse in copia le comunicazioni previste dalle norme di farmacovigilanza; in particolare, questo Comitato richiede che le comunicazioni relative ad eventi avversi seri siano integrate dal numero totale di eventi registrati e del numero totale di pazienti esposti al trattamento.

Allo Sperimentatore viene richiesto, al termine della sperimentazione, un riassunto dei risultati in termini di efficacia e sicurezza.

Il Comitato Etico deve essere immediatamente informato relativamente a:

1. deviazioni dal protocollo o modifiche allo stesso al fine di eliminare i rischi immediati per i soggetti dello studio;
2. modifiche che aumentino il rischio per i soggetti e/o che incidano significativamente alla conduzione dello studio;
3. tutte le reazioni avverse da farmaci che siano serie ed inattese;
4. nuove informazioni che possano incidere negativamente sulla sicurezza dei soggetti o sulla conduzione dello studio.

Distinti saluti.



Dott. Atanasio Nonis
Responsabile Segreteria Tecnico-Scientifica

IEO S392/108

ELENCO DOCUMENTI:

- Protocollo Restore-2 rev A del 31/10/07
 - Riassunto del progetto di ricerca (modulo IEO)
 - Informativa al paziente e consenso informato, versione del 10/1/08
 - Questionari: valutazione lent-soma, QOL, valutazione della soddisfazione
 - Lettera al medico curante del 10/1/08
 - Polizza di assicurazione di n. 010109869C di Ace Europe, con scadenza 29/10/08
 - Investigator's Brochure IB-CT-800 rev b del 20/12/07
 - IMPD V2 del 1/1/08
 - Scheda raccolta dati draft del 3/8/07
 - Certificato marchio CE
-



**Istituto Europeo di Oncologia
Comitato Etico**

Presenze membri riunione del 16 luglio 2008

	APOLONE Dottor Giovanni (Vice Presidente) Capo Lab. Ricerca Traslaz. e Outcome, Istituto Mario Negri
	BONARDI Maria Santina Rappresentante del settore infermieristico
ASSENTE	CASCINELLI Dottor Natale Clinico, Libero Professionista
ASSENTE	GALLUS Professor Giuseppe Professore di Statistica Medica, Milano
	GASTALDI Dottor Stefano Psicologo e Psicoterapeuta, Resp. Scient. di Attivecomeprima
	GOLDHIRSCH Professor Aron Direttore Dipartimento di Medicina IEO
ASSENTE	LA PIETRA Dottor Leonardo (ex-officio) Direttore Sanitario IEO
ASSENTE	LOI Dottor Umberto Esperto in materia giuridica
ASSENTE	MARINI Professor Luca Vice Presidente, Comitato Nazionale di Bioetica
	MARTINI Professor Luciano (Presidente) Istituto di Endocrinologia, Università degli studi, MI
ASSENTE	MERZAGORA Dottoressa Francesca Presidente Osservatorio Nazionale sulla Salute della Donna
	NONIS Dottor Atanasio Direttore Ufficio Studi Clinici & Attività Regolarie IEO
	OMODEO SALÈ Dottoressa Emanuela (ex-officio) Direttore Servizio di Farmacia IEO
	PELEGRINI Dottor Maurizio Responsabile Distretto Socio Sanitario, ASL Città di Milano
	ROTMENSZ Dottoressa Nicole Direttore Data Quality Control IEO
	VELLA Monsignor Charles Bioeticista teologo
ASSENTE	VERONESI Professor Umberto (ex-officio) Direttore Scientifico IEO

I componenti del Comitato Etico si attengono a quanto previsto dall'art. 3 punto c del DM 12/5/06.

Cytori Therapeutics

MODULO DI CONSENSO INFORMATO

Numero del protocollo:	RESTORE-2 A
Titolo dello studio:	Valutazione Clinica di Cellule Rigenerative Derivate da Cellule Adipose nel Trattamento di Pazienti con Deformità Mammarie post-Resezione Mammaria Segmentale (Lumpectomia) con o senza Terapia Radiante Fase IV Post Market – Trial <u>RESTORE-2</u>
Consenso Informato	
Data versione modulo:	10 Gennaio 2008
Sponsor:	Cytori Therapeutics, Inc.
Responsabile della Ricerca:	Dr. Mario Rietjens

Il Modulo di Consenso Informato è composto di due parti:

- Foglio Informativo (per le informazioni riguardanti questa ricerca)
- Dichiarazione di consenso (da firmare se accetta di prendervi parte)

Le verrà fornita una copia del modulo di Consenso Informato completo da tenere per sé.

Cytori Therapeutics

FOGLIO INFORMATIVO PER LA PAZIENTE

INTRODUZIONE

Lei è stata invitata a prendere parte a uno studio di ricerca clinica perché ha riportato una lesione mammaria a seguito di una resezione segmentale della mammella (lumpectomia) e della terapia radiante. Per potere decidere se desidera prendere parte a questo studio lei deve disporre di sufficienti informazioni circa i suoi possibili rischi e benefici. Questo modulo di consenso le fornisce informazioni particolareggiate su questo studio, e un medico o altro membro dello staff dello studio ne discuterà con lei. Quando le saranno chiari lo studio e le sue procedure le verrà chiesto se desidera parteciparvi e, in caso di risposta affermativa, le verrà chiesto di firmare questo modulo di consenso.

Questo modulo di consenso potrebbe contenere termini o informazioni che non le sono chiari. La preghiamo di chiedere al medico o al personale dello studio di spiegarle quelle parole o quelle informazioni che non le sono chiari. Lei è libera in qualsiasi momento durante tutto il corso dello studio di fare tutte le domande che desidera. Ha la facoltà di trattenere una copia non firmata di questo modulo di consenso per esaminarlo con calma o per discuterne con i suoi familiari o amici prima di prendere una decisione. Prima di accettare di prendere parte a questo studio si assicuri di avere ricevuto risposta a tutte le sue domande.

SCOPO DI QUESTO STUDIO

Questo è uno studio di ricerca sull'impiego di un dispositivo che viene utilizzato per preparare il grasso e le cellule ottenute dalla paziente per il re-impianto nella mammella (o mammelle) nel tessuto adiposo (grasso) della paziente stessa abbinato a cellule ottenute mediante separazione da una porzione di tale grasso avente allo scopo di correggere anomalie della mammella, da piccole a moderate, provocate dal trattamento che ha ricevuto per il carcinoma alla mammella. L'impiego del dispositivo utilizzato è già stato approvato dalle autorità regolatorie nel Paese in cui viene effettuato lo studio. Il dispositivo di questo studio è stato approvato per re-iniettare nel suo corpo le cellule, rielaborate, ottenute dal suo tessuto adiposo. Lo scopo di questo studio è di raccogliere ulteriori informazioni specificatamente riguardanti l'impiego di questa procedura su donne con anomalie mammarie dopo un carcinoma.

Questo studio è sponsorizzato da Cytori Therapeutics, Inc. che è la ditta produttrice del dispositivo utilizzato per preparare il grasso e le cellule per il re-impianto nella sua mammella (e mammelle) lesionata.

Se lei è qualificata e meno per partecipare a questo studio, nonché le specifiche aree su cui procedere con un intervento correttivo, saranno argomento di discussione tra lei e il medico dello studio.

QUADRO GENERALE

Il trapianto di grasso autologo è una procedura con cui si asporta del grasso da una zona del corpo del paziente per trapiantarlo in un'altra zona del corpo della stessa persona. Il grasso viene prelevato mediante un processo chiamato liposuzione, una procedura ormai seguita da molti anni. Tuttavia essa non ha avuto sempre successo perché il grasso può decomporsi, per cui si rende necessario un trattamento supplementare.

Il dispositivo sviluppato da Cytori Therapeutics consente di utilizzare un metodo diverso. Il dispositivo separa le naturali cellule rigenerative del suo corpo (cioè quelle cellule che possono potenzialmente trasformarsi in altre cellule) che si trovano all'interno dell'effettivo tessuto adiposo e poi le concentra (cioè le rende meno diluite). Queste cellule vengono poi rimescolate in una quantità separata di grasso che era stato messo da parte e che viene quindi re-impiantato nel

Cytori Therapeutics

paziente. Si ritiene infatti che l'aggiunta e la miscelazione di queste cellule concentrate al grasso permettano di re-impiantare quest'ultimo con successo evitando quella decomposizione che subentra quando si re-impia il solo tessuto adiposo.

Questo studio esaminerà questo re-impianto nei tessuti molli della mammella per riempire, delineare o incrementare la massa in quella zona e rimediare così alle anomalie della mammella. Lo studio arruolerà un numero massimo di 70 pazienti con lesioni mammarie a seguito di un trattamento per il carcinoma della mammella.

PROCEDURE DELLO STUDIO

Il suo medico e il personale dello studio decideranno durante il processo di screening se lei è idonea o meno a partecipare a questo studio. Se lei soddisfa tutti i requisiti richiesti per essere idonea a partecipare a questo studio e accetta di prendervi parte firmando questo Modulo di Consenso Informato, la sua partecipazione complessiva a questo studio durerà circa 13 mesi. In questo periodo ci sarà un minimo di cinque visite presso il centro dello studio. Queste visite sono descritte qui di seguito.

Visita di Screening (entro 30 giorni dalla data della visita di Trattamento)

1. Prima di effettuare qualsiasi test previsto dallo studio sarà necessario che lei firmi questo Modulo di Consenso Informato.
2. Verrà registrata la sua storia medica.
3. Verranno registrati tutti i farmaci che sta prendendo o che ha preso entro i 30 giorni dalla data di arruolamento nello studio.
4. Le verranno misurati il peso e l'altezza e sarà effettuato un esame obiettivo abbreviato.
5. Sarà sottoposta ai seguenti esami: un mammogramma per assicurarci che non ci sia una ricorrenza del carcinoma mammario e una MRI (risonanza magnetica a Immagini, analoga a una radiografia) per esaminare il volume delle sue mammelle e per riconfermare che non ci sia una ricorrenza del carcinoma mammario.
6. Il medico dello studio esaminerà la zona (o le zone) da trattare. Il medico determinerà qual è la zona migliore del suo corpo per asportare il grasso mediante liposuzione, il volume del grasso e le cellule che sarà necessario asportare e re-impiantare, e i punti di re-impianto nella mammella (o mammelle).
7. Le mammelle da trattare verranno valutate in base alla gravità della lesione. Le valutazioni sono effettuate mediante questionari chiamati uno Classificazione delle Conseguenze Estetiche (compilati dal suo medico addetto allo studio) e un altro LENT-SOMA (compilati da lei e dal suo medico dello studio).
8. Lei e il suo medico dello studio compilerete quindi dei questionari sulla Valutazione della Soddisfazione per stabilire il suo grado di soddisfazione attuale in merito a: deformità complessiva delle mammelle, simmetria tra le mammelle e segni di cicatrizzazione e pigmentazione della pelle. Inoltre le verrà chiesto di compilare un questionario per valutare la sua attuale Qualità della Vita.
9. Verranno scattate fotografie da cinque angolazioni diverse delle aree da trattare, con lei in posizione eretta. Nelle fotografie la sua identità sarà mantenuta riservata.

Visita di Trattamento (non oltre 30 giorni dalla data della visita di Screening)

La sessione di trattamento si divide in quattro parti; attività di studio pre-trattamento, il prelievo del grasso, re-impianto e attività di studio post-procedura.

Cytori Therapeutics

Attività di studio pre-trattamento:

1. Verrà valutato qualsiasi cambiamento nei farmaci che sta attualmente assumendo.
2. Le verrà fatto un test urinario di gravidanza per assicurarci che non sia gravida nel caso lei sia potenzialmente fertile.
3. Le sarà misurato il peso

Prelevamento di grasso (liposuzione):

1. Per la procedura di liposuzione sarà necessario sottoporla ad anestesia. Il suo medico dello studio deciderà qual è il tipo di anestesia migliore nel suo caso.
2. Il suo medico ha scelto un punto del suo corpo da cui prelevare il grasso. Questo punto potrà trovarsi sul suo addome o sulla coscia, ma potrebbero esserci altre zone (al di sotto del torace e sopra le ginocchia) da cui il medico potrà prelevare una quantità di grasso sufficiente per il trattamento. Le verrà praticata una piccola incisione sulla pelle nel punto in cui prelevare il grasso. Nell'incisione potrà essere iniettata una miscela di soluzione salina per agevolare l'asportazione del grasso. Il medico dello studio preleverà il tessuto adiposo mediante l'ago di una siringa. Per potere disporre di una quantità sufficiente di grasso e di cellule per il re-impianto il medico dovrà prelevare il doppio della quantità di grasso necessaria per il re-impianto.
3. L'incisione sulla sua pelle potrà essere chiusa con una sutura e il suo medico o un infermiere potrà applicare una medicazione o un bendaggio idonei.

Metà del grasso prelevato verrà lavorato dal dispositivo Cytori per lavare il grasso e separarlo dalle cellule rigenerative e concentrare queste ultime (come è stato già descritto in questo Modulo di Consenso Informato). L'altra metà del grasso sarà sottoposta a lavaggio, ma non passerà attraverso il dispositivo della Cytori. Una volta terminato di preparare le due metà queste verranno miscelate insieme per il re-impianto. Questo processo non la coinvolgerà minimamente.

Una piccola quantità del grasso elaborato verrà esaminato per controllare il numero delle cellule che contiene. Questo viene fatto per valutare la qualità della procedura.

Re-impianto:

1. Il suo medico dello studio potrà decidere di impiegare dei farmaci prima del re-impianto per ridurre la possibilità di eventuali emorragie. Questi farmaci possono venire somministrati mediante iniezione o semplicemente applicandoli sulla pelle.
2. La zona del re-impianto verrà pulita.
3. Le verranno praticate circa 3 incisioni da 2 mm sulla pelle, nella zona del re-impianto.
4. Una soluzione anestetizzante può essere iniettata nell'incisione sulla pelle per preparare la zona all'iniezione.
5. Il grasso potenziato con le cellule le verrà iniettato lentamente nella mammella (o mammelle) muovendo costantemente l'ago in tutta la zona del trattamento per distribuire in modo uniforme il grasso potenziato con le cellule.
6. Quando il medico dello studio sarà soddisfatto del risultato, le incisioni sulla sua pelle verranno chiuse con una sutura e il medico o un infermiere potrà applicare una medicazione o un bendaggio idonei.

Attività di studio post-trattamento:

Cytori Therapeutics

1. Il suo medico dello studio esaminerà le zone trattate, farà osservazioni e le chiederà come si sente.
2. Verranno scattate fotografie da cinque angolazioni diverse delle aree trattate, con lei in posizione eretta. Nelle fotografie la sua identità sarà mantenuta riservata..

Potrà tornare a casa quando il medico dello studio reputerà che lei possa farlo in tutta sicurezza. Il medico dello studio potrà prescriberle farmaci antibiotici e/o analgesici se necessario e le dirà di limitare i movimenti nei primi giorni dopo l'intervento. Il medico potrà anche dirle di applicare compresse fredde o impacchi di ghiaccio sulle zone trattate.

Visita di controllo a 3-7 giorni (3-7 giorni dopo la visita di Trattamento)

1. Verrà valutato qualsiasi cambiamento nei farmaci che sta attualmente assumendo.
2. Verrà effettuato un esame obiettivo abbreviato.
3. Il suo medico dello studio esaminerà le zone trattate e le chiederà come si sente.
4. Lei compilerà un questionario per segnalare eventuali dolori, gonfiori o arrossamenti.
5. Verranno scattate fotografie da cinque angolazioni diverse delle aree interessate dallo studio, con lei in posizione eretta. La sua identità sarà mantenuta riservata..

Altre visite di controllo: (6 e 12 mesi dopo la visita di Trattamento)

Le visite al 6° e 12° mese dopo la visita di Trattamento sono visite di controllo, tuttavia il suo medico dello studio potrebbe anche decidere di effettuare un trattamento supplementare (liposuzione e re-impianto) nel corso della visita al 6° mese se lo reputerà necessario. Per potere ricevere i trattamenti supplementari lei dovrà soddisfare le stesse condizioni di qualificazione che erano state richieste per permetterle di partecipare all'inizio. Questa decisione di ricevere trattamenti supplementari verrà presa di concerto tra lei e il suo medico dello studio. Lei potrà anche decidere di non sottoporsi a trattamenti supplementari senza subire penalità e senza che venga modificata la sua assistenza medica.

Sia che lei riceva o meno un trattamento supplementare verranno effettuate le seguenti procedure dello studio. Tuttavia, se lei e il suo medico dello studio decidete che lei riceverà un trattamento supplementare nel corso della visita al 6° mese, queste procedure verranno effettuate prima che venga eseguita la procedura di trattamento.

1. Verrà valutato qualsiasi cambiamento nei farmaci che sta attualmente assumendo.
2. Le verranno misurati il peso e le verranno misurate l'altezza (solo nel corso della visita del 12° mese) e sarà effettuato un esame obiettivo abbreviato.
3. Il suo medico dello studio esaminerà le zone trattate e le chiederà come si sente.
4. Alla sua mammella (o mammelle) verrà assegnata una Classificazione delle Conseguenze Estetiche (come già fatto allo Screening).
5. Lei e il suo medico compilerete separatamente il questionario LENT-SOMA (come già fatto allo Screening).
6. Lei sarà sottoposta a MRI per esaminare il volume delle mammelle.
7. Lei e il suo medico dello studio compilerete quindi dei questionari sulla Valutazione della Soddisfazione per stabilire il suo grado di soddisfazione attuale in merito a: deformità complessiva delle mammelle, simmetria tra le mammelle e segni di cicatrizzazione e pigmentazione della pelle e soddisfazione complessiva riguardo ai risultati del trattamento.

Cytori Therapeutics

8. Lei compilerà un questionario per segnalare eventuali dolori, gonfiori o arrossamenti.
9. Verranno scattate fotografie da cinque angolazioni diverse delle aree interessate dallo studio, con lei in posizione eretta. La sua identità sarà mantenuta riservata.
10. Le verrà chiesto di compilare un questionario per valutare la sua attuale Qualità della Vita.

Se lei e il suo medico dello studio decidete che lei riceverà un trattamento supplementare nel corso della visita al 6° mese, le verranno effettuate le seguenti attività supplementari dello studio.

Attività di studio pre-trattamento:

1. Il suo medico dello studio o il personale addetto valuteranno se lei è idonea o meno a ricevere un trattamento supplementare.
2. Le verrà fatto un test urinario della gravidanza per assicurarci che non sia gravida nel caso lei sia ancora potenzialmente fertile.
3. Il suo medico dello studio determinerà qual è la zona migliore del suo corpo per prelevare il grasso mediante liposuzione, il volume del grasso e le cellule che sarà necessario asportare e re-impiantare, e i punti di re-impianto nella mammella (o mammelle).

Verranno quindi effettuati il prelievo e il re-impianto del grasso secondo le modalità descritte nel corso della prima Visita di Trattamento.

Attività di studio post-trattamento:

1. Il suo medico dello studio esaminerà la zona (o le zone) trattate e farà le sue osservazioni.
2. Le verrà chiesto come si sente.
3. Verranno scattate fotografie da cinque angolazioni diverse delle aree trattate, con lei in posizione eretta. Nelle fotografie la sua identità sarà mantenuta riservata (si noti che verranno scattate fotografie prima e dopo ogni ri-trattamento, perciò in quei giorni avrà due serie di fotografie).

Potrà tornare a casa quando il medico dello studio reputerà che lei possa farlo in tutta sicurezza. Il medico dello studio potrà prescrivere farmaci antibiotici e/o analgesici se necessario e le dirà di limitare i movimenti nei primi giorni dopo l'intervento. Potrà anche dirle di applicare compresse fredde o impacchi di ghiaccio sulle zone trattate.

POTENZIALI RISCHI

Pur non essendo completamente noti tutti i possibili effetti collaterali del re-impianto nella mammella di grasso miscelato con cellule rigenerative, si ritiene che tali effetti non siano molto diversi dai possibili effetti collaterali della liposuzione e del tradizionale re-impianto di grasso. I possibili effetti collaterali della liposuzione e del tradizionale re-impianto di grasso sono noti e generalmente di lieve entità, e la ripresa è di solito rapida. Sussistono alcuni effetti collaterali a lungo termine. Nelle aree del trattamento possono verificarsi i seguenti effetti collaterali:

- Gonfiore
- Arrossamento
- Dolenzia
- Sensazione di formicolio
- Modesti lividi
- Calcificazione (depositi di calcio)

Cytori Therapeutics

Gli effetti collaterali meno frequenti comprendono:

- Gonfiori che durano per diverse settimane
- Emorragie che durano per più di 2 settimane
- Ristagni di sangue sotto pelle che possono apparire come lividi o rigonfiamenti
- Punti di puntura visibili
- Cisti oleose
- Necrosi adiposa

Tra le complicanze rare figurano:

- Infezione
- Indurimento del punto di re-impianto

Partecipando a questa ricerca è possibile che lei possa provare qualche piccolo disagio a causa di alcune procedure dello studio, come per esempio le iniezioni praticate per l'anestesia.

Possono inoltre presentarsi anche altri effetti collaterali o disagi che non sono noti o non sono prevedibili e quindi non sono elencati in questo Modulo di Consenso Informato. La preghiamo di discutere col suo medico dello studio qualsiasi preoccupazione che possa avere riguardo alla sua partecipazione allo studio.

GRAVIDANZA

La partecipazione a questo studio potrebbe comportare possibili rischi (al momento imprevedibili) per il soggetto, per il nascituro o per il neonato in allattamento se la paziente dovesse rimanere incinta durante lo studio o ha intenzione di allattare durante lo svolgimento dello studio. Perciò se lei è incinta o allatta al seno o intende rimanere incinta o allattare al seno nel corso di svolgimento dello studio non è idonea a parteciparvi. Se è potenzialmente fertile dovrà acconsentire a utilizzare un'accettabile forma di controllo delle nascite durante lo svolgimento dello studio. Questi metodi comprendono i contraccettivi ormonali autorizzati come le pillole anticoncezionali (se permesse dal ricercatore), metodi barriera (come profilattico o diaframma usati in abbinamento a uno spermicida), o dispositivo intrauterino (IUD o spirale). La preghiamo di discutere il metodo di controllo delle nascite che intende usare (se applicabile) col suo medico dello studio.

RESTRIZIONI/REQUISITI NEL CORSO DELLO STUDIO

Le verrà chiesto di interrompere qualsiasi uso cronico (>7 giorni consecutivi) di farmaci anticoagulanti (come l'aspirina) o antinfiammatori non steroidei (FANS) nei 15 giorni precedenti al suo arruolamento nello studio. Dovrà inoltre assicurarsi di non prendere questi farmaci in modo cronico nei 15 giorni precedenti alla sua visita di controllo al 6° mese nel caso lei e il suo medico dello studio decideste che necessita di un altro ri-trattamento in occasione di quella visita. In caso contrario non le sarà permesso di essere sottoposta a ri-trattamento. Se per motivi medici non è in condizioni di potere interrompere l'uso dei farmaci sopra indicati, non sarà in grado di partecipare a questa ricerca clinica.

Non potrà partecipare a questo studio se ha intenzione di sottoporsi a un intervento chirurgico per la riduzione del peso o se ha intenzione di guadagnare o perdere una significativa quantità di peso nel corso della sua partecipazione a questo studio (modifica dell'indice di massa corporea (BMI) maggiore di 5 rispetto al momento in cui è stata arruolata per lo studio).

Potrà essere arruolata per questo studio solo una volta. Una volta arruolata, sarà considerata parte dello studio e non potrà ripartecipare allo studio una volta terminata la partecipazione.

Cytori Therapeutics

Inoltre non potrà essere arruolata in qualsiasi altro studio di ricerca clinica che possa interferire con la sua partecipazione a questo studio. Non manchi di discutere immediatamente qualsiasi sua partecipazione ad altro studio col suo medico.

POSSIBILI BENEFICI

Se deciderà di partecipare a questo studio, potrà avere il vantaggio di poter correggere la sua attuale lesione mammaria. Tuttavia, non possiamo garantirle che trarrà un beneficio personale dalla sua partecipazione a questo studio di ricerca.

PROCEDURE ALTERNATIVE

Se deciderà di non partecipare a questo studio, Le saranno proposte e saranno altre procedure alternative disponibili per lei, come il rimodellamento e/o la riduzione della mammella che discuterà. ~~Si assicuri di discutere tutte le possibilità di trattamenti alternativi con il suo medico dello studio.~~

PRIVACY E RISERVATEZZA

I suoi dati di carattere medico verranno resi disponibili a persone autorizzati da Cytori (clinical monitor, coordinatori dello studio, auditor sia dipendenti di Cytori che di altra organizzazione), al solo scopo di accertare periodicamente la corrispondenza dei dati contenuti nelle schede raccolta dati anonime conservate da Cytori con quelle contenute nella cartella clinica conservate dall'istituto ed eventualmente al Comitato Etico ed alle Autorità Regolatorie, per la valutazione ed il controllo delle procedure e/o dei dati raccolti.

Tutto ciò verrà fatto in accordo con le leggi e normative in vigore e mantenendo assoluta riservatezza. Firmando il presente modulo, Lei acconsente a quanto sopra esposto.

In particolare Lei accetta che siano trattati oltre ai dati comuni, anche i Suoi dati personali così detti "sensibili" cioè idonei a rivelare il Suo stato di salute (ai sensi del D.Lgs n. 193/03).

Lei acconsente che le informazioni ottenute attraverso il presente studio, inclusi i risultati di tutti gli esami che la riguardano, vengano conservate in sistemi di archiviazione computerizzati e cartacei, nei quali Lei non sarà identificata per nome. Lei accetta inoltre che questi dati siano utilizzati per la registrazione del prodotto e vengano quindi resi disponibili alle Autorità Regolatorie e che siano analizzati dal personale dell'azienda farmaceutica o da terzi, all'interno dell'Unione Europea o negli Stati Uniti. Questi dati verranno conservati per un periodo necessario e sufficiente e potranno essere presentati in occasione di convegni o pubblicazioni; in ogni caso, la Sua identità sarà mantenuta riservata e non verrà resa pubblica.

Nel quadro di questo studio, verranno scattate fotografie in alcune parti del suo corpo. Ogniquale volta la sua identità sarà mantenuta riservata.. I risultati di questo studio potranno venire pubblicati. Non verrà inclusa alcuna informazione personale che possa essere utilizzata per identificarla.

COSTI DELLO STUDIO

Non sono previsti costi a suo carico legati alla partecipazione ~~le saranno addebitati i costi relativi~~ allo studio. I costi relativi allo studio comprendono i costi connessi alla liposuzione, alla lavorazione delle cellule adipose, alle procedure del trattamento e ad altre procedure dello studio richieste per lo svolgimento di questo studio.

COMPENSI

Per la sua partecipazione a questo studio non le verrà corrisposto alcun compenso.

Cytori Therapeutics

LESIONI E ASSISTENZA DI EMERGENZA

Se riportasse una qualsiasi lesione o si ammalasse come conseguenza diretta del trattamento o delle procedure dello studio riceverà assistenza medica specialistica senza che le venga addebitato alcun costo.

Cytori Therapeutics, Inc. (lo sponsor di questo studio) non sarà responsabile di alcun costo imputabile a negligenza delle persone coinvolte in questo studio, dall'istituto o se lei non seguirà le istruzioni relative allo studio. Cytory non coprirà i costi sanitari di lesioni, ferite o danni non connessi al trattamento dello studio o imputabili al decorso naturale di una malattia o di un trattamento preesistente.

Nel caso lei riporti qualche lesione o contragga una malattia come conseguenza diretta della sua partecipazione allo studio, Cytory Therapeutics (lo sponsor dello studio) è coperta da un'assicurazione, polizza n. 010109869C, con la compagnia ACE EUROPEAN GROUP LIMITED.

NUOVE SCOPERTE SIGNIFICATIVE

Se nel corso dello studio verranno alla luce nuove informazioni che potrebbero modificare la sua decisione di continuare a partecipare a questo studio. In questo caso il personale addetto la informerà tempestivamente e lei potrà decidere se vorrà o meno continuare a partecipare allo studio.

CONCLUSIONE ANTICIPATA

Lei potrà decidere di interrompere la sua partecipazione a questo studio in qualsiasi momento senza alcuna influenza sulle cure che riceve regolarmente o sui benefici a cui ha diritto. Lo sponsor o il medico dello studio potrà inoltre decidere di interrompere la sua partecipazione allo studio in qualsiasi momento (per esempio nel caso che non segua le istruzioni del medico dello studio o se riterranno che l'interruzione sarà nel suo interesse). Se lei, il suo medico dello studio o lo sponsor interromperete la sua partecipazione per qualsivoglia motivo prima del completamento dello studio, le verrà chiesto di sottoporsi a una valutazione finale. Lei non sarà tenuta a sottoporsi a questa visita se ritirerà il suo consenso, tuttavia questa valutazione è importante per la sua salute e la sua sicurezza.

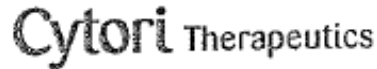
PERSONA DA CONTATTARE

Se ha qualche domanda riguardo alla ricerca o se subirà qualche lesione connessa a questa ricerca, dovrà contattare Dr. Rietjens al 02-57489 723. Se ha qualche domanda da fare circa i suoi diritti come soggetto di una ricerca o reclamo che non può presentare al Dr. Rietjens potrà rivolgersi al Comitato Etico dell' IRCCS Istituto Europeo di Oncologia di Milano in Via Ripamonti, 435 o telefonare: 0257489848

PARTECIPAZIONE VOLONTARIA

La Sua partecipazione allo studio è volontaria. La sua decisione di parteciparvi o meno non influirà sui suoi rapporti col Dr. Rietjens né sulla sua attuale o futura assistenza sanitaria. Se deciderà di parteciparvi sarà libera di cambiare idea e di interrompere la partecipazione allo studio ritirando in qualsiasi momento il suo consenso. La sua decisione di non prendere parte allo studio non influirà in nessun modo sulle cure che riceve regolarmente o sui benefici a cui ha diritto

11.2 TERMO DE CONSENTIMENTO LIVRE E ESCLARECIDO PÓS- INFORMADO



DICHIARAZIONE DI CONSENSO: Studio RESTORE-2

Io sottoscritto, _____ ho letto il foglio informativo per la paziente e acconsento volontariamente a prendere parte, come paziente allo studio di ricerca clinica RESTORE-2 A.

Mi è stata fornita una copia del testo del modulo di consenso informato e mi sarà data una copia del relativo consenso informato, firmato e datato. Mi sono stati spiegati la natura, lo scopo, la durata dello studio, i possibili rischi e benefici. Mi sono stati illustrati i trattamenti alternativi disponibili. Mi è stato fornito sufficiente tempo e mi è stata data l'opportunità per rivolgere delle domande. A tutte le mie domande hanno dato risposte in modo esauriente.

Accetto di collaborare pienamente con il medico ed il personale infermieristico e riferirò loro qualunque effetto collaterale, sintomo o variazione dello stato di salute che dovessero verificarsi. Ho elencato al medico tutti i farmaci, prescritti e da automedicazione, che sto assumendo o che ho assunto prima dell'inizio della mia partecipazione allo studio.

Sono stato informato(a) dell'esistenza di una copertura assicurativa in caso di danni attribuiti alle procedure e trattamenti dello studio.

Sono consapevole che questo studio è stato esaminato ed approvato da un Comitato Etico Indipendente (IEC).¹

Sono consapevole che sono libera di ritirarmi dallo studio in qualunque momento e per qualunque motivo, senza che ciò interferisca negativamente sulle mie cure mediche future.

Acconsento che i risultati dello studio possano essere trasferiti alle autorità competenti ed allo sponsor dello studio. Il mio nome, indirizzo e numero telefonico saranno mantenuti segreti.

Sono consapevole che rappresentanti dallo sponsor, dell' IEC e delle Autorità Regolatorie competenti possano voler esaminare i miei dati medici. Sono stato rassicurato(a) sul fatto che le informazioni raccolte saranno mantenute strettamente confidenziali secondo quanto stabilito dalla normativa vigente (D.Lgs. n. 196/03). Firmando questo documento, acconsento all'accesso diretto a qualunque informazione che fornirò in corso di studio.

Firma della Paziente

Data

Nome in stampatello

Confermo di aver spiegato la natura, lo scopo, la durata dello studio e i potenziali rischi e benefici alla paziente. La paziente ha acconsentito a partecipare allo studio firmando e datando personalmente questo modulo.

Firma della persona che ha condotto il colloquio per il consenso

Data

Nome in stampatello