



Abstract

Immunohistochemical localization of estrogen α and β receptors in adult stallion epididymis[☆]

I. Martin^{a,*}, C.M. Melo^a, M.M.P. Rodrigues^b, G.A. Monteiro^a, P.N. Guasti^a, L.C.O. Magalhães^a, R. Laufer-Amorim^b, F.O. Papa^a

^a Department of Animal Reproduction and Veterinary Radiology, School of Veterinary Medicine and Animal Science, Unesp, Botucatu, Distrito de Rubião Jr, s/n, SP, Cep 18618-000, Brazil

^b Department of Clinical Veterinary Medicine, School of Veterinary Medicine and Animal Science, Unesp, Botucatu, Distrito de Rubião Jr, s/n, SP, Cep 18618-000, Brazil

1. Introduction

Steroid hormones like testosterone and estradiol are primarily produced in the testes, delivered to the epididymides by the systemic circulation, and exert their effects by binding to specific receptors in the target tissue (Hess et al., 2002). There is evidence that estrogens are also important for epididymal function (Hess et al., 1997), mainly in species like the horse, where the testes produce large amounts of estrogens (Stewart and Roser, 1998). The importance of estrogens for proper epididymal function is most clearly demonstrated in estrogen receptor knockout mice which have significantly impaired fluid reabsorption from the efferent ducts, abnormal epididymal morphology and abnormal epididymal sperm (Eddy et al., 1996). Testosterone and estradiol may regulate the epididymal secretion of many proteins and other factors important for sperm maturation (Parlevliet et al., 2006). The present study investigated whether the stallion epididymis is an estrogen responsive tissue and also characterized changes in the localization of the estrogen receptor subtypes α (ER α) and β (ER β) among the different regions of the epididymis.

2. Materials and methods

The caput, corpus and cauda of the epididymis were collected from seven adult stallions, 5 years old, castrated during the breeding season. The tissue specimens, approximately 5 mm in diameter were washed in saline, placed in plastic cassettes for inclusion, fixed in 10% buffered formalin for 24 h and stored in 70% ethanol until embedding in paraffin. Four micrometers tissue sections were mounted onto glass slides previously treated with Organosilane (Sigma Chemical Co., USA). Sections were deparaffinized with xylene and rehydrated in graded alcohol. The slides were then washed in tap water for 10 min. For antigen retrieval, sections were microwaved for three periods of 5 min in sodium citrate 10 mM (pH 6.0) solution (ER β) or in a Pascal pressure chamber (Dako, USA) also in sodium citrate solution (ER α). After heating, slides were allowed to cool for 20 min and then washed 10 times in distilled water. Endogenous peroxidase activity was quenched with 8% peroxidase solution for 20 min (two periods of 10 min) followed by 10 baths in distilled water and incubation with a 3% milk solution for 1 h at room temperature for blocking. Slides were then washed in Tris buffered solution 10 mM (pH 7.4), encircled using DakoPen (Dako, USA) and incubated with the primary mouse anti-human-ER α monoclonal antibody (clone 1D5, Dako, USA), diluted 1:50 in antibody diluent (Antibody Diluent with Background Reducing Components, Dako, USA) or with the primary mouse anti-human-ER β monoclonal antibody (clone PPG5/10, Dako, USA), diluted 1:100 in antibody diluent. Both were incubated in a humidified chamber for 18 h at 4 °C. Then, slides were washed in Tris buffered solution and incubated with the secondary antibody (Advance,

[☆] This paper is part of the supplement entitled "Proceedings of the Tenth International Symposium on Equine Reproduction". Guest Edited by Margaret J. Evans.

* Corresponding author. Tel.: +55 14 38116249; fax: +55 14 38116249. E-mail address: ianmartin@uol.com.br (I. Martin).

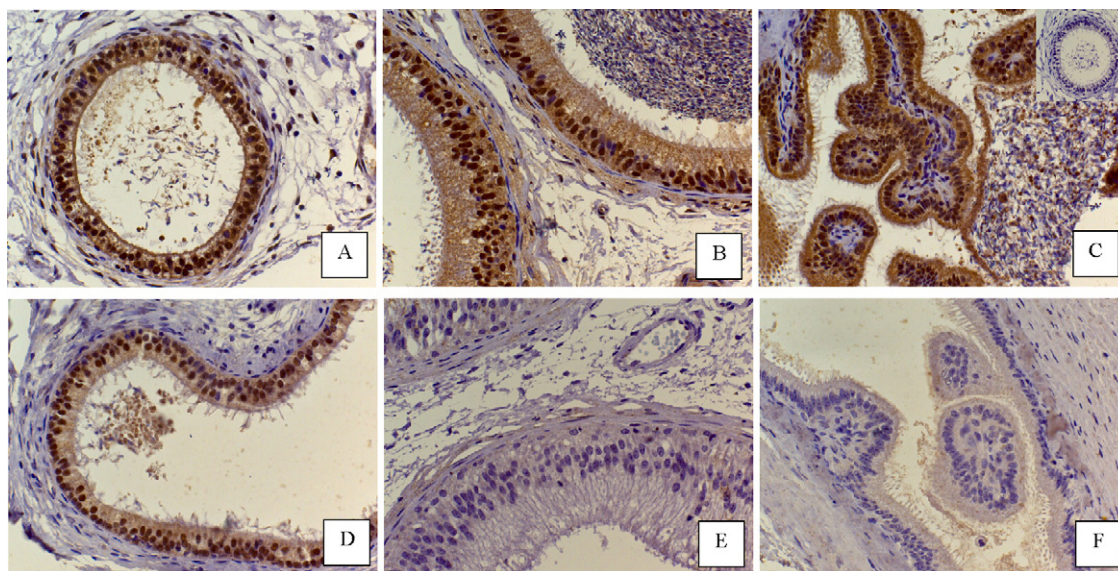


Fig. 1. Immunolocalization of ER β in caput (A), corpus (B) and cauda (C) of the stallion epididymis. Immunolocalization for ER α in caput (D), corpus (E) and cauda (F) of the stallion epididymides. Negative control, inset in C. Immunohistochemistry, DAB, counterstaining with Mayer's hematoxylin, magnification of 400 \times .

Dako, USA) for 30 min with each reagent in a humidified chamber, according to manufacturer instructions. Each tissue section was washed in Tris buffered solution, and DAB chromogen (3,3'-diaminobenzidine, Dako, USA) was added as a chromogen staining substrate for 5 min. Reaction was stopped by rinsing in Tris buffered solution. Tissue sections were counterstained with Mayer's hematoxylin for either 3 min (ER β) or 1 min (ER α), dehydrated and preserved using Permount (Fisher Scientific, USA) mounting medium. For negative controls, another section was incubated with mouse immunoglobulin (N-Universal Negative Control Mouse, Dako, USA) instead of primary antibody.

For the evaluation of immunoreactivity, stained sections were observed and photographed using a Leica DML optical microscope (Leica Microsystems, DMLB, Germany) at magnifications of 400 \times , with an image analyzer program (Leica QWin Standard V2.5). Both positively and negatively staining nuclei were evaluated in all slides.

3. Results

Immunolocalization for ER β was observed in caput, corpus and cauda of the epididymides. The great majority of epithelial cells (basal and principal cells) were strongly positive. Smooth muscle presented more sporadic staining with more positive cells observed in the caput, half of the cells positive in the corpus and more negative cells in the cauda. Connective tissue presented the majority of positive cells in the caput and half of the cells positive in corpus and cauda. Spermatozoa present in the lumen were always negative. Endothelial cells were positive in all three evaluated regions and vascular smooth muscle cells presented more positive cells in the caput and half of the cells positive in the corpus and cauda (Fig. 1).

Immunolocalization for ER α was observed only in caput, with corpus and cauda remaining negative. Immunos-

taining for ER α was always weaker when compared to ER β . ER α was localized in basal and principal cells of the caput, was absent in the majority of the smooth muscle and connective tissue with some cells presenting a weak immunostaining. Spermatozoa present in the lumen, vascular smooth muscle cells and endothelial cells were negative. No staining was seen in negative control (Fig. 1).

4. Discussion

Results show that the estradiol receptor is present in the epididymides of the stallion and that subtype β is more expressed in all regions of the epididymis. These findings reinforce that estrogens are involved in epididymal function (Hess et al., 1997) and corroborate the findings of Parlevliet et al. (2006) with respect to ER β . Hejmej et al. (2005) also evaluated the intensity of the staining; although our findings were similar for ER β , the intensity of the staining was stronger in the present than previous study. Findings in the present study differ from those of Parlevliet et al. (2006) and Hejmej et al. (2005) with respect to ER α , because no immunostaining was found in the corpus and cauda of epididymides.

In conclusion, these results suggest that the stallion epididymis is responsive to estrogens and that this hormone is important for proper epididymal function. Regional differences in estrogen regulation are probably due to differences in receptor expression.

Acknowledgement

To Fapesp for financial support.

Conflict of interest

None.

References

- Eddy, E.M., Washburn, T.F., Bunch, D.O., Goulding, E.H., Gladen, B.C., Lubahn, D.B., Korach, K.S., 1996. Targeted disruption of the estrogen receptor gene in male mice causes alteration of spermatogenesis and infertility. *Endocrinology* 137, 4796–4805.
- Hejmej, A., Gorazd, M., Kosiniak-Kamysz, K., Wisznieska, B., Sadowska, J., Bilinska, B., 2005. Expression of aromatase and oestrogen receptors in reproductive tissues of the stallion and a single cryptorchid visualised by means of immunohistochemistry. *Domest. Anim. Endocrinol.* 29, 534–547.
- Hess, R.A., Bunick, D., Lee, K.H., Bahr, J.M., Taylor, J.A., Korach, K.S., Lubahn, D.B., 1997. A role for oestrogens in the male reproductive system. *Nature* 390, 509–512.
- Hess, R.A., Zhou, Q., Nie, R., 2002. The role of estrogens in the endocrine and paracrine regulation of the efferent ductules, epididymis and vas deferens. In: Robaire, B., Hinton, B.T. (Eds.), *The Epididymis: From Molecules to Clinical Practice*. Kluwer Academic/Plenum Publishers, New York, pp. 317–337.
- Parlevliet, J.M., Pearl, C.A., Hess, M.F., Famula, T.R., Roser, J.F., 2006. Immunolocalization of estrogen and androgen receptors and steroid concentrations in the stallion epididymis. *Theriogenology* 66, 755–765.
- Stewart, B.L., Roser, J.F., 1998. Effects of age, season, and fertility status on plasma and intratesticular immunoreactive (IR) inhibin concentrations in stallions. *Domest. Anim. Endocrinol.* 15, 129–139.