



The Use of Fragments of Thin Veneers as a Restorative Therapy for Anterior Teeth Disharmony: A Case Report with 3 Years of Follow-up

Ricardo Coelho Okida, Aljomar José Vechiato Filho, Valentim Adelino Ricardo Barão, Daniela Micheline dos Santos
Marcelo Coelho Goiato

ABSTRACT

Aim: The present case report described the use of contact lens of thin porcelain veneers as a restorative therapy to solve anterior teeth disharmony.

Background: Fragments of thin veneers are minimally invasive restorations with little or no dental preparation and present thickness ranging from 0.2 to 0.5 mm. They are used in case of diastema closure, small changes of teeth, color and restoration of teeth with small fractures.

Case report: A 25-year-old man was admitted at a dental clinic complaining about the diastema presence on the upper anterior teeth. Patient was referred to an orthodontic treatment in order to provide better distribution of the diastemas and harmonious proportion of the teeth. Afterwards, contact lens of thin porcelain veneers were fabricated on the six upper anterior teeth.

Conclusion: Based on the outcomes of this clinical report, we considered the use of fragments of thin veneers as a successful treatment option after 3 years of follow-up.

Clinical significance: The fragments of thin veneers have been established to be an interesting alternative to esthetically restore the anterior teeth with minimal invasiveness. However, since it is a new treatment modality, longitudinal studies are necessary to understand the material's behavior.

Keywords: Porcelain, Dental contact lens, Diastema, Oral rehabilitation, Dental esthetic, Clinical case.

How to cite this article: Okida RC, Filho AJV, Barão VAR, dos Santos DM, Goiato MC. The Use of Fragments of Thin Veneers as a Restorative Therapy for Anterior Teeth Disharmony: A Case Report with 3 Years of Follow-up. *J Contemp Dent Pract* 2012;13(3):416-420.

Source of support: Nil

Conflict of interest: None declared

BACKGROUND

The advent of new restorative materials and new technologies in oral rehabilitation during the past 30 years

improved the restorative dentistry field. There are a variety of approaches to treat the different cases of shape, position, alignment, symmetry, proportion, surface texture and color of anterior teeth in our daily practices.¹ Thus, the clinician should choose more conservative treatments, i.e. with greater preservation of healthy dental structure. The porcelain veneers have been used as a successful approach to solve esthetic problems in anterior region.

The use of fragments of thin veneers also known as contact lens is an innovative technique in the restorative and esthetic dentistry fields. These restorations are minimally invasive with reduced or no dental preparation, which is their principal advantage,²⁻⁵ present 0.2 to 0.5 mm thickness^{1,5} and can be used to redraw the smile, increase the teeth size, change teeth format and reduce the diastema.⁶ Nevertheless, it is imperative for the patient to have good oral hygiene and to take care when chewing hard foods.⁴

Therefore, the aim of this report was to describe step-by-step the clinical process of the use of contact lens of thin porcelain veneers as a therapy to solve esthetic disharmony in the anterior teeth.

CASE REPORT

A 25-year-old man was admitted at the Aracatuba Dental School, São Paulo State University, Brazil complaining about the diastema presence and color alteration on the upper anterior teeth (Fig. 1). Diagnostic impressions were made using stock trays with irreversible hydrocolloid (Hydrogum, Zhermack SpA Rovigo, Italy) then poured in dental stone (Gesso-Rio, Orlando Antonio Bussioli-ME, Rio Claro, SP, Brazil). Several treatment options (direct composite veneers, porcelain veneers, contact lens of thin porcelain veneers) were discussed with the patient in relation to life expectancy,

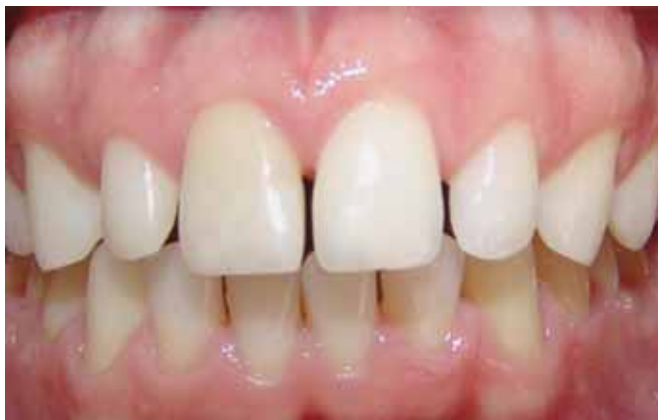

Fig. 1: Initial clinical aspect

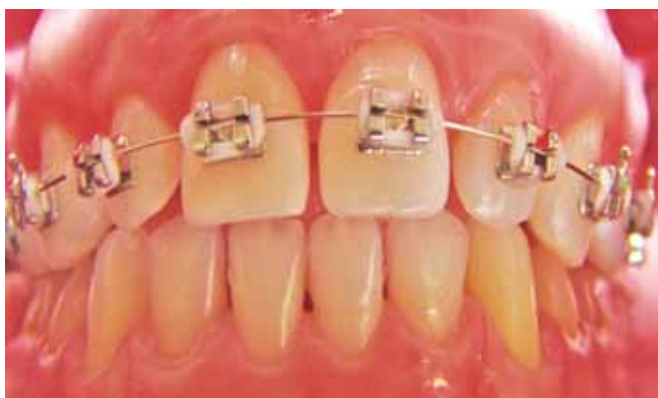

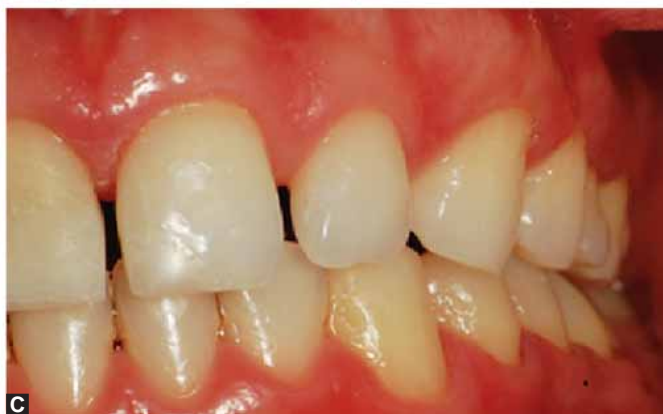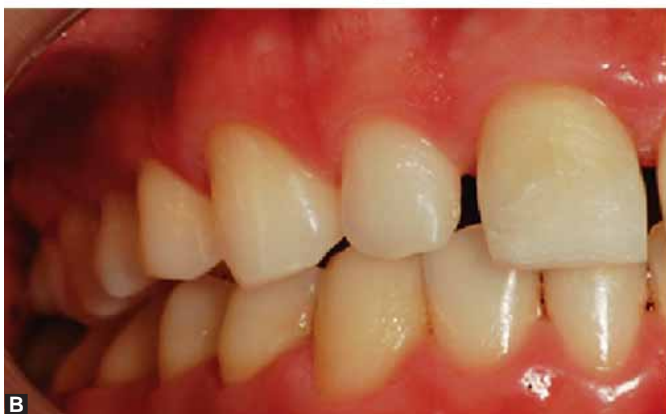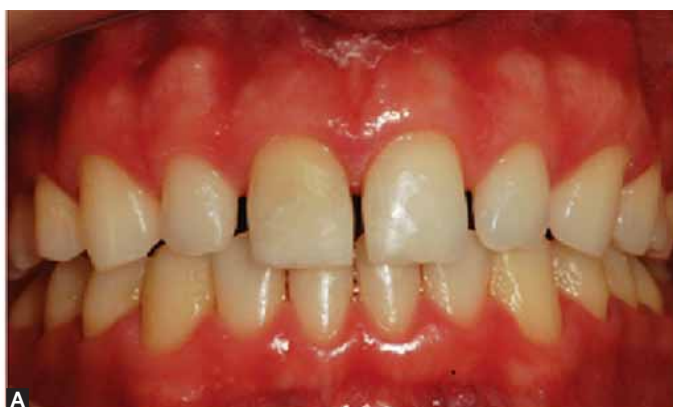Fig. 2: Fixed retainer installed

invasiveness, esthetic results, clinical time and cost. The patient chose rehabilitation with contact lens of thin porcelain veneers. The driving forces toward patient's decision were that contact lens of thin porcelain veneers provide a durable, stain-resistant surface and conserve the dental structure.

After deciding the treatment approach, patient was referred to an orthodontic treatment in order to provide better distribution of the diastemas, harmonious proportion of the teeth, and to balance the midline (Fig. 2). After 1 year of bracketed orthodontic treatment, a removable retainer was manufacture in order to maintain the distributed spaces among the anterior teeth.

Patient underwent a home bleaching teeth with 16% carbamide peroxide (Whiteness perfect, FGM, Joinville, SC, Brasil) during 2 weeks. After that, very conservative teeth preparation was carried out in the six anterior upper teeth. The mesial and distal interproximal areas of the central and lateral incisors and canines were slightly reduced. The facial surfaces were slightly shaped and a gentle subgingival chamfer margin was created. The corners of the prepared teeth were slightly rounded. Preparations involved no more than 0.2 mm of tooth reduction so, that the veneers would be very thin and healthy teeth structure preserved (Figs 3A to C).

Impressions of the prepared teeth were made using vinyl polysiloxane impression material (Aquasil ULV, Dentsply,



Figs 3A to C: Clinical aspects of the prepared teeth: (A) Frontal view; (B) right lateral view; (C) left lateral view

Caulk Milford, DE, USA). Size # 0 gingival retraction cord (Ultrapak, Ultradent Products, Inc., South Jordan, UT, USA) was used to expose the cervical margins of the preparations. The patient was provided provisional veneers fabricated with direct composite resin (Filtek Z250, 3M Espe, St Paul, Minnesota, USA) using a mock-up. They were slightly bonded with the same resin material after spot-etching the prepared teeth. On the master cast, the six contact lens of thin porcelain veneers were fabricated using the shade of a Vita B1 ceramic (IPS Emax, Ivoclar Vivadent, Barueri, SP) through standard laboratory protocol (Figs 4 and 5).

Based on the try-in, a colorless luting agent was chosen. A 16% fluoride acid (Dentsply, Petrópolis, Rj, Brazil) was applied in the inner surface of the restorations during 2 minutes, thoroughly washed and dried. A silane coupling agent (Prosil, FGM Produtos Odontológicos, Joinville, RS, Brazil) was applied to the internal etched surfaces of the veneers. The prepared teeth were cleaned and etched for 60 seconds with 32% phosphoric acid (Dentsply, Petrópolis, Rj, Brazil), rinsed and dried. Three layers of one-step bonding agent (Prime and Bond 2.1, Dentsply) were applied to the surfaces and photopolymerized during 20 seconds each layer (Figs 6A and B).

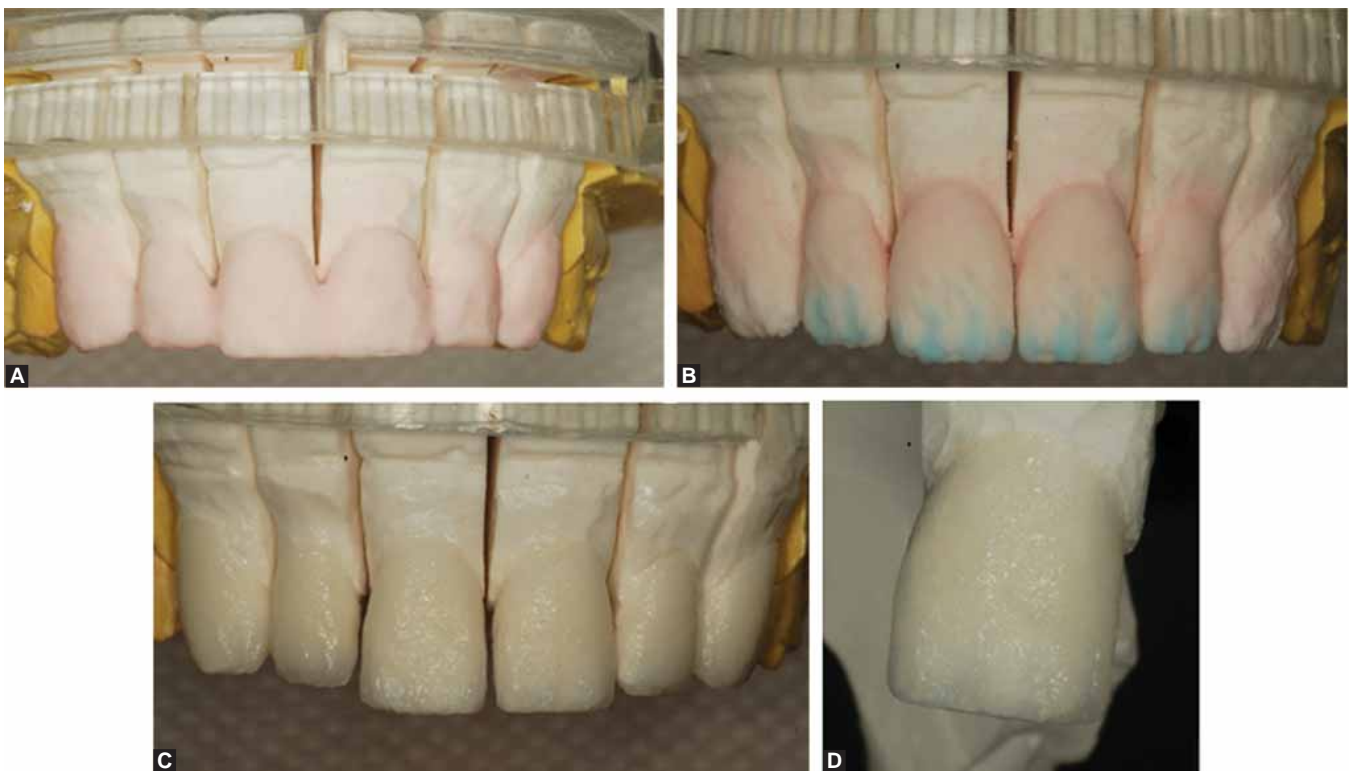
A dual-curing luting agent (Variolink, Ivoclar Vivadent AG, Schaan, Liechtenstein) was mixed and applied to the internal surfaces of the veneers. The veneers were placed on the prepared teeth and held in place. A slightly photo-

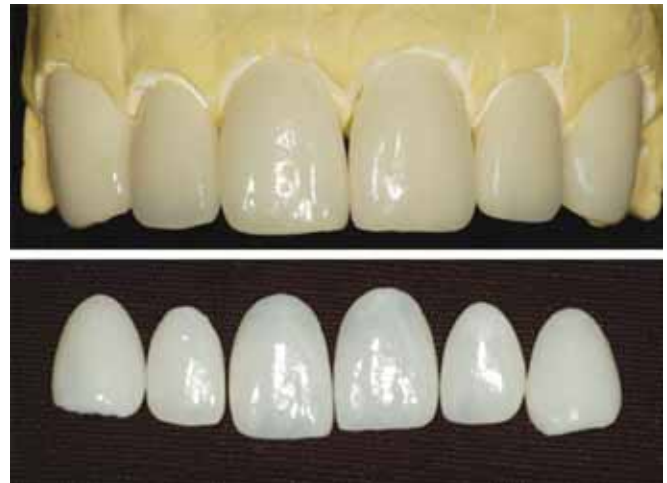

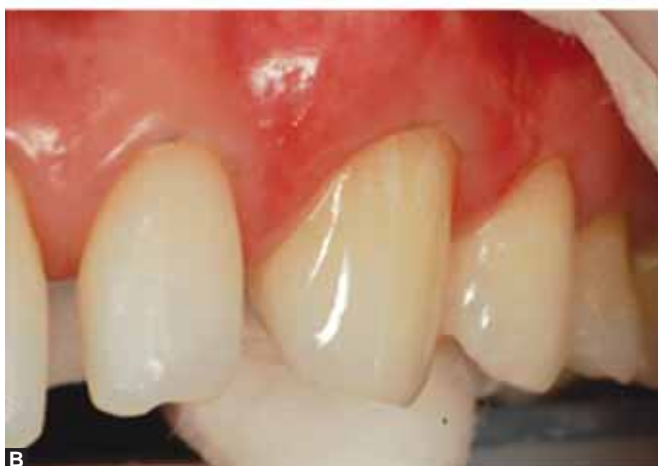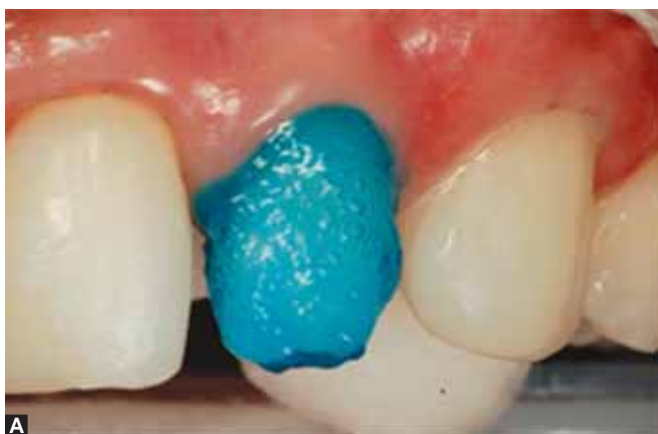Fig. 5: Laboratorial aspect of the contact lens

polymerization was performed during 10 seconds on the buccal surface of the veneers just to remove the excess of luting agent from the margins using a thin scaler. The final photopolymerization was carried out during 60 seconds on each face of the restorations. The margins were slightly finished with carbide finishing bur and rubber cup (Enhance, Dentsply, Petrópolis, Rj, Brasil). Occlusal contacts were checked (Figs 7A and B).

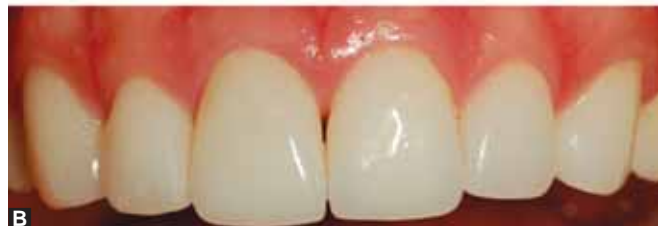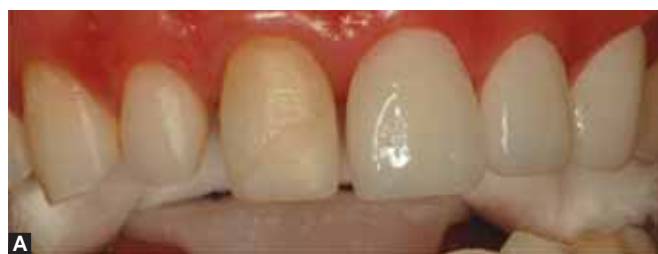Detailed instructions regarding maintenance and oral hygiene were given to the patient. The patient was recalled at 6 months intervals. Three years of follow-up showed no visible deterioration in the veneers and the periodontal



Figs 4A to D: Laboratorial procedure to fabricate the contact lens with IPS Emax system: (A) Application of ceramic body; (B) Incisal characterization; (C) aspect of the ceramic its firing; (D) close-up view of the ceramic after its firing



Figs 6A and B: Teeth preparation to receive the contact lens: (A) Phosphoric acid application; (B) adhesive application



Figs 7A and B: Clinical aspect of the contact lens: (A) Try-in; (B) Final aspect after contact lens cementation

tissues remained healthy (Fig. 8). The patient considered the treatment outcome both esthetically and functionally satisfactory.

DISCUSSION

In this study, the fragments of thin veneers were chosen to close the patient's diastemas. The dental preparation of this

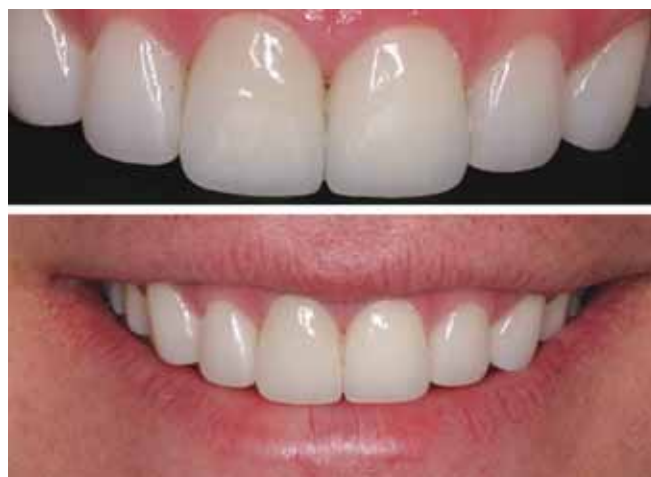

Fig. 8: Clinical aspect of the contact lens after 3 years of follow-up

type of restoration when necessary reduces a small amount of enamel (0.2-0.5 mm) and do not affect dentin.⁶ The main advantage of using fragments of thin veneers is the minimal or no necessity of preparation of the healthy tooth. It makes such treatment an excellent alternative of esthetic oral rehabilitation. However, the success of esthetics restorations depends on several factors, such as integration of the restoration with the surrounding periodontal tissue.⁷ In this case report, the interproximal preparation provided more space for the technician (ceramist) to apply the ceramic which delivers an adequate insertion axis and keeps the restoration in position during the cementation time. Additionally, it offers a correct anatomic proportion among the fragments of thin veneers helping in the diastemas closure.⁸ Therefore a smoother emergency profile and a proper correct gingival contour to accommodate the papilla and to prevent periodontal damages are achieved. In the same way, the chamfer was made to avoid both the incorrect restoration fit and bacterial accumulation that could cause gingival inflammation.⁹

Glass ceramics are the first choice in case of esthetic restorations because of their similarity with dental optical properties,¹⁰ excellent biocompatibility,⁷ great physical and mechanical as well as color stability. Furthermore, they have good adhesion to natural teeth and present abrasion resistance.^{6,10} On the other hand, the ceramics can be negatively affected by humidity and chemical solutions. Acidulated fluorides for example, can cause microfractures which may change the physical properties of these restorations. This degradation process affects the ceramic surface which increases bacterial accumulation and affects the esthetic results. Therefore, the clinicians should consider the presence of ceramic restorations and the type of material used during prophylactic procedures.¹⁰

The success of this type of restorative procedure depends on the correct treatment plan conducted by the clinician in

conjunction with the technician (ceramist), followed by photographs, cast, diagnostic testing, dental reduction guides and mock-up. Through the mock-up is possible to identify lip support, midline position, teeth arrangement, phonetic, occlusion, teeth shape and desired color of the ceramic restorations.^{11,12} The clinician should always respect patient's wishes and have in mind that esthetic concept is subjective.¹¹

Furthermore, since the contact lens of thin porcelain veneers are a new treatment modality, longitudinal studies are warranted to provide more knowledge of this restoration behavior in intraoral conditions. Additionally, its use should be cautiously indicated in case of pockets, gingival recession, sensitivity, secondary caries and dental fractures.¹³

CONCLUSION

The present clinical report showed the use of fragments of thin veneers (contact lens) to re-establish the anterior teeth harmony. Based on the outcomes of this clinical report, we considered such therapy as a successful treatment option after 3 years of follow-up. The restorations are integrated with the surrounding periodontal tissue.

CLINICAL SIGNIFICANCE

The fragments of thin veneers have been established to be an interesting alternative to esthetically restore the anterior teeth with minimal invasiveness. However, since it is a new treatment modality, longitudinal studies are necessary to understand the material's behavior.

REFERENCES

1. Heymann HO. The artistry of conservative esthetic dentistry. *J Am Dent Assoc* 1987; Spec No:14-23E.
2. Malcmacher L. No-preparation porcelain veneers. *Dent Today* 2003;22:66-71.
3. Nash WR. A 6-year follow-up on cerinate porcelain veneers. *Compend Contin Educ Dent* 1998;19:664-69.
4. Nash WR. The contact lens porcelain veneer. *Dent Today* 2003; 22:56-59.
5. Shuman I. Simplified restorative correction of the dentition using contact lens-thin porcelain veneers: A report of three cases. *Dent Today* 2006;25:88-92.
6. Al-Zain A. No-preparation porcelain veneers. 2009. 24f. Dissertation. School of Dentistry, Indiana University, Iupui, 2009. Available in: http://www.iusd.iupui.edu/Depts/GO/Dental_Information.aspx. Accessed in: 16 Set 2010.
7. Barão VA, Gennari-Filho H, Goiato MC, Dos Santos DM, Pesqueira AA. Factors to achieve aesthetics in all-ceramic restorations. *J Craniofac Surg* 2010;21:2007-12.
8. Rouse JS. Full veneer versus traditional veneer preparation: A discussion of interporximal extesion. *J Prosthet Dent* 1997;78: 545-49.
9. Weishaupt P, Bernimoulin JP, Lange KP, Rothe S, Naumann M, Hägewald S. Clinical and inflammatory effects of galvano-ceramic and metal-ceramic crowns on periodontal tissues. *J Oral Rehabilitation* 2007;34:941-47.
10. Ccahuana VZ, Özcan M, Mesquita AM, Nishioka RS, Kimpara ET, Bottino MA. Surface degradation of glass ceramics after exposure to acidulated phosphate fluoride. *J Appl Oral Sci* 2010: 18:155-65.
11. Javaheri D. Considerations for planning esthetic treatment with veneers involving no or minimal preparation. *J Am Dent Assoc* 2007;138:331-37.
12. Magne P, Bercel UC. Novel porcelain laminate preparation approach driven by a diagnostic mock-up. *J Esthet Restor Dent* 2004;16:7-16.
13. Granell-Ruiz M, Fons-Font A, Labaig-Rueda C, Martínez-González A, Juan-Luis Rr, Solá-Ruiz MF. A clinical longitudinal study of 323 porcelain laminate veneers. period of study from 3 to 11 years. *Med Oral Patol Oral Cir Bucal* 2010;15:531-37.

ABOUT THE AUTHORS

Ricardo Coelho Okida

Assistant Professor, Department of Restorative Dentistry, Univ Estadual Paulista (UNESP), Aracatuba Dental School, São Paulo, Brazil

Aljomar José Vechiato Filho

Graduate Student, Department of Dental Materials and Prosthodontics Univ Estadual Paulista (UNESP), Aracatuba Dental School, São Paulo Brazil

Valentim Adelino Ricardo Barão

Post-Doc Research Fellow, Department of Dental Materials and Prosthodontics, Univ Estadual Paulista (UNESP), Aracatuba Dental School, São Paulo, Brazil

Daniela Micheline dos Santos

Assistant Professor, Department of Prosthodontics, Univ Estadual Paulista (UNESP), Aracatuba Dental School, São Paulo, Brazil

Marcelo Coelho Goiato

Associate Professor, Department of Prosthodontics, Univ Estadual Paulista (UNESP), Aracatuba Dental School, São Paulo, Brazil

CORRESPONDING AUTHOR

Aljomar José Vechiato Filho, Graduate Student, Department of Dental Materials and Prosthodontics, Jose Bonifacio, 1193, Aracatuba, São Paulo, Brazil-16015-050, e-mail: jovechiato@hotmail.com